


First case report of nematode parasitic myelopathy in a wild feline in Brazil

Primeiro relato de caso de mielopatia parasitária causada por nematódeo em um felídeo selvagem no Brasil

Cláudia Cerutti Dazzi¹; Alex dos Santos²; Tanise Policarpo Machado¹; Michelli Westphal de Ataíde³; Rubens Rodriguez^{4,5}; Ananda Müller Pereira^{6,7}; Paulina Sepúlveda García⁶; Adriana Costa da Motta^{1*} 

¹ Laboratório de Patologia Animal, Programa de Pós-graduação em Bioexperimentação – PPGBIOEX, Faculdade de Agronomia e Medicina Veterinária – FAMV, Universidade de Passo Fundo – UPF, Passo Fundo, RS, Brasil

² Programa de Pós-graduação em Medicina Veterinária, Área de Concentração em Patologia e Patologia Clínica Veterinária, Centro de Ciências Rurais – CCR, Universidade Federal de Santa Maria – UFSM, Santa Maria, RS, Brasil

³ Clínica e Cirurgia de Animais Silvestres, Curso de Medicina Veterinária, Faculdade de Agronomia e Medicina Veterinária – FAMV, Universidade de Passo Fundo – UPF, Passo Fundo, RS, Brasil

⁴ Curso de Medicina, Faculdade de Medicina – FM, Universidade de Passo Fundo – UPF, Passo Fundo, RS, Brasil

⁵ Instituto de Patologia de Passo Fundo, Passo Fundo, RS, Brasil

⁶ Instituto de Ciencias Clínicas, Facultad de Ciencias Veterinarias, Universidad Austral de Chile, Valdivia, Chile

⁷ Ross University School of Veterinary Medicine, Basseterre, Saint Kitts and Nevis

How to cite: Dazzi CC, Santos A, Machado TP, Ataíde MW, Rodriguez R, Pereira AM, García PS, Motta AC. First case report of nematode parasitic myelopathy in a wild feline in Brazil. *Braz J Vet Parasitol* 2020; 29(1): e014619. <https://doi.org/10.1590/S1984-29612019099>

Abstract

Parasitic myelopathy caused by *Gurltia paralyans* in domestic cats is a disease commonly reported in several South American countries. The adult parasite is lodged in the meningeal veins and spinal cord, often causing clinical manifestations of vascular proliferation, thrombophlebitis, and medullary compression. Wild felines are believed to be the definitive hosts of this parasite. The infection occurs through the ingestion of paratenic hosts, but the life cycle of *G. paralyans* is not yet clearly understood. In this paper, we discuss a case of parasitic myelopathy in a margay (*Leopardus wiedii*) that died during post-surgical care. Necropsy revealed focal hemorrhages in the thoracolumbar spinal cord. A microscopic examination revealed adult nematodes and eggs inside the veins of subarachnoid space in spinal cord, suggesting *G. paralyans* infection. This is first description of parasitic myelopathy in a margay in Brazil.

Keywords: *Gurltia paralyans*, *Leopardus wiedii*, spinal cord.

Resumo

Mielopatia parasitária causada por *Gurltia paralyans* em gatos domésticos é uma doença comumente relatada em vários países da América do Sul. O parasita adulto aloja-se nas veias das meninges e da medula espinhal, muitas vezes causando proliferação vascular, tromboflebite e compressão medular, que se manifestam como sinais clínicos. Acredita-se que os felídeos selvagens sejam hospedeiros definitivos deste parasita e que a infecção ocorre por ingestão de hospedeiros paratênicos, entretanto seu ciclo de vida completo é desconhecido. Aqui, apresentamos um caso de um gato-maracajá (*Leopardus wiedii*) que morreu durante a assistência pós-cirúrgica. Na necropsia, foram observadas hemorragias focais na medula espinhal toracolombar. A microscopia revelou presença de nematódeos adultos e ovos, localizados dentro das veias do espaço subaracnoide da medula espinhal, o que sugeriu a infecção por *G. paralyans*. Esta é a primeira descrição de mielopatia parasitária em um gato-maracajá no Brasil.

Palavras-chave: *Gurltia paralyans*, *Leopardus wiedii*, medula espinhal.

Received August 15, 2019. Accepted October 23, 2019.

*Corresponding author: Adriana Costa da Motta. E-mail: acmotta@upf.br



This is an Open Access article distributed under the terms of the Creative Commons Attribution License, which permits unrestricted use, distribution, and reproduction in any medium, provided the original work is properly cited.

Gurltia paralyans, which is an intravascular parasite that infects domestic cats, belongs to the family Angiostrongylidae and comprises intravascular and pulmonary nematodes (Gómez et al., 2011; Mieres et al., 2013; Bowman, 2014). The adult parasite is found inside leptomeningeal vessels of the spinal cord, or even inside intramedullary venules (Gómez et al., 2011; Rivero et al., 2011; Mieres et al., 2013). Feline myelopathy associated with *G. paralyans* infection was first reported by Wolffhügel in Chile in 1933, and subsequent reports have come from Colombia, Uruguay, and Brazil (Gómez et al., 2010; Rivero et al., 2011; Moroni et al., 2012; Togni et al., 2013). The condition is clinically known as feline crural parasitic paraplegia, and the parasite is acquired through the ingestion of intermediary hosts such as mollusks or small reptiles. Wild felids are believed to be the definitive hosts of this nematode (Gómez et al., 2010; Rivero et al., 2011; Togni et al., 2013). The clinical signs are caused by the combined presence of adult parasites and eggs, and are associated with congestion and thrombosis within the subarachnoid and medullary vessels (Moroni et al., 2012; Mieres et al., 2013). At necropsy, hemorrhagic foci may be present at the sites containing parasites in the spinal cord, but macroscopic lesions are often absent. Microscopic lesions include vascular proliferation due to mechanical obstruction of the subarachnoid spinal cord veins, white matter degeneration, meningomyelitis, and thrombophlebitis (Gómez et al., 2010; Mieres et al., 2013; Togni et al., 2013). This report describes anatomopathological findings of parasitic myelopathy in a margay (*Leopardus wiedii*).

An adult female margay (*Leopardus wiedii*) was found on a road in the city of Chapecó, Santa Catarina, Brazil. The animal, which may have been run over by a vehicle, was unable to move its hind limbs and was taken to the intensive care unit at the Veterinary Hospital of the University of Passo Fundo – UPF. After a physical examination and checkup of its vital signs, blood samples were drawn for a complete blood cell count (CBC), which proved to be within the normal range for the species. A radiograph revealed fracture of the right femur, and thoracic vertebral luxation at T11 and T12. The fracture was treated surgically by intramedullary pinning, and no complications occurred during the procedure. However, a few days after surgery, the animal self-mutilated the operated region and adjacent tissues in the right hind limb, which was immediately amputated. A new post-operative CBC was taken and showed severely low hematocrit and anemia due to the extensive blood loss caused by self-mutilation, resulting in death. Soon thereafter, the animal was necropsied at the Laboratory of Animal Pathology of UPF, where tissue samples were taken from all its organs, fixed in 10% buffered formalin, embedded in paraffin, cut into 5µm thick sections, and stained with hematoxylin and eosin (H&E) for histological examination.

A gross examination revealed pale mucus membranes, absence of right hind limb, thin watery blood, and marked paleness of the internal organs. The stomach contained pieces of hair, skin, muscles, and bones ingested during self-mutilation. The thoracic cavity presented marked hydrothorax. Lungs had areas of atelectasis and a dark rose color associated with normal colored foci resembling pneumonia-like lesions. The remaining organs showed no significant gross abnormalities. A hemorrhagic focus was observed in the thoracolumbar region of the spinal cord.

A microscopic examination of the lungs revealed parasite eggs in various stages of maturation inside alveolar spaces, admixed with xanthomatous macrophages, associated with interstitial sub-acute suppurative pneumonia (moderate to severe). Other discrete lesions found in the lungs were focal emphysema, alveolar septal hyperplasia, diffuse atelectasis, bronchiolar muscle hyperplasia, and bronchial gland dilation. Lumbar spinal cord segments contained adult nematodes with cuticle (Figure 1 and 2), muscle layer, pseudocoelomic cavity, digestive and reproductive tract (Figure 3), and embryonated eggs inside subarachnoid venules associated with vascular proliferation and thrombi. These parasites were characterized morphologically as *G. paralyans*. There was distention of subarachnoid space, and mild lymphoplasmacytic infiltration surrounding the parasites.

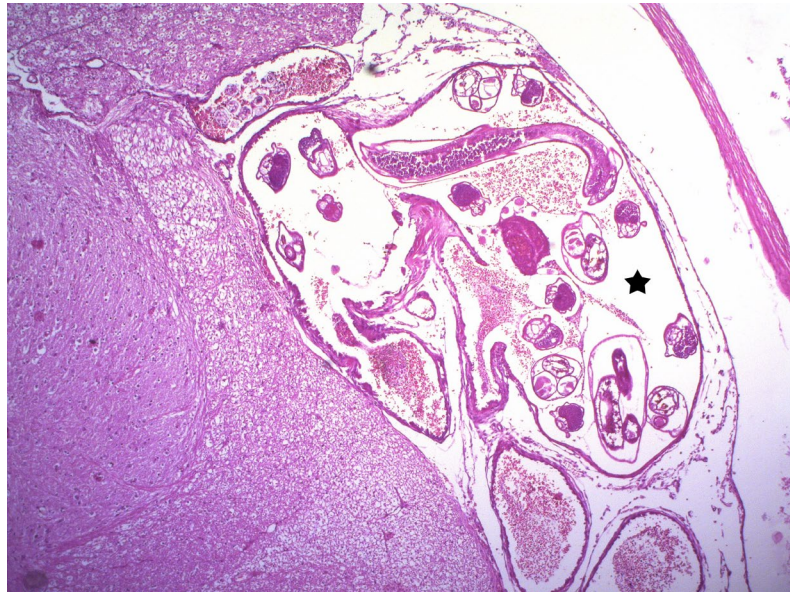

Figure 1. Transverse and longitudinal sections of adult nematodes (*Gurltia paralyans*) inside the lumbar spinal cord vein lumen (star) of *Leopardus wiedii*. H&E staining, 50x magnification.

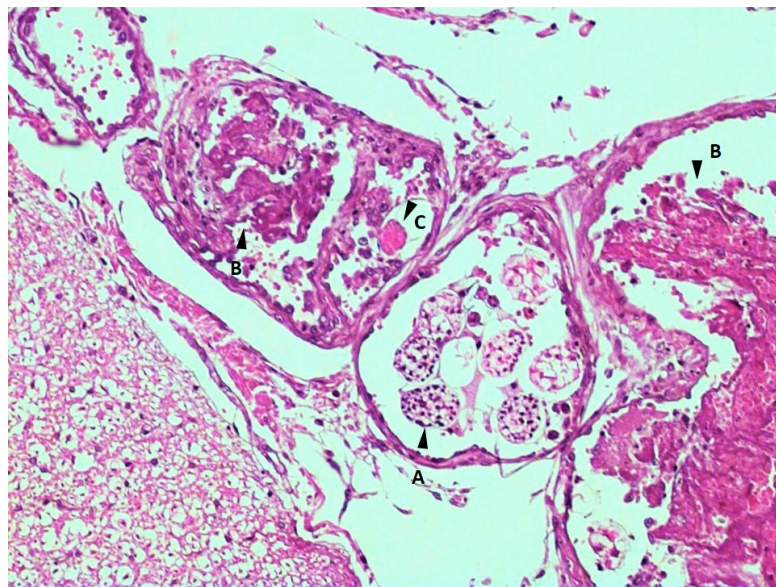


Figure 2. (A) Nematode eggs in different stages of development inside the vein lumen; (B) Vascular thrombosis; (C) Deteriorated egg. H&E staining, 100x magnification.

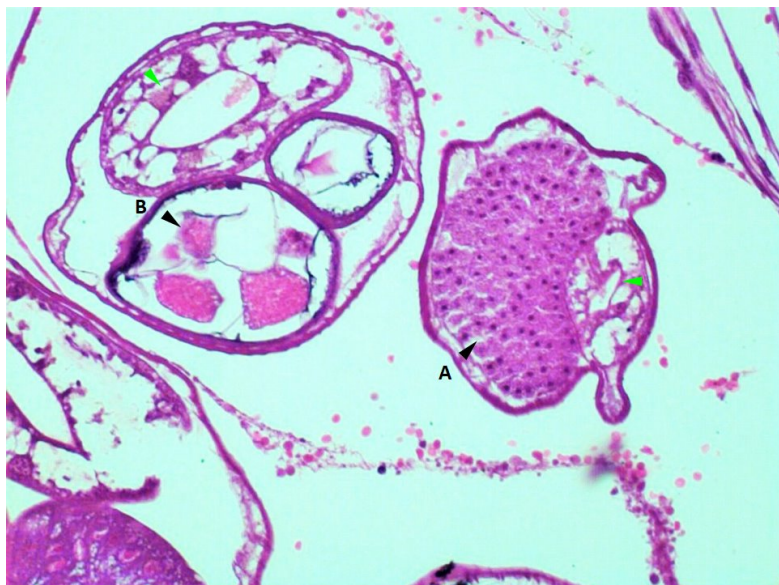


Figure 3. Adult nematodes (*Gurltia paralyzans*) in the vascular lumen: (A) Male reproductive tract containing male gametes (black arrow) and digestive tube (green arrow); (B) Female reproductive tract containing eggs (black arrow) and digestive tube (green arrow). H&E staining, 200x magnification.

To confirm the presence of *G. paralyzans* and exclude that of other parasites (in lungs), spinal cord and lung fragments embedded in paraffin were sent for molecular detection to the Laboratory of Veterinary Clinical Pathology at the Austral University of Chile. DNA was extracted following the instructions on the kit of the ReliaPrep™ FFPE gDNA Miniprep System (Promega), and this procedure was repeated three times. First, a conventional polymerase chain reaction (PCR) for mammalian endogenous IRBP gene was performed using the primers IRBP-F (5′-TCC AAC ACC ACC ACT GAG ATC TGG AC- 3′) and IRBP-R (5′-GTG AGG AAG AAA TCG GAC TGG CC- 3′) to confirm the quality and presence of DNA. Only one sample (lung) tested positive. Immediately thereafter, this sample was subjected to nested PCR for *G. paralyzans* and *Aelurostrongylus abstrusus* using the generic primer sets AaGp28Sa1 (5′-AGGCATAGTTCACCATCT-3′) and AaGp28Ss1 (5′-CGAGTRATATGTATGCCATT-3′). In the second row, a generic primer AaGp28Ssa1 (5′-AGGCATAGTTCACCATCT-3′) was associated with a specific primer Aa28Ss2 (5′-CGTTGATGTTGATGAGTATC-3′) for the detection of gen 28S rRNA of *A. abstrusus* (final product 300pb) and the generic primer AaGp28Ss1 (5′-CGAGTRATATGTATGCCATT-3′) associated with a specific primer Gp28Sa3 (5′-TCTTGCCGCCATTATAGTAG-3′) for the detection of gen 28S rRNA of *G. paralyzans* amplification (product 356pb). Unfortunately, our sample tested negative in the nested PCR, although positive and negative controls showed the expected results.

The morphological features of the parasite and its location inside the medullary veins were compatible with those of the nematode parasite *G. paralyzans* commonly reported in domestic felines (Gómez et al., 2010, 2011; Rivero et al., 2011; Mieres et al., 2013; Togni et al., 2013). Wild felids are believed to be the definitive hosts of this parasite (Gómez et al., 2010; Rivero et al., 2011; Togni et al., 2013), with Geoffroy's cat (*Leopardus geoffroyi*) suspected to be the definitive host in Rio Grande do Sul, Brazil (Togni et al., 2013) and the kodkod (*Leopardus guigna*) in Chile, despite the absence of data that confirm this hypothesis.

The kodkod, also known as güiña, is also suspected of harboring *G. paralyzans* in its lungs, closing the parasitic cycle and corresponding to the definitive host (Gómez et al., 2010, 2011; Rivero et al., 2011; Togni et al., 2013). However, our lung findings should be

considered with caution. The morphology of eggs and larvae, associated inflammatory response and lesions were compatible with nematodes, and adult parasites were found in spinal cord but not in lung tissue. This information would seem to suggest that the eggs came from *G. paralyans*, as reported by Rivero et al. (2011). Unfortunately, the fact is that the lungs of domestic and wild felines may harbor other nematodes, such as *A. abstrusus* (Ferreira da Silva et al., 2005; Traversa et al., 2014), and that these felines may have concomitant parasite infections (Dib et al., 2018). What we can state unequivocally is that no adult parasites were present in bronchi or bronchioles, a common finding in *A. abstrusus* infection. Therefore, to ascertain a possible role of *G. paralyans* in the lung pathology, the paraffin embedded tissues were subjected to nested PCR (Muñoz et al., 2017). Unfortunately, however, the samples did not amplify due to DNA and rRNA degradation, possibly because of prolonged formalin fixation, paraffin embedding time and conservation, processing temperature or PCR inhibitors in the samples (Merkelbach et al., 1997; Macabeo-Ong et al., 2002; Malik et al., 2013; Rodriguez et al., 2014).

Hemorrhagic lesions detected in the lumbar spinal cord were consistent with previously reported necropsy findings of domestic felines infected with this parasite (Gómez et al., 2010, 2011; Rivero et al., 2011). However, the pelvic muscular atrophy usually observed in such cases (Togni et al., 2013) was absent. The venous proliferation, thrombus formation, and subarachnoid space distention found here are consistent with parasitic myelopathy (Gómez et al., 2010, 2011; Rivero et al., 2011; Mieres et al., 2013; Togni et al., 2013). In chronic cases, gray matter necrosis (Gómez et al., 2011; Togni et al., 2013), meningeal macrophages, mild presence of axonal spheroids, and areas of microgliosis are also noted (Gómez et al., 2011; Rivero et al., 2011). The general pallor found at necropsy was attributed to extensive blood loss caused by self-mutilation, leading to hypovolemic shock and death.

It is difficult to make a diagnosis based on clinical signs, given that the neurological symptoms of other disorders such as neoplasia and infection of the nervous system resemble those of parasitic myelopathy (Gómez et al., 2010; Mieres et al., 2013; Togni et al., 2013). Therefore, imaging techniques such as magnetic resonance imaging, radiography, and computed tomography may be helpful for the clinical diagnosis of the disease (Mieres et al., 2013). No fecal examination was performed in this case, but *G. paralyans* eggs are not shed in the feces of infected domestic cats; instead, they are usually present inside medullary veins (Gómez et al., 2010; Moroni et al., 2012). In *A. abstrusus* infection, larvae are eliminated through feces, and can be identified easily in routine laboratory fecal examinations (Ferreira Da Silva et al., 2005).

In conclusion, taken together, the histopathological findings, the parasite's location inside subarachnoid vessels, and its morphological features suggest a diagnosis of parasitic myelopathy caused by *G. paralyans*. This is the first reported case of this parasite in wild felines in Brazil.

References

- Bowman DD. *Georgis' parasitology for veterinarians*. 10th ed. St. Louis: Elsevier Saunders; 2014.
- Dib LV, Cronemberger C, Pereira FA, Bolais PF, Uchôa CMA, Bastos OMP, et al. Gastrointestinal parasites among felids inhabiting the Serra dos Órgãos National Park, Rio de Janeiro, Brazil. *Ver Bras Parasitol Vet* 2018; 27(2): 131-140. <http://dx.doi.org/10.1590/s1984-296120180016>. PMID:29846454.
- Ferreira da Silva JM, Pereira da Fonseca IM, Madeira de Carvalho LM, Meireles JAFS, Fazendeiro I. Pneumonia em gato por *Aelurostrongylus abstrusus*: necessidade de um diagnóstico precoce. *RPCV* 2005; 100(553-554): 103-106.
- Gómez GA, Taborda DA, Alzate A, Gutiérrez JJC. Domestic cat paraplegia compatible with *Gurllia paralyans* nematode: first cases reported in Colombia. *Rev Colomb Cienc Pecu* 2011; 24(4): 663-669.

- Gómez M, Mieres M, Moroni M, Mora A, Barrios N, Simeone C, et al. Meningomyelitis due to nematode infection in four cats. *Vet Parasitol* 2010; 170(3-4): 327-330. <http://dx.doi.org/10.1016/j.vetpar.2010.02.039>. PMID:20307937.
- Macabeo-Ong M, Ginzinger DG, Dekker N, McMillan A, Regezi JA, Wong DTW, et al. Effect of duration of fixation on quantitative reverse transcription polymerase chain reaction analyses. *Mod Pathol* 2002; 15(9): 979-987. <http://dx.doi.org/10.1097/01.MP.0000026054.62220.FC>. PMID:12218216.
- Malik R, Smits B, Reppas G, Laprie C, O'Brien C, Fyfe J. Ulcerated and nonulcerated nontuberculous cutaneous mycobacterial granulomas in cats and dogs. *Vet Dermatol* 2013; 24(1): 146-153. <http://dx.doi.org/10.1111/j.1365-3164.2012.01104.x>. PMID:23331691.
- Merkelbach S, Gehlen J, Handt S, Füzesi L. Novel enzyme immunoassay and optimized DNA extraction for the detection of polymerase-chain-reaction-amplified viral DNA from paraffin-embedded tissue. *Am J Pathol* 1997; 150(5): 1537-1546. PMID:9137080.
- Mieres M, Gómez MA, Lillo C, Rojas MA, Moroni M, Muñoz P, et al. Clinical, imaging, and pathologic characteristics of *Gurltia paralyans* myelopathy in domestic cats from Chile. *Vet Radiol Ultrasound* 2013; 54(3): 237-244. <http://dx.doi.org/10.1111/vru.12026>. PMID:23464605.
- Moroni M, Muñoz P, Gómez M, Mieres M, Rojas MA, Lillo C, et al. *Gurltia paralyans* (Wolffhügel, 1933): description of adults and additional case reports of neurological diseases in three domestic cats from southern Chile. *Vet Parasitol* 2012; 184(2-4): 377-380. <http://dx.doi.org/10.1016/j.vetpar.2011.08.035>. PMID:21944845.
- Muñoz P, Hirzmann J, Rodriguez E, Moroni M, Taubert A, Gibbons L, et al. Redescription and first molecular characterization of the little known feline neurotropic nematode *Gurltia paralyans* (Nematoda: metastrongyloidea). *Vet Parasitol Reg Stud Rep* 2017; 10: 119-125. <http://dx.doi.org/10.1016/j.vprsr.2017.10.001>. PMID:31014582.
- Rivero R, Matto C, Adrien ML, Nan F, Bell T, Gardiner C. Parasite meningomyelitis in cats in Uruguay. *Rev Bras Parasitol Vet* 2011; 20(3): 259-261. <http://dx.doi.org/10.1590/S1984-29612011000300017>. PMID:21961761.
- Rodriguez R, da Silva ACA, Müller CA, Alves SL, Graeff-Teixeira C, Fornari F. PCR for the diagnosis of abdominal angiostrongyliasis in formalin-fixed paraffin-embedded human tissue. *PLoS One* 2014; 9(4): e93658. <http://dx.doi.org/10.1371/journal.pone.0093658>. PMID:24705328.
- Togni M, Panziera W, Souza TM, Oliveira JC, Fo, Mazzanti A, Barros CSL, et al. Aspectos epidemiológicos, clínicos e anatomopatológicos da infecção por *Gurltia paralyans* em gatos. *Pesq Vet Bras* 2013; 33(3): 363-371. <http://dx.doi.org/10.1590/S0100-736X2013000300015>.
- Traversa D, Romanucci M, Di Cesare A, Malatesta D, Cassini R, Iorio R, et al. Gross and histopathological changes associated with *Aelurostrongylus abstrusus* and *Troglostrongylus brevior* in a kitten. *Vet Parasitol* 2014; 201(1-2): 158-162. <http://dx.doi.org/10.1016/j.vetpar.2014.01.020>. PMID:24548702.

Erratum

In the article "First case report of nematode parasitic myelopathy in a wild feline in Brazil" (<https://doi.org/10.1590/S1984-29612019099>) published in issue 1, volume 29, 2020, the Brazilian Journal of Veterinary Parasitology, on page 1, which reads:

Cláudia Ceruti Dazzi

Read up:

Cláudia Cerutti Dazzi

