



The effects of Cyclosporin A and *Heteropterys tomentosa* on the rat liver

KARINE M. DE FREITAS¹, JACQUELINE M. ALMEIDA¹, JULIANA C. MONTEIRO²,
MARIA APARECIDA S. DIAMANTE¹, JÉSSICA S.F. DO VALE¹, CAMILA CAMARGO³,
MARÇAL H.A. JORGE⁴ and HEIDI DOLDER¹

¹Departamento de Biologia Estrutural e Funcional, Universidade Estadual de Campinas,
Avenida Bertrand Russel, s/n, Bairro Cidade Universitária, 13083-865 Campinas, SP, Brasil

²Departamento de Ciências Agronômicas e Biológicas, Universidade Federal do Espírito Santo,
Espírito Santo, BR 101 Norte, Km 60, Bairro Litorâneo, 29932-540 São Mateus, ES, Brasil

³Departamento de Bioquímica, Universidade Estadual de Campinas,
Rua Monteiro Lobato, 255, Bairro Cidade Universitária, 13083-970 Campinas, SP, Brasil

⁴Tecnologia de Mudanças e Sementes, Empresa Brasileira de Pesquisa Agropecuária/Embrapa Hortaliças,
BR 060, Km 09, Fazenda Tamanduá, 70351-970 Gama, DF, Brasil

Manuscript received on August 29, 2013; accepted for publication on September 8, 2014

ABSTRACT

Cyclosporin A (CsA) is a widely employed immunosuppressive drug that is associated with several side effects, among them hepatotoxicity. *Heteropterys tomentosa* is a Brazilian plant efficient in reducing damage caused by CsA on the rat testis and prostate. The aim of this study was to evaluate the effect of CsA and *H. tomentosa* (administered isolated or simultaneously) on the liver of Wistar rats. The animals were treated daily with water (control), CsA (15mg/kg/day), *H. tomentosa* infusion or CsA+*H. tomentosa*, for 21 or 56 days. The treatments did not alter liver morphology or cause fibrosis. *H. tomentosa* administered for 21 days increased the number of hepatocyte nuclei and Kupffer cell volumetric proportion. After 56 days of treatment, *H. tomentosa* administration did not alter the parameters analyzed. Biochemical plasma dosages and liver stereology showed impairment caused by CsA-treatment after 21 days; these results were not observed after 56 days of treatment. The simultaneous treatment with CsA and *H. tomentosa* for 21 or 56 days did not alleviate nor accentuate CsA hepatic effects. The present study showed that the 21 days treatment with CsA caused more alteration to the liver than the 56 days treatment; this could be related to hepatic recovery after the long term treatment.

Key words: hepatotoxicity, *Heteropterys aphrodisiaca*, medicinal plant, phytotherapy.

INTRODUCTION

Cyclosporin A (CsA) is a neutral, hydrophobic, cyclic peptide with 11 amino acids (Shevach 1985) that is administered as an immunosuppressant drug (Shevach 1985, Matsuda and Koyasu 2000). This drug is widely used to treat autoimmune diseases,

being associated with reduction in the number of hospitalization days for transplanted patients and for rejection episodes (Rezzani 2004). However, several side effects are associated with CsA treatment such as: nephrotoxicity (Bertani et al. 1987, Baliga et al. 1997, Fellstrom 2004, Rezzani 2004, Hagar et al. 2006, Josephine et al. 2006, 2007, Rezzani et al. 2006b), hepatotoxicity (Durak

Correspondence to: Karine Moura de Freitas
E-mail: karinemfreitas@gmail.com

et al. 2004, Hagar 2004, Rezzani 2004, 2006, Kurus et al. 2008, Bohmer et al. 2011), testicular dysfunction (Monteiro et al. 2008) and damages to the ventral prostate (Freitas et al. 2012a). Most of these are related to the increase of reactive oxygen species (Wolf et al. 1997, Buffoli et al. 2005, Rezzani 2006), causing damage to tissue structure and functional disorders (Whiting et al. 1983).

Several researchers have investigated substances that reduce CsA side effects (Rezzani et al. 2001, 2006a, b, Parra Cid et al. 2003, Monteiro et al. 2008, Wongmekiat et al. 2008). *Heteropterys tomentosa* A. Juss. (sin. *Heteropterys aphrodisiaca* O. Mach.), a native species from the Brazilian "Cerrado" (a savannah-like biome), is used by the local population as a hypoglycemic to treat diabetes (Guarim Neto and Morais 2003, Macedo and Ferreira 2004), as an aphrodisiac and to treat nervous weakness and collapse (Corrêa 1984, Pott and Pott 1994). The antioxidant properties of *H. tomentosa* root extract (BST0298) were demonstrated by Mattei et al. (2001), and this same extract was also efficient in the recovery of learning and memory of aged rats (Galvão et al. 2002). *H. tomentosa* root infusion has been successfully used to reduce CsA-related effects on testicular tissue (Monteiro et al. 2008), ventral prostate and biochemical parameters related to hepatotoxicity – plasma levels of glutamic oxaloacetic transaminase, total and indirect bilirubin and cholesterol (Freitas et al. 2013).

Considering the well documented hepatic damage caused by CsA, which is probably due to oxidative stress, and the potential of *H. tomentosa* as an antioxidant, we investigated the potential benefits of using this medicinal plant against the CsA-related hepatotoxicity. The following aspects were studied: (1) determination of the side effects of CsA on the liver structure and function; (2) evaluation of hepatotoxicity caused by *H. tomentosa* intake; (3) effects of simultaneous treatment with CsA and *H. tomentosa*.

MATERIALS AND METHODS

PREPARATION OF THE TREATMENT SOLUTIONS

The methodology used for infusion preparation was the same as that used by previous authors (Monteiro et al. 2008, 2011, Gomes et al. 2011, Freitas et al. 2012b, 2013). In brief, *Heteropterys tomentosa* A. Juss. (sin. *Heteropterys aphrodisiaca* O. Mach., herbarium CPAP number 21625) roots were obtained from plants cultivated by Embrapa Pantanal in Corumbá, MS, Brazil. The plants were grown in controlled conditions of soil, fertilization and irrigation, without insecticides. The roots were harvested, dried and ground. The infusion was prepared immersing ground roots (75.76mg/kg of body weight) in 100mL of boiled water; the animals' weight was used to calculate quantity of ground roots. The infusion was maintained at room temperature for 4 hours, and then filtered. It was kept at 4° C and used for two days.

Cyclosporin A (Sandimmun Neoral[®], Novartis Pharma AG, Switzerland) was administered in a therapeutic dose (15mg/kg body weight) as in previous studies (Chung et al. 2005, Kotolová et al. 2006, Monteiro et al. 2008, Bohmer et al. 2011, Freitas et al. 2012a, 2013).

EXPERIMENTAL ANIMALS AND PROTOCOL

This experimental protocol was carried out according to the standards of the Brazilian Society for Laboratory Animals Sciences (SBCAL/COBEA) and was approved by the Ethics Committee for Animal Studies of the State University of Campinas (Protocol number 2295-1). The treatment protocol was similar to that previously employed (Monteiro et al. 2008, Freitas et al. 2013).

Forty Wistar rats (*Rattus norvegicus* albinus), eight weeks old, were obtained from the Multi-research Center for Biological Investigation of Laboratory Animal - CEMIB (State University of Campinas, Campinas - SP, Brazil) and maintained under standard conditions with 12h light/dark

periods, fed with commercial chow and water “*ad libitum*”. They were separated into two groups of 20 animals each. One group was treated for 21 days and the other for 56 days. In each group, the animals were separated in 4 subgroups (n=5 in each): Control groups (CG) received 0.5mL of distilled water; CsA-treated groups (CsA) received CsA diluted in 0.5 mL distilled water; *H. tomentosa* treated groups (Ht) received 0.5mL of infusion; and groups treated with CsA and *H. tomentosa* (CsA+Ht) received the CsA dose diluted in 0.5 mL of infusion. All treatments were administered daily, by gavage.

The administrations of CsA for 21 (Buffoli et al. 2005, Rezzani et al. 2005a, b, Türk et al. 2007) or 56 days (Monteiro et al. 2008, Freitas et al. 2012a, 2013) were chosen based on previous experiments reported in literature.

COLLECTION OF THE BIOLOGICAL SAMPLES

The animals were weighed and anesthetized with Xylazine and Ketamine (5 and 80 mg/kg, respectively) by intramuscular injection. Blood was collected from the left ventricle by cardiac puncture using Vacuette® tubes with heparin, centrifuged at 3500rpm for 10 minutes (4° C) and the plasma was collected for further biochemical analyses. The liver was collected and weighed. Liver relative weight (%) was calculated using the formula: (Liver weight x 100)/ body weight.

PLASMA BIOCHEMISTRY

The plasma was used to quantify the levels of glucose (Kit Laborlab®, enzymatic and colorimetric methods), triglycerides (Kit Bioclin®, enzymatic and colorimetric methods), total cholesterol (Kit Laborlab®, enzymatic and colorimetric methods), total proteins (by refractometry, analysis made at VetPat Laboratory), creatinine (Kit Bioclin® Kit, colorimetric and kinetic methods), alkaline phosphatase (Kit Laborlab®, kinetic method), glutamic pyruvate transaminase/aspartate amino-

transferase (GPT/AST) (Kit Bioclin®, colorimetric method) and glutamic oxaloacetic transaminase/alanine aminotransferase (GOT/ALT) (Kit Bioclin®, colorimetric method).

LIGHT MICROSCOPY

Liver fragments were fixed in 4% paraformaldehyde (in phosphate buffer 0.1M, pH 7.4) for 24 hours, at room temperature. The fragments were washed in the same buffer, dehydrated in ethanol, cleared in xylol and embedded in paraffin (Histosec®, Leica). The tissue was sectioned with 5µm thickness. One slide was stained with hematoxylin and eosin for morphological, morphometrical and stereological analyses. Another slide was stained with Masson's trichrome (EasyPath® kit) for fibrosis detection.

MORPHOMETRICAL AND STEREOLOGICAL ANALYSES

The proportions of hepatocytes (nuclei and cytoplasm), sinusoid capillaries and Kupffer cells were estimated using a grid with 130 intersections over digital images (40x objective). Ten images were analyzed per animal. The number and diameter of all hepatocyte nuclei were counted and measured, respectively, in 10 fields per animal (40x objective), in which each field had $2.97 \times 10^4 \mu\text{m}^2$. The number of hepatocyte nuclei (HN) per μm^2 was calculated ($\text{HN}/\mu\text{m}^2 = \text{Number of Hepatocytes per field} / \text{field area}$). Hepatocyte nuclei volume (NV) was calculated using the formulas: $\text{area} = \pi r^2$ and $\text{volume} = 4/3\pi r^3$. The hepatocyte cytoplasm volume (CV) was calculated using the formula: $\text{CV} = (\text{NV} \times \text{cytoplasm proportion}) / \text{nuclei proportion}$. The hepatocyte volume was the sum of nuclei and cytoplasm volumes.

STATISTICAL ANALYSES

A nonparametric test (Kruskal Wallis Multiple Comparison) was performed using the software Minitab 16. For all the tests the significance was 95%. All values are shown as mean \pm standard deviation (SD).

RESULTS

CYCLOSPORIN A - EFFECTS ON LIVER

CsA treatment did not alter the liver absolute and relative weight (Figure 1). The tissue structure did not show any alteration either (Figures 2 and 3) and fibrosis was not observed even after 56 days of treatment.

Volumetric proportions of hepatocytes were reduced in the group treated with CsA for 21 days ($p=0.045$); and the volumetric proportions of sinusoids increased 29.06%, however this alteration was not statistically significant. These results were not observed after treatment with CsA for 56 days (Table I).

The treatment with CsA for 21 days increased total cholesterol ($p=0.021$) and in comparison to the control group (Table II). GOT levels were 40.38% higher in the CsA group when compared to the control, however the difference was not statistically significant ($p=0.06$). Yet, the treatment with CsA for 56 days increased GPT levels ($p=0.012$) (Table II).

Heteropterys tomentosa - EFFECTS ON THE LIVER

The treatment with *H. tomentosa* (during 21 and 56 days) did not alter liver absolute and relative weights (Figure 1) or the morphology (Figures 2

and 3) and nor did it cause fibrosis. However, an increase of the volumetric proportion of Kupffer cells was observed after treatment with the infusion for 21 days ($p=0.013$). Furthermore, these animals showed an increase of hepatocyte nucleus proportion and a reduction of their cytoplasm ($p=0.003$) (Table I). Higher number of hepatocyte nuclei was found per μm^2 ($p=0.023$). The treatment with *H. tomentosa* also reduced the total and the cytoplasmic volume of hepatocytes ($p=0.002$ and 0.001 respectively) (Table I).

No alterations of hepatic morphometry/stereology and plasma parameters were observed after the treatment with *H. tomentosa* for 56 days (Tables I and II).

CSA AND *H. tomentosa* ASSOCIATED - EFFECTS ON THE LIVER

As observed in the other groups, simultaneous treatment with CsA and infusion did not alter liver absolute and relative weights (Figure 1) or morphology (Figures 2 and 3) and did not cause fibrosis.

The group CsA+Ht (21 days) did not show the alterations observed for the CsA group (21 days) (Table I). On the other hand, in this group the volumetric proportion of Kupffer cells increased ($p=0.002$). This was also observed for animals treated only with *H. tomentosa* (during

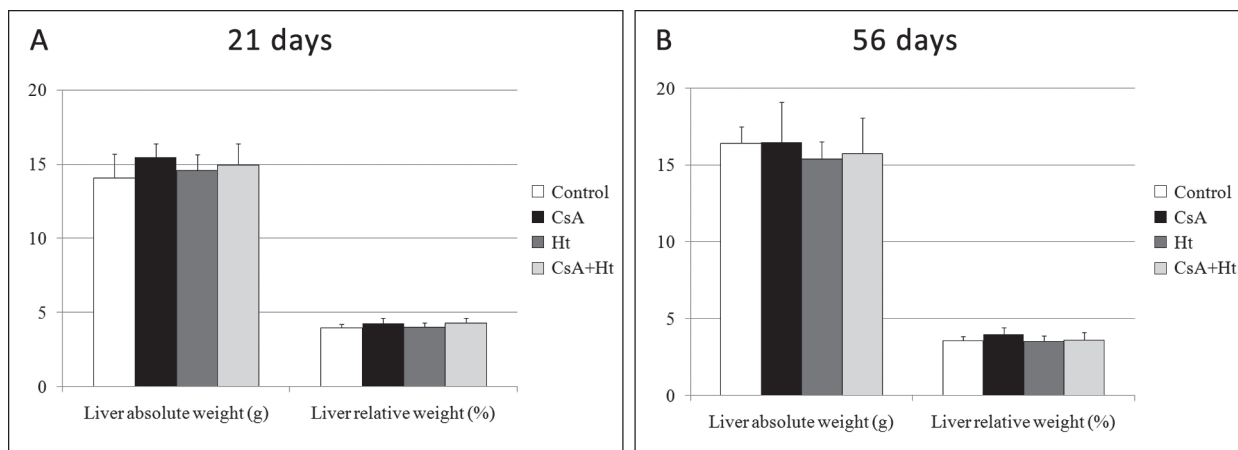


Figure 1 - Liver absolute (g) and relative weight (%). Control, treated with CsA (CsA), *Heteropterys tomentosa* (Ht) and CsA + *H. tomentosa* (CsA+Ht), for 21 or 56 days.

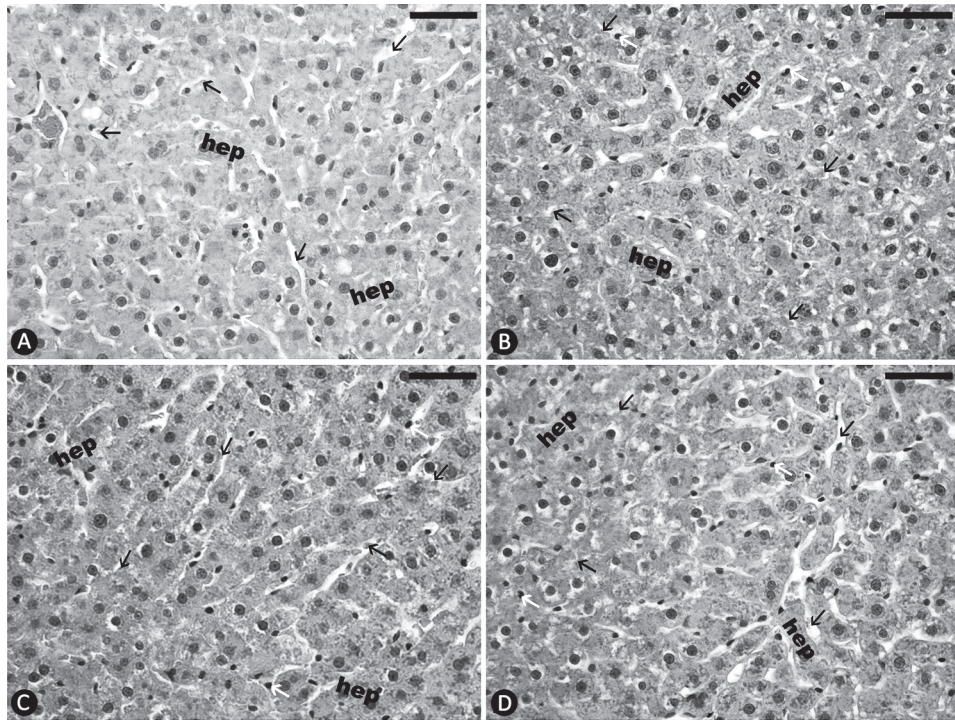


Figure 2 - Liver (H&E staining). Control (A), treated with CsA (B), *H. tomentosa* infusion (C) and both substances (D), for 21 days. Hep: hepatocytes; white arrows: Kupffer cells; black arrows: sinusoids. Bars= 50 μ m.

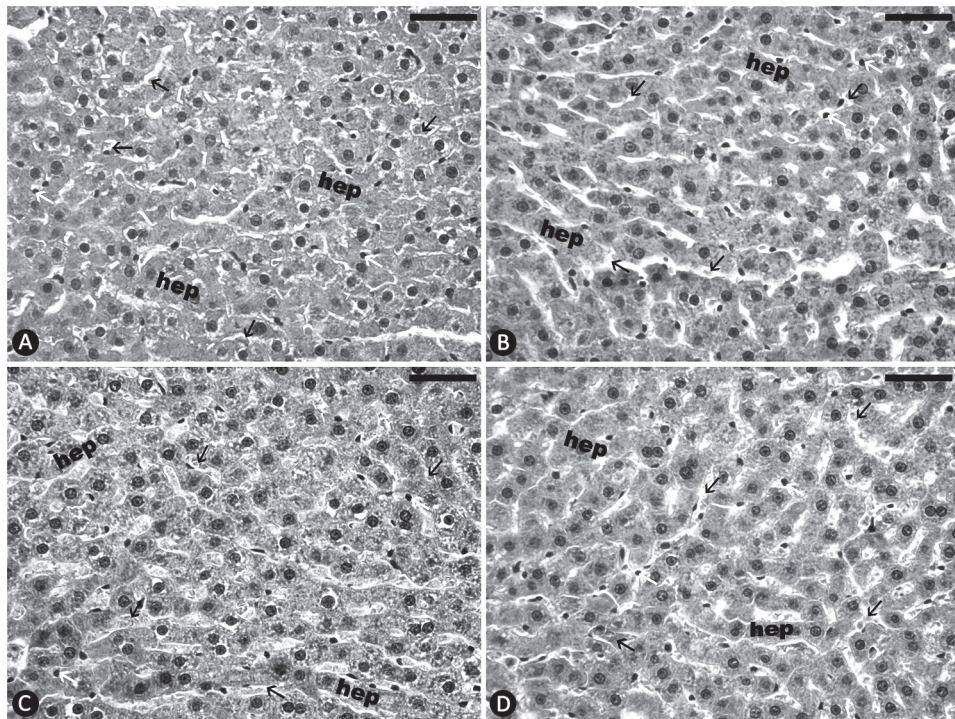


Figure 3 - Liver (H&E staining). Control (A), treated with CsA (B), *H. tomentosa* infusion (C) and both (D) for 56 days. Hep: hepatocytes; white arrows: Kupffer cells; black arrows: sinusoids. Bars= 50 μ m.

TABLE I
Hepatic parameters of Wistar rats treated with water (control), CsA,
***H. tomentosa* infusion or CsA+*H. tomentosa* infusion for 21 or 56 days.**

Parameters	Groups							
	21 Days				56 Days			
	CG	CsA	Ht	CsA+Ht	CG	CsA	Ht	CsA+Ht
Volumetric Proportions (%)								
Hepatocytes (% nuclei; % cytoplasm)	89.15 ± 2.39 ^a (11.39 ± 1.28 ^a ; 88.61 ± 1.28 ^a)	86.17 ± 2.61 ^b (12.22 ± 0.69 ^a ; 87.78 ± 0.69 ^a)	88.48 ± 1.08 ^{ab} (15.19 ± 1.69 ^b ; 84.81 ± 1.69 ^b)	90.46 ± 1.50 ^a (12.24 ± 2.37 ^{ab} ; 87.76 ± 2.37 ^{ab})	90.09 ± 2.04 (11.85 ± 1.67; 88.15 ± 1.67)	90.26 ± 2.83 (12.72 ± 1.89; 87.28 ± 1.89)	89.01 ± 4.64 (11.88 ± 1.50; 88.12 ± 1.50)	88.71 ± 0.85 (12.12 ± 2.04; 87.88 ± 2.04)
Sinusoids	9.43 ± 2.38 ^{ab}	12.17 ± 2.87 ^a	9.14 ± 1.06 ^{ab}	7.01 ± 1.26 ^b	8.06 ± 1.56	7.37 ± 3.14	8.71 ± 4.49	8.85 ± 1.09
Kupffer cells	1.41 ± 0.26 ^a	1.65 ± 0.44 ^a	2.38 ± 0.37 ^b	2.52 ± 0.33 ^b	1.85 ± 0.51	2.37 ± 0.45	2.28 ± 0.39	2.45 ± 0.33
Volume (µm ³)								
Hepatocyte	2501.46 ± 145.0 ^a	2267.7 ± 313.1 ^{ab}	1760.0 ± 242.5 ^c	1887.9 ± 281.0 ^{bc}	2265.9 ± 429.7	2111.2 ± 205.3	2322.5 ± 468.4	2525.1 ± 419.7
HC	2217.9 ± 161.0 ^a	1991.9 ± 286.5 ^{ab}	1491.8 ± 198.1 ^c	1661.73 ± 286.6 ^{bc}	2002.7 ± 416.3	1844.96 ± 210.8	2050.3 ± 439.4	2225.0 ± 418.7
HN	283.55 ± 16.67 ^a	275.80 ± 29.40 ^a	268.12 ± 56.89 ^{ab}	226.19 ± 21.23 ^b	263.18 ± 20.25 ^a	266.30 ± 26.53 ^a	272.22 ± 38.02 ^{ab}	300.05 ± 25.85 ^b
Number of HN per area - µm ² (x10 ⁻³)	1.00 ± 0.09 ^a	1.01 ± 0.13 ^a	1.23 ± 0.13 ^b	1.07 ± 0.16 ^{ab}	0.94 ± 0.10 ^a	1.03 ± 0.2 ^{ab}	1.00 ± 0.14 ^{ab}	1.11 ± 0.01 ^b

Control group (CG), Cyclosporin A treated group (CsA), *Heteropterys tomentosa* treated group (Ht) and group with simultaneous treatment of CsA and *H. tomentosa* (CsA+Ht). HC: Hepatocyte cytoplasm; HN: Hepatocyte nucleus. The values are mean ± SD. In each row, values with different superscripts are significantly different (p<0.05) by Kruskal Wallis Multiple Comparison test.

21 days). Higher hepatocyte nuclear volume was observed when compared to the control and the CsA group (21 days) (p=0.004) (Table I). As observed for the Ht group, the simultaneous treatment with CsA and *H. tomentosa* also caused reduction of hepatocyte volume (p=0.012), due to the reduction on cytoplasm volume (p=0.012) (Table I).

In the CsA+Ht group (21 days) the levels of GOT did not differ significantly in relation to the control or the CsA group (Table II). The plasma creatinine levels were higher in CsA+Ht group (21 days) when compared to the control (p=0.049) and CsA (p=0.02) (21 days) (Table II).

Despite the results observed after 21 days of treatment, animals treated with both infusion and CsA for 56 days showed an increase in the number of hepatocyte nuclei per µm² (p=0.04) (Table I).

Total cholesterol and GPT levels were increased in CsA+Ht group (56 days) when compared to the control (p=0.044 and 0.001, respectively) (Table II).

DISCUSSION

Hepatotoxicity induced by CsA administration is widely reported in literature (Wolf et al. 1997, Durak et al. 2004, Hagar 2004, Rezzani 2004, 2005a, 2006, Kurus et al. 2008, Bohmer et al. 2011). There are two possible mechanisms of CsA-induced hepatotoxicity: (1) due to an excess of free radical production during CsA metabolism in the liver; or (2) CsA may impair the antioxidant defense (Durak et al. 2004). Rezzani et al. (2005a) suggested that the oxidative stress induced by CsA is associated with the imbalance of free oxygen radical production and the antioxidant defense system. The increase of CsA-associated oxidative

TABLE II
Plasma biochemical parameters of Wistar rats treated with water (control), CsA, *H. tomentosa* infusion or CsA+*H. tomentosa* infusion for 21 or 56 days.

Parameters	Groups							
	21 Days				56 Days			
	CG	CsA	Ht	CsA+Ht	CG	CsA	Ht	CsA+Ht
Glucose (mg/dL)	272.13 ± 43.46 ^a	276.96 ± 38.77 ^a	301.26 ± 44.94 ^{ab}	367.78 ± 67.54 ^b	305.22 ± 45.02	317.39 ± 75.93	300.39 ± 75.67	293.09 ± 35.36
Total Cholesterol (mg/dL)	93.29 ± 5.45 ^a	105.42 ± 7.82 ^b	91.87 ± 6.35 ^a	103.87 ± 4.08 ^b	104.26 ± 5.21 ^a	108.13 ± 14.58 ^{ab}	101.03 ± 7.12 ^a	114.45 ± 0.07 ^b
Triglycerides (mg /dL)	109.31 ± 7.91 ^{ab}	105.37 ± 9.29 ^{ab}	89.13 ± 25.38 ^a	124.86 ± 22.70 ^b	124.77 ± 19.07	142.02 ± 22.17	123.07 ± 27.89	148.53 ± 30.34
Alkaline Phosphatase (U/L)	109.27 ± 32.12 ^{ab}	129.43 ± 15.40 ^a	72.19 ± 49.68 ^b	124.67 ± 101.20 ^{ab}	86.72 ± 19.17	81.03 ± 23.94	76.45 ± 19.63	97.9 ± 43.92
Total Proteins (g/dL)	6.3 ± 0.2	6.55 ± 0.44	6.45 ± 0.38	6.35 ± 0.25	7.44 ± 0.46	6.92 ± 0.48	7.4 ± 0.58	7.15 ± 0.17
GOT (U/L)	81.21 ± 20.76 ^{ab}	114.21 ± 27.43 ^a	71.36 ± 8.59 ^b	81.19 ± 18.60 ^b	86.57 ± 14.74	91.79 ± 38.12	81.64 ± 12.67	82.43 ± 21.94
GPT (U/L)	41.73 ± 6.26	43.22 ± 11.32	47.14 ± 12.75	46.09 ± 7.74	39.09 ± 3.50 ^a	57.82 ± 14.29 ^{bc}	44.23 ± 5.84 ^{ab}	61.04 ± 5.87 ^c
Creatinine (mg/dL)	0.65 ± 0.11 ^a	0.66 ± 0.06 ^a	0.78 ± 0.09 ^{ab}	0.79 ± 0.09 ^b	0.75 ± 0.07	0.80 ± 0.20	0.73 ± 0.10	0.75 ± 0.10

Control group (CG), Cyclosporin A treated group (CsA), *Heteropterys tomentosa* infusion treated group (Ht) and group with simultaneous treatment of CsA and *H. tomentosa* (CsA+Ht). GOT: Glutamic Oxalacetic Transaminase; GPT: Glutamic Pyruvate Transaminase. The values are mean ± SD. In each row, values with different superscripts are significantly different ($p < 0.05$) by Kruskal Wallis Multiple Comparison test.

stress is positively correlated with biochemical parameter alterations, which are characteristic of hepatotoxicity (Hagar 2004).

According to Bohmer et al. (2011), CsA-associated histopathological changes on the liver comprise sinusoidal dilatation, hepatocyte cytoplasmic vacuolization, cell infiltration, parenchymal mitosis and moderate hepatocellular necrosis. Rezzani et al. (2005a) observed evident liver morphological alterations caused by CsA (15mg/kg/day) subcutaneously injected in Wistar rats, for 30 days. These authors observed widespread cell swelling and congestion of sinusoids. Hagar (2004) observed, in the rabbits' liver, severe hydropic degeneration in parenchymal cells after treatment with CsA (25mg/kg/day, orally during 10 days). However, Bohmer et al. (2011), working with CsA treated animals (5 and 15mg/kg daily) by gavage for 8 weeks, did not observe clear histopathological

and clinicopathological alterations of the liver, which supports our findings. The absence of hepatic histopathological impairment observed in this study can be related to the dose and route of drug administration. Despite the absence of clear morphological alteration, the treatment with CsA for 21 days reduced the volumetric proportion of hepatocytes and increased (not statistically significant) the volumetric proportion of sinusoids. Bohmer et al. (2011) listed sinusoids dilatation as one of the histopathological changes associated with CsA administration. However, the authors did not explain how CsA induced this change.

CsA-associated fibrosis is largely reported in the kidney (Bakker et al. 2003, Ling et al. 2003, Li et al. 2004). Hagar (2004) working with CsA (25mg/kg daily), administered daily to rabbits, observed mild connective tissue proliferation in the liver periportal region. However, in the present

study, CsA did not cause fibrosis even after 56 days of treatment, which was probably due to the lower CsA-dose used in our experiment.

The histopathological alterations were consistent with the biochemical findings. CsA administered for 21 days caused increase of total cholesterol and GOT levels. On the other hand, the treatment with CsA for 56 days caused an increase of GPT levels. Bohmer et al. (2011) did not observe alterations of GOT and GPT levels after treatment of rats with 15mg/kg/day of CsA by gavage for 30 days. According to the authors, CsA caused immunosuppression without hepatotoxicity. The treatment with CsA is known to cause hyperglycemia (Neto et al. 1999, Freitas et al. 2012a) however, in our study this response was not observed even after treatment for 56 days. The simultaneous treatment with *H. tomentosa* and CsA caused an increase of glucose and creatinine level after 21 days of treatment; these effects were not observed after a long term treatment or when the animals were treated with only CsA or *H. tomentosa*.

The increased volumetric proportion of hepatocyte nuclei associated with the infusion treatment can be explained by the higher number of hepatocyte nuclei (hyperplasia) since an increase of nucleus area or volume (hypertrophy) was not observed. The increase of hepatocyte nucleus number and Kupffer cells proportion could indicate toxicity induced by *H. tomentosa* after the treatment for 21 days. The effect of the infusion administration can be associated with the acute treatment since after 56 days of treatment no alterations caused by the plant could be observed. The proliferation of hepatocytes could be related to liver recovery after injury (Tan et al. 2014).

The use of antioxidant substances against CsA-induced hepatotoxicity is reported in literature. The efficiency against CsA-induced hepatotoxicity of taurine (Hagar et al. 2006), oral L-arginine (Kurus et al. 2008), melatonin (Rezzani et al. 2005a) and vitamins C and E (Durak et al. 2004) has been confirmed. According to Ng et al. (2000) flavonoid

compounds exhibit antioxidant and free radical scavenging properties. Flavonoids are also considered as a protective substance against harmful external influences (Hassig et al. 1999). Galvao et al. (2002) listed flavonoid glycosides among the substances present on *H. tomentosa* root extract. However, according to Galvao et al. (2002) it is not possible to affirm if the effects of *H. tomentosa* could be attributed to one or more chemical constituents.

In the present study the treatment with *H. tomentosa* together with CsA for 21 days did not alter sinusoids and hepatocyte proportions, as found for the treatment with CsA (21 days). In addition, the alteration observed in GOT levels after the treatment with CsA (21 days) was not present for animals treated simultaneously with the drug and the infusion. However, the simultaneous treatment (for 21 days) caused alterations of glucose and creatinine levels. The alteration of GPT levels caused by CsA (56 days) also occurred in the CsA+Ht group. The absence of hepatotoxicity after 56 days of CsA administration did not allow the evaluation of *H. tomentosa* protection. The simultaneous treatment administered for 56 days did not induce hepatotoxicity.

Freitas et al. (2013), working with Wistar rats treated with CsA, *H. tomentosa* and both substances, observed an increase of GOT, bilirubin (total and indirect), triglycerides, cholesterol and glucose levels caused by CsA. They also observed that animals treated simultaneously with CsA and infusion showed normalization of GOT, triglycerides and glucose levels. The above authors did not observe any alterations caused by *H. tomentosa* on biochemical parameters of hepatotoxicity. Freitas et al. (2013) worked with 90 days-old Wistar rats and the animals were treated for 56 days with the same dose of CsA and *H. tomentosa* used in the present study. The differences between the present results and the findings of Freitas et al. (2013) could be due to the time of drug administration (in the case of the animals treated for 21 days), the different source of

H. tomentosa roots, animals' initial age (we started the experiment with 56 days-old animals) or the animals' individual sensibility to the treatment.

CONCLUSIONS

The results suggested that the treatment with CsA for 21 days caused hepatotoxicity which was reduced over a longer administration period (56 days). Possibly the hepatic defense system against higher oxidative stress was able to recover during this period with an increase of the enzymes involved in free radical elimination. *H. tomentosa* caused alterations of some of the parameters analyzed, mainly after 21 days of treatment. The association with the plant administration and hepatotoxicity has to be better studied. The simultaneous treatment with CsA and *H. tomentosa* did not accentuate nor attenuate the CsA-related side-effects studied.

ACKNOWLEDGMENTS

The authors wish to thank Fundação de Amparo à Pesquisa do Estado de São Paulo (FAPESP, grant number 2011/01160-6) for the financial support. They are also grateful to Enzo Guidotti Mattioli for the Statistical support. The authors declare that there are no conflicts of interest. This article is part of a PhD thesis.

RESUMO

A Ciclosporina A (CsA) é uma droga imunossupressora amplamente utilizada que está associada a diversos efeitos colaterais, dentre eles hepatotoxicidade. *Heteropterys tomentosa* é uma planta brasileira eficiente na redução dos danos causados pela CsA nos testículos e próstata de ratos. O objetivo deste estudo foi avaliar o efeito da CsA e *H. tomentosa* (administrados isolada ou simultaneamente) no fígado de ratos Wistar. Os animais foram tratados diariamente com água (controle), CsA (15mg/kg/dia), infusão de *H. tomentosa* ou CsA+*H. tomentosa*, por 21 ou 56 dias. Os tratamentos não alteraram a morfologia do fígado nem causaram fibrose. A administração de *H. tomentosa* por 21 dias aumentou o número de núcleos de hepatócitos e proporção volumétrica de células de

Kupffer. Após 56 dias de tratamento, a administração de *H. tomentosa* não alterou os parâmetros analisados. As dosagens bioquímicas plasmáticas e a estereologia do fígado revelaram danos causados pelo tratamento com CsA por 21 dias; estes resultados não foram observados após 56 dias de tratamento. O tratamento simultâneo com CsA e *H. tomentosa* por 21 e 56 dias não atenuou ou acentuou os efeitos hepáticos da CsA. O presente estudo revelou que o tratamento com a CsA por 21 dias causou mais alterações ao fígado que o tratamento durante 56 dias; isso pode estar relacionado a recuperação hepática após o tratamento a longo prazo.

Palavras-chave: hepatotoxicidade, *Heteropterys aphrodisiaca*, planta medicinal, fitoterapia.

REFERENCES

- BAKKER RC, KOOP K, SIJKENS YW, EIKMANS M, BAJEMA IM, DE HEER E, BRUIJN JA AND PAUL LC. 2003. Early interstitial accumulation of collagen type I discriminates chronic rejection from chronic cyclosporine nephrotoxicity. *J Am Soc Nephrol* 14: 2142-2149.
- BALIGA R, UEDA N, WALKER PD AND SHAH SV. 1997. Oxidant mechanisms in toxic acute renal failure. *Am J Kidney Dis* 29: 465-477.
- BERTANI T, PERICO N, ABBATE M, BATTAGLIA C AND REMUZZI G. 1987. Renal injury induced by long-term administration of cyclosporin A to rats. *Am J Pathol* 127: 569-579.
- BOHMER AE, MENDES RIBEIRO CORREA A, DE SOUZA DG, KNORR L, HANSEL G, CORBELLINI LG, DRIEMEIER D, PORTELA LV AND SOUZA DO. 2011. Long-term cyclosporine treatment: evaluation of serum biochemical parameters and histopathological alterations in Wistar rats. *Exp Toxicol Pathol* 63: 119-123.
- BUFFOLI B, PECHANOVA O, KOJSOVA S, ANDRIANTSITOHAINA R, GIUGNO L, BIANCHI R AND REZZANI R. 2005. Provinol prevents CsA-induced nephrotoxicity by reducing reactive oxygen species, iNOS, and NF- κ B expression. *J Histochem Cytochem* 53: 1459-1468.
- CHUNG BH ET AL. 2005. Rosiglitazone protects against cyclosporine-induced pancreatic and renal injury in rats. *Am J Transplant* 5: 1856-1867.
- CORRÊA MP 1984. Dicionário de Plantas Úteis do Brasil e das Exóticas Cultivadas. nº 5, Rio de Janeiro: Ministério da Agricultura/Instituto Brasileiro de Desenvolvimento Florestal, 293 p.
- DURAK I, OZBEK H AND ELGUN S. 2004. Cyclosporine reduces hepatic antioxidant capacity: protective roles of antioxidants. *Int Immunopharmacol* 4: 469-473.
- FELLSTROM B. 2004. Cyclosporine nephrotoxicity. *Transplant Proc* 36: 220S-223S.

- FREITAS KM, MONTEIRO JC, GOMES ML, TABOGA SR AND DOLDER H. 2012a. Cyclosporin A causes impairment of the ventral prostate tissue structure of Wistar rats. *Hum Exp Toxicol* 31:1262-1270.
- FREITAS KM, MONTEIRO JC, GOMES ML, TABOGA SR AND DOLDER H. 2012b. Study of the ventral prostate of Wistar rats treated with *Heteropterys tomentosa* (A. Juss.). *J Med Plants Res* 6: 5640-5646.
- FREITAS KM, MONTEIRO JC, GOMES ML, TABOGA SR AND DOLDER H. 2013. *Heteropterys tomentosa* (A. Juss.) infusion counteracts Cyclosporin a side effects on the ventral prostate. *BMC Complement Altern Med* 13: 30.
- GALVAO SM, MARQUES LC, OLIVEIRA MG AND CARLINI EA. 2002. *Heteropterys aphrodisiaca* (extract BST0298): a Brazilian plant that improves memory in aged rats. *J Ethnopharmacol* 79: 305-311.
- GOMES MLM, MONTEIRO JC, FREITAS KM, SBERVELHERI MM AND DOLDER H. 2011. Association of the infusion of *Heteropterys aphrodisiaca* and endurance training brings spermatogenic advantages. *Biological Research* 44: 235-241.
- GUARIM NETO G AND MORAIS RGD. 2003. Recursos medicinais de espécies do Cerrado de Mato Grosso: um estudo bibliográfico. *Acta Botanica Brasílica* 17: 561-584.
- HAGAR HH. 2004. The protective effect of taurine against cyclosporine A-induced oxidative stress and hepatotoxicity in rats. *Toxicol Lett* 151: 335-343.
- HAGAR HH, EL ETTER E AND ARAFA M. 2006. Taurine attenuates hypertension and renal dysfunction induced by cyclosporine A in rats. *Clin Exp Pharmacol Physiol* 33: 189-196.
- HASSIG A, LIANG WX, SCHWABL H AND STAMPFLI K. 1999. Flavonoids and tannins: plant-based antioxidants with vitamin character. *Med Hypotheses* 52: 479-481.
- JOSEPHINE A, VEENA CK, AMUDHA G, PREETHA SP AND VARALAKSHMI P. 2006. Evaluating the effect of sulphated polysaccharides on cyclosporine a induced oxidative renal injury. *Mol Cell Biochem* 287: 101-108.
- JOSEPHINE A, VEENA CK, AMUDHA G, PREETHA SP AND VARALAKSHMI P. 2007. Protective role of sulphated polysaccharides in abating the hyperlipidemic nephropathy provoked by cyclosporine A. *Arch Toxicol* 81: 371-379.
- KOTOLOVÁ H, KOLLÁR P AND JAROŠOVÁ M. 2006. Carvedilol Protects against Cyclosporine Nephropathy in Rats. *Acta Veterinaria Brno* 75: 85-89.
- KURUS M, ESREFOGLU M, KARABULUT AB, SOGUTLU G, KAYA M AND OTLU A. 2008. Oral L-arginine protects against cyclosporine-induced hepatotoxicity in rats. *Exp Toxicol Pathol* 60: 411-419.
- LI C, YANG CW, PARK JH, LIM SW, SUN BK, JUNG JY, KIM SB, KIM YS, KIM J AND BANG BK. 2004. Pravastatin treatment attenuates interstitial inflammation and fibrosis in a rat model of chronic cyclosporine-induced nephropathy. *Am J Physiol Renal Physiol* 286: F46-57.
- LING H, LI X, JHA S, WANG W, KARETSKAYA L, PRATT B AND LEDBETTER S. 2003. Therapeutic role of TGF-beta-neutralizing antibody in mouse cyclosporin A nephropathy: morphologic improvement associated with functional preservation. *J Am Soc Nephrol* 14: 377-388.
- MACEDO M AND FERREIRA AR. 2004. Plantas hipoglicemiantes utilizadas por comunidades tradicionais na Bacia do Alto Paraguai e Vale do Guaporé, Mato Grosso - Brasil. *Revista Brasileira de Farmacognosia* 14: 45-47.
- MATSUDA S AND KOYASU S. 2000. Mechanisms of action of cyclosporine. *Immunopharmacology* 47: 119-125.
- MATTEI R, PAZ BARROS M, GALVÃO S, BECHARA E AND DE ARAUJO CARLINI E. 2001. *Heteropterys aphrodisiaca* O. Machado: effects of extract BST 0298 on the oxidative stress of young and old rat brains. *Phytother Res* 15: 604-607.
- MONTEIRO J, PREDES F, MATTÁ S AND DOLDER H. 2008. *Heteropterys aphrodisiaca* infusion reduces the collateral effects of cyclosporine A on the testis. *Anat Rec (Hoboken)* 291: 809-817.
- MONTEIRO JC, GOMES ML, TOMIOSSO TC, NAKAGAKI WR, SBERVELHERI MM, FERRUCCI DL, PIMENTEL ER AND DOLDER H. 2011. More resistant tendons obtained from the association of *Heteropterys aphrodisiaca* and endurance training. *BMC Complement Altern Med* 11: 51.
- NETO AB ET AL. 1999. Metabolic and ultrastructural effects of cyclosporin A on pancreatic islets. *Transpl Int* 12: 208-212.
- NG TB, LIU F AND WANG ZT. 2000. Antioxidative activity of natural products from plants. *Life Sci* 66: 709-723.
- PARRA CID T, CONEJO GARCÍA J, CARBALLO ALVAREZ F AND DE ARRIBA G. 2003. Antioxidant nutrients protect against cyclosporine A nephrotoxicity. *Toxicology* 189: 99-111.
- POTT A AND POTT VJ 1994. *Plantas do Pantanal*. Corumbá: Empresa Brasileira de Pesquisa Agropecuária do Pantanal, 320 p.
- REZZANI R. 2004. Cyclosporine A and adverse effects on organs: histochemical studies. *Prog Histochem Cytochem* 39: 85-128.
- REZZANI R. 2006. Exploring cyclosporine A-side effects and the protective role-played by antioxidants: the morphological and immunohistochemical studies. *Histol Histopathol* 21: 301-316.
- REZZANI R, BUFFOLI B, RODELLA L, STACCHIOTTI A AND BIANCHI R. 2005a. Protective role of melatonin in cyclosporine A-induced oxidative stress in rat liver. *Int Immunopharmacol* 5: 1397-1405.
- REZZANI R, GIUGNO L, BUFFOLI B, BONOMINI F AND BIANCHI R. 2005b. The protective effect of caffeic acid phenethyl ester against cyclosporine A-induced cardiotoxicity in rats. *Toxicology* 212: 155-164.
- REZZANI R, RODELLA L, CORSETTI G AND BIANCHI R. 2001. Does methylene blue protect the kidney tissues from damage induced by cyclosporin A treatment? *Nephron* 89: 329-336.
- REZZANI R, RODELLA LF, BONOMINI F, TENGATTINI S, BIANCHI R AND REITER RJ. 2006a. Beneficial effects of melatonin in protecting against cyclosporine A-induced cardiotoxicity are receptor mediated. *J Pineal Res* 41: 288-295.

- REZZANI R, RODELLA LF, TENGATTINI S, BONOMINI F, PECHANOVA O, KOJSOVA S, ANDRIANTSITOHAINA R AND BIANCHI R. 2006b. Protective role of polyphenols in cyclosporine A-induced nephrotoxicity during rat pregnancy. *J Histochem Cytochem* 54: 923-932.
- SHEVACH E. 1985. The effects of cyclosporin A on the immune system. *Annu Rev Immunol* 3: 397-423.
- TAN CY, LAI RC, WONG W, DAN YY, LIM SK AND HO HK. 2014. Mesenchymal stem cell-derived exosomes promote hepatic regeneration in drug-induced liver injury models. *Stem Cell Research & Therapy* 5: 76.
- TÜRK G, ATESSAHİN A, SÖNMEZ M, YÜCE A AND ÇERİBASİ A. 2007. Lycopene protects against cyclosporine A-induced testicular toxicity in rats. *Theriogenology* 67: 778-785.
- WHITING PH, SIMPSON JG, DAVIDSON RJ AND THOMSON AW. 1983. Pathological changes in rats receiving cyclosporin A at immunotherapeutic dosage for 7 weeks. *Br J Exp Pathol* 64: 437-444.
- WOLF A, TRENDELENBURG CF, DIEZ-FERNANDEZ C, PRIETO P, HOUY S, TROMMER WE AND CORDIER A. 1997. Cyclosporine A-induced oxidative stress in rat hepatocytes. *J Pharmacol Exp Ther* 280: 1328-1334.
- WONGMEKIAT O, LEELARUGRAYUB N AND THAMPRASERT K. 2008. Beneficial effect of shallot (*Allium ascalonicum* L.) extract on cyclosporine nephrotoxicity in rats. *Food Chem Toxicol* 46: 1844-1850.

