

An innovation in glaucoma surgery: XEN45 gel stent implantation

Uma inovação na cirurgia de glaucoma: implante de endoprótese de gel XEN45

SADIK ALTAN OZAL¹, OSMAN KAPLANER², BAYBARS BARIS BASAR², HANDE GUCLU¹, ECE OZAL³

ABSTRACT

Purpose: To report follow-up data for patients who underwent XEN45 gel stent implantation, a new method of minimally invasive glaucoma surgery.

Methods: Fifteen eyes in fifteen patients who underwent XEN45 gel stent implantation surgery were investigated in the study. All patients were examined preoperatively and at the following postoperative time points: 1 day; 1 and 2 weeks; and 1, 2, 3, 6, and 12 months. Intraocular pressure (IOP) was measured via Goldmann applanation tonometry. Combined surgical procedures (XEN45 + phacoemulsification + intraocular lens) were performed in patients who had cataracts in addition to glaucoma.

Results: The mean IOP values were significantly lower than the preoperative values at all postoperative visits ($p < 0.001$). In two patients, the IOP exceeded 20 mmHg 12 months after surgery. These IOP increases were controlled by medical therapy, and none of the patients needed another surgical procedure.

Conclusion: XEN45 gel stent implantation is a minimally invasive glaucoma surgery that ensures the effective reduction of IOP. This new treatment modality also avoids the destructive complications encountered in other invasive surgical procedures. However, further studies with greater numbers of patients and longer follow-up periods are needed to clarify certain points.

Keywords: Glaucoma open-angle/surgery; Trabeculectomy; Minimally invasive surgical procedure, stent

RESUMO

Objetivo: Relatar os dados de acompanhamento dos pacientes que apresentaram implante de endoprótese de gel XEN45, um novo método de cirurgia de glaucoma minimamente invasiva.

Métodos: Foram investigados quinze olhos de quinze pacientes que tiveram cirurgia de implante de endoprótese de gel XEN45 no estudo. Todos os pacientes foram examinados no pré-operatório e nos seguintes pontos de tempo pós-operatório: 1 dia; 1 e 2 semanas; e 1, 2, 3, 6 e 12 meses. A pressão intraocular foi medida pela tonometria de aplanamento de Goldmann. Procedimentos cirúrgicos combinados (XEN 45 + facoemulsificação + lente intraocular) foram realizados nos casos que apresentavam catarata além do glaucoma.

Resultados: Os valores médios de PIO foram significativamente menores em todas as visitas pós-operatórias quando comparados aos valores pré-operatórios ($p < 0,001$). Em 2 casos, os valores da pressão intraocular foram superiores a 20 mmHg aos 12 meses pós-operatório. Estes aumentos da pressão intraocular foram controlados por terapia médica, e nenhum dos pacientes necessitou de outro procedimento cirúrgico.

Conclusão: Implantação de endoprótese de gel XEN45 é uma cirurgia de glaucoma minimamente invasiva que garante a redução efetiva da pressão intraocular. Esta nova modalidade de tratamento também evita as complicações destrutivas encontradas em outros procedimentos cirúrgicos invasivos. No entanto, estudos adicionais com um maior número de pacientes e períodos de acompanhamento mais longos são necessários para esclarecer certos pontos.

Descritores: Glaucoma de ângulo aberto/cirurgia; Trabeculectomia; Procedimentos cirúrgicos minimamente invasivos

INTRODUCTION

Glaucoma comprises a group of eye diseases that results in damage to the optic nerve and permanent visual loss, and more than 60 million people globally are affected⁽¹⁾. Increased intraocular pressure (IOP) is the most important risk factor for the development of optic nerve damage and changes in the visual field. Therefore, the most effective treatment modality is the reduction of IOP to prevent glaucoma progression and optic nerve atrophy⁽²⁾. Trabeculectomy and episcleral aqueous drainage implants are currently the most widely used surgical methods for reducing IOP and treating glaucoma. Unfortunately, these procedures are linked to potentially destructive intraoperative and postoperative complications, such as hypotony, choroidal effusion, blebitis, and endophthalmitis^(3,4). Therefore, investigators have sought to develop new surgical procedures to avoid the complications arising from conventional surgical procedures. These new surgical methods, collectively called "minimally invasive glaucoma surgery" (MIGS), have some advantages

over conventional glaucoma surgical procedures, such as *ab interno* applicability, the elimination of external intervention requirements, and the ease of performance alongside cataract surgery⁽⁵⁻⁸⁾. These advantages allow MIGS methods to be safer and less invasive than other surgical methods.

The XEN gel stent (Allergan, Dublin, Ireland) is a recently developed, permanent, *ab interno* collagen implant that reduces IOP by draining aqueous fluid from the anterior chamber into the subconjunctival space. The stent is a hydrophilic tube that is 6-mm long, and it is composed of porcine gelatin crosslinked with glutaraldehyde. The stent comes in three sizes, 45, 63, and 140 μm , all possessing different inner diameters. The XEN45 gel stent is CE-marked in the European Union, and it is indicated for the treatment of refractory glaucoma that has proven resistant to previous surgical treatment and for patients with primary open angle glaucoma (POAG), pseudoexfoliative glaucoma, or pigmentary glaucoma that cannot be controlled with maximum tolerated medical therapy. It is also licensed for use in Canada, Switzerland, and Turkey. The XEN45 gel stent

Submitted for publication: March 22, 2017
Accepted for publication: July 17, 2017

¹ Department of Ophthalmology, Trakya University Faculty of Medicine, Edirne, Turkey.

² Department of Ophthalmology, Uzunkopru State Hospital, Edirne, Turkey.

³ Department of Ophthalmology, Edirne State Hospital, Edirne, Turkey.

Funding: No specific financial support was available for this study.

Disclosure of potential conflicts of interest: None of the authors has any potential conflicts of interest to disclose.

Corresponding author: Sadik Altan Ozal. Trakya University, Faculty of Medicine. Department of Ophthalmology, Edirne-Turkey - E-mail: altanozal@hotmail.com

Approved by the following research ethics committee: Trakya University (# TUTF-BAEK 2016/213).

was recently approved by the US Food and Drug Administration⁽⁹⁻¹²⁾. Because it is a new device, some aspects of its efficacy and safety and of the proper surgical technique for its use remain unknown. This study aimed to report follow-up data after XEN45 gel stent implantation surgery in patients with different types of glaucoma.

METHODS

This was a retrospective, consecutive case series study. Patients who underwent XEN45 gel stent implantation surgery between January 2015 and March 2016 were enrolled. Patients with refractory glaucoma that was resistant to previous surgical treatment; Those with POAG, pseudoexfoliative glaucoma, or pigmentary glaucoma in patients with uncontrolled IOP and progressive visual field damage despite using the maximum tolerated dose of topical antiglaucomatous medications; and those who underwent prior glaucoma surgery were included. The exclusion criteria included primary closed-angle glaucoma, a history of uveitis, and the presence of corneal disease. Patients who did not attend follow-up visits were also excluded. All patients were informed about the treatment and potential complications. Informed consent was obtained preoperatively. The procedures of the study were approved by the institutional review board of the hospital, and they adhered to the tenets of the Declaration of Helsinki. The study protocol was approved by the local ethics committee (approval code: TUTF-BAEK 2016/213).

Before the XEN45 implantation, slit-lamp biomicroscopy and gonioscopic examination were performed. IOP was measured using Goldmann applanation tonometry (AT 900, Haag Strait, Bern, Germany). A detailed fundus examination was performed using a 78-diopter non-contact lens after pupil dilatation induced by 1% Gutt tropicamide.

All surgical procedures were performed under sterile conditions by the same surgeon (OK). Irrigation of the eyelashes, eyelids, and periorbicular tissues was performed with antiseptic 10% povidone iodine. While using an eye speculum, 5% povidone iodine was flushed onto the conjunctiva and fornix for 2 min, after which conjunctival irrigation was completed with saline. The surgery was performed under peribulbar anesthesia with 5 mL of prilocaine and 5 mL of bupivacaine. After peribulbar anesthesia, the superonasal quadrant of the conjunctiva was marked using blue surgical dye at a point 3 mm posterior to the limbus. Clear corneal incisions (main and side-port) were created in the inferotemporal and superotemporal quadrants. A highly cohesive viscoelastic was used to stabilize the anterior chamber during surgery. A 27-gauge pre-loaded injector was placed into the eye through the main clear corneal incision at the inferotemporal quadrant. The needle was directed toward the superonasal quadrant (Figure 1). One hand was used to manipulate the injector, and the other was used to fix and rotate the eye. The needle was pushed into the sclera and carried forward into the subconjunctival space. The surgery was performed under gonioscopic control. A 6-mm-long implant was positioned 2 mm into the subconjunctival space, 3 mm into the sclera, and 1 mm into the anterior chamber. Therefore, visualization of the tip of the needle exiting from the sclera indicated that an optimal 3-mm intrascleral tunnel had been formed. The XEN45 implant was deployed by rotating a dial on the inserter (Figure 2). Once bleb formation was observed, the needle was withdrawn (Figure 3). The viscoelastic material was aspirated, and then 0.1 mL of 1% cefuroxime was injected into the anterior chamber. Finally, the clear corneal incisions were hydrated with balanced salt solution. Mitomycin C was not injected into the conjunctiva at any stage of the surgery. Topical steroid and antibiotic treatments were applied after surgery. A topical steroid (prednisolone acetate 1%) was applied six or more times daily to control postoperative intraocular inflammation. Topical steroid treatment was stopped 1 month after surgery. Ocular massage for 1 min four times daily was recommended during the postoperative period. Needling was not performed at

any of the postoperative visits. Topical antiglaucomatous medications were added as needed according to the postoperative IOP levels. Follow-up visits were planned for 1 day; 1 and 2 weeks; and 1, 2, 3, 6, and 12 months after surgery.

Combined surgery (XEN45 + phacoemulsification + intraocular lens) was performed in patients who had cataracts in addition to glaucoma. In these cases, the XEN45 implantation was performed after phacoemulsification, filling the anterior chamber with a highly cohesive viscoelastic material after implantation of the intraocular lens in the capsular bag.

All data were compiled into a computer file for statistical analysis, and Statistical Package for Social Sciences for Windows 17.0 was used to perform the Wilcoxon signed rank test. A *p* value less than 0.05 was considered statistically significant.

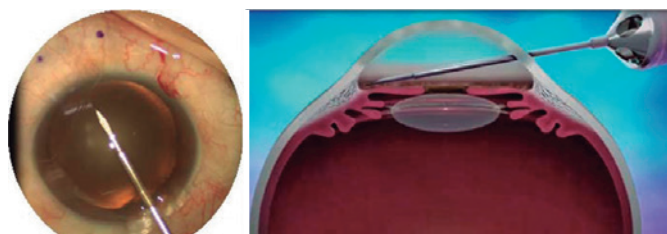


Figure 1. The left panel shows an image from the surgical microscope. The right panel shows a schematic image of the direction of the needle (Vera V, Horvath C. Xen gel stent: the solution designed by AqueSys. In: Samples JR, Ahmed, IIK, editors. *Surgical innovations in glaucoma*. New York: Springer Science+Business Media; 2014. p. 189-98).

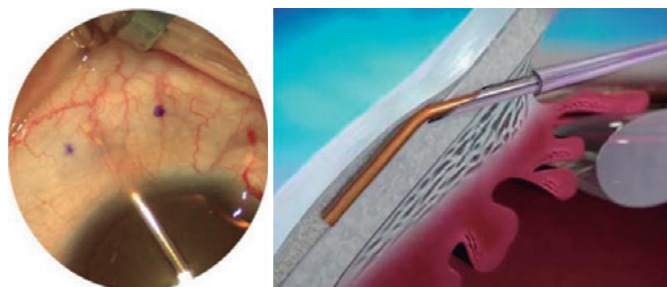


Figure 2. The left panel shows an image from the surgical microscope. The right side shows a schematic image of the XEN gel stent being deployed into position (Vera V, Horvath C. Xen gel stent: the solution designed by AqueSys. In: Samples JR, Ahmed, IIK, editors. *Surgical innovations in glaucoma*. New York: Springer Science+Business Media; 2014. p. 189-98).

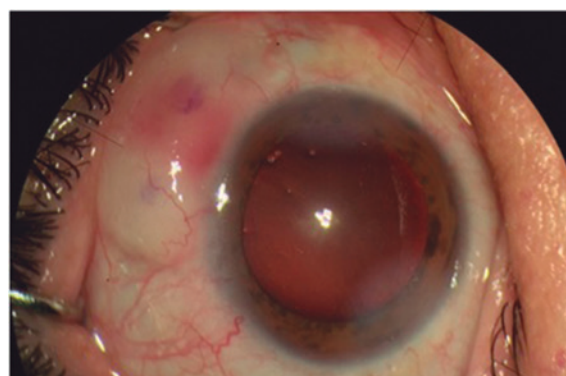


Figure 3. The appearance of bleb formation viewed through the surgical microscope.

RESULTS

A total of 15 eyes of 15 patients were investigated in the study. Tables 1-2 show the baseline patient demographics, characteristics, and findings. Three patients (20%) previously underwent incisional glaucoma surgery. Of the 15 patients examined, nine (60%) underwent only XEN45 gel stent implantation surgery, with six (40%) undergoing XEN45 gel stent implantation combined with cataract surgery. There were no complications related to cataract surgery.

The mean IOP values were significantly lower than the preoperative values at all postoperative visits ($p < 0.001$; Figures 4-5). The mean number of antiglaucomatous medications was 3.60 ± 0.50 in the preoperative period; at 1 year after surgery, the mean number of antiglaucomatous medications had decreased to 0.33 ± 0.90 ($p < 0.001$). At the end of the follow-up period, only two patients (13.3%) required antiglaucomatous treatment. In one patient, the stent was removed because it prolapsed into the anterior chamber, and antiglaucomatous treatment was started 12 months after surgery. None of the patients required further glaucoma surgery.

Table 1. Baseline patient demographics and characteristics

Parameter	Value
Age	
Mean \pm SD	63.6 \pm 13.3
Range	34-80
Sex, n (%)	
Men	10 (66.7)
Women	5 (33.3)
Eyes, n (%)	
Right	7 (46.7)
Left	8 (53.3)
Glaucoma type, n (%)	
Primary open angle	10 (66.7)
Exfoliation	4 (26.7)
Pigmentary	1 (6.7)

Table 2. Patient findings

Cases	Sex	Age	Type of glaucoma	Surgery	Baseline IOP	Last visit IOP	Number of medications preoperatively	Number of medications on last visit	Complications
Case 1	M	57	POAG	Xen	36	17	4	0	No
Case 2	M	71	POAG	Xen+Phaco	35	15	4	0	No
Case 3	M	34	POAG	Xen	39	16	3	0	No
Case 4	F	80	POAG	Xen+Phaco	39	15	3	0	No
Case 5	M	69	PEXG	Xen	32	12	4	0	No
Case 6	M	54	POAG	Xen	39	25	4	2	No
Case 7	M	64	POAG	Xen	34	24	4	3	Stent prolapsus
Case 8	M	78	POAG	Xen	30	15	3	0	No
Case 9	F	76	POAG	Xen+Phaco	34	18	3	0	No
Case 10	F	77	POAG	Xen+Phaco	30	18	3	0	No
Case 11	M	40	POAG	Xen	37	17	3	0	AC hemorrhage
Case 12	M	60	PG	Xen	43	16	4	0	No
Case 13	F	62	PEXG	Xen	40	16	4	0	No
Case 14	M	63	PEXG	Xen+Phaco	38	15	4	0	No
Case 15	F	69	PEXG	Xen+Phaco	35	12	4	0	No

POAG= primary open angle glaucoma; PG= pigmentary glaucoma; PEXG= pseudoexfoliative glaucoma; Phaco= phacoemulsification; IOP= intraocular pressure.

Anterior chamber hemorrhage occurred in only one patient (6.6%) intraoperatively. This complication was easily resolved via an intraoperative viscoelastic injection into the anterior chamber. The viscoelastic material was removed at the end of the operation. It did not cause any IOP increase in the postoperative period. None of the patients experienced any serious ocular complications (e.g., hypotony, choroidal effusion, iritis, stent exposure, endophthalmitis) in the postoperative period.

DISCUSSION

In this study, implantation of an XEN45 gel stent significantly reduced IOP during the 12-month postoperative period. There are many advantages of this new surgical procedure; specifically, it is easy to learn and perform, and it allows for a short operating time with topical anesthesia. Another advantage is that this method can be easily performed in combination with cataract surgery. This new treatment modality also avoids the destructive complications encountered in other invasive surgical procedures. Because the XEN45 gel stent has a small internal lumen diameter (45 μ m), it eliminates postoperative hypotony by providing approximately 6-8 mmHg of outflow resistance^(9-10,13).

The role of topical antiglaucomatous therapy in ocular surface disease has been demonstrated in several studies^(14,15). Some patients with glaucoma cannot adapt to the use of topical antiglaucomatous drops, and thus, they discontinue the treatment. Therefore, XEN45 gel stent implantation should be considered to reduce the need for topical antiglaucomatous therapy and prevent ocular surface diseases.

Because the XEN45 gel stent is a new device, there are few articles to date about its implantation in the literature⁽¹⁶⁻¹⁸⁾. Previous authors⁽¹⁷⁾ performed XEN45 gel stent implantation with mitomycin C injections combined with cataract surgery in 30 eyes. They achieved a significant IOP reduction (29.34%) after 12 months of follow-up. At the end of the follow-up period, three patients required antiglaucomatous treatment. The most common complications were hemorrhage at the scleral exit point (90%) and minor intracameral hemorrhage (86%). No vision-threatening complications were observed.

Other authors⁽¹⁸⁾ reported the results of XEN63 and XEN140 gel stent implantations, but without mitomycin C injections, combined with cataract surgery in 37 eyes. They achieved a significant IOP reduction and a decreased number of antiglaucomatous medications

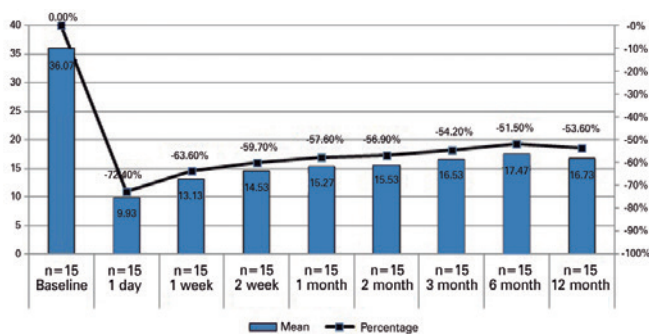


Figure 4. Changes in the mean intraocular pressure and percent reduction.

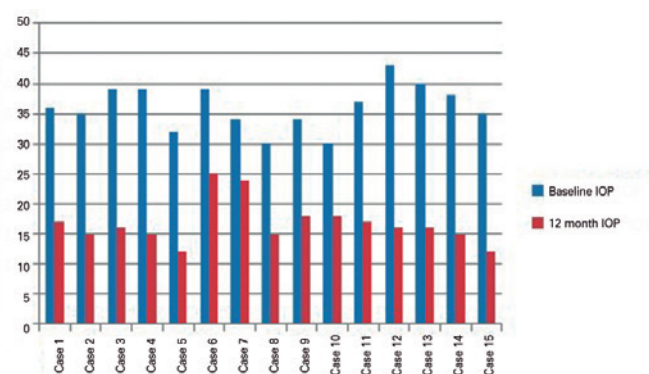


Figure 5. Changes in the intraocular pressure at 12 months after surgery compared to the preoperative value for each patient.

used after 12 months of follow-up. Twelve patients (32%) required a needling procedure with antifibrotic agents in the postoperative period. Hypotony was observed in the first month after surgery, particularly in the XEN140 group.

One study⁽¹⁹⁾ presented the results of XEN45 gel stent implantations with preoperative mitomycin C injections in 71 eyes. The authors maintained a 36% decrease in the IOP level in 34 eyes at 12 months. The intraoperative complications were anterior camera bleeding in two patients, subconjunctival bleeding in one patient, and the preoperative fracture of one implant. The postoperative complications were a flat anterior chamber (1.4%), hyphema (4.1%), and hypotony below 6 mmHg on the first day (12.6%).

Additionally, internal ostium occlusion of the XEN45 gel stent has been reported in the literature⁽²⁰⁾. The authors removed a blood clot occluding the internal ostium after XEN45 gel stent implantation, leading to a reduction in IOP.

In our study, the IOP reduction rate was higher at 12 months after surgery than reported in other studies in the literature. We suspect that this occurred because our baseline IOPs were higher than those in the other studies. Because mitomycin C may increase the incidence of late bleb-related complications, we did not inject this agent into the conjunctiva at any stage of the surgery. However, even without mitomycin C, we achieved a significant IOP reduction 12 months after the implantation of XEN45 gel stents.

There are some limitations to this study; in particular, our small number of patients and the lack of control group limit our compari-

sons. Thus, it has not been evaluated whether the efficacy of XEN45 gel implantation differs between patients according to prior glaucoma surgery. Furthermore, the mild IOP-reducing effect of phacoemulsification alone was not evaluated. In addition, we could not evaluate in which glaucoma type this surgical method is most effective.

Clinical trials (NCT02006693, NCT02036541) are ongoing for XEN gel stents.⁽²¹⁾ We think that after the results of these studies have been published, new aspects of XEN gel stent implantation will be revealed.

Consequently, the results of our study are promising, and XEN45 gel stent implantation presents a valuable contribution to glaucoma surgery. Using XEN45 gel stents, we reduced IOP and medication use without significant complications in patients with different forms of glaucoma. We believe that this new surgical procedure will play an important role in glaucoma surgery in the future. However, further studies with greater numbers of patients and longer follow-up periods are needed to clarify certain points.

REFERENCES

1. Tham Y-C, Li X, Wong TY, Quigley HA, Aung T, Cheng C-Y. Global prevalence of glaucoma and projections of glaucoma burden through 2040: A systematic review and meta-analysis. *Ophthalmology*. 2014;121(11):2081-90.
2. Heijl A, Leske MC, Bengtsson B, Hyman L, Bengtsson B, Hussein M. Reduction of intraocular pressure and glaucoma progression: results from the Early Manifest Glaucoma Trial. *Arch Ophthalmol*. 2002;120(10):1268-79.
3. Nouri-Mahdavi K, Brigatti L, Weitzman M, Caprioli J. Outcomes of trabeculectomy for primary open-angle glaucoma. *Ophthalmology*. 1995;102(12):1760-9.
4. Landers J, Martin K, Sarkies N, Bourne R, Watson P. A twenty-year follow-up study of trabeculectomy: risk factors and outcomes. *Ophthalmology*. 2012;119(4):694-702.
5. Minckler D, Mosaed S, Dustin L, Ms BF. Trabectome (trabeculectomy-internal approach): additional experience and extended follow-up. *Trans Am Ophthalmol Soc*. 2008;106:149-59.
6. Mosaed S, Rhee DJ, Filippopoulos T, Tseng H, Deokule S, Weinreb RN. Trabectome outcomes in adult open-angle glaucoma patients: One-year follow-up. *Clin Surg Ophthalmol*. 2010;28(8-9):182-6.
7. Ting JLM, Damji KF, Stiles MC. Ab interno trabeculectomy: Outcomes in exfoliation versus primary open-angle glaucoma. *J Cataract Refract Surg*. 2012;38(2):315-23.
8. Bussell II, Kaplowitz K, Schuman JS, Loewen NA. Outcomes of ab interno trabeculectomy with the trabectome by degree of angle opening. *Br J Ophthalmol*. 2015;99(7):914-9.
9. Lewis RA. Ab interno approach to the subconjunctival space using a collagen glaucoma stent. *J Cataract Refract Surg*. 2014;40(8):1301-6.
10. Vera V, Horvath C. Xen gel stent: the solution designed by AqueSys. In: Samples JR, Ahmed, IIK, editors. *Surgical innovations in glaucoma*. New York: Springer Science+Business Media; 2014. p. 189-98.
11. Richter GM, Coleman AL. Minimally invasive glaucoma surgery: current status and future prospects (review). *Clin Ophthalmol*. 2016;28(10):189-206.
12. Kerr NM, Wang J, Barton K. Minimally invasive glaucoma surgery as primary stand-alone surgery for glaucoma (review). *Clin Exp Ophthalmol*. 2016;45(4):393-400.
13. Sheybani A, Reitsamer H, Ahmed II. Fluid Dynamics of a novel micro-fistula implant for the surgical treatment of glaucoma. *Invest Ophthalmol Vis Sci*. 2015;56(8):4789-95.
14. Garcia-Feijoo J, Sampaolesi JR. A multicenter evaluation of ocular surface disease prevalence in patients with glaucoma. *Clin Ophthalmol*. 2012;6:441-6.
15. Valente C, Iester M, Corsi E, Rolando M. Symptoms and signs of tear film dysfunction in glaucomatous patients. *J Ocul Pharmacol Ther*. 2011;27(3):281-5.
16. Dupont G, Collignon N. New surgical approach in primary open-angle glaucoma: Xen Gel Stent a minimally invasive technique. *Rev Med Liege*. 2016;71(2):90-3.
17. Perez-Torregrosa VT, Olate-Perez A, Cerda-Ibanez M, Gargallo-Benedicto A, Osorio-Alayo V, Barreiro-Rego A, et al. Combined phacoemulsification and XEN45 surgery from a temporal approach and 2 incisions. *Arch Soc Esp Ophthalmol*. 2016;91(9):415-21.
18. Sheybani A, Lenzhofer M, Hohensinn M, Reitsamer H, Ahmed IIK. Phacoemulsification combined with a new ab interno gel stent to treat open-angle glaucoma: pilot study. *J Cataract Refract Surg*. 2015;41(9):1905-9.
19. Lavin-Dapena C, Arteaga JV, Cervero MAC, Suarez LC, Segarra MAS, Mardero OD, et al. 12 month results from a minimally-invasive, 45µm lumen ab interno gelatin stent in combination with a preoperative mmc from a multicenter study conducted in Spain. *Hong Kong: World Glaucoma Congress*; 2015.
20. Pinto Ferreira N, Abegao Pinto L, Marques-Neves C. XEN gel stent internal ostium occlusion: Ab-interno revision. *J Glaucoma*. 2017;26(4):e150-e152.
21. Keskin AM, Sevim DG, Unlu M, Mirza GE. Ab interno approach of subconjunctival filtration with XEN gel stent. *Austin Ophthalmol*. 2016;1(1):1002.