

---

NEURONAL CEROID-LIPOFUSCINOSIS, A TYPE OF AMAUROTIC  
FAMILY IDIOCY

CLINICAL AND PATHOLOGICAL STUDY OF FOUR CASES

LUCIANO DE SOUZA QUEIROZ \*  
JOAQUIM N. DA CRUZ NETO \*\*  
J. LOPES DE FARIA \*\*\*

The term "Amaurotic Family Idiocy" (AFI), introduced by Sachs in 1896, has been currently used to designate a group of genetic diseases characterized by progressive dementia, retinal degeneration with blindness, seizures, myoclonias, as well as pyramidal and cerebellar syndromes. The typical neuropathologic change is ubiquitous intraneuronal accumulation of lipid, classically known as the Schaffer-Spielmeier cell process. Age at the onset of symptoms, and peculiarities of clinical evolution were criteria employed in the distinction of six types of AFI: Congenital, Infantile, Late Infantile, Juvenile, Adult and Senile.

In 1939, Klenk<sup>26</sup> isolated ganglioside GM-2 from the brains of two patients with infantile type of AFI (Tay-Sachs disease), but was unable to disclose abnormalities in the sphingolipid pattern of five brains from patients with juvenile type of AFI. From this paper on, a number of histochemical, biochemical and ultrastructural studies on AFI have appeared, leading to the recognition, within the former group of AFI, of two different types of nosological entities, which are as follows<sup>55</sup>:

The first group consists in ganglioside storage diseases, and includes the original Tay-Sachs disease (GM-2 gangliosidosis, Type I) and several other autosomal recessive entities. These have been discovered and biochemically characterized in the past few years (GM-2 gangliosidoses, Types II and III;

---

From the Faculdade de Ciências Médicas da Universidade Estadual de Campinas. Presented in part at the Fifth Brazilian Congress of Neurology, São Paulo, July 1972, and at the Neurological Meeting of the Associação Paulista de Medicina, São Paulo, October 1972. This study is dedicated to the memory of Prof. Oswaldo Freitas Julião.

\* Intern, Dept. of Pathology; \*\* Resident, Dept. of Clinical Neurology and Neurosurgery (Late Chairman — Prof. O. F. Julião); \*\*\* Chairman, Dept. of Pathology.

GM-1 gangliosidoses, Types I and II)<sup>33</sup>. For each of them, deficiencies of specific lysosomal enzymes (glycohydrolases) were demonstrated<sup>4, 12, 32, 38, 44, 50</sup>.

The second group began to emerge in 1960, when Zeman and Alpert<sup>58</sup> found that the intraneuronal substance in the juvenile type of AFI was probably lipofuscin. Kristensson and Sourander<sup>28</sup> also recognized several histochemical features of lipofuscin in the storage material from patients of this disease, including primary yellowish fluorescence. In 1969, Zeman and Dyken<sup>60</sup> reported 26 patients of late infantile, juvenile and adult types of AFI. In 18, neuropathological studies disclosed neuronal accumulation of pigments of the ceroid-lipofuscin type. Clinical features varied widely, but included autosomal recessive inheritance, progressive failure of vision, intellect and motor functions, as well as recurrent seizures. The terms "Batten's disease" and "Neuronal ceroid-lipofuscinosis" were used to designate this new entity, and have since been accepted by others<sup>5, 10, 19, 22, 23, 27, 35, 42, 45</sup>.

In the Brazilian literature, a few cases of AFI have been reported. The patients of Barbosa (1926), Fialho (1930), Fonseca (1936) (all quoted by Julião et al.<sup>24</sup>), Julião et al.<sup>25</sup> and Rosenberg and Lefèvre<sup>41</sup> all belonged to the infantile form. The cases of Tretiakoff and Pujol (1926), Guimarães (1930), Valença (1942) (all quoted by Julião et al.<sup>24</sup>), Marques et al.<sup>31</sup>, Julião et al.<sup>24</sup>, Levy et al.<sup>30</sup>, Dantas et al.<sup>11</sup> and Alencar<sup>1</sup> were patients with the late infantile and juvenile forms. The term "Neuronal ceroid-lipofuscinosis" was first used in Brazilian literature by Queiroz<sup>37</sup>.

The purpose of this paper is to report the clinical and pathological study of four patients with Neuronal ceroid-lipofuscinosis. To the best of our knowledge, our cases are the first in Brazil, in which the stored substance was classified as lipopigment.

#### CASE REPORTS

Cases 1 and 2 are brothers, and cases 3 and 4 are a brother and a sister. Both families are unrelated.

CASE 1 — A.P.S., a Brazilian white eight-year-old boy, was admitted to the Neurological Department on 2-21-1972. His parents, of non-jewish ancestry, are first cousins. They and three siblings are in good health, but one brother is affected in a similar fashion (Case 2). No history of familial disease or of mental abnormalities in the family could be obtained. The patient was born after an uneventful gestation. Apart from some delay in speech development, he was thought to be a normal child until the age of four, when he had a generalized convulsion. Three months later, unsteadiness of gait and frequent falling to the ground, together with several petit-mal spells, were noted. The seizures were unresponsive to anticonvulsant drugs. Gradual behavior deterioration and rapid impairment of vision appeared at the same time. A year prior to admission, myoclonic jerks of the limbs and trunk had begun to occur, especially under sound stimulation. Physical examination showed an emaciated, pale patient, with diffuse muscle wasting. Cephalic perimeter measured 52 cm. Neurological findings consisted in severe dementia, flexion of the superior extremities and extension of the inferior ones, spasticity and pyramidal signs. Pathological reflexes, such as suction, grasping and groping were also present. Vertical and horizontal nystagmus, with a rotatory component, could be seen, and ophthalmologic examination demonstrated bilateral optic atrophy, attenuated retinal vessels, macular and retinal degeneration. Others systems were normal. Except for severe

anemia, routine examinations including cerebrospinal fluid and search for metachromatic substance in the urine were unrevealing. Vacuolated lymphocytes and azurophilic hypergranulation of neutrophils failed to be observed in the peripheral blood. EEG showed lessened cortical activity, presence of slow waves and frequent low-voltage spike-and-wave complexes. A right occipital brain biopsy was carried out. Evolution was progressively downhill, and the patient died of bronchopneumonia on 5-19-1972.

CASE 2 — J.P.S. This Brazilian white four-year-old boy was admitted to the Pediatric Department on 2-21-1972. He is the brother of Case 1, and his gestation and birth were normal. The patient had only some delay in speech development, with a very poor vocabulary, until the age of two and half years, when progressive difficulties in walking, which was wide-based, were noted. Three months later, he was unable to walk. By the age of three, vision and mental functions quickly deteriorated, progressing to blindness and dementia. Seizures, involuntary movements and myoclonic jerks were absent. Physical examination disclosed a pale boy, with diffuse muscle wasting. Cephalic perimeter measured 49 cm. Neurological examination showed mild dementia, flexion of all limbs, increased tonus, spasticity and corticospinal signs. Pathological reflexes, such as suction, grasping and groping were manifest. Ophthalmologic examination gave the same result as in Case 1. Other systems were unremarkable. Laboratory findings and EEG were non-informative, and similar to those of Case 1. The patient was discharged to the outpatient department after three months hospitalization.

CASE 3 — A.B.D. — This Brazilian white seventeen-year-old boy was admitted to the Neurological Department on 6-16-1972. The parents are third cousins and of non-jewish ancestry. They enjoy good health, as well as five other normal siblings. A sister (case 4) is similarly affected. Another died at the age of 19, of presumably the same disease. Gestation, birth and subsequent development were normal up to the age of nine years, when visual difficulties began to develop. Except for blindness, the patient did well until fifteen years old, when generalized tonic-clonic seizures appeared. These occurred with a regular interval of two months, despite anticonvulsant therapy, and were soon followed by progressive behavior abnormalities, mental deterioration, and motor dysfunctions, such as unsteady gait. Later, walking became impossible. Physical examination was normal, except for a moderate degree of emaciation and generalized muscle wasting. Neurological examination showed dementia, flexion of all limbs, pyramidal and cerebellar signs. Grasping and groping reflexes, and vertical and horizontal nystagmus were also present. The optic fundi displayed atrophy of the papillae, attenuated vessels, and retinal degeneration similar to retinitis pigmentosa. Other systems were normal. Peripheral blood smears revealed the presence of 60% vacuolated lymphocytes. Other laboratory examinations were non-contributory. The pneumoencephalogram showed only a large ponto-cerebellar cistern. EEG under barbituric sleep revealed no abnormalities. A right occipital brain biopsy was performed. The patient was discharged home and is being followed in the outpatient clinic.

CASE 4 — E.B.D., a Brazilian white nine-year-old girl, was admitted to the Neurological Department in June 1972. She is the sister of Case 3, and her gestation and birth were normal. By the age of eight, she noticed a decrease of visual acuity, that progressed to blindness in a few months. Mild behavior abnormalities, such as diminished interest in her surroundings and irritability were observed by her mother. Motor dysfunctions and convulsions were absent. Physical and neurological examinations were normal, apart from the optic fundi, which revealed pale optic discs and retinal degeneration with mildly attenuated vessels. Vacuolated lymphocytes were present in the peripheral blood. Other investigations showed normal results. EEG demonstrated epileptic discharges in the left cerebral hemisphere. A needle occipital cortical biopsy was done by another service and the material was sent to us for examination. Her status is at present essentially unchanged.

## MATERIALS AND METHODS

Autopsy was performed in Case 1, and cortical biopsies were obtained in cases 1, 3 and 4. All material was fixed in 10% formalin. In case 1, blocks were taken from representative areas of the cerebral cortex, basal ganglia, diencephalon, brain stem and spinal cord. Paraffin-embedded tissue was stained by hematoxylin & eosin, Nissl, Holzer and Ziehl-Nielsen methods<sup>40</sup>, and the following histochemical procedures were employed<sup>36</sup>: PAS, Sudan black B, Nile blue sulfate (Hueck's reaction) and Schmorl reaction. Frozen sections were stained by the Spielmeyer method for myelin sheaths<sup>40</sup>, Scarlet R<sup>40</sup>, Sudan black B and PAS. Both paraffin and frozen sections were mounted unstained in glycerol medium and examined in ultraviolet light.

## RESULTS

In case 1, autopsy (Dra. Miriam A. S. Trevisan) disclosed a cachectic boy, weighing 11.5 kg and measuring 100 cm, with numerous decubitus ulcers. Examination of thoracic and abdominal organs revealed bilateral bronchopneumonia and absence of hepatosplenomegaly. In addition to moderate diffuse hyperostosis of the skull, a right posterior parieto-occipital craniectomy hole of 3 cm diameter was noted. The cerebral dura mater was very thickened over the whole convexity, with bilateral old hemorrhages on its internal surface. The brain (Fig. 1) weighed 680 g (average normal = 1,273 g), measured 13 cm in both sagittal and biparietal diameters, had a firm consistency, was yellowish and severely atrophic. The cerebral pia-arachnoid exhibited prominent thickening, especially along the longitudinal cerebral fissure. The sulci were widened, markedly so in the occipital lobes, and the calcarine fissure measured 0.3 cm wide. Coronal sections revealed striking generalized thinning of the cerebral cortex, most intense in the occipital region, where visual cortex showed

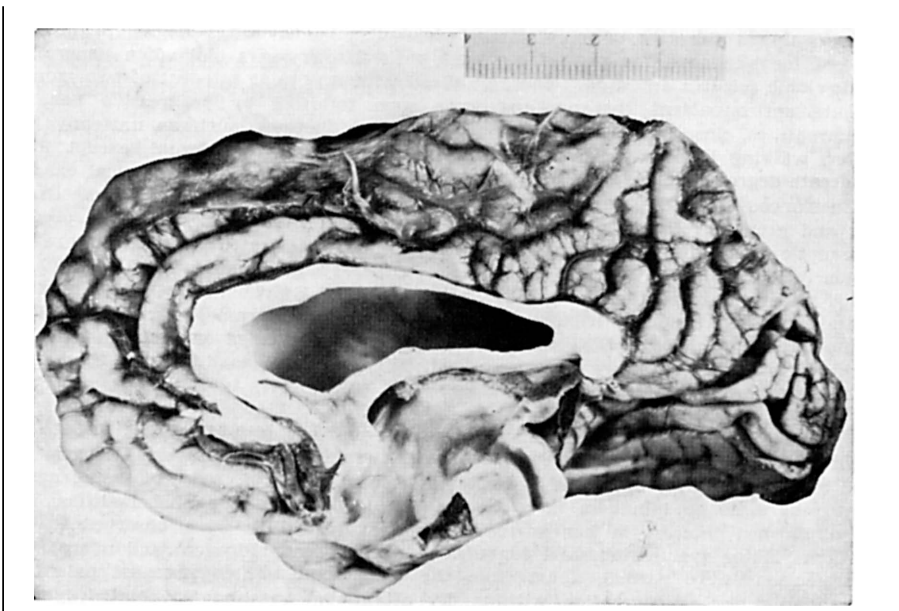


Fig. 1 — Severe cerebral atrophy, most marked in the occipital region. Leptomeningeal thickening, enlargement of the lateral ventricle, foramen of Monro and aqueduct.

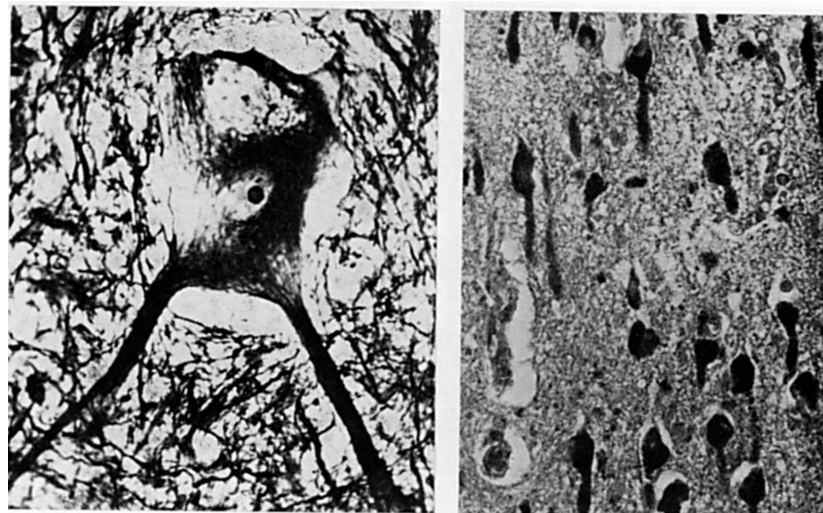


Fig. 2 — Anterior horn neuron: focal accumulation of granular substance with disappearance of the neurofibrils, in an area close to the upper surface of the cell. (Bielschowsky-Gros, 400 ×).

Fig. 3 — Parietal cerebral cortex: ballooning of the perikarion and distention of the proximal segment of the axon in pyramidal cells. (Sudan black B, paraffin section, 250 ×).

a thickness of 0.1 cm. The white matter was also reduced in territory, and the corpus callosum markedly narrowed. The lateral ventricles, the foramina of Monro and the third ventricle presented strong dilatation. The latter had a width of 1.4 cm as a consequence of severe thalamic atrophy. The basal ganglia were less affected. The brain stem and cerebellum exhibited only slight reduction of volume, and no gross atrophy of the folia could be observed. No pigmentation was seen in the substantia nigra. The fourth ventricle displayed moderate dilatation. The spinal cord failed to show gross abnormalities.

The following histopathological description concerns autopsy of Case 1 — *Nerve cells* in all parts of the central nervous system showed intracytoplasmic accumulation of a slightly yellowish granular substance, with distention of the perikarion and rounding of the cell contours, assuming a ballooned appearance (Schaffer-Spielmeier cell process). Most frequently, the cytoplasm was diffusely replaced by granular material, and the Nissl substance completely lost. In some types of neurons, such as the motor cells of the anterior horns (Fig. 2), circumscribed distribution of the granules predominated and the rest of the cytoplasm was apparently healthy. In the dendrites, the abnormal substance occurred in small quantities, except in the Purkinje cells, whose dendritic tree showed sharply localized, spindle-shaped dilatations, consisting of agglomerates of storage material. The cortical pyramidal cells often had the proximal segment of the axon distended in a similar fashion (Fig. 3). The nucleus was eccentric, reduced in size, pyknotic, showing no nucleolus as a rule. It was pushed towards one of the dendrites or, less frequently, towards the axon hillock.

*The accumulated substance* consisted of very small, closely joined granules, either yellowish or slightly eosinophilic in H & E stain. In the neurons of the substantia nigra (Fig. 4) the granules were strongly eosinophilic, much coarser

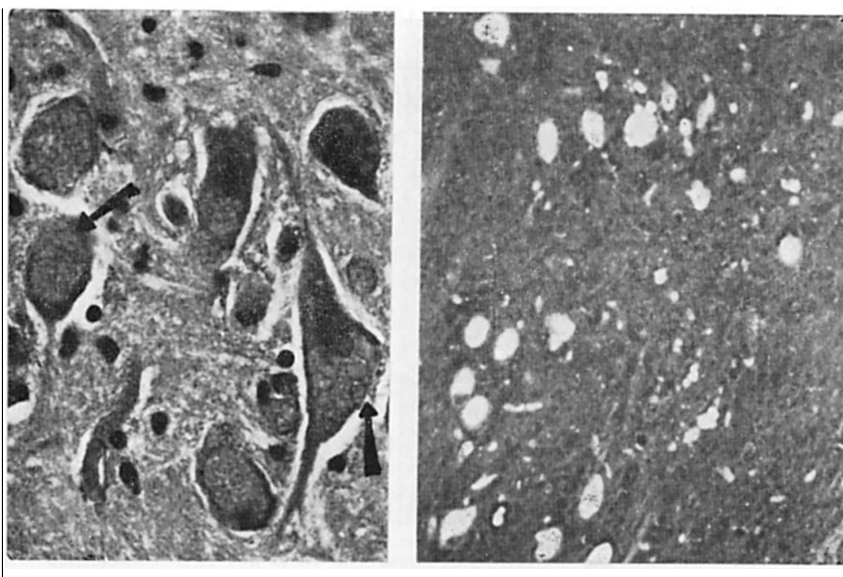


Fig. 4 — Substantia nigra: coarse irregular cytoplasmic granules (arrows) in neurons. "Myoclonus bodies of the protein type". (H & E, 400 ×).

Fig. 5 — Globus pallidus: autofluorescence of lipopigment granules in neurons. (Unstained paraffin section, 100 ×).

and of variable size (Seitelberger's myoclonic bodies of the protein type). Such morphology was found only in this location. Histochemically, the intracytoplasmic deposit exhibited the following features: a) It was insoluble in ethanol and xylene, and non-extractable by chloroform-methanol 2:1 overnight at 60°C. The usual procedures of dehydrating, clearing and paraffin-embedding did not significantly alter the histochemical results. b) It stained a deep blue or black with Sudan black B, but only a pale pink or not at all with Scarlet R. c) It was PAS-positive. d) It was acid-fast. e) It stained a deep blue with Schmorl's ferric-ferricyanide reaction for lipofuscin. f) It stained reddish violet with Nile blue sulfate. g) Examination of unstained, glycerin-mounted, paraffin and frozen sections in ultraviolet light revealed a dim yellowish-green autofluorescence of the granules (Fig. 5). The above enabled the interpretation of the accumulated substance as lipopigment.<sup>28</sup>

*Distribution of lesions* — No region of gray matter and no type of neuron were free of lipopigment accumulation. The least intense degree of Schaffer-Spielmeier cell process was found in the remaining granule cells of the cerebellum. Neuronal loss proved most marked in the cerebellar granular layer, retina and occipital cortex, where extensive areas of status spongiosus were found. In all other regions, ballooning and loss of nerve cells occurred to mild or moderate degrees. Gemistocytic astrocytes were observed in the cerebral cortex, most frequently in areas of status spongiosus. The latter regions also showed gitter cells. The white matter exhibited relatively good preservation, oligodendrocytes were normal in number and morphology, except for mild acute swelling. Myelin sheaths were reduced in number in certain cortical areas, but normal in others. All parts examined revealed moderate to severe gliosis, responsible for the firm consistency of the fresh brain tissue.

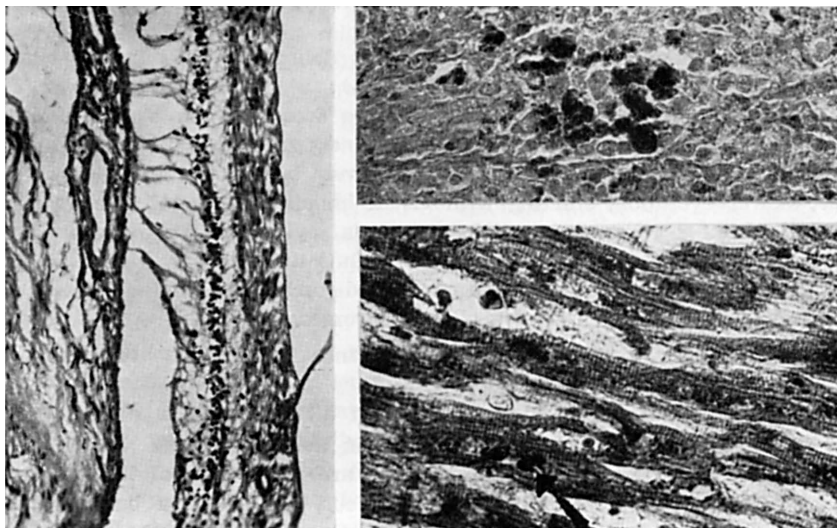


Fig. 6 — Severe retinal atrophy. (H & E, 100 ×).

Fig. 7 — Spleen: lipopigment-laden macrophages in the red pulp. (Sudan black B, paraffin section, 250 ×).

Fig. 8 — Heart: lipopigment granules in myocardial fibers, sometimes with coarse appearance (arrow). (Sudan black B, paraffin section, 400 ×).

*Ophthalmic pathology* — The retina was much reduced in thickness (Fig. 6). The inner limiting membrane and the stratum opticum were well preserved. There was total disappearance of the ganglionic layer, where only pyknotic nuclear rests were visible. The inner nuclear layer showed numerous cells charged with dark pigment (melanin). A complete atrophy of both plexiform and outer nuclear layers was accompanied by total loss of rods and cones, with concomitant neuroglial proliferation. In the optic nerve, a severe gliosis replaced the nerve fibers. Other ophthalmic structures were unremarkable.

*Extraneural findings* — Examination of skeletal muscle revealed only disuse atrophy. Lipopigment granules were also found in the liver (scarce granules in hepatocytes and, in larger amounts, in the Kupffer cells), spleen (Fig. 7) (in macrophages, both in the white and red pulps) and heart (Fig. 8) (granule accumulations in the myocardial fibers, both in perinuclear and diffuse locations). The visceral granules, like those of neurons, were not brown, but pale pink and could be seen with H & E stain only in the myocardium. Sudan black B or PAS were necessary for their demonstration elsewhere. These findings were confirmed by ultraviolet microscopy. Lungs and kidneys showed no lipopigment.

*Brain biopsies*, performed in cases 3 and 4, demonstrated essentially the same aspect described for the cerebral cortex of case 1, except that the amount of lipopigment was far less. Neuronal ballooning existed only in some cells, and the others exhibited normal contours. The number of neurons and the glial elements also seemed normal. The histochemical features of the lipopigment were the same described for Case 1.

## DISCUSSION

In 1970, Zeman and his collaborators<sup>59</sup> delineated three major clinical forms of Neuronal ceroid-lipofuscinosis (NCL): a) *Jansky-Bielschowsky (JB) type*, symptoms beginning at any age, more frequently in early childhood. Rapid evolution with seizures, dementia, blindness and coma. Death invariably occurs 2 to 6 years after the first symptoms. b) *Spielmeyer-Sjögren (SS) type*, slower evolution, starting with visual impairment, usually between the ages of 5 and 8 years, followed by dementia, pyramidal syndrome and convulsions. Death occurs after an average evolution of 11 years. c) *Kufs type*, insidious onset in adulthood, with psychic disturbances, mild or absent dementia, extrapyramidal and cerebellar syndromes.

Symptoms and signs of cardinal importance in the NCL are as follows:

1) *Seizures* of any type may occur in all three major clinical forms, but prove remarkably intense and frequent in the JB patients. In the latter, seizures may be the presenting sign. They are most often of the grand-mal type, frequently progress to status epilepticus, and carry a bad prognosis, since their occurrence hastens the downhill course of the disease.

2) *Visual impairment*, progressing insidiously to complete blindness, is usually the first manifestation in the SS type, and may dominate the picture, at least until the onset of seizures. Blindness also occurs in the JB type, but is overshadowed by mental deterioration. In the Kufs type, visual involvement is absent as a rule. The optic fundi of affected cases reveal optic disc and retinal atrophy, and attenuated vessels, the association of the latter two being of the utmost importance for the diagnosis. Macular degeneration of the granular type and peripheral incontinence of pigment are also found, but the cherry red spot in the macula is not seen.

3) *Mental changes*, though uncharacteristic, are an obligatory sign of NCL, except for the Kufs type. In the SS type, the psychiatric picture shows progressive deterioration of all superior mental functions, as well as disturbances of affective behavior and memory impairment. In the JB form, dementia is the only finding, since intellect is still poorly developed by the time the disease begins. In the Kufs type, loss of intellectual abilities is mild and may even lack.

4) *Motor dysfunction*. In the SS type, early extrapyramidal signs are quite characteristic, followed by cerebellar and pyramidal dysfunctions. In the JB form, pyramidal involvement predominates, together with myoclonic hyper-excitability. Steitelberger (1967), quoted by Ricoy Campo et al.<sup>39</sup> suggested in this connection the existence of a clinical variety of AFI, termed "Myoclonic variant of cerebral lipidosis". In the Kufs type, pyramidal signs and symptoms rarely occur, but cerebellar and extrapyramidal dysfunctions may be severe.



Prior to the start of overt neurological disturbances, minor signs are sometimes observed, such as mild behavior abnormalities, delay in speech development and incipient cerebellar troubles.

Laboratory findings of significance are confined to the presence in the peripheral blood of vacuolated lymphocytes<sup>3</sup> and of leukocytes containing azurophilic cytoplasmic granules<sup>48</sup>. The former are more consistently observed in the SS type, while the latter predominate in the JB type. Recently, Witzleben and associates<sup>52, 53</sup> described by electron microscopy lamellar cytoplasmic inclusions in lymphocytes of patients with NCL; this finding may be used in the near future as a simple diagnostic procedure. EEG abnormalities are almost always present, though non-specific<sup>20</sup>. Radiologic examinations show only variable cerebral atrophy.

Differential diagnosis should include sub-acute sclerosing panencephalitis, Schilder's disease, myoclonus epilepsy of Unverricht and Lundborg, the leukodystrophies and especially the gangliosidoses. The latter may be confirmed or discarded by investigation of the serum hexosaminidases<sup>33, 44</sup>.

In conclusion, some history data and neurological findings in patients with NCL are reasonably constant, and may suggest this diagnostic possibility. However, considerable overlap occurs with the clinical pictures of other metabolic diseases<sup>60</sup> and a definite diagnosis can only be achieved through cerebral or rectal biopsy.

The clinical and histopathologic findings in our cases are consistent with the diagnosis of NCL, as delineated by Zeman<sup>59, 60</sup> and no gross deviations from their data were observed.

Cases 1 and 2 were classified as JB type, on account of the early beginning of mental deterioration, disturbances of vision and motor signs. Seizures and myoclonias were prominent in case 1, as expected, but were absent from case 2, at least up to this date. Absence of lymphocytic vacuolation is common in the JB type, but azurophilic hypergranulation of leukocytes, though frequent in this form, was not found either. EEG findings were in accordance to the literature<sup>20</sup>.

Cases 3 and 4 were considered to belong to the SS type, based on the later onset and slower progression, with clear predominance of visual impairment, which remains the single finding in case 4. Case 3 presents already the full-blown picture. Lymphocytic vacuolation was found in both patients, as expected.

Our histopathologic findings are essentially in accordance to those described by Zeman and collaborators<sup>59</sup>. In case 1, lipopigment accumulation was far more intense than in cases 3 and 4, and this might correlate with milder symptoms and slower evolution in the latter patients. The presence of lipopigment granules in the liver, myocardium and spleen, as previously reported by others<sup>28, 59</sup>, was also noteworthy. The smallest neurons, such as the cerebellar granule cells and the retinal cells, showed minor ballooning, but striking decrease in number. Such finding, already commented by Zeman<sup>59</sup> is a supporting element of the recently advanced theory on pathogenesis of the NCL<sup>57, 59</sup>. Ophthalmic pathology as also closely similar to that of Duke-Elder<sup>14</sup>.

Concerning the correlation of the clinical and pathological findings, it suffices to say that the intense and diffuse affection of all neurons in all parts of the CNS accounted for the capital signs of severe dementia, blindness, seizures, pyramidal and cerebellar dysfunctions.

The exact nature of the accumulated substance in the NCL is still in dispute, and two conflicting views exist.

One group of investigators, headed by Zeman and his colleagues, considers the granular deposit as a lipopigment, a view already held by Spielmeyer, as early as 1905, on account of its physical and histochemical characters. They realize that the ultrastructure of the granules frequently differs from that of lipofuscin<sup>43</sup>, but, for reasons detailed elsewhere<sup>56, 59</sup>, they do not take this as an argument against their opinion. A number of histochemical studies on lipofuscin are available<sup>16, 47, 54</sup>. Björkerud<sup>7</sup> also defined lipofuscin granules by their structural, histochemical and physical properties on the light microscopic level. Recently, several patients with AFI were reported, in whom the accumulated substance was identified as ceroid or lipofuscin<sup>5, 6, 8, 9, 18, 19, 22, 23, 27, 29, 35, 39, 42, 45, 46, 49</sup>.

The other group is represented by electron microscopists, for whom the fine structure of the stored substance is the all-important factor for classification of the substance and, consequently, of the cases. On ultrastructural grounds, they do not consider the granules as a lipopigment, and a wealth of new descriptive terms have been advanced to designate all morphological patterns of the stored material in different patients<sup>2, 13, 17, 21, 34, 51</sup>.

Since the biochemical pathogenesis is still unknown, it is obvious that more than one entity may exist in the group that is now called NCL, but it seems unwise to attempt their differentiation on purely morphological grounds. The nosological delineation of Tay-Sachs, Niemann-Pick and Gaucher diseases caused much confusion in the past, as long as the underlying enzyme defects remained undiscovered, and morphology was the single approach in their consideration. The same applies to the NCL, and biochemical, rather than morphological studies are needed for their full elucidation.

The relationship of lipofuscin in NCL, and the wear-and-tear pigment of old age is far from clear, due to obscurity concerning pathogenesis of the former condition. Full analysis of the problem is beyond the scope of this paper. Reference is made to Zeman's interesting considerations<sup>57</sup> on the possible mechanisms by which accelerated lipopigment production could be noxious to the nerve cell. Though such statements must still be regarded as speculative, a parallelism is traced between lipopigment production in normal aging and in the NCL<sup>15</sup>. The latter is thus proposed as a model for human aging, and it is hoped that progress in the NCL may provide answers to hitherto unsolved problems in the field of Gerontology.

#### SUMMARY

Neuronal ceroid-lipofuscinosis (NCL) is a recent term, proposed for accurate designation of the late-onset types of Amaurotic Family Idiocy (AFI).

Histopathology shows ubiquitous intraneuronal accumulation of lipopigments, being the most important factor for characterization of the entity at present time. Biochemical changes and pathogenesis are obscure. NCL is in contrast to the infantile type of AFI (Tay-Sachs disease), in which intraneuronal accumulation of gangliosides (sphingolipids) is due to the well known deficiency of a lysosomal enzyme.

The authors report on four cases of NCL, two brothers of the late infantile (Jansky-Bielschowsky) type and a brother and a sister of the juvenile (Spielmeyer-Sjögren) type. One autopsy and three cortical biopsies revealed moderate to severe distention of the neurons by lipopigment, with nerve cell loss, gliosis and cerebral atrophy. Lipopigment was also increased in liver, heart and spleen. The patients were the first in Brazilian literature in whom the storage material was identified as lipopigment by histochemical methods.

A brief summary of the clinical features of NCL is presented, and relevant problems are discussed, concerning interpretation of the nature of the storage material, and significance of the disease for gerontological research.

---

ACKNOWLEDGEMENTS — *The authors are indebted to Dr. Alberto Pellegrini F.º for the clinical observation of case 3, to Dr. Nubor O. Facure for the cerebral biopsies, to Dr. Leoncio S. Queiroz F.º for the histopathologic description of the eye, and to Dr. and Mrs. John Cook Lane for revision of the manuscript. The skillful technical assistance of Mr. Ismael Vencio (histopathology) and Mr. Mauro Sanches (photographs) is greatly appreciated.*

---

#### RESUMO

*Ceróide-lipofuscinosose neuronal, um tipo de idiotia amaurótica familiar:  
Estudo clínico-patológico de quatro casos*

Estudos histoquímicos, bioquímicos e ultraestruturais permitiram recentemente distinguir dois tipos de entidades nosológicas dentre as doenças conhecidas como "Idiotia amaurótica familiar" (IAF). O primeiro, que inclui a doença de Tay-Sachs, ou tipo infantil de IAF, é constituído por doenças de armazenamento de gangliósides. Sua patogenia é conhecida, baseando-se em deficiências de enzimas lisossômicos. O segundo grupo, cuja patogenia é desconhecida, foi recentemente designado "Ceróide-lipofuscinosose neuronal" (CLN) por Zeman e colaboradores. Corresponde aos tipos infantil tardio, juvenil e adulto de IAF, caracterizando-se histopatologicamente pelo acúmulo intraneuronal de lipopigmentos.

Os autores descrevem quatro casos de Ceróide-lipofuscinosose neuronal, sendo dois irmãos do tipo infantil tardio (Jansky-Bielschowsky) e um casal de irmãos do tipo juvenil (Spielmeyer-Sjögren). Uma autópsia e três biópsias corticais revelaram distensão de moderada a intensa dos neurônios por lipopigmentos, assim como gliose e atrofia cerebral generalizada. Acúmulo simi-

lar foi também encontrado no baço, no fígado e no miocárdio. Os casos descritos são os primeiros da literatura brasileira em que o material de acúmulo foi identificado histoquimicamente como lipopigmento.

Além de breve resumo da clínica da CLN, discutem-se problemas relativos à identificação da substância intraneuronal por histoquímica e microscopia eletrônica.

## REFERENCES

1. ALENCAR, A. A. — Forma juvenil da idiotia amaurótica familiar (doença de Spielmeyer-Vogt-Batten). Mem. Inst. Oswaldo Cruz (Rio de Janeiro) 70:353, 1972.
2. ANDREWS, J. M.; SORESON, V.; CANCELLA, P. A.; PRICE, H. M. & MENKES, J. H. — Late infantile neurovisceral storage disease with curvilinear bodies. Neurology (Minneapolis) 21:207, 1971.
3. von BAGH, K. & HORTLING, H. — Blodfynd vid juvenil amaurotisk idioti. Nord. Med. 38:1072, 1948.
4. BAIN, A. D.; TATESON, R.; ANDERSON, J. M. & CUMINGS, J. N. — Sandhoff's disease (GM-2 gangliosidosis, type 2) in a Scottish family. J. Ment. Def. Res. 16:119, 1972.
5. BENZ, U. U.; PEIFFER, J. & SCHLOTE, W. — Morphologische und biochemische Untersuchungen über einen Fall von juveniler amaurotischer Idiotie (Neuronale Ceroid-Lipofuszinosis). Verh. Deutsch. Ges. Path. 55:427, 1971.
6. BIGNAMI, A.; PALLADINI, G. & BORRI, P. — Neuronal lipidosis with visceral involvement in an adult. Acta Neuropathol. (Berlin) 12:50, 1969.
7. BJÖRKERUD, S. — Isolated lipofuscin granules. A survey of a new field. Adv. Geront. Res. 1:257, 1964.
8. BOEHME, D. H.; COTTRELL, J. C.; LEONBERG, S. C. & ZEMAN, W. — Dominant form of neuronal ceroid-lipofuscinosis. Brain 94:745, 1971.
9. CARPENTER, S.; KARPATI, G.; WOLFE, L. S. & ANDERMANN, F. — A type of juvenile cerebro-macular degeneration, characterized by granular osmiophilic deposits. J. Neurol. Sci. 18:67, 1973.
10. CAVANAGH, J. B. — Batten's disease. A separate entity? Develop. Med. Child Neurol. 12:377, 1970.
11. DANTAS, A. M.; CURI, R. M.; GOMES, J. C. A.; INOCENTE, E. L.; GUEDES, J. B.; PAIVA, L. M. & ESTRADA, A. D. — Doença de Spielmeyer-Vogt — dois casos. Rev. Bras. Oftalmol. 30:87, 1971.
12. DERRY, D. M.; FAWCETT, J. S.; ANDERMANN, F. & WOLFE, L. S. — Late infantile systemic lipidosis. Major monosialgangliosidosis. Delineation of two types. Neurology (Minneapolis) 18:340, 1968.
13. DUFFY, P. E.; KORNFELD, M. & SUZUKI, K. — Neurovisceral storage disease with curvilinear bodies. J. Neuropath. Exp. Neurol. 27:351, 1968.
14. DUKE-ELDER, S. — System of Ophthalmology. Vol. X, Diseases of the Retina. Henry Kimpton, London, 1967.
15. Editor's Note — A new line on age pigment? Lancet 2:451, 1970.
16. GEDIGK, P. & PIOCH, W. — Über die formale Genese lipogener Pigmente. Untersuchungen mit Estern hochungesättigter Fettsäuren. Virchows Arch. 339: 100, 1965.
17. GONATAS, N. K.; GAMBETTI, P. & BAIRD, H. — A second type of late infantile amaurotic idiocy with multilamellar cytosomes. J. Neuropath. Exp. Neurol. 27:371, 1968.
18. GONATAS, N. K.; TERRY, R. D.; WINKLER, R.; KOREY, S. R.; GOMEZ, C. J. & STEIN, A. — A case of juvenile lipidosis: the significance of electron microscopic and biochemical observations of a cerebral biopsy. J. Neuropath. Exp. Neurol. 22:557, 1963.

19. GORDON, N. S.; MASSDEN, H. B. & NORONHA, M. J. — Neuronal ceroid-lipofuscinosis (Batten's disease). *Arch. Dis. Childh.* 47:285, 1972.
20. GREEN, J. B. — Neurophysiological studies in Batten's disease. *Develop. Med. Child Neurol.* 13:477, 1971.
21. HABERLAND, C.; BRUNGRABER, E. G.; WITTING, L. A. & HOF, H. — Late infantile amaurotic idiocy (LIAI). *Neurology (Minneapolis)* 22:305, 1972.
22. HALTIA, M.; RAPOLA, J.; SANTAVUORI, P. & KERÄNEN, A. — Infantile type of so-called neuronal ceroid-lipofuscinosis: Part 2 — Morphological and biochemical studies. *J. Neurol. Sci.* 18:269, 1973.
23. HERMANN, M. M.; RUBINSTEIN, J. L. & MCKHANN, G. M. — Additional electron microscopic observations on two cases of Batten-Spielmeyer-Vogt disease (Neuronal-ceroid-lipofuscinosis). *Acta Neuropathol. (Berlin)* 17:85, 1971.
24. JULIAO, O. F.; CANELAS, H. M. & LONGO, N. A. — Idiotia amaurotica familiar, forma juvenil. Estudo clinico e laboratorial de três casos. *Arq. Neuro-Psiquiat.* (São Paulo) 14:136, 1956.
25. JULIAO, O. F.; MAGALHÃES, P. B. & BRANDI, A. J. — Moléstia de Tay-Sachs. A propósito de três casos. *Arq. Neuro-Psiquiat.* (São Paulo) 2:359, 1944.
26. KLENK, E. — Beiträge zur Chemie der Lipoidosen, Niemann-Picksche Krankheit und amaurotische Idiotie. *Hoppe-Seylers Z. physiol. Chem.* 262:128, 1939.
27. KORNFELD, M. — Generalized lipofuscinosis (generalized Kufs' disease). *J. Neuropath. Exp. Neurol.* 31:668, 1972.
28. KRISTENSSON, K. & SOURANDER, P. — Occurrence of lipofuscin in inherited metabolic disorders affecting the nervous system. *J. Neurol. Neurosurg. Psychiat.* 29:113, 1966.
29. LEVINE, A. S.; LEMIEUX, B.; BRUNNING, R.; WHITE, J. G.; SHARP, H. L.; STADLAN, E. & KRIVIT, W. — Ceroid accumulation in a patient with progressive neurological disease. *Pediatrics* 42:483, 1968.
30. LEVY, J. A.; CANELAS, H. M.; JULIAO, O. F.; MANISSADJIAN, A.; PILEGGI, F. L.; FRANÇA, L. C. M.; TENUTO, R. A. & DE JORGE, F. B. — Idiotia amaurotica. Estudo clinico, bioquímico e histopatológico de quatro casos. *Rev. Paul. Med.* 67:171, 1965.
31. MARQUES, A. — Idiotia amaurotica familiar. Estudo de um caso pessoal e revisão da casuística brasileira. *Arq. Neuro-Psiquiat.* (São Paulo) 1:207, 1943.
32. O'BRIEN, J. S. — GM-1 Gangliosidose. In Stanbury, J. B.; Wyngaarden, J. B. & Fredrickson, D. S. (eds.) — *The Metabolic Basis of Inherited Disease*, 3rd Ed. McGraw-Hill, New York, 1972.
33. O'BRIEN, J. S.; OKADA, S.; HO, M. W.; FILLERUP, D. L.; VEATH, M. L. & ADAMS, K. — Ganglioside storage diseases. *Fed. Proc.* 30:956, 1971.
34. ODOR, D. L.; PEARCE, L. A. & JANEWAY, R. — Juvenile amaurotic idiocy. An electron microscopic study. *Neurology (Minneapolis)* 16:496, 1966.
35. PALLIS, C. A.; DUCKETT, S. & PEARSE, A. G. E. — Diffuse lipofuscinosis of the central nervous system. *Neurology (Minneapolis)* 17:381, 1967.
36. PEARSE, A. G. E. — *Histochemistry, Theoretical and Applied*. Ed. 2. Little, Brown & Co., Boston, 1960.
37. QUEIROZ, L. S. — Ceroide-lipofuscinosose neuronal. *Sinop. Neurol. Psiquiat.* (São Paulo) 2:6, 1973.
38. RESIBOIS, A.; TONDEUR, A.; MOCKEL, S. & DUSTIN, P. — Lysosomes and storage disease. *Int. Rev. Exp. Path.* 9:93, 1970.
39. RICOY-CAMPO, J. R. & BRUENS, J. H. — Contribution critique à l'étude de la variante dite myoclonique des idioties amaurotiques familiales non-gangliosidiques. *J. Neurol. Sci.* 10:435, 1970.
40. ROMEIS, B. — *Mikroskopische Technik*. R. Oldenbourg, München, 1948.
41. ROSENBERG, S. & LEFÈVRE, A. B. — Doença de Tay-Sachs em criança de raça negra. *Arq. Neuro-Psiquiat.* (São Paulo) 28:376, 1970.

42. RYAN, G. B.; ANDERSON, R. McD.; MENKES, J. H. & DENNETT, X. — Lipofuscin (ceroid) storage disease of the brain. Neuropathological and neurochemical studies. *Brain* 93:617, 1970.
43. SAMORAJSKI, T.; ORDY, J. M. & KEEFE, J. R. — The fine structure of lipofuscin age pigment in the nervous system of aged mice. *J. Cell Biol.* 26:779, 1965.
44. SANDHOFF, K.; HARZER, K.; WASSLE, W. & JATZKEWITZ, H. — Enzyme alterations and lipid storage in three variants of Tay-Sachs disease. *J. Neurochem.* 18:2469, 1971.
45. SANTAVUORI, P.; HALTIA, M.; RAPOLA, J. & RAITTA, C. — Infantile type of so called neuronal ceroid-lipofuscinosis: Part I — A clinical study of 15 patients. *J. Neurol. Sci.* 18:257, 1973.
46. SCHRÖDER, J. M.; THOMAS, E. & KOLLMANN, F. — Formvarianten kurvilliner Zytosomen im Gehirn-, Leber- und Knochenmarksbiopsien bei neuroviszeraler Lipidose. *Verh. Deutsch. Ges. Path.* 55:432, 1971.
47. STREHLER, B. L. — On the histochemistry and ultrastructure of age pigment. *Adv. Geront. Res.* 1:343, 1964.
48. STROUTH, J. C.; ZEMAN, W. & MERRITT, A. D. — Leukocyte abnormalities in familial amaurotic idiocy. *New Engl. J. Med.* 274:36, 1966.
49. SUZUKI, K.; JOHNSON, A. B.; MARQUET, E. & SUZUKI, K. — A case of juvenile lipidosis: electron microscopic, histochemical and biochemical studies. *Acta Neuropathol. (Berlin)* 11:122, 1968.
50. SUZUKI, Y.; BERMAN, P. H. & SUZUKI, K. — Detection of Tay-Sachs disease heterozygotes by assay of hexosaminidase A in serum and leukocytes. *J. Pediat.* 78:643, 1971.
51. TOWFIGHI, J.; BAIRD, H. W.; GAMBETTI, P. & GONATAS, N. K. — The significance of cytoplasmic inclusions in late infantile and juvenile amaurotic idiocy. An ultrastructural study. *Acta Neuropathol. (Berlin)* 23:32, 1973.
52. WITZLEBEN, C. L. — Lymphocyte inclusions in a late-onset amaurotic idiocy. Value as a diagnostic test and genetic marker. *Neurology (Minneapolis)* 22:1075, 1972.
53. WITZLEBEN, C. L.; SMITH, K.; NELSON, J. S.; MONTELEONE, P. & LIVINGSTON, D. — Ultrastructural studies in late-onset amaurotic idiocy. Lymphocyte inclusions as a diagnosis marker. *J. Pediat.* 79:285, 1971.
54. WOLMAN, M. — Lipid Pigments. *In* Handbuch der Histochemie, Band V/2. Gustav Fisher Verlag, Stuttgart, 1964.
55. ZEMAN, W. — Historical development of the nosological concept of amaurotic familial idiocy. *In* Vinken, P. J. and Bruyn, G. W. (eds.) — Handbook of Clinical Neurology, Vol. 10, North Holland Publishing Co., Amsterdam, 1970.
56. ZEMAN, W. — Morphologic approaches to the nosology of nervous system defects. *In* Bergsma, D. (ed.) — The Second Conference on the Clinical Delineation of Birth Defects. Part VI, Nervous System. The Williams and Wilkins Co., Baltimore, 1971.
57. ZEMAN, W. — The neuronal ceroid-lipofuscinosis: Batten-Vogt syndrome. A model for human aging? *Adv. Geront. Res.* 3:147, 1971.
58. ZEMAN, W. & ALPERT, M. — On the nature of the stored lipid substance in juvenile amaurotic idiocy (Batten-Spielmeier-Vogt). *Ann. Histochem.* 8:255, 1963.
59. ZEMAN, W.; DONAHUE, S.; DYKEN, P. & GREEN, J. — The neuronal ceroid-lipofuscinosis (Batten-Vogt syndrome). *In* P. J. Vinken and G. W. Bruyn (eds.) — Handbook of Clinical Neurology. Vol. 10. North Holland Publishing Co., Amsterdam, 1970.
60. ZEMAN, W. & DYKEN, P. — Neuronal ceroid-lipofuscinosis (Batten's disease). Relationship to amaurotic family idiocy? *Pediatrics* 44:570, 1969.

*Address reprint requests to: Prof. J. Lopes de Faria — Faculdade de Ciências Médicas — Dept.º de Anatomia Patológica — Caixa Postal 1170 — 13100 Campinas, SP — Brazil.*