

INTRAMEDULLARY SPINAL CORD PARACOCCIDIOIDOMYCOSIS

REPORT OF TWO CASES

BENEDICTO OSCAR COLLI*, JOÃO ALBERTO ASSIRATI JR**, HÉLIO RUBENS MACHADO***,
JOSÉ FERNANDO DE CASTRO FIGUEIREDO****, LEILA CHIMELLI*****,
CÁRMINE PORCELLI SALVARANI*****, FÁBIO DOS SANTOS*****

ABSTRACT - Two cases of intramedullary paracoccidiodomycosis are reported. Paracoccidiodomycosis is a systemic disease that involves the buccopharyngeal mucosa, lungs, lymph nodes and viscera and infrequently the central nervous system. Localization in the spinal cord is rare. Case 1: a 55-year old male admitted with crural paresis, tactile/painful hypesthesia and sphincter disturbances of 15 days duration. Cutaneous-pulmonary blastomycosis was diagnosed 17 years ago. Myelotomography showed a blockade of T3-T4 (intramedullary lesion). The lesion surgically removed was a *Paracoccidoides brasiliensis* granuloma. Treatment with sulfadiazine was started after the surgery. Follow-up of 15 month showed an improvement of the clinical signs. Case 2: a 57-year old male was admitted elsewhere 6 months ago and, with a radiologic diagnosis of pulmonary paracoccidiodomycosis, was treated with amphotericin B. He progressively developed paresthesia and tactile/pain anaesthesia on the left side, sphincter disturbances and tetraparesis with bilateral extensor plantar response and clonus of the feet. Myelotomography showed a blockade of C4-C6 (intramedullary lesion). The lesion was not found during surgical exploration and the patient deteriorated and died. Post-mortem examination revealed an intramedullary tumor above the site of the myelotomy (*Paracoccidoides brasiliensis* granuloma). The preoperative diagnosis of intramedullary paracoccidiodomycotic granulomas is difficult because the clinical and radiologic manifestations are uncharacteristic. Clinical suspicion was possible in our cases based on the history of previous systemic disease. Contrary to intracranial localizations, paracoccidiodomycotic granulomas causing progressive spinal cord compression may require early surgery because response to clinical treatment is slow and the reversibility of neurological deficits depends on the promptness of the decompression.

KEY WORDS: intramedullary paracoccidiodomycosis, granuloma intramedullary blastomycotic, spinal cord compression, surgical treatment, medical treatment.

Granuloma paracoccidiodomycótico intramedular: relato de dois casos

RESUMO - São relatados dois casos de granuloma blastomycótico intramedular. A paracoccidiodomycose é micose sistêmica que atinge predominantemente a mucosa bucofaringea, pulmões, linfonodos e vísceras e infrequentemente o sistema nervoso. A localização medular é rara. Caso 1: paciente masculino, de 55 anos, admitido com parestesias, hipoestesia tátil/dolorosa, paraparesia crural e distúrbios esfinterianos. Tinha diagnóstico de blastomycose cutâneo-pulmonar há 17 anos. A mielotomografia mostrou bloqueio em T3-T4 (lesão intramedular). A lesão removida cirurgicamente revelou-se um granuloma blastomycótico. Após a cirurgia foi tratado com sulfadiazina. Durante o seguimento (15 meses) apresentou melhora do quadro clínico. Caso 2: paciente masculino, de 57 anos, internado em outro hospital há 6 meses por blastomycose pulmonar e tratado com anfotericina B. Desenvolveu parestesias, hipoestesia tátil/dolorosa à esquerda, distúrbios esfinterianos e tetraparesia com sinal de Babinski bilateral e clonus nos pés. A mielotomografia mostrou bloqueio de C4-C6

Division of Neurosurgery - Department of Surgery, Departments of Internal Medicine and Pathology, Hospital das Clínicas, Ribeirão Preto Medical School, University of São Paulo Ribeirão Preto, Brazil: * M.D., PhD, Associate Professor and Head of the Division of Neurosurgery; ** M.D., Assistant Physician, Division of Neurosurgery; *** M.D., PhD., Associate Professor, Division of Neurosurgery; **** M.D., PhD., Assistant Professor; ***** M.D., PhD., Associate Professor, Department of Pathology; ***** M.D., Resident of Neurosurgery. Aceite: 17-abril-1996.

Dr Benedicto Oscar Colli - Department of Surgery HCFMRP, Campus Universitário USP - 14049-900 Ribeirão Preto SP - Brasil. FAX 016 6330836

(lesão intramedular). A lesão não foi encontrada durante a cirurgia e o paciente piorou e faleceu. A necrópsia revelou um granuloma blastomicótico intramedular, acima do local da mielotomia. O diagnóstico dos granulomas blastomicóticos intramedulares apresenta dificuldades porque as manifestações clínicas e radiológicas são incaracterísticas. Nos casos relatados, a suspeita clínica foi baseada nos antecedentes de doença sistêmica prévia. Para os granulomas blastomicóticos raquídicos que causam compressão medular progressiva, ao contrário dos encefálicos, a cirurgia precoce deve ser considerada, pois a regressão com o tratamento clínico é lenta e a reversibilidade dos déficits neurológicos depende da rapidez da descompressão medular.

PALAVRAS-CHAVE: paracoccidioidomycose, granuloma intramedular, compressão medular, tratamento cirúrgico, tratamento clínico.

Paracoccidioidomycosis is a systemic disease caused by the fungus *Paracoccidioides brasiliensis*. Although isolated cases have been reported in some countries in Europe and in North and Central America³ the disease predominates in South America and is therefore also designated as "South American blastomycosis". Most cases are observed in Brazil, where prevalence in different regions has been found 5.6 to 17.5% in studies carried out using intradermal tests¹. The disease is acquired by the inhalatory route and habitually manifests as lesions in the oral mucosa and skin, possibly also involving the lungs, lymph nodes, liver, bones and the adrenal glands in a combined or separated manner, although any organ may be involved. Involvement of the nervous system is not infrequent, ranging from 9.6 to 12.5%, with predominance in the brain and meninges^{2,5,6,11,13,16,17,25-28,30,32,34}. Lesions of the nervous system may manifest as granulomas, meningitis or as a mixed form. Localization in the spinal cord is considered rare, with only seven cases reported in the literature. We report two new cases.

REPORT OF THE CASES

Case 1. JB, registration N° 067103-J, a 54-year old white male driver, married, born and living in Batatais, SP, was admitted to the Neurosurgical Division of our hospital on January 25, 1993. He had been followed at our hospital with a diagnosis of cutaneous-mucosal-pulmonary blastomycosis for 17 years. He was initially medicated with sulfadiazine for several years and later with sulfamethoxazole and trimetoprim for 4



Fig 1. Chest X-ray. Infiltrative reticulo-nodular lesions in the lower two thirds of both lungs, suggesting paracoccidioidomycosis.

years, and was considered cured of the disease. In 1982 he developed Addison's disease due to the adrenal involvement and in 1985 he suffered an acute myocardial infarction, with a good course. On a recent hospitalization he had complained of ascending numbness of the lower limbs of 15 days duration and a progressive decrease in muscle strength which had prevented him from walking for the past week. During the last week he developed fecal and urinary retention. He also reported pain in the lumbar region and decreased sensitivity from the xiphoid process downward. He had been admitted to another hospital where he had been submitted to a spinal tap during which blockade of the spinal canal was observed by the Queckenstedt-Stookey maneuver. Physical examination revealed good general condition, decreased vesicular murmur and crepitations in the upper third of the right lung. Neurologic examination revealed a conscious, oriented patient confined to bed. There were marked flaccid crural paraparesis with predominance on the right, bilateral hyperactive knee and ankle jerks, bilateral extensor plantar response and flexor withdrawal reflexes and tactile and painful hypesthesia from T6. Complementary tests showed: chest X-ray (01/26/93), a radiological picture compatible with paracoccidioidomycosis (Fig 1); cerebrospinal fluid (01/27/93), blockade of the spinal canal, 0.3 cells, 115 mg% proteins, 64 mg% glucose, and 702 mg% chlorides; myelography and myelotomography (01/27/93), partial blockade of the spinal canal at the T3-T4 level due to enlargement of the spinal cord, suggesting an expansive intramedullary process (Figs 2 and 3). With the diagnosis of an intramedullary granuloma, treatment with sulfadiazine and dexamethasone was started and a T2-T5 laminectomy and exeresis of the lesion (01/28/93) were performed (Fig 4). Intraoperative histopathology revealed a granulomatous inflammatory process with caseous material and the presence of fungi which were found to be *Paracoccidioides brasiliensis* upon definitive examination (Fig 5). From 01/28/93 to 02/02/93 he was medicated with sulfamethoxazole and trimetoprim, and

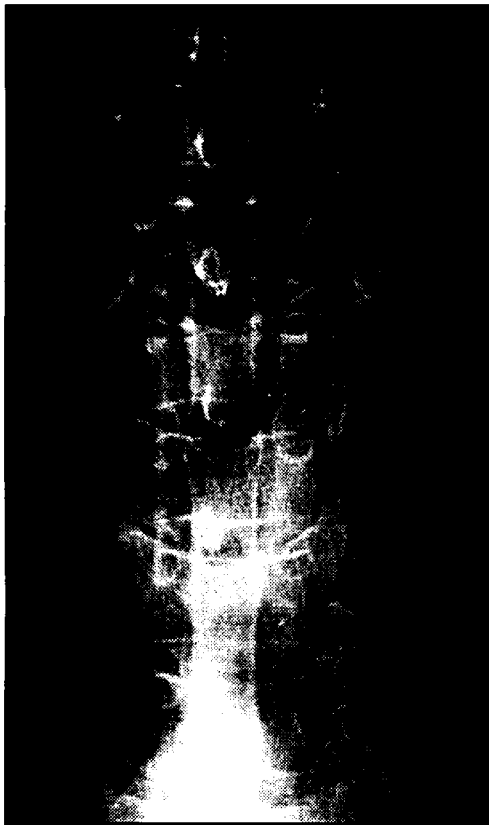

Fig 2. Myelography showing enlargement of the spinal cord (intramedullary expansive process) at the T3-T4 level causing partial blockade of the spinal canal.

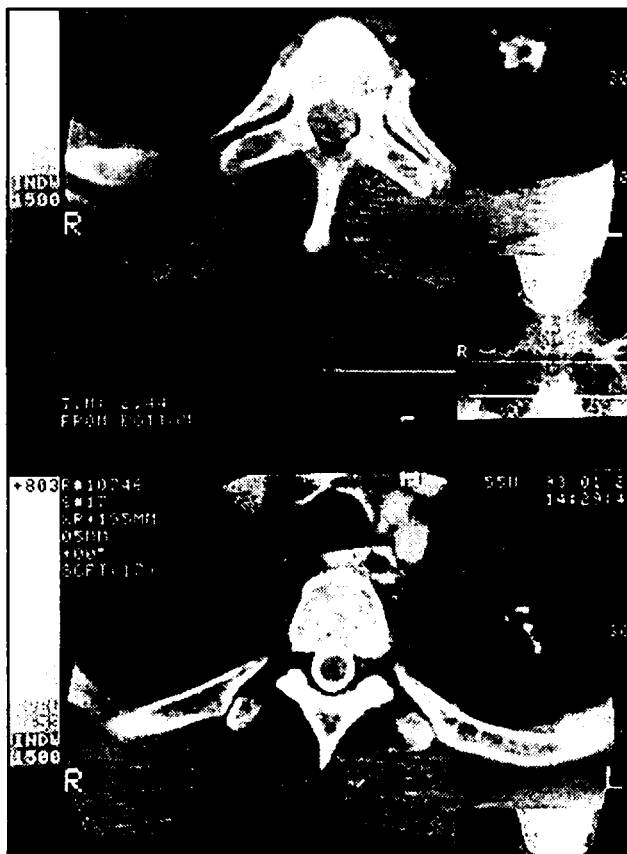


Fig 3A. Myelotomography. Transversal sections at the T6 level showing contrast in the subarachnoid space around the spinal cord (bottom) and at the T4 level showing enlargement of the spinal cord displayed by the absence of contrast around it (top), suggesting an intramedullary expansive process.

then discharged on sulfadiazine. At discharge, he presented normal sphincter functions and slight improvement of paresis. He used sulfadiazine until 03/01/93, when the medication was again switched to sulfamethoxazole and trimetoprim. On 05/25/93 he started to take sulfadiazine again. On the last return visit (8 months after) he presented progressive improvement of spastic crural paraparesis, was walking with support and presented boot hypesthesia in the right lower limb. He continued to take sulfadiazine.

Case 2. PW, registration N° 0380296-K, a 57-year old white male, cleaner, married, born and living in Rifaina, SP, was admitted to the Neurosurgical Division of our hospital on August 15, 1995. He had been admitted in another hospital 6 months ago due to neck pain. Because of chest X-ray images compatible with paracoccidioidomycosis he was submitted to specific treatment with amphotericin B for 28 days. He progressively developed paresthesia and paresis in U-distribution starting in the right superior limb and became incapable of walking since one month. During the last two months he developed urinary and fecal retention. With this clinical picture he was referred to our hospital. Physical examination at admission revealed a severe flaccid tetraparesis, hyperactive appendicular reflexes, bilateral plantar extensor response, clonus of the feet, and tactile and pain anaesthesia in the left side of the body. Complementary test showed: chest X-ray (15/08/95) - images compatible with paracoccidioidomycosis; myelography and myelotomography (17/08/95) - partial blockage of the spinal canal at the C4-C6 level due to enlargement of the spinal cord, suggesting an expansive intramedullary tumor. On August 21 he was submitted to a C3-T1 laminectomy and myelotomy with biopsy that revealed edema and gliosis. After surgery the patient woke up tetraplegic and did not recovery spontaneous respiration.

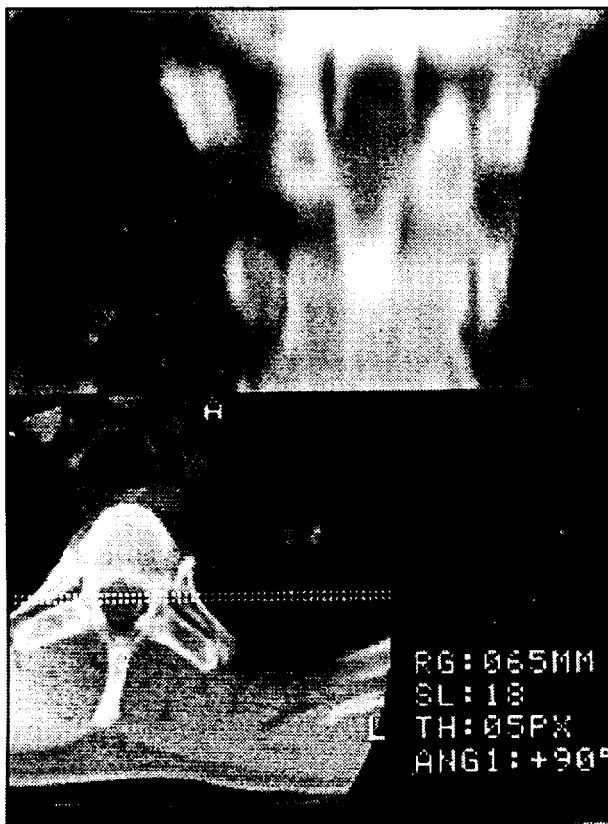


Fig 3B. Myelotomography. Sagittal reconstruction showing a contrast gap at the T3-T4 level due to enlargement of the spinal cord.

The specific treatment was changed for sulfamethoxazole and trimetoprim but he developed pulmonary infection and died on September 12. At post-mortem examination of the spinal cord a well delimited intramedullary tumor was found above the level of the myelotomy. Histopathologic examination revealed a granulomatous inflammatory process with caseous material and the presence of fungi which were found to be *Paracoccidioides brasiliensis*.

DISCUSSION

Involvement of the central nervous system (CNS) by paracoccidioidomycosis was first suggested by Pereira and Jacobs²³ but it was only after the sixties that the problem started to be studied more in depth^{11,16,21,22,24,25,27}. Like other internal organs, the CNS is impaired by dissemination of the fungus from the primary lesions through the lymphatic and blood pathways. Besides the brain hemispheres, which are the regions most frequently involved, other sites such as the medulla, pons, cerebellum, thalamus, spinal cord and spinal roots may also be involved²⁴. In the nervous system the parasites provoke granulomatous reactions of the leptomeninges or isolated or multiple granulomas in the parenchyma. Location in the spinal canal is considered infrequent. Only 7 cases have been reported specifically in relation to spinal cord compromising, all of them in Brazil^{4,5,10,14,18,19}, agreeing with the high frequency of the disease in the country. In these cases the clinical signs suggested spinal cord compression or transverse myelitis. In 4 of them the diagnosis was made based on clinical signs and on the presence of paracoccidioidomycosis out of the CNS and in the 3 remaining cases the diagnosis was made based on histopathological examination of the spinal cord lesion after surgical removal.

A definite diagnosis of isolated granulomas in the nervous system usually is very difficult, except after surgical excision or patient death^{22,23,33}. The clinical manifestations of brain granulomas

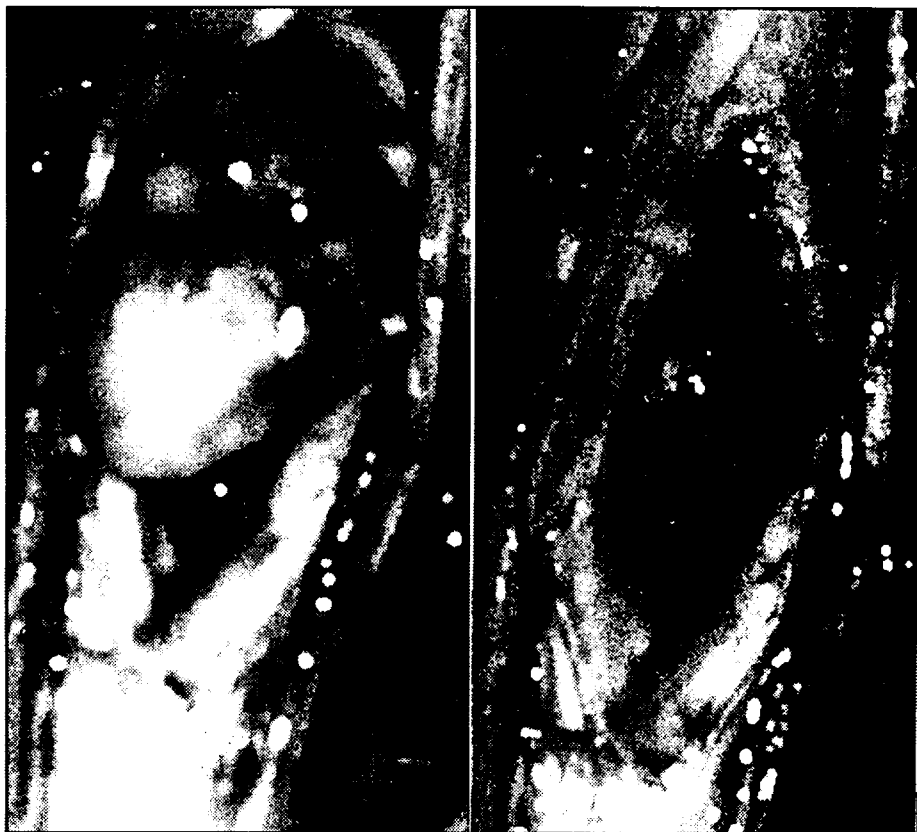


Fig 4. Intraoperative photomicrograph. A (left). Well delimited intramedullary expansive process after median myelotomy. B(right). Spinal cord decompressed after the removal of the lesion.

are nonspecific, reflecting an expansive process of slow evolution⁷. Intraspinial granulomas usually progress to a picture of spinal cord compression^{4,5,14,18,23,33}, which, due to the lack of space, may progress in a more rapid and severe manner. Minguetti¹⁶ described the characteristics of encephalic blastomycotic granulomas. However, these findings do not allow precise differentiation with other expansive lesions, especially tuberculous or toxoplasmotic granulomas or even some types of neoplasias. The neuroradiological characteristics of intramedullary granulomas are also nonspecific^{4,5,14,18,33}. Myelography and myelotomography demonstrate an enlargement of the spinal cord with full or partial blockade of the spinal canal. Magnetic resonance images reveal an expansive process, but with no characteristics that might permit its specific diagnosis³³. The hypothesis of a granuloma of the nervous system should be raised when multiple lesions are observed by computerized tomography⁷. In these cases, the evidence of pulmonary involvement by the disease, at time asymptomatic, may suggest the etiologic diagnosis. In the hypothesis of granulomas of the CNS, due to the high incidence of tuberculosis and blastomycosis in Brazil, these granulomas should be most frequently kept in mind⁸. Exceptionally, when there is previous or current evidence of systemic disease, a granuloma of the nervous system should be the primary suspicion in the presence of signs and symptoms suggesting an intracranial or intraspinal expansive process^{7,8,22}, as observed on both cases reported here.

In our service, blastomycosis has been preferentially treated with sulfadiazine at an attack dose of 6.0 g per day for adults. After clinical remission, the dose is reduced to 2.0 to 3.0 g per day and is maintained for at least 3 years. After this period, treatment may be interrupted in selected

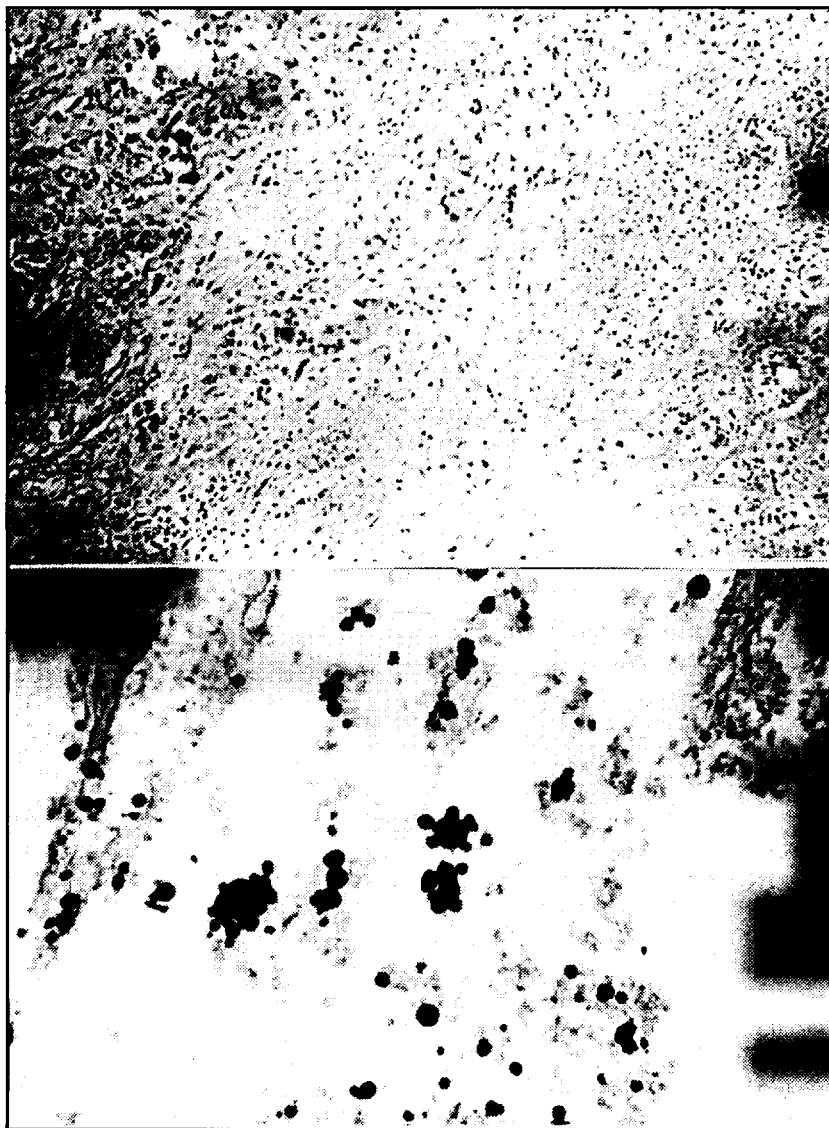


Fig 5. Histopathological examination of the lesion. A (top). Chronic granulomatous inflammatory process with multinucleated giant cells. HE, 200X. B (bottom). Numerous silver-stained fungi with the characteristics of Paracoccidioides brasiliensis. GMS, 900X.

cases. The criteria for cure are the absence of signs and symptoms of the disease, normalization of inflammatory activity tests and negativity of specific serologic reactions (or their stabilization at residual levels). In cases of intolerance of, or a poor response to sulfadiazine, a combination of sulfamethoxazole and trimetoprim, fluconazole, ketoconazole, itraconazole, and amphotericin B may be used as alternative drugs^{9,12,15,19-21,29,31}.

In most cases, treatment of brain granulomas is conservative, with the preferential use of sulfadiazine because of its good penetration in the nervous system, according to the schedule presented above. Surgical treatment should be indicated when there is a diagnostic doubt, when there is no

response to clinical treatment or when there is a risk to life due to transtentorial herniation. However, the response to drug treatment is slow. Due to the small number of cases reported it is not clear if intramedullary blastomycotic granulomas should be surgically treated or if they are best treated with specific therapy. Canelas et al.⁵ reported 2 cases that improved with clinical treatment. Because of the slowly response to medical treatment observed in cerebral granulomas we believe that early surgical resection of the lesion should be considered in cases of progressive spinal cord compression in order to preserve neurologic function, as observed in our first case. Inflammatory reaction and severe parenchymal edema caused by these granulomas make precise level localization by myelography and myelotomography difficult, as observed in the second case. Magnetic resonance imaging of the spinal cord and intraoperative ultrasound could help to achieve this goal. Clinical treatment should also be started early, and the role of corticosteroids in the protection of the nervous tissue and in the treatment of edema is controversial. In both cases presented here, treatment with sulfadiazine and dexamethasone was started as soon as the diagnosis was suspected.

REFERENCES

1. Andrade JJA.F, Andrade TM, Lucasz CS, Rodrigues MC, Preuss M, Lourenço R, Badaró R. Inquérito com paracoccidioidina em uma população da Bahia (Brasil). *Rev Inst Med Trop São Paulo* 1984;26:1-6.
2. Araujo JC, Werneck L, Cravo MA. South American blastomycosis presenting as posterior fossa tumor. *Neurosurg* 1978;49:425-428.
3. Barbosa W. Blastomycose sul americana: contribuição ao seu estudo no Estado de Goiás. Thesis, Federal University of Goiás, Goiânia, 1968.
4. Braga FM, Okamura M. Blastomycose medular. *Seara Med Neurocir (São Paulo)* 1973;1:435-441.
5. Canelas HM, Lima FP, Bittencourt IM, Araújo RP, Anghinah A. Blastomycose do sistema nervoso. *Arq Neuropsiquiatr* 1951;9:203-22.
6. Campos EC, Cuderematori MS. Blastomycose mesencefálica. *Neurobiologia* 1963;26:83-102.
7. Colli BO, Martelli N, Assirati JA Jr, Machado HR. Lesões múltiplas na tomografia computadorizada do crânio. *Arq Neuropsiquiatr* 1986;44:155-164.
8. Colli BO, Assirati JA Jr, Machado HR, Figueiredo JFC, Chimelli L. Tuberculomas cerebrais. *Arq Bras Neurocir* 1994;4:55-64.
9. Del Negro G. Ketonazole in paracoccidioidomycosis: a long-term therapy study with prolonged follow-up. *Rev Inst Med Trop São Paulo* 1982;24:27-29.
10. Farage M Filho, Braga MRG, Kuhn MDS. Granuloma blastomycótico na medula cervical: registro de um caso. *Arq Neuropsiquiatr* 1977;35:151-155.
11. Hutzler RU, Brussi MLP, Capitani CM, Lima SS. Acometimento neurológico da paracoccidioidomycose avaliado pela tomografia computadorizada do crânio. *Rev Paul Med* 1985;103:243-244.
12. Lima NS, Teixeira GA, Miranda JL, Valle ACF. Treatment of South American blastomycosis (paracoccidioidomycosis) with orally administered miconazole. *Rev Inst Med Trop São Paulo* 1978;20:347-352.
13. Maffei WE. Micoses do sistema nervoso. *An Fac Med Univ São Paulo* 1943;29:297-327.
14. Marchiori E, Freitas MAL, Ranufo AML. Paracoccidioidomycose medular: relato de um caso. *Arq Neuropsiquiatr* 1989;47:224-229.
15. Marcondes J, Meira DA, Mendes RP, Pereira PCM, Barravieira B, Mota NGS, Morceli J. Avaliação do tratamento da paracoccidioidomycose com ketonazol. *Rev Inst Med Trop São Paulo* 1984;26:113-121.
16. Minguetti G. Tomografia computadorizada dos granulomas blastomycóticos encefálicos. *Rev Inst Med Trop São Paulo* 1983;25:99-107.
17. Minguetti G, Madalozzo LE. Paracoccidioidal granulomatosis of the brain. *Arch Neurol* 1983;40:100-102.
18. Morato-Fernandez RN, Beraldo PSS, Masini M, Costa PHC. Paracoccidioidomycose do sistema nervoso de localização intramedular e cerebral. *Arq Neuropsiquiatr* 1991;49:192-197.
19. Moura LP, Raffin CN, Del Negro GMB, Ferreira MS. Paracoccidioidomycose evidenciando comprometimento medular tratada com sucesso por fluconazol. *Arq Neuropsiquiatr* 1994;52:82-86.
20. Negroni R. Azole derivatives in the treatment of paracoccidioidomycosis. *Ann NY Acad Sci* 1988;544:497-503.
21. Negroni R, Rubinstein P, Herрман A, Gimenez A. Results of miconazole therapy in twenty-eight patients with paracoccidioidomycosis (South American blastomycosis). *Proc R Soc Med* 1977;70:24-28.
22. Nóbrega JPS. Micoses do sistema nervoso central. *Arq Bras Neurocir* 1982;1:157-171.
23. Pedro RJ, Branchini MLM, Lucca RS, Silveira ML, Fature NO, Amato V Neto. Paracoccidioidomycose do sistema nervoso central: a propósito de 2 casos. *Rev Inst Med Trop São Paulo* 1980;22:269-274.
24. Pereira JM, Jacobs F. Um caso de blastomycose cutânea com acessos epilépticos. *Ann Paul Cir* 1919;10:217-219.
25. Pereira WC, Raphael A, Sallum J. Lesões neurológicas na blastomycose sul americana: estudo anatomopatológico de 14 casos. *Arq Neuropsiquiatr* 1965;23:95-112.
26. Pereira WC, Tenuto RA, Raphael A, Sallum J. Localização encefálica da blastomycose sul americana: considerações a propósito de 9 casos. *Arq Neuropsiquiatr* 1965;23:113-126.
27. Pimentu AM, Marques JS, Settani FAP. Blastomycose cerebral: forma tumoral. *Seara Med Neurocir* 1972;1:73-84.
28. Raphael A. Localização nervosa da blastomycose sul americana. *Arq Neuropsiquiatr* 1966;24:69-90.
29. Restrepo A, Gomez I, Cano LE, Arango MD, Gutierrez F, Sunin A, Robledo MAI. Treatment of paracoccidioidomycosis with ketonazole: a three year experience. *Am J Med* 1983;78:53-57.
30. Ritter FH. Tumor cerebral granulomatoso por paracoccidioidina: a propósito de 2 casos operados. *Arq Neuropsiquiatr* 1948;6:352-359.
31. Stevens DA, Restrepo A, Cortes A, Betancurt T, Galgiani JN, Gomes I. Paracoccidioidomycosis (South American blastomycosis): treatment with miconazole. *Am J Trop Med Hyg* 1978;27:801-807.
32. Teive HAG, Arruda WO, Ramina R, Meneses MS, Bleggi-Torres LF, Telles FQ Filho. Paracoccidioidomycosis granuloma simulando posterior fossa tumour. *J R Soc Med* 1991;84:562-563.
33. Volker JL, Muller J, Worth RM. Intramedullary spinal Histoplasma granuloma. *J Neurosurg* 1989;70:959-961.
34. Wittig EO, Kasting GL, Leal R. Neuroblastomycose: registro de três casos. *Arq Neuropsiquiatr* 1968;23:73-79.