

SPONTANEOUS ACUTE SUBDURAL HEMATOMA CONTRALATERAL TO AN ARACHNOID CYST

*José Gilberto de Brito Henriques¹, Geraldo Pianetti Filho²,
Karina Santos Wandeck Henriques³, Luiz Fernando Fonseca⁴,
Renato Pacheco de Melo⁵, Márcia Cristina da Silva⁶, José Augusto Malheiros⁷*

ABSTRACT - Arachnoid cysts (AC) are extra-cerebral cerebrospinal fluid collections of unknown origin. They correspond to 1% of all intracranial nontraumatic space-occupying lesions and appear more frequently in the middle fossa (50%). More than 25% of these cysts are incidental findings and the majority of patients are asymptomatic. Seizures, intracranial hypertension signs, neurological deficits, macrocrania, developmental delay and bulging of the skull are the main signs and symptoms of the lesion. AC rupture and bleeding are rare, usually occurring in young adults and associated with trauma. The risk of hemorrhage does not exceed 0.04% / year. We describe the case of a ten-year-old boy who presented with acute signs of intracranial hypertension secondary to a spontaneous acute subdural hematoma, contralateral to an AC of the middle fossa. Three factors were significant in this case: signs and symptoms occurred spontaneously; the presence of an acute subdural hematoma exclusively contralateral to the AC; successful outcome of the conservative treatment.

KEY WORDS: arachnoid cyst, subdural hematoma, pediatric neurosurgery.

Hematoma subdural agudo espontâneo contralateral a cisto aracnóideo

RESUMO - Os cistos aracnóideos (CA) são coleções líquóricas extra-cerebrais e intra-aracnóideas de origem desconhecida. Correspondem a 1% de todas as lesões expansivas intracranianas não traumáticas e têm nítido predomínio na fossa média (50%). Até 25% destes cistos são achados incidentais sendo que a maioria dos pacientes é assintomática. Crises epilépticas, sinais de hipertensão intracraniana, déficits neurológicos focais, macrocrania, atraso no desenvolvimento e abaulamento da calota craniana são os principais sinais e sintomas da lesão. A ruptura dos CA, assim como seu sangramento, são situações raras, geralmente associadas a traumas e acometem adultos jovens. O risco de hemorragia em pacientes com CA não excede 0,04% ao ano. É descrito caso de paciente de dez anos de idade que subitamente apresentou sinais de hipertensão intracraniana secundários a hematoma subdural agudo espontâneo, contralateral a volumoso CA de fossa média. Três fatores foram de relevância neste paciente: a ocorrência de sinais e sintomas espontaneamente, especialmente em um menino; presença de hematoma subdural agudo exclusivamente contralateral ao CA; e a boa evolução com o tratamento conservador.

PALAVRAS-CHAVE: cisto aracnóideo, hematoma subdural, neurocirurgia pediátrica.

Arachnoid cysts (AC) are extra-cerebral, intra-arachnoidal cerebrospinal fluid (CSF) collections of unknown origin. They correspond to 1% of all intracranial nontraumatic space-occupying lesions¹ and appear more frequently in the middle fossa (50%)²⁻⁴. Up to 25% of these cysts are incidental findings and the majority of patients are asymptomatic^{5,6}. Rarely they can become symptomatic due to cyst enlargement or hemorrhage, often after head trauma¹.

We report a case of a ten-year-old child who had

acute signs of intracranial hypertension secondary to a spontaneous acute subdural hematoma, contralateral to a large AC of the middle fossa. Aspects of the treatment and possible causes of the subdural hematoma are discussed.

CASE

A ten-year-old boy, resident at a country area, was awoken at night with an abrupt intense headache, accompanied by vomiting and ocular deviation. The mother in-

¹MD, Pediatric Neurosurgeon of Hospital das Clínicas, Federal University of Minas Gerais and Mater Dei Hospital. Professor of Medicine, Unifenas University, Belo Horizonte MG, Brazil; ²MD, Professor of Medicine, Federal University of Minas Gerais. Head of Pediatric Neurosurgery of Hospital das Clínicas UFMG; ³MD, Pediatric Neurology of Mater Dei and Belo Horizonte Hospitals; ⁴MD, Head of Pediatric Neurology Department of Centro Geral de Pediatria (FHEMIG) and Hospital Mater Dei; ⁵MD, Pediatric Neurology of São Vicente and São José Hospitals; ⁶MD, Pediatric Neurosurgeon of João XXIII and São Camilo Hospitals; ⁷MD, Resident of Neurosurgery of Hospital das Clínicas, Federal University of Minas Gerais.

Received 13 April 2007, received in final form 12 July 2007. Accepted 24 August 2007.

Dr. José Gilberto de Brito Henriques - Rua Araguari 1045 / 301 - 30190-111 Belo Horizonte MG - Brasil. E-mail: henriques_jgb@hotmail.com

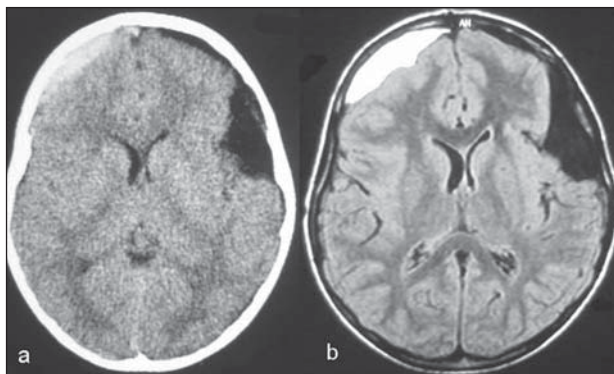


Fig 1. (A) CT scan and (B) MRI showing left temporal arachnoid cyst with subdural hygroma adjacent to the cyst associated to an acute subdural hematoma contralateral to the cyst.

formed that the pain persisted for one week and resolved spontaneously. Because of the distant country location, where the family lives, medical assistance was very difficult. The ocular deviation persisted and the patient was taken to an ophthalmologic consultation. At examination, convergent strabismus on the right side and bilateral papilledema were observed. The patient was sent to a pediatric neurologist and a computed tomography (CT) scan showed a lesion suggestive of a left temporal AC with signs of a subdural hygroma adjacent to the cyst. There was also a fronto-parietal acute subdural hematoma contralateral to the cyst, with slight mass effect (Fig 1A). There was no sign of an acute hematoma ipsilateral to the cyst. A neurosurgical consultation was possible one month after the beginning of symptoms. At that moment, there were no complaints of headaches or diplopia and physical examination demonstrated only mild papilledema. Parents and the patient denied any type of previous trauma or other disease and confirmed the acute onset of the symptoms. Magnetic resonance imaging (MRI) of the brain (Fig 1B) confirmed the findings of the CT scan and the absence of vascular abnormalities on MR angiography (Fig 2). As the headache and strabismus had disappeared and the papilledema was regressing, conservative treatment was chosen. The patient remained hospitalized for one week. A new CT scan showed regression of the hematoma. Another CT scan was ordered eight months after the bleeding and demonstrated complete resolution of the hematoma and an unchanged AC (Fig 3).

DISCUSSION

Most of AC are asymptomatic^{7,8}. Seizures, signs of intracranial hypertension, focal neurological deficits, macrocrania, developmental delay and bulging of the skull at a site corresponding to the cyst are the main signs and symptoms of the lesion^{8,9}. In the case reported here, the patient did not present any sign or symptom of an AC until the occurrence of the subdural hematoma. Rupture of the AC, and also its bleeding, are rare, usually associated with trauma in young adults^{1,4,9}. The risk of bleeding of AC is 0.04%

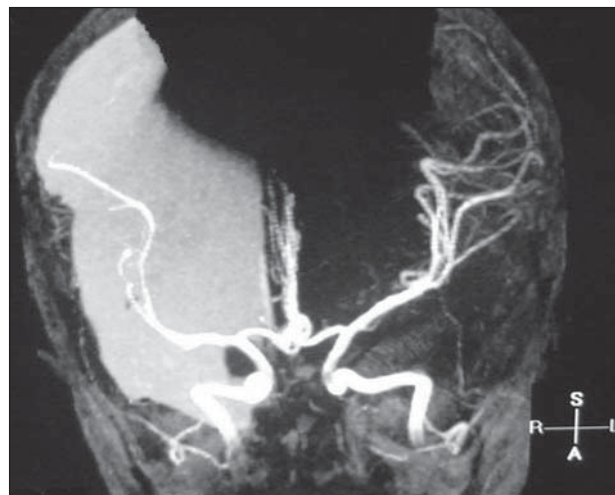

Fig 2. MRI angiography showing no vascular abnormality.

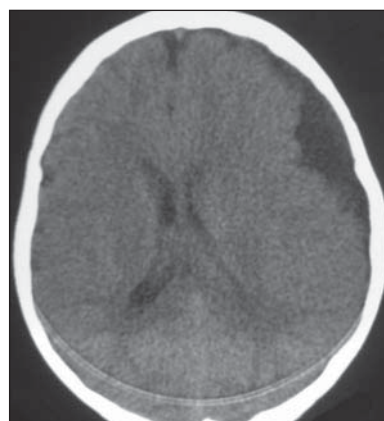


Fig 3. CT scan eight months after the beginning of symptoms showing complete resolution of subdural hematoma and arachnoid cyst without changes.

/ year⁴. Iaconetta published a review of 37 cases reported which had AC associated with intracystic hemorrhage and subdural hematomas¹. The subdural hematoma was ipsilateral to the AC in 21 patients. There were bilateral hematomas in two patients. There was no report of an exclusively contralateral hematoma.

Two hypotheses could explain the occurrence of exclusively contralateral hematomas: the hematoma may be the result of a spontaneous rupture of an AC that also presents a hygroma which could have reached the contralateral subdural space. At that point the hygroma may have caused the rupture of a vessel resulting in bleeding at the opposite side of the AC. The spontaneous rupture of AC has been reported in the literature and can occur as the result of continuing CSF production by its walls, however, the occurrence of an exclusively contralateral hematoma is extremely rare^{3,4,7}.

Another hypothesis for the contralateral hematoma is that the subdural bleeding might have occurred

initially on both sides and they would be at different stages of resolution on CT scan: in a chronic stage on the left and still on an acute stage on the right. This latter hypothesis seems to be the least probable one, due to the intense signal difference of the lesions on the initial CT scan.

Other hypotheses were considered. The association of AC and arteriovenous malformations has been described¹⁰. Thus, an MR angiography was requested and demonstrated no vascular abnormalities. The possibility of head trauma also was investigated but the patient and his parents strongly denied it and, in the first examination by the local doctor, when the symptoms started, there were no signs of head trauma that could justify the hematoma. Trivial traumas could have caused intracystic bleeding by rupture of vessels inside the cyst itself, since these vessels do not have parenchymal support¹¹, but it would not justify the contralateral bleeding.

The ideal treatment of asymptomatic AC of the middle fossa remains undefined. Some authors recommend prophylactic surgery but this is not the approach generally used⁹. By the time our patient came for a neurosurgical consultation, more than 30 days had passed from the beginning of symptoms. Therefore a conservative approach was chosen. Had he been evaluated at the beginning of his symptoms, surgical treatment would have been indicated. If surgical treatment was necessary late in the course of the disease, pre-operative intracranial pressure monitoring could have been useful¹² in order to define intracranial hypertension. The conservative treatment was also reported by Parsch in two patients with an AC and associated hematomas that presented mild symptoms. Both had favorable outcomes⁴. When emergency surgery is necessary for patients with AC and subdural hematomas the direct approach to the AC is usually not necessary, because the cyst frequently decreases or disappears after the evacuation of the hematoma or hygroma^{4,13,14}. This is the expected outcome for intracystic or ipsilateral hematomas, which are different of the contralateral hematoma of our patient.

Despite the good outcome and resolution of the subdural hematoma, the AC remains unchanged as seen on follow-up imaging exams (Fig 3). An enlargement of the AC is seldom noted; conversely its sponta-

neous disappearance is more frequently described^{15,16}. Besides, surgical approach of the AC after evacuation or spontaneous resolution of the hematoma should only be undertaken if the pre-operative symptoms persist⁴.

The present case illustrates an unusual occurrence of AC associated with contralateral subdural hematoma. This case allowed to know a little more about the presentation and natural history of the AC. Three factors were significant: the spontaneous occurrence of signs and symptoms not related to trauma, especially in a child; the presence of a contralateral subdural hematoma associated to an AC; the successful outcome after a conservative treatment.

REFERENCES

1. Iaconetta G, Esposito M, Maiuri F, Cappabianca P. Arachnoid cyst with intracystic haemorrhage and subdural haematoma: case report and literature review. *Neurol Sci* 2006;26:451-455.
2. Aicardi J, Bauman F. Supratentorial extracerebral cysts in infants and children. *J Neurol Neurosurg Psychiatry* 1975; 38:57-68.
3. Harsh GR IV, Edwards MSB, Wilson CB. Intracranial arachnoid cysts in children. *J Neurosurg* 1986;64:835-842.
4. Parsch CS, Krauss J, Hofmann E, Meixensberger J, Roosen K. Arachnoid cysts associated with subdural hematomas and hygromas: analysis of 16 cases, long-term follow-up, and review of the literature. *Neurosurgery* 1997;40:483-490.
5. Galassi E, Gaist G, Giuliani G, Pozzati EU. Arachnoid cysts of the middle cranial fossa: experience with 77 cases treated surgically. *Acta Neurochir (Wien)* 1988;42(Suppl):S201-S204.
6. Garcia-Bach M, Isamat F, Vila F. Intracranial arachnoid cysts in adults. *Acta Neurochir (Wien)* 1988;42(Suppl):S205-S209.
7. Gosalakal JA. Intracranial arachnoid cysts in children: a review of pathogenesis, clinical features, and management. *Pediatr Neurol* 2002;26: 93-98.
8. Mazurkiewicz-Beldzinska M, Dilling-Ostrowska E. Presentation of intracranial arachnoid cysts in children: correlation between localization and clinical symptoms. *Med Sci Monit* 2002;8:462-465.
9. Poirrier AL, Ngosso-Tetanye I, Mouchamps M, Misson JP. Spontaneous arachnoid cyst rupture in a previously asymptomatic child: a case report. *Eur J Paediatr Neurol* 2004;8:247-251.
10. Pascual-Castroviejo I, Pascual-Pascual JI, Blazquez MG, Lopez-Martin V. Spontaneous occlusion of an intracranial arteriovenous malformation. *Childs Brain* 1977;3:169-179.
11. Eustace S, Toland J, Stack J. CT and MRI of arachnoid cyst with complicating intracystic and subdural haemorrhage. *J Comput Assist Tomogr* 1992;16:995-997.
12. Di Rocco C, Tamburrini G, Caldarelli M, Velardi F, Santini P. Prolonged ICP monitoring in Sylvian arachnoid cysts. *Surg Neurol* 2003;60:211-218.
13. Albuquerque FC, Giannotta SL. Arachnoid cyst rupture producing subdural hygroma and intracranial hypertension: case reports. *Neurosurgery* 1997;41:951-956.
14. Mori K, Yamamoto T, Horinaka N, Maeda M. Arachnoid cyst is a risk factor for chronic subdural hematoma in juveniles: twelve cases of chronic subdural hematoma associated with arachnoid cyst. *J Neurotrauma* 2002;19:1017-1027.
15. Dodd RL, Barnes PD, Huhn SL. Spontaneous resolution of a prepontine arachnoid cyst. Case report and review of the literature. *Pediatr Neurosurg* 2002;37:152-157.
16. Yamauchi T, Saeki N, Yamaura A. Spontaneous disappearance of temporo-frontal arachnoid cyst in a child. *Acta Neurochir (Wien)* 1999; 141:537-540.