

# BROCA'S APHEMIA

## An illustrated account of its clinico-anatomic validity

Ricardo de Oliveira-Souza<sup>1,2</sup>, Jorge Moll<sup>2</sup>, Egas M.A. Caparelli-Dáquer<sup>1,2</sup>

**ABSTRACT - Objective:** To present the case of a 54-year-old man with loss of speech, but with preservation of voluntary facio-lingual motility, language and other cognitive abilities (Broca's aphemia). **Method:** Observation of patient oral communicative abilities and general behavior, neuropsychological assessment and cranial computed tomography. **Results:** Computed tomography showed a hyperdense lesion in the sub-cortex of the left precentral gyrus corresponding to Brodmann's area 6 and 44. Neuropsychological assessment confirmed that the major cognitive domains were intact. **Conclusion:** Our patient reiterates the validity of Broca's aphemia as a clinico-anatomic entity allowing us to portray it for the first time in pictures. From a neurobehavioral perspective, aphemia is related to apraxia rather than to aphasia, a fact that may have hampered the full grasp of its far-reaching implications for neurology and aphasiology.

**KEY WORDS:** aphemia, Broca's area, Broca's aphasia, apraxia.

### Afemia de Broca: um relato ilustrado sobre sua validade anátomo-clínica

**RESUMO - Objetivo:** Apresentar o caso de um paciente de 54 anos de idade com perda da fala, mas preservação da linguagem, das demais capacidades cognitivas, e da motilidade fácio-lingual voluntária (afemia de Broca). **Método:** Observação da capacidade de comunicação oral e do comportamento geral, exame neuropsicológico e tomografia computadorizada do crânio. **Resultados:** A tomografia computadorizada revelou lesão hiperdensa no subcórtex do giro precentral esquerdo correspondendo às áreas 6 e 44 de Brodmann. O exame neuropsicológico confirmou que os principais domínios cognitivos se encontravam intactos. **Conclusão:** Nosso paciente reiterou a validade da afemia de Broca como entidade anátomo-clínica permitindo documentá-la em fotos pela primeira vez. Da perspectiva neurocomportamental, a afemia está vinculada às apraxias e não às afasias, o que pode ter prejudicado a apreensão plena do seu profundo significado para a neurologia e para a afasiologia.

**PALAVRAS-CHAVE:** afemia, área de Broca, afasia de Broca, apraxia.

Pierre Paul Broca (1824-1880) coined the term "aphemia" for the loss of speech without impairment of language in patients with left frontal lobe damage<sup>1</sup>. As shown in the passage below, Broca was mostly impressed by retained ability of such patients to move the faciolingual territories employed in speech:

"There are cases where the general language faculty persists unaltered, where the auditory apparatus is intact, where all the muscles, not even excepting those of the voice and those of articulation, obey the will, and yet where a cerebral lesion abolishes articulated language. This abolition of speech (...) constitutes a symptom so singular that it seems to me useful to designate it with a special name (...) aphemia ( $\alpha$ , *deprive*;  $\varphi\eta\mu\iota$ , *I speak, pronounce*); it is only

the faculty of articulating words that these patients lack. They hear and comprehend all that one says to them; they all have their intelligence; they emit vocal sounds with ease; they execute with their tongue and their lips movements much more extensive and energetic than those required for the articulation of sounds, and yet the perfectly sensible response that they would want to make is reduced to a very small number of articulated sounds, always the same and always performed in the same manner (...)"

We report on a case of aphemia very similar to the one Broca described on patient Lelong<sup>2</sup>. To our knowledge, this is the first pictorial illustration of the amazing preservation of voluntary motor power in the faciolingual territories employed in speech in a speechless patient. This dissociation rests at the

<sup>1</sup>Hospital Universitário Gaffrée e Guinle, Rio de Janeiro RJ, Brazil; <sup>2</sup>Cognitive and Behavioral Neuroscience Unit, LABS - D'Or Hospitals Network, Rio de Janeiro RJ, Brazil.

Received 27 July 2007. Accepted 22 September 2007.

Dr. Ricardo de Oliveira-Souza - Rua Conde de Bonfim 232 / 304 - 20550-012 Rio de Janeiro RJ - Brasil. E-mail: rdeoliveira@gmail.com

root of most inferences on the existence of a cerebral "speech center" apart from motor "centers" related to the production of voluntary faciolingual movements unrelated to speech.

**CASE**

A 54-year-old right-handed (Edinburgh Inventory=100) waiter with 8 years of formal education lost the ability to speak and swallow on the evening before consultation. His ability to swallow rapidly returned to normal, but he remained speechless and unable to spontaneously generate and repeat even single words, although he retained the ability to vocalize a sound resembling an "Ah..." Although he strived to articulate consonant and other vowel sounds, he was absolutely unsuccessful. He did not present verbal stereotypies or recurring utterances. He nonetheless communicated by gestures and writing, and by soliciting the aid of his wife and daughters to convey what he meant. He was oriented to time and place, and understood oral and written language perfectly. He could write meaningful sentences, both spontaneously and on dictation, with correct orthography and spelling. Figure 1 (bottom) shows a sample of the patient's handwriting and a freehand copy of two intersecting pentagons. He could sit, stand, and walk, and execute complex orofacial and limb movements in response to verbal and gestural (visuo-imitative) commands [Florida Apraxia Screening Test = 15/15<sup>3</sup>]. At rest, spontaneous blinking was symmetric, but the lower face deviated slightly to the left (Fig 1A). On command, he contracted the frontalis, corrugator, and orbicularis oculi (Fig 1B). His ability to pucker the lips (Fig 1C) contrasted with his inability to retract or lift the right corner of the mouth (Fig 1D). The tongue was trophic and without fasciculations (Fig 1E). The soft palate and tongue did not deviate at rest or dur-

ing movement. There was no emotional incontinence. Fundoscopy and eye movements were normal. He had no history of hypertension or diabetes, the heart rate was regular and the blood pressure was 130x80 mmHg. He denied fever, headache, visual symptoms, dizziness, incontinence, and fainting. He fared normally on the Mini-Mental State Exam (28/30), Token Test (33/36), Right-Left Orientation (20/20), 3D Block Construction (29/29) (Fig 1F), Visual Form Discrimination (28/32), Judgment of Line Orientation (19/30), and the Visual Organization (26/30) tests<sup>4</sup>. On the Wisconsin Card Sorting test he completed one category and committed 23 perseverative errors. He scored 24/36 (normal  $\geq 25/36$ ) on the Tower of London task<sup>5</sup>. Figure 1K shows a sample of spontaneous handwriting, Figure 1H shows a freehand copy of intersecting pentagons. CT (10 mm slices, parallel to the orbito-meatal line) showed a hyperdense egg-shaped lesion surrounded by a thin hypodense halo in the subcortex of the left lower precentral gyrus exerting a slight mass effect on surrounding regions (Fig 1I). The lesion spared the insula, the temporal lobe, and the medial hemispheric wall, suggestive of a lobar hematoma in the subcortex of Brodmann's areas (BA) 6 and 44<sup>6</sup>. Written informed consent was obtained from the patient to publish his pictures. He died a few days later of an acute myocardial infarction before completion of further tests.

**DISCUSSION**

The relevant findings of this case were (i) the loss of speech with preservation of voice, language and cognition, with (ii) relative sparing of faciolingual motility and praxis, and (iii) the location of the lesion. Our patient presented loss of speech in the absence of proportional faciolingual paralysis and aphasia. He did not develop agraphia, alexia, and apraxia – in par-

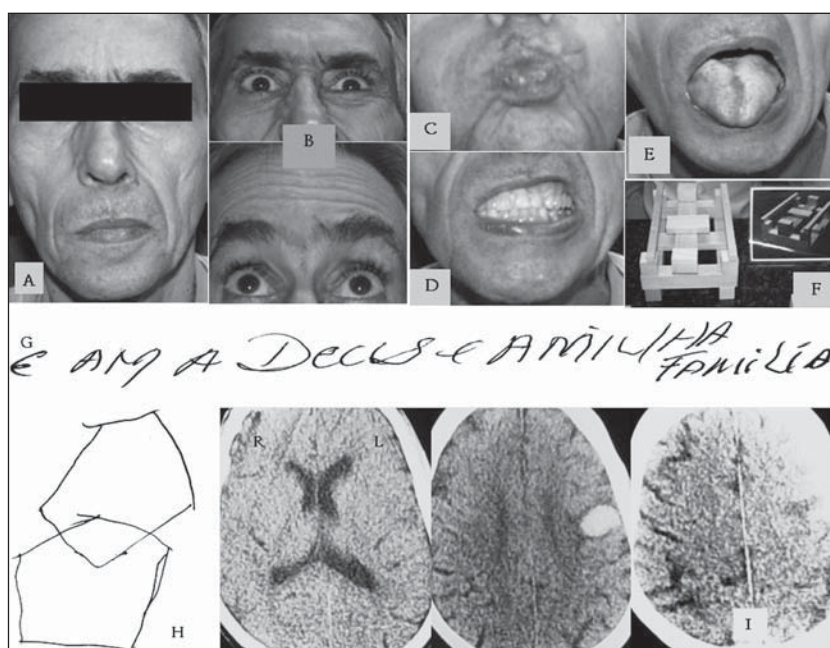


Fig 1. (A) Deviation of the lower face to the left at rest. (B) Contraction of the corrugator and frontalis muscles on verbal command. (C) Retained ability to pucker the lips contrasting with (D) the impossibility to retract or lift the right corner of the mouth. (E) Normal trophism and strength of tongue. (F) Flawless performance on the 3D Block Construction Test (the insert shows the model to be reproduced by patient). (G) A sample of spontaneous handwriting: "I love God and my family". (H) Freehand copy of intersecting pentagons. (I) Computed tomography suggestive of subcortical hemorrhage in the left posterior inferior frontal gyrus.

ticular, faciolingual praxis was preserved, *provided he would not attempt to speak*. The clinical manifestations of this case represent a typical instance of aphemia as described by Broca on patient Lelong<sup>2</sup>. Thus defined, aphemia must be differentiated from a host of conditions that compromise fluent speech. At the outset we would like to emphasize that, since our patient could still produce vocal sounds, we did not consider him to be "mute", a term that usually implies an inability to produce articulation *and* voice. The facial deviation could lead to an erroneous impression of *Bell's palsy*, which was discarded by the disproportional affection of speech, the bilateral preservation of spontaneous blinking and the ability to close the eyes. *Suprabulbar paralysis* consists of impairment of voice, articulation, lower face motility, and swallowing with preservation of trophism and reflexes in the affected territories, most often caused by multiple cerebral infarcts. The latter differentiate suprabulbar from the *bulbar paralysis* of motor neuron disease, marked by lingual and masticatory atrophy and ar-reflexia. Thus, even conceding that the dysphagia of our patient might have represented a fragment of a suprabulbar paresis at the onset of symptoms, the severe speech deficit could not be attributed to interruption of corticobulbar fascicles. A *non-fluent aphasia* was altogether discarded by the intactness of language, as defined by the ability to comprehend and express ideas and thoughts by means other than by articulated speech. Finally, the typical "misarticulatory symptoms among areas of fluent speech" described in cases of damage to the precentral gyrus of the insula<sup>7</sup> were conspicuously absent.

The lesion responsible for aphemia is typically seated in the opercular division of the inferior frontal gyrus ("Broca's area", BA 44)<sup>8</sup>. Lesions of the opercular cortex or of the short cortico-cortical fibers issuing from it lead to "true" aphemia because they impair speech without compromising language, faciolingual motility, and the ability to produce vocal sounds. This was the case in our patient and in two others reported in the recent literature<sup>9,10</sup>. In contrast, lesions of the lower precentral gyrus, where the cranial motor territories are represented, that spare the frontal operculum impair speech due to "anarthria"<sup>11</sup> [Case 2], a term that should be reserved for paralysis from interruption of corticobulbar pathways<sup>12</sup>. In practice, lesions are seldom small enough to produce pure aphemia or pure anarthria. Most often, variable combinations of aphasia, aphemia and anarthria produce complex impairments of oral language output that may be inadvertently taken as unique. A systematic

assessment of such cases will often show that they fit current concepts of the anatomical organization of the anterior language zone.

The left frontal operculum is composed of heteromodal ("association") cortex lying at the interface of language and speech. It sends short projections to the adjacent motor cortex, where the corticonuclear neurons responsible for the integration between articulation and voice are ultimately recruited. The frontal operculum contains the kinetic formula (*Bewegungsformel*) responsible for the automatic conversion of verbal language, a cognitive phenomenon, into speech, the product of the motor innervation of the articulatory muscles. The aphemia in our patient probably resulted from a lobar hematoma in the left frontal lobe. Coincidentally, aphemia in Lelong may likewise have resulted from an identical hemorrhage, both in size and in shape ("Il s'agit donc d'un *ancien foyer apoplectique*"<sup>3</sup>). Ruff and Arbit<sup>10</sup> described a 15-year-old girl who developed aphemia after evacuation of a hematoma in the left precentral gyrus and frontal operculum. To our knowledge, these are the only instances of aphemia due to intracerebral hemorrhage.

The diagnostic value of the status of faciolingual motility in the differentiation of aphemia (frontal operculum) and anarthria (lower precentral gyrus and its efferent pathways) has seldom been emphasized. Nevertheless, the relative preservation of faciolingual motility constituted the most interesting finding in our patient, as it provided a fresh insight into the mechanism of aphemia. The impairment of learned motor actions that manifests itself in certain behavioral contexts but not in others is a core feature of apraxia<sup>13,14</sup>. Conceptually, then, the aphemia of our patient represented a particular instance of apraxia, namely, an apraxia of speech. The relationship between aphemia due to injury of the left precentral gyrus of the left frontal lobe and the articulatory syndrome that results from lesion of the left precentral gyrus of the insula<sup>7</sup> remains to be determined<sup>15</sup>. The recognition of aphemia as a discrete neurobehavioral syndrome provides a natural solution for inconsistencies that have confounded aphasiology for decades. Our case also underscores the validity of Broca's apt distinction between speech ("le langage articulé" or, more simply, "la parole") and language ("la faculté générale du langage") and his contention that what was lateralized to the left hemisphere was speech only. For him, language was a non-localizable faculty that was equipotentially supported by both cerebral hemispheres<sup>16</sup>.

**Acknowledgments** – The authors are indebted to Dr. Dayse Gusmão for referral of the patient and to Professor Omar da Rosa Santos (Head of the Internal Medicine Service of HUGG) for helpful comments. Mr. José Ricardo Pinheiro and Mr. Jorge Baçal (Instituto Oswaldo Cruz Library, Rio de Janeiro) provided invaluable help in retrieving classical texts.

## REFERENCES

1. Broca P. Remarques sur le siège de la faculté du langage articulé; suivies d'une observation d'aphémie (perte de la parole). *Bull Soc Anat (Paris)* 1861;6:330-357. Translated as "Remarks on the seat of the faculty of articulated language, following an observation of aphemia (loss of speech), by Mr. Paul Broca (186)" by C. D. Green on <http://psychclassics.yorku.ca/Broca/aphemie-e.htm>. Accessed July 25, 2005.
2. Broca P. Nouvelle observation d'aphémie par une lésion de la moitié postérieure des deuxième et troisième circonvolutions frontales. *Bull Soc Anat (Paris)* 1861;6:398-407.
3. Ochipa C, Rothi LJG, Heilman KM. Ideational apraxia: a deficit in tool selection and use. *Ann Neurol* 1989;25:190-193.
4. Lezak MD. *Neuropsychological assessment*, 3.Ed. New York: Oxford, 1995.
5. Oliveira-Souza R, Ignácio FA, Cunha FC, Oliveira D LG, Moll J. The neuropsychology of executive behavior: performance of normal individuals on the Tower of London and Wisconsin Card Sorting tests. *Arq Neuropsiquiatr* 2001;59:526-531.
6. Damasio H, Damasio AR. *Lesion analysis in neuropsychology*. New York: Oxford, 1989.
7. Dronkers NF. A new brain region for coordinating speech articulation. *Nature* 1996;384:159-161.
8. Schiff HB, Alexander MP, Naeser MA, Galaburda AM. Aphemia: clinical-anatomic correlations. *Arch Neurol* 1983;40:720-727.
9. Fox RJ, Kasner SE, Chatterjee A, Chalela JA. Aphemia: an isolated disorder of articulation. *Clin Neurol Neurosurg* 2001;103:123-126.
10. Ruff RL, Arbit E. Aphemia resulting from a left frontal hematoma. *Neurology* 1981;31:353-356.
11. Tonkonogy J, Goodglass H. Language function, foot of the third frontal gyrus, and rolandic operculum. *Arch Neurol*. 1981;38:486-490.
12. Lecours AR, Lhermitte F. The "pure form" of the phonetic disintegration syndrome (pure anarthria): anatomo-clinical report of a historical case. *Brain Lang* 1976;3:88-113.
13. Liepmann H. The left hemisphere and action (1905). In: D Kimura (Ed). *Translations of Liepmann's essays on apraxia*. London, Ontario: DK Consultants, 1980:17-50.
14. Moll J, Oliveira-Souza R, Passman LJ, Cunha FC, Lima FS, Andreiuolo PA. Functional MRI correlates of real and imagined tool-use pantomimes. *Neurology* 2000;54:1331-1336.
15. Hillis AE, Work M, Barker PB, Jacobs MA, Breese EL, Maurer K. Re-examining the brain regions crucial for orchestrating speech articulation. *Brain*. 2004;127:1479-1487.
16. Berker EA, Berker AH, Smith A. Translation of Broca's 1865 report: localization of speech in the third left frontal convolution. *Arch Neurol* 1986;43:1065-1072.