

Lemierre's syndrome leading to cerebral venous thrombosis

Síndrome de Lemierre como causa de trombose venosa cerebral

Alberto R. M. Martinez¹, Carlos Roberto Martins Jr¹, Lucas N. De Resende¹, Tânia A. M. O. Cardoso¹, Fabiano Reis², Marcondes C. França Jr¹

A febrile 53-year-old man presented with a severe headache one month post-esophagectomy. Inspection highlighted inflammatory signs in the neck incision. Neurological examination was normal. Cerebrospinal fluid demonstrated increased protein levels (155 mg/dL) and mild pleocytosis (11 cells/mm³) with negative bacterial and fungi cultures. Blood cultures were positive for *Streptococcus*

mitis. Vascular imaging of the head and neck revealed a central venous thrombosis, which together with the laboratory findings, matched the characteristics of Lemierre's syndrome (Figure). Lemierre's syndrome is a thrombophlebitis of the internal jugular vein¹ commonly related to an infection². The patient had a good outcome after antibiotic and oral anticoagulant treatment.

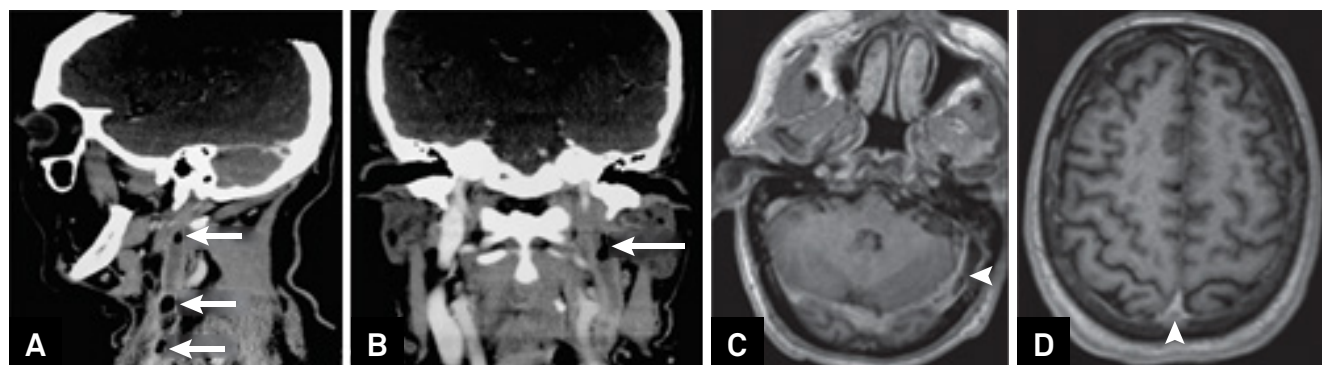


Figure. A/B: Sagittal (A) and coronal (B) contrast enhanced computed tomography of the neck revealing thickened and enhanced walls with filling defects in the left internal jugular vein (consistent with thrombosis). It is also possible to note air bubbles inside this vein (arrows). C/D: Axial T1-weighted images after contrast also showing filling defects (arrowheads) in the left transverse sinus (C) and in the superior sagittal sinus (D) compatible with cerebral venous thrombosis.

References

1. Kim BY, Yoon DY, Kim HC, Kim ES, Baek S, Lim KJ et al. Thrombophlebitis of the internal jugular vein (Lemierre syndrome): clinical and CT findings. *Acta Radiol.* 2013 Nov;54(6):622-7. <https://doi.org/10.1177/0284185113481019>
2. Farhan A, Shah YA, Ali BT, Mumtaz U, Farooq U. The forgotten disease: Lemierre's syndrome. *J Pak Med Assoc.* 2016;66(12):1652-5.

¹ Universidade de Campinas, Departamento de Neurologia, Campinas SP, Brasil;

² Universidade de Campinas, Departamento de Radiologia, Campinas SP, Brasil;

Correspondence: Marcondes Cavalcante França Jr, Departamento de Neurologia da UNICAMP; Rua Tessália Vieira de Camargo, 126; 13083-887 Campinas SP, Brasil; E-mail: mcfrancajr@uol.com.br

Conflict of interest: There is no conflict of interest to declare.

Support: Fundação de Amparo à Pesquisa do Estado de São Paulo (FAPESP) (Grant #13/01766-7 and #2014/19786-7), Coordenação de Aperfeiçoamento de Pessoal de Nível Superior (CAPES).

Received 02 January 2018; Received in final form 17 January 2018; Accepted 03 February 2018.