

Asteroid hyalosis - clinical review of 58 cases

Asteroides hialoides - revisão de 58 casos clínicos

José Nuno Vargas Galveia¹, Ana Sofia Marques Travassos², Dídia Maria Mateus Barreiros Proença², António Casanova Tavares Travassos², Rui Daniel Mateus Barreiros Proença²

ABSTRACT

Objective: Understand the behavior, functional repercussion and relationship with epidemiological factors of asteroid hyalosis (AH) and retrospective observational case series. **Methods:** Fifty-eight patients diagnosed with AH (24 women and 34 men) were studied. All patients were submitted to a thorough ophthalmological examination. **Results:** We observed a statistical association between the presence of AH and male sex ($p=0,042$). An increase in prevalence of this pathology was observed with increasing age. We determined an odds ratio of 5,24 of a patient over 50 years old having AH, when compared to patients below this threshold. Eighty-six percent of patients had unilateral vitreous deposits. We measured a lower IOP in the affected eye, with the difference being in average $2,68 \pm 1,45$ mmHg ($p=0,037$). We observed no statistical association between AH and age related macular degeneration, diabetes or glaucoma. Five eyes were submitted to facoemulsification combined with pars plana vitrectomy with an average gain of 7 lines (Snellen) in visual acuity ($p=0,03$). **Conclusion:** In our sample a clear association between AH, ageing and male sex was observed. The majority of patients had unilateral vitreous deposits. Vitrectomy in association with facoemulsification is a safe and effective intervention in this group of patients.

Keywords: Vitreous body/pathology; Eye diseases/pathology; Vitrectomy

RESUMO

Objetivo: Compreender o comportamento dos asteroides hialoides, sua repercussão funcional em relação aos fatores epidemiológicos, de modo retrospectivo e observacional de casos clínicos. **Métodos:** Cinquenta e oito doentes com diagnóstico de asteroides hialoides (24 mulheres e 34 homens) foram estudados. Todos os doentes foram submetidos a exame oftalmológico completo. **Resultados:** Observamos uma associação estatística entre a presença de asteroides hialoides e o sexo masculino ($p=0,042$). Verificamos um aumento de prevalência desta patologia com o aumento da idade sendo o risco relativo após os 50 anos de 6,25 face aos doentes abaixo desta idade. Oitenta e seis por cento dos doentes estudados apresentavam depósitos unilaterais. Não observamos associação estatística entre a presença de asteroides hialoides e a degeneração macular ligada à idade, diabetes mellitus ou glaucoma. Em 5 dos olhos estudados avaliamos o resultado funcional de cirurgia de facoemulsificação associada à vitrectomia via pars plana e observamos um ganho médio de 7 linhas de acuidade visual de Snellen ($p=0,03$) pós-cirurgia. **Conclusão:** A amostra apresenta uma clara associação entre o envelhecimento e sexo masculino e a incidência de asteroides hialoides. Na maioria dos doentes estudados os depósitos foram unilaterais. A vitrectomia via pars plana, associada à facoemulsificação é uma terapêutica segura e eficaz neste grupo de doentes.

Descritores: Corpo vítreo/patologia; Oftalmopatias/patologia; Vitrectomia

¹ Hospital de Egas Moniz – Lisbon, Portugal;

² Centro Cirúrgico de Coimbra – Coimbra, Portugal.

The work was carried out in Centro Cirúrgico de Coimbra – Coimbra, Portugal

All the patients provided informed consent. The study adhered to the tenets of the Declaration of Helsinki.

The authors declare no conflicts of interest

Recebido para publicação em 16/10/2012 - Aceito para publicação em 28/1/2013

INTRODUCTION

Asteroid hyalosis (AH) consists of spherical bodies in the vitreous cavity, appearing white under direct illumination and golden under diffuse illumination. Their distribution is at times heterogeneous, predominating inferiorly and being deposited along the collagen fibers of the vitreous body (figure 1).

Ultra structural studies with electron microscopy⁽¹⁻³⁾ and X-ray diffraction, confirmed calcium and phosphorus as the main constituents of these deposits, forming hydroxyapatite crystals.

Several publications⁽⁴⁻⁶⁾, found an association between AH and aging. Others suggested an association between AH and diabetes mellitus (DM)⁽⁷⁻⁹⁾, hypertension, dyslipidaemia and elevated serum calcium levels⁽¹⁰⁾.

AH is asymptomatic in most patients and diagnosis is mostly fortuitous in the context of a periodical ophthalmological examination. Most patients are observed regularly but no treatment is undertaken. The indications for pars plana vitrectomy (PPV) are not consensual. Some authors proposed PPV in the context of diabetic retinopathy, when laser therapy is necessary and made impossible by the vitreous deposits⁽¹¹⁾, or when the clinician believes that AH is responsible for a significant deterioration of the visual acuity^(12,13).

The present study aims to better understand this pathology, its epidemiological context in association with other ocular or systemic diseases.

METHODS

Fifty-eight patients, observed in the Centro Cirúrgico de Coimbra between 2006 and 2012 were studied retrospectively. The sample was obtained by searching our digital clinical database (available since 2006) for the diagnosis asteroid hyalosis.

Only patients with clinical diagnosis of AH and complete ophthalmological examination were included. We excluded patients with only one eye. Also excluded were eyes previously submitted to PPV outside this hospital, whenever clinical information was unavailable.

For the intraocular pressure values, only the data obtained before surgery was considered for statistical comparisons.

All the patients provided informed consent. The study adhered to the tenets of the Declaration of Helsinki. Institutional Review Board approval was obtained.

Statistical analysis was performed using JMP 8.02 (SAS institute 2009) for OSX. Statistical significance was defined as a p value inferior to 0,05.

RESULTS

The studied sample included 58 patients, 24 (41%) women and 34 (59%) men with an average age of $75,36 \pm 12,95$ years (range 37 to 95). We compared the sex distribution and age in patients studied with the general distribution in patients observed in the Centro Cirúrgico de Coimbra in the same time frame (age $60,78 \pm 20,37$ years, 53% women). We found a statistically significant association between gender and AH (χ^2 with $p=0,042$).

Age distribution revealed a right shift when compared with the normal distribution (Shapiro Wilk $p=0,004$), with an increase in the number of cases up to the 9th decade of life and decreasing in the 10th (figures 2 and 3).

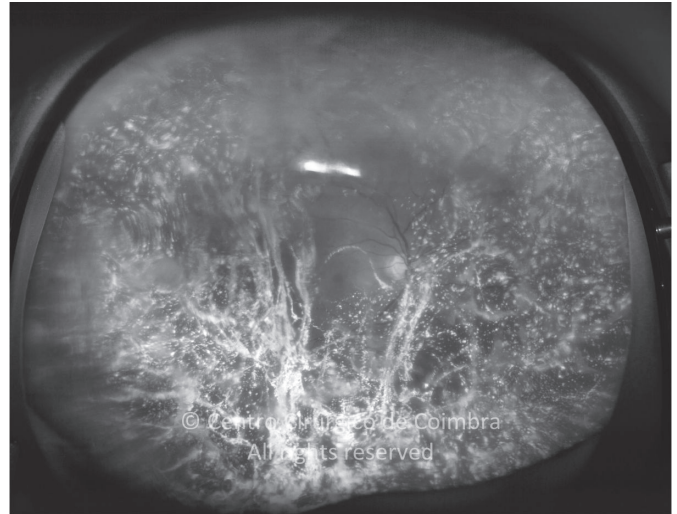


Figure 1: Ultra-wide field fundus photograph (Optomap®), showing asteroid hyalosis

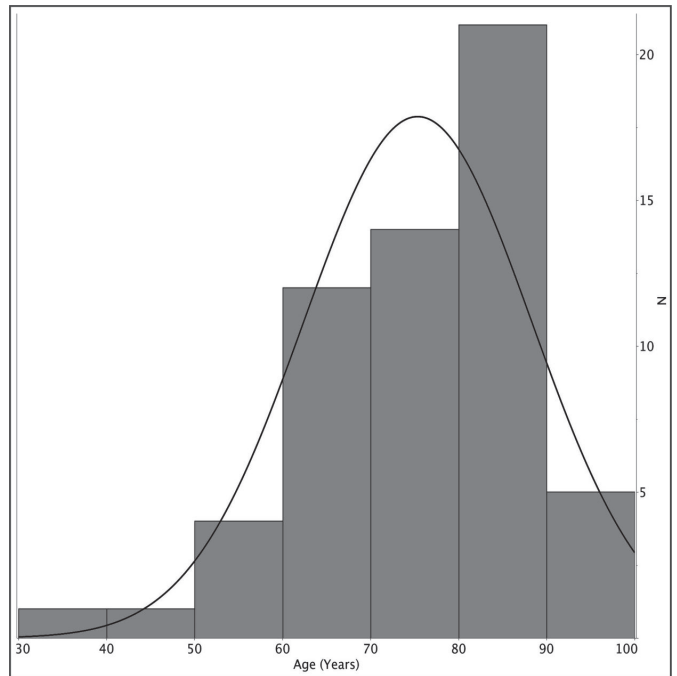


Figure 2: Histogram showing the number of patients according to decade of life

We stratified our sample in 2 groups: patients with age inferior to 50 years and the rest. We determined an odds ration of 5,24 (confidence interval 1,63 - 16,67, $p=0,002$) for the presence of AH in the second group when compared with the first. When comparing the age distribution of the studied sample with the age distribution of patients that attend the ophthalmology clinics involved in this study we found that patients with AH were in average $14,2 \pm 1,7$ years older ($p<0,001$) than the reference group.

Of the observed patients, 50 (86%) presented with unilateral pathology, while 8 (14%), had AH bilaterally. We didn't find an association between sex and the presence of unilateral or bilateral deposits (χ^2 , $p=0,19$).

Eleven patients (12 eyes) were submitted to PPV due to decreased visual acuity caused by the vitreous deposits. In the

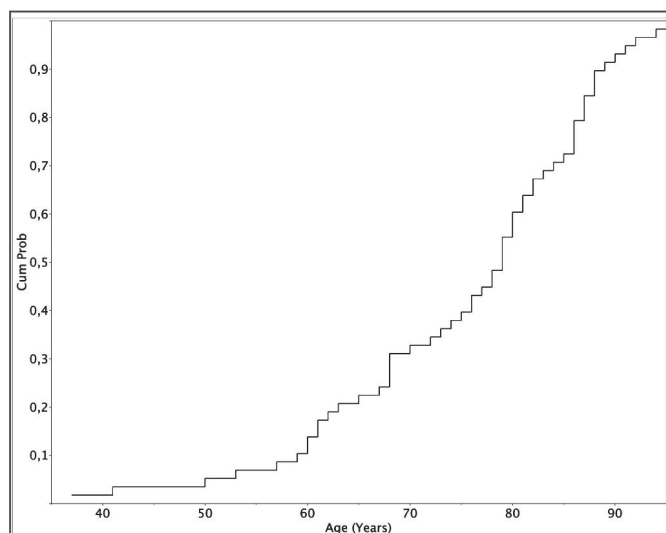


Figure 3: Probability of the presence AH as a function of age in the studied sample

functional evaluation of the surgical results, some cases were excluded: 2 eyes with associated retinal detachment, 2 eyes with epiretinal membrane, 1 eye with *retinitis pigmentosa*, 1 eye with serious glaucomatous optic neuropathy and 1 eye lost in follow-up. In the five remaining eyes, PPV and facoemulsification with intraocular lens implantation was performed. No intraoperative or postoperative complications occurred. Initial best-corrected visual acuities were $0,28 \pm 0,16$ preoperatively and $0,98 \pm 0,04$ postoperatively, with an average gain of 7 lines (Wilcoxon with $p=0,03$).

We then tried to determine the prevalence of other ocular as well as systemic pathologies in the studied sample.

In our sample, 5 patients (10%) presented with age related macular degeneration (ARMD). We compared this distribution with the prevalence of ARMD determined for the Portuguese population⁽¹⁴⁾ of 12% and didn't find a statistically significant difference (χ^2 com $p=0,66$).

Glaucoma was diagnosed in 12 patients (21%). Concerning intra-ocular pressure (IOP) values and taking into account only unilateral cases (in order to use the fellow eye as control), we observed a lower IOP in the affected eye, with the difference being in average $2,68 \pm 1,45$ mmHg (t-Student $p=0,037$) (Figure 4). When only eyes with glaucoma and unilateral AH were included, the IOP was an average of $7 \pm 4,11$ mmHg lower in the eyes with AH (t-Student $p=0,06$).

The diagnosis of *diabetes mellitus* (DM) was present in 10 patients (17,2%). We compared this distribution with the one proposed for the Portuguese population⁽¹⁵⁾ of 11,7% and found no difference ($5\text{Ø}2$ with $p=0,19$).

DISCUSSION

The presence of AH was correlated with ageing in two great previous studies.

In the Beaver Dam Study in Wisconsin⁽⁴⁾, that included 4952 patients, the prevalence of AH was 1,2%, ranging from 0,2% in the ages between 43-56 years and 2,9% for the ages between 75-86 years.

In the Blue Mountains Eye Study⁽⁵⁾, that included 3654

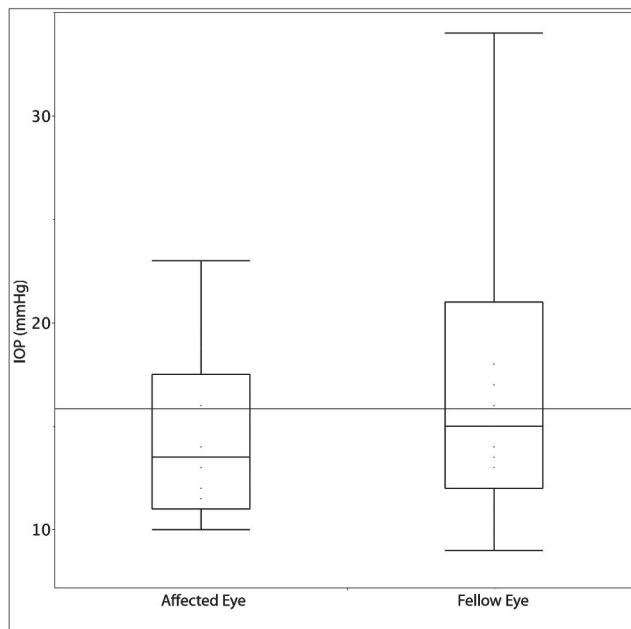


Figure 4: IOP in patients with unilateral AH, affected eye vs fellow eye

patients, the global prevalence of AH was estimated to be 1%. A relation with ageing was also observed, so that 0,2% of the individuals between 49-55 years presented with AH, versus 2,1% in the age group between 75-97 years.

In our sample we observed this association with age group. However, since our study is not a population study but a retrospective analysis of a convenience sample, our results should be interpreted cautiously. We calculated for our sample an odds ratio of 5,24 for the presence of AH in the age group above 50 years when compared to the younger age group.

The association with ageing is an attractive one. Since AH consist of calcium deposits, their accumulation may be related to degenerative processes in the vitreous humour. On the other hand, the passing years may allow a gradual build up of these deposits, which is consistent with our data.

We observed an association between sex and the presence of AH, with a higher frequency in the male sex, which is according to the published data^(4,5).

Concerning IOP values, we found a lower value in eyes with AH, being an average of 2,68 mmHg inferior to the contralateral eye. In patients with glaucoma this difference was higher - 7 mmHg in average (although not statistically significant). These findings should be interpreted cautiously since we are analysing a convenience sample, of a centre offering tertiary care.

The incidence of ARMD (10%) and DM (17,2%) in our sample does not differ significantly from the national averages for Portugal.

In the past, some published studies associated the presence of AH with DM, arterial hypertension and dyslipidaemia⁽⁷⁻⁹⁾. In our opinion and since the prevalence of AH and the other cited nosological entities increase with age, the conclusion found could have been no more than a mere statistical association. On the other hand 86% of patients studied had unilateral deposits and so it would be reasonable to weigh local ophthalmological factors as more important than systemic ones.

Of all the patients studied, 11 (19%) were submitted to PPV in the context of decreased visual acuity related to AH. This figure agrees with the literature that states that most patients

with AH are asymptomatic and the therapeutic approach should be conservative. In patients submitted to PPV in association with phacoemulsification and after excluding co-morbidities that could compromise the visual result, we observed an average gain of 7 lines in best-corrected visual acuity and observed no intraoperative or postoperative complications. Obviously, since we have no control group submitted to isolated PPV these functional results should be interpreted conservatively.

We believe that the sample studied has a dimension comparable to the largest series published. However it is a convenience sample in a centre offering tertiary care and therefore all extrapolations to the general population should be made cautiously.

CONCLUSION

In the studied sample, we observed a clear association between ageing and the incidence of AH. An association was also found with the male sex.

No statistically significant association between AH and ARMD or DM was found.

Most patients (86%) had unilateral vitreous deposits and IOP values were lower in the affected eye.

PPV combined with phacoemulsification proved to be a safe and effective therapy in selected patients.

REFERENCES

1. Winkler J, Lünsdorf H. Ultrastructure and composition of asteroid bodies. *Invest Ophthalmol Vis Sci.* 2001;42(5):902-7.
2. Miller H, Miller B, Rabinowitz H, Zonis S, Nir I. Asteroid bodies—an ultrastructural study. *Invest Ophthalmol Vis Sci.* 1983;24(1):133-6.
3. Kador PF, Wyman M. Asteroid hyalosis: pathogenesis and prospects for prevention. *Eye (Lond).* 2008;22(10):1278-85.
4. Moss SE, Klein R, Klein BE. Asteroid hyalosis in a population: the Beaver Dam eye study. *Am J Ophthalmol.* 2001;132(1):70-5.
5. Mitchell P, Wang MY, Wang JJ. Asteroid hyalosis in an older population: the Blue Mountains Eye Study. *Ophthalmic Epidemiol.* 2003;10(5):331-5.
6. Fawzi AA, Vo B, Kriwanek R, Ramkumar HL, Cha C, Carts A, et al. Asteroid hyalosis in an autopsy population: The University of California at Los Angeles (UCLA) experience. *Arch Ophthalmol.* 2005;123(4):486-90.
7. Luxenberg M, Sime D. Relationship of asteroid hyalosis to diabetes mellitus and plasma lipid levels. *Am J Ophthalmol.* 1969;67(3):406-13.
8. Bergren RL, Brown GC, Duker JS. Prevalence and association of asteroid hyalosis with systemic diseases. *Am J Ophthalmol.* 1991;111(3):289-93.
9. Bard LA. Asteroid hyalitis: relationship to diabetes and hypercholesterolemia. *Am J Ophthalmol.* 1964;58:239-42.
10. Jervey ED, Anderson WB Jr. Asteroid hyalitis: a study of serum calcium levels in affected patients. *South Med J.* 1965;58:191-4.
11. Lambrou FH Jr, Sternberg P Jr, Meredith TA, Mines J, Fine SL. Vitrectomy when asteroid hyalosis prevents laser photocoagulation. *Ophthalmic Surg.* 1989;20(2):100-2.
12. Parnes RE, Zakov ZN, Novak MA, Rice TA. Vitrectomy in patients with decreased visual acuity secondary to asteroid hyalosis. *Am J Ophthalmol.* 1998;125(5):703-4.
13. Feist RM, Morris RE, Witherspoon CD, Blair NP, Ticho BH, White MF Jr. Vitrectomy in asteroid hyalosis. *Retina.* 1990;10(3):173-7.
14. Vaz JC, Conceição L. Principais recomendações na degenerescência macular relacionada com a idade (DMRI). Portugal: Direção Geral de Saúde; 2006. Disponível em: <http://www.dgsaude.min-saude.pt/visao/OTec-DMRI.pdf>
15. Diabetes: factos e números. Relatório Anual do Observatório Nacional da Diabetes [Internet]. Portugal: 2011. [citado 2013 Jan 12]. Disponível em: http://www.insa.pt/sites/INSA/Portugues/ComInf/Noticias/Documents/2012/Marco/Relatorio Anual Diabetes_2011-2.pdf

Corresponding author:

José Nuno Vargas Galveia
Rua da Junqueira, nº 126
ZIP Code 1349-019 – Lisboa – Portugal
E-mail: Jgalveia@gmail.com