

Scleral re-fixation technique with pars plana approach for luxated haptica into the vitreous cavity in patient with keratoplasty

Técnica de refixação escleral via pars plana de háptica luxada para o vítreo em paciente com transplante de córnea

Grazielle Fialho de Souza¹, Ediberto de Magalhães², Ricardo Mitsuo Sato³, Paulo Falabella⁴

ABSTRACT

The purpose of this case report is to describe a new technique to re-establish a scleral fixation of one luxated haptic, which previous suture ruptured, causing the fall of the intraocular lens into the vitreous cavity. Considering that the patient underwent two penetrant keratoplasty surgeries, there was a major concern to cause minimal intraocular manipulation and less surgical trauma. This technique consists in a closed eye procedure using the fixation lens, without exposing the haptics or using special surgical instruments. The endothelial cell loss after the surgery was similar to that observed after phacoemulsification in eyes with penetrating keratoplasty. The technique proved to be simple, safe, and therefore reproducible, less invasive than the previously published methods and promoted the patient's early visual rehabilitation.

Keywords: Lens Subluxation; Suture technique; Corneal endothelial cell loss; Corneal transplantation; Case reports

RESUMO

O objetivo deste relato de caso é descrever uma nova técnica de refixação escleral, unilateral, de uma háptica cuja sutura escleral prévia rompeu-se, levando ao deslocamento da lente intraocular para o vítreo. Trata-se de um olho submetido anteriormente a dois transplantes de córnea, em que se buscou minimizar a manipulação intraocular e o trauma cirúrgico. Esta técnica consiste em realizar o procedimento em olho fechado, utilizando a mesma lente de fixação, sem a necessidade de externalizar as hápticas ou do uso de instrumentos cirúrgicos especiais. A perda de células endoteliais após o procedimento foi similar à observada após a facoemulsificação em pacientes com ceratoplastia penetrante. A técnica mostrou-se simples, segura, e, portanto, reproduzível, além de ser menos invasiva do que os métodos já descritos, permitindo a reabilitação visual precoce do paciente.

Descritores: Subluxação do cristalino; Técnicas de sutura; Perda de célula endoteliais da córnea; Transplante de córnea; Relatos de casos

¹3rd-year Resident in Ophthalmology, Tadeu Cvintal Ophthalmology Institute, São Paulo/SP, Brazil.

²Ophthalmologist, Retina and Vitreous Unit, Tadeu Cvintal Ophthalmology Institute, São Paulo/SP, Brazil.

³Ophthalmologist, Retina and Vitreous Unit, Tadeu Cvintal Ophthalmology Institute, São Paulo/SP, Brazil.

⁴Ophthalmologist, 2nd year fellow, Retina and Vitreous Unit, Tadeu Cvintal Ophthalmology Institute, São Paulo/SP, Brazil.

Work conducted at the Tadeu Cvintal Ophthalmology Institute, São Paulo/SP, Brazil.

The authors declare no conflicts of interest

Received for publication: 23/5/2011 - Accepted for publication: 15/9/2011

INTRODUCTION

Fixation of an intraocular lens (IOL) in the posterior chamber is a common indication for cases where there is no support in the posterior capsule or ciliary sulcus for IOL implantation after phakectomy. In some cases, the fixated IOL can suffer inclination and decentration caused by the dislocation of a haptic due to suture erosion or dialysis^(1,2). IOL dislocation usually requires surgical intervention due to potential secondary complications, such as retinal tears, rhegmatogenous retinal detachment, and vitreous haemorrhage^(3,4).

The incidence of IOL dislocation requiring reoperation after phacoemulsification is approximately 1%⁽³⁾. Kim et al. conducted a retrospective study on 277 patients who underwent surgery due to IOL dislocation following cataract surgery. They found that in 38% of cases, IOL repositioning did not require fixation; in 39% the IOL was repositioned with scleral fixation; in 17% the IOL was exchanged; IOL explantation leading to aphakia was performed in 2% of cases; and other techniques were used in 4% of cases⁽⁴⁾.

IOL explantation involves the risk of vitreous prolapse, retinal trauma, collapse of ocular structures, intraocular haemorrhage, cystoid macular oedema, and loss of corneal endothelial cells. Repositioning an IOL using a closed-eye technique is a good alternative, due to its lower risk of complications secondary to intraocular manipulation^(4,6).

The aim of this case report is to describe a new technique for scleral refixation through the pars plana in a patient whose previous scleral suture of one of the haptics was ruptured, leading to the dislocation of the IOL into the vitreous cavity. This eye had been previously subjected to two corneal transplants; therefore, we sought to minimise surgical trauma and intraocular manipulation without the need for any special surgical instruments.

Case report

IOC, a male, 17-year-old student born and living in São Paulo, Brazil, had keratoconus. He was submitted to penetrating keratoplasty in the right eye (RE) and, 4 years later, to phacoemulsification with IOL implantation in the RE due to posterior subcapsular cataract.

The IOL suffered decentration 10 days after surgery, although no intraoperative complications occurred during the phacoemulsification. A new procedure was performed to reposition the IOL. However, due to IOL instability and vitreous loss during surgery, it was decided to explant the IOL.

The patient suffered decompensation of the transplantation and was therefore subjected to a second penetrating keratoplasty combined with scleral fixation of the IOL at the 6 and 12 o'clock positions.

The patient complained of low visual acuity 20 days after the procedure. On examination, the superior haptic of the IOL was found to be dislocated into the vitreous cavity; the fixation suture (10-0 prolene) was ruptured and attached to the haptic. Corrected visual acuity (CVA) was 20/50. Initially we opted for expectant management; however, the dislocation progressed, therefore we opted for surgery after 10 months of follow-up. Specular microscopy showed 1760 cells/mm³.

In order to protect the endothelium of the transplanted cornea, a new approach was developed to refixate the dislocated haptic with minimal intraocular manipulation. We used the Magalhães fixation technique through the pars plana, described below, which consists of a closed-eye procedure using the

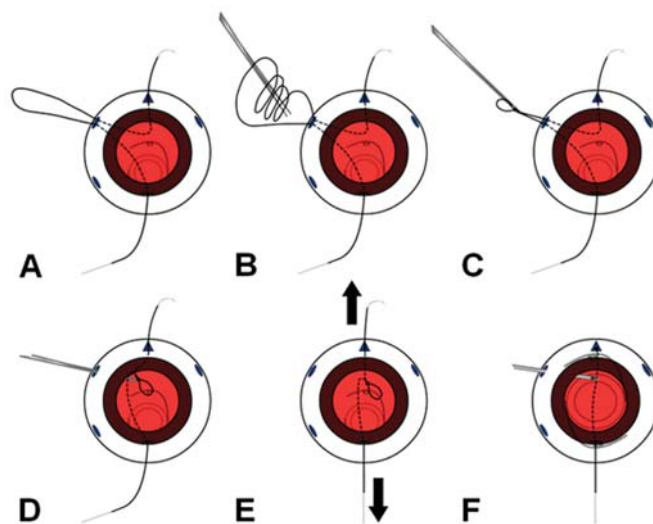


Figure 1 A, Capture and externalisation of the 10-0 prolene suture; B and C, Tying the loop; D, Capturing the free haptic with the loop; E, Tying a knot on the inner part of the haptic; F, Lysis of the lower end of the prolene suture with a vitreotome

previously-implanted IOL.

By the 7th postoperative month, the IOL was centred, the cornea was clear, CAV was 20/20, and specular microscopy of the cornea showed 1452 cells/mm³, corresponding to a 17.5% loss of endothelial cells.

Description of the technique

1. Inferior temporal sclerotomy 3.5 mm from the limbus with introduction and fixation of infusion with a 7-0 vicrylTM suture;
2. Scleral flap at the 12 o'clock position;
3. Two superior sclerotomies 3.5 mm from the limbus, positioned at the 2 and 10 o'clock positions;
4. Pars plana vitrectomy (20-gauge system) with full release of the vitreous gel from the dislocated IOL haptic and body;
5. Infusion of perfluorocarbon in the posterior pole to protect the retina from any contact in case of complete dislocation of the IOL;
6. Passing the needle of a 10-0 prolene suture 1 mm from the limbus (12 o'clock position) under the scleral flap, reaching the opposite end (6 o'clock) and externalising it in the margin of the recipient cornea;
7. Capture and externalization of the prolene suture through the superior sclerotomy using a vitreoretinal microforceps (Figure 1A);
8. Tying three loops over the externalised suture (Figures 1B and 1C);
9. Reintroducing the suture using the microforceps to tie the haptic in the part internal to the orifice (Figure 1D);
10. Pulling the two ends of the prolene suture (12 and 6 o'clock) simultaneously, observing the formation of a knot on the haptic (Figure 1E);
11. Suturing the upper end of the suture in the superior scleral bed;
12. Lysis of the lower end of the prolene suture in the vitreous cavity with a vitreotome (Figure 1F) and removing it through the cornea.

13. Removing the perfluorocarbon using a backflush cannula with a silicone tip.

14. Suturing the scleral flap, the sclerotomies, and the conjunctiva.

DISCUSSION

The alternatives for managing the dislocation of a posterior chamber IOL include explanting and exchanging the IOL, externalising the haptics, and fixation in the ciliary sulcus or the pars plana^(1,5,7-10). Fixation in the ciliary sulcus is associated with the risk of intraocular haemorrhage, postoperative retinal detachment⁽¹¹⁾, and postoperative myopia⁽¹²⁾. Some studies suggest that fixation in the pars plana could reduce the incidence of these complications⁽¹³⁾, but it is unclear which of the two techniques is more stable in the long term.

Several studies have described closed-eye techniques for trans-scleral fixation to correct IOL dislocation^(1,5-9,14-18). However, many of these methods are technically complex, require special instruments, and may even increase the risk of complications⁽¹⁾.

Insler, Manie and Peyman⁽¹⁴⁾; Kokame, Yamamoto and Mandel⁽¹⁵⁾; and Nikeghbali and Falavarjani⁽¹⁶⁾ described closed-eye fixation techniques involving haptic externalisation — the former through the pars plana, and the latter two using clear cornea incisions. Most authors describe fixation in the scleral wall^(8,9) or the ciliary sulcus⁽¹⁸⁾.

Little et al. developed an instrument to tie a 9-0 prolene suture specifically adapted for closed-eye trans-scleral fixation of posteriorly dislocated IOLs⁽¹⁷⁾.

The technique described by Han, Hui and Wang consists of tying a double-loop knot with a prolene suture around the haptic of the dislocated IOL to stabilise it. With the help of a hook, this knot can be placed in an appropriate part of the haptic. Two clear cornea incisions are needed to allow manipulation of the IOL and the needle, and a triangular scleral flap is created 1 mm posterior to the limbus for fixation⁽¹⁾.

Nakashizuka et al. described a technique for fixation in the pars plana which was used in 3 patients. The sclerotomies were made 3 mm from the limbus using different sites for vitrectomy and fixation. A cow hitch knot with 10-0 prolene suture was used for fixation. A vitreoretinal forceps was used to attach the suture to the IOL haptic. The loop was then pulled toward the sclerotomy. The same procedure was used for the other haptic, and both sutures were fixated under the scleral flaps⁽⁵⁾.

In most cases of IOL dislocation, the vitreous is present in the anterior chamber surrounding the haptic. Anterior vitrectomy can be performed through the corneal incision to remove the vitreous prolapse or through the pars plana^(1,3,5,8). In procedures requiring delicate handling near the retina, perfluorocarbon can be used to create a space between the IOL and the retina, reducing the risk of contact with the retina⁽⁵⁾.

The loss of corneal endothelial cells after fixation of the IOL is reported to be between 7.84% and 11.7%^(19,20), but there are no studies assessing endothelial cell loss in transplanted corneas. In the absence of other factors that accelerate endothelial cell loss, such as surgery, expected cell loss in the graft is known to vary between 3.5% and 7% per year in the first two years; from years 3 to 5, cell loss is 7.8% per year; and from years 5 to 10 it is about 4.2% per year^(21,22). Kim and Kim⁽²³⁾ assessed endothelial cell counts after phacoemulsification with IOL implantation in 49 patients with previous penetrating

keratoplasty (50 eyes) (PK-CAT group) and 65 patients not submitted to corneal transplantation (100 eyes) (CAT group) and found a significantly higher loss of endothelial cells in transplanted patients. One month after cataract surgery, the density of endothelial cells decreased by 19.03% in the PK-CAT group and 7.91% in the CAT group, and after 24 months the loss was 58.10% and 14.98%, respectively. In the case reported here, endothelial cell counts by specular microscopy decreased from 1760 cells/mm² preoperatively to 1452 cells/mm² 7 months after surgical fixation of the IOL, corresponding a loss of 17.5%.

Leão e Sousa compared the post-operative results of triple surgery and corneal transplantation with secondary trans-scleral IOL fixation. They reported a 50% increase in intra-ocular pressure (IOP) in patients who had undergone previous surgery with vitreous loss⁽²⁴⁾. No change in IOP was observed in our patient during postoperative follow-up.

In the technique described here, we chose not to perform IOL explantation, externalisation of the haptic, or any other intervention through the anterior chamber in order to minimise intraocular manipulation to preserve the integrity of the transplanted cornea. The procedure was simple, safe, and therefore reproducible, with early visual rehabilitation.

REFERENCES

- Han QH, Wang L, Hui YN. Transscleral suture technique for fixation of a dislocated posterior chamber intraocular lens. *J Cataract Refract Surg.* 2004;30(7):1396-400.
- Lee SC, Chen FK, Tseng SH, Cheng HC. Repositioning a subluxated sutured intraocular lens in a vitrectomized eye. *J Cataract Refract Surg.* 2000;26(11):1577-80.
- Mönestam EI. Incidence of dislocation of intraocular lenses and pseudophakodonesis 10 years after cataract surgery. *Ophthalmology.* 2009;116(12):2315-20.
- Kim SS, Smiddy WE, Feuer W, Shi W. Management of dislocated intraocular lenses. *Ophthalmology.* 2008;115(10):1699-704.
- Nakashizuka H, Shimada H, Iwasaki Y, Matsumoto Y, Sato Y. Pars plana suture fixation for intraocular lenses dislocated into the vitreous cavity using a closed-eye cow-hitch technique. *J Cataract Refract Surg.* 2004;30(2):302-6.
- Mensiz E, Aytulun E, Ozerturk Y. Scleral fixation suture technique without lens removal for posteriorly dislocated intraocular lenses. *Can J Ophthalmol.* 2002;37(5):290-4.
- Chan CK, Agarwal A, Agarwal S, Agarwal A. Management of dislocated intraocular implants. *Ophthalmol Clin North Am.* 2001;14(4):681-93.
- Smiddy WE, Flynn HW Jr. Management of dislocated posterior chamber intraocular lenses. *Ophthalmology.* 1991;98(6):889-94.
- Johnson MW, Schneiderman TE. Surgical management of posteriorly dislocated silicone plate intraocular lenses. *Curr Opin Ophthalmol.* 1998;9(3):11-5. Review.
- Nehemy MB, Vale MB, Reis FV. Tratamento de luxação de lente intraocular de câmara posterior. *Rev Bras Oftalmol.* 1997;56(12):919-24.
- Bellucci R, Pucci B, Morselli S, Bonomi L. Secondary implantation of angle-supported anterior chamber and scleral-fixated posterior chamber intraocular lenses. *J Cataract Refract Surg.* 1996;22(2):247-52.
- Hayashi K, Hayashi H, Nakao F, Hayashi F. Intraocular lens tilt and decentration, anterior chamber depth, and refractive error after trans-scleral suture fixation surgery. *Ophthalmology.* 1999;106(5):878-82.
- Teichmann KD. Transscleral suture fixation of posterior chamber lenses at the pars plana. *J Cataract Refract Surg.* 1994;20(4):475-7. Comment in *J Cataract Refract Surg.* 2000;26(8):1102-3.
- Insler MS, Mani H, Peyman GA. A new surgical technique for dislocated posterior chamber intraocular lenses. *Ophthalmic Surg.* 1988;19(7):480-1.

15. Kokame GT, Yamamoto I, Mandel H. Scleral fixation of dislocated posterior chamber intraocular lenses: Temporary haptic externalization through a clear corneal incision. *J Cataract Refract Surg.* 2004;30(5):1049-56.
16. Nikeghbali A, Falavarjani KG. Modified transscleral fixation technique for refixation of dislocated intraocular lenses. *J Cataract Refract Surg.* 2008;34(5):743-8.
17. Little BC, Rosen PH, Orr G, Aylward GW. Trans-scleral fixation of dislocated posterior chamber intraocular lenses using a 9/0 microsurgical polypropylene snare. *Eye (Lond).* 1993;7(Pt 6):740-3.
18. Ma KT, Kang SY, Shin JY, Kim NR, Seong GJ, Kim CY. Modified Sieser sliding knot technique for scleral fixation of subluxated posterior chamber intraocular lens. *J Cataract Refract Surg.* 2010;36(1):6-8.
19. Oshima Y, Oida H, Emi K. Transscleral fixation of acrylic intraocular lenses in the absence of capsular support through 3.5 mm self-sealing incisions. *J Cataract Refract Surg.* 1998;24(9):1223-9.
20. Lee JH, Oh SY. Corneal endothelial cell loss from suture fixation of a posterior chamber intraocular lens. *J Cataract Refract Surg.* 1997;23(7):1020-2.
21. Bourne WM, Hodge DO, Nelson LR. Corneal endothelium five years after transplantation. *Am J Ophthalmol.* 1994;118(2):185-96.
22. Ing JJ, Ing HH, Nelson LR, Hodge DO, Bourne WM. Ten-year postoperative results of penetrating keratoplasty. *Ophthalmology.* 1998;105(10):1855-65.
23. Kim EC, Kim MS. A comparison of endothelial cell loss after phacoemulsification in penetrating keratoplasty patients and normal patients. *Cornea.* 2010;29(5):510-5.
24. Leão DMP, Sousa LB. Comparação entre os resultados pós-operatórios de pacientes submetidos ao procedimento tríplice e transplante de córnea combinado a fixação secundária de lente intra-ocular. *Arq Bras Oftalmol.* 2006;69(4):497-502.

Corresponding author:

Grazielle Fialho de Souza
Rua Ribeiro do Amaral, nº 366 - Bairro Ipiranga
CEP 04268-000, São Paulo (SP), Brazil
Fax: (11) 2215-6007
Email: grazifi@gmail.com