

Morphological, comparative and qualitative tissue reaction analysis due to the implantation of alloplant™ to the eyelid and subcutaneous of rabbits

Análise morfológica comparativa e qualitativa da reação tecidual à colocação do alloplant™ (aloimplante) em pálpebra e dorso de coelhos

Carmen Silvia Bongiovanni de Miranda Gonçalves¹, Moacyr Pezati Rigueiro¹, Marinho Jorge Scarpi¹

ABSTRACT

Purpose: To compare by optical microscopy, tissue reaction caused by the Alloplant™ to conjunctiva and backs of 24 rabbits. **Methods:** All rabbits underwent implantation of Alloplant™ on the inner third of the lower eyelid, replacing the tarsal conjunctiva of one eye. After thirty days six rabbits (Group I) were sacrificed and lower eyelids of both sides and a back fragment (control) routed to optical microscopy. After sixty days six rabbits (group II) were sacrificed and their eyelids and a back fragment (control) sent for microscopic examination. That day were also performed surgical implantation of Alloplant™ on the back of the twelve remaining rabbits. They were sacrificed ninety days (group III) and one hundred and twenty days (group IV) after the first surgery of the eyelids and microscopic study backs. **Results:** The “Alloplant™” (aloimplante), caused an intense inflammatory reaction, mixed exudative and proliferative with a predominance of lymphocytes, macrophages and formation of foreign body granulomas in both locations, which evolved with the replacement of the implant by dense fibrous connective tissue. **Conclusion:** eyelid inflammatory reaction was more intense and more prolonged in the eyelid than in the back. In the back the formation of fibrosis was more intense, what is not suitable for eyelid surgery.

Keywords: Experimental implants; Histology; Eyelids; Ambulatory surgical procedures; Microscopy; Rabbits

RESUMO

Objetivo: Analisar comparativamente através da microscopia óptica, a reação tecidual causada pelo Alloplant Ô na conjuntiva e dorso de 24 coelhos. **Métodos:** Todos os coelhos foram submetidos a implantação do Alloplant Ô no terço interno da pálpebra inferior, em substituição à conjuntiva tarsal de um dos olhos. Após trinta dias seis coelhos (grupo I) foram sacrificados e as pálpebras inferiores dos dois lados e um fragmento do dorso (controle) foram encaminhados para a microscopia óptica. Após sessenta dias foram sacrificados mais seis coelhos (grupo II) e suas pálpebras um fragmento do dorso (controle) foram encaminhados para estudo microscópico. Nesse dia também foram realizadas implantações cirúrgicas do aloimplante Ô no dorso dos doze coelhos restantes, os quais foram sacrificados noventa (grupo III) e cento e vinte (grupo IV) dias após a primeira cirurgia para estudo microscópico das pálpebras e dorsos. **Resultados:** O “Alloplant Ô” (aloimplante), causou intensa reação inflamatória mista exsudativa e proliferativa com predominância de linfócitos, macrófagos e formação de granulomas de corpo estranho nas duas localizações, que evoluiu com a substituição do implante por tecido conjuntivo fibroso denso. **Conclusão:** na pálpebra a reação inflamatória foi mais intensa e mais prolongada do que no dorso e no dorso a formação de fibrose foi mais intensa, mostrando inadequação ao uso cirúrgico.

Descritores: Implantes experimentais; Histologia; Pálpebras; Procedimentos cirúrgicos ambulatoriais; Microscopia; Coelhos

¹ Universidade Federal de São Paulo, São Paulo, SP, Brazil.

Thesis approved by the Sciences / Ophthalmology Department, Universidade Federal de São Paulo, São Paulo, SP, Brazil(1998).

The authors declare no conflicts of interest

Received for publication 09/02/2015 - Accepted for publication 02/04/2015

INTRODUCTION

The goals in eyelid reconstruction include protection of the eyeball, restoring motility and appropriate cosmetic resolution (1).

Surgical procedures commonly used to construct the anterior lamella of the eyelid are free skin graft and microcutaneous flaps (2). For the posterior eyelid lamella reconstruction other techniques are: sliding tarso conjunctival flaps, free tarsal grafts, nasal cartilage, auricular cartilage, hard palate, preserved sclera and the "AlloDerm™" among others (3-8).

In 1976 Muldashev, Kamelieva and Vasilieva, proposed the use of an allograft, with very similar characteristics to the human tarsus, extracted from fascia, tendons, fat and plantar region of human cadavers, as another option for the reconstruction of the eyelid. According to these authors, the material "Alloplant™" (allograft) was well incorporated into the host, with a quickly epithelization, stimulating the regeneration of the local tissue and could be used in different surgical procedures besides oculo plastics. (9-14).

The aim of this study was to comparatively analyze the tissue reaction caused by implantation of "Alloplant™" (Figure 1A and 1B) in the eyelid and backs of rabbits, by light microscopy with qualitative and semi-quantitative analysis.

METHODS

The experimental study was performed in 1997. Twenty four rabbits were divided into four groups (I, II, III and IV) of six rabbits each and two surgical modalities: surgery with implantation in the eyelid of all rabbits and surgery with implantation in the back of 12 rabbits.

For a better understanding the study was divided into five times as follows (Table 1):

Experimental time zero: 24 rabbits underwent surgery with implantation on the lower eyelid of one side, chosen randomly at the time of surgery.

Experimental time one: (30th day after eyelid surgery), 6 rabbits in group I were sacrificed and lower eyelid and fragments of the back (control) were sent to histopathological study.

Experimental time two: (60th day after eyelid surgery), 6 rabbits in group II were sacrificed, lower eyelids and one fragment of the back (control), were sent to histopathological study. At this experimental time the surgery with implantation in the back of the rabbits in groups III and IV were performed.

Experimental time three: (90th day after eyelid surgery), 6 rabbits in group III were sacrificed, lower eyelids and fragments of the back (30th day after dorsal surgery) were sent to histopathological study.

Experimental time four: (120th days after eyelid surgery), 6 rabbits of group IV were sacrificed, lower eyelids and fragments of the back (60th day after dorsal surgery) were sent to histopathological study.

These animals were kept in individual appropriate cages and suitable environmental conditions (DPC Laboratory Medlab - São Paulo - Brazil) during the pre and postoperative times. The postoperative ocular health of each rabbit was followed up by clinical examination with drops of fluorescein and cobalt blue filter flash light, for corneal examination at the surgical site on the first, seventh, fifteenth and thirtieth postoperative day of the eyelid surgery.

The back was assessed in the first and seventh postoperative when the 6-0 mono nylon sutures were removed.

Table 1

Twenty four rabbits were divided into four groups (I, II, III and IV) of six rabbits each and two surgical modalities: surgery with implantation in the eyelid of all rabbits and surgery with implantation in the back of 12 rabbits.

	Group I	Group II	Group III	Group IV
Time 0	eyelid surgery	eyelid surgery	eyelid surgery	eyelid surgery
Time 1	sacrificed	waited	waited	waited
Time 2	extint	sacrificed	back surgery	back surgery
Time 3	extint	extint	sacrificed	waited
Time 4	extint	extint	extint	sacrificed

Surgical techniques

Each rabbit was placed separately in a suitable location for containment and anesthetized with intravenous injection of sodium pentobarbital at a dose of 33mg/kg and one drop of proparacaine 0.5% instilled in the lower conjunctival fornix for **lower eyelids surgery**, where a fragment of approximately 5x7mm of the middle third tarsal conjunctiva was resected (Figure 1C) and in its place it was sutured a similar fragment of the allograft with interrupted 6-0 Vycril sutures.

For **surgery in the back** it was used 2% lidocaine with 1:200,000 epinephrine injected into the subcutaneous before the

introduction of an implant fragment with approximately 0,5 X 1,0cm (Figure 1D). The incision on the back was sutured with interrupted 6-0 mononylon.

Collection of tissue

The lower eyelids and backs were taken from all rabbits of the study when they were sacrificed, and the non-operated eyelids and backs were considered controls.

Histological examination of the eyelids

All specimens, including a fragment of Alloplant were fixed

in 10% formalin, submitted to histological examination, stained with Hematoxylin - Eosin (HE) and Masson's Trichromium (TM) (15). Received coded identification numbers, so that the pathologist had no information on the time elapsed between the graft and biopsy (double blind). The research was conducted at DPC MEDLAB PRODUTOS DIAGNÓSTICOS, at São Paulo, Brazil.

The scores were given for the presence of inflammation: 0 = no inflammatory reaction; 1 = mild inflammation; 2 = moderate inflammatory reaction; 3 = severe inflammatory reaction.

Statistical analysis

For statistical analysis Wilcoxon tests were applied; Analysis of Variance points by Kruskal -Wallis and the Fisher exact test was set at 0.05 or 5% ($\alpha < 0.05$) the level of rejection of the null hypothesis, indicating with an asterisk a significant values outcomes.

RESULTS

Regarding the ocular health of the rabbits it was observed in the early day slight to moderate punctate keratitis on the lower third of the operated side cornea which decreased significantly on the seventh day disappearing completely altogether in the fifteenth postoperative.

Histology of the "Alloplant™": Presence of dense fibrous connective tissue fibers permeating blood vessels, fat and rare glandular connective tissue, similar to humans sweat glands (eccrine) epithelial structures (Figure 1B).

Histologic controls

Eyelid Controls: the cross-section showed up: skin, orbicularis, tarsal plate permeated by Meibomian gland covered by cylindrical conjunctival epithelium, very similar to human eyelid (Figures 2A and B).

Backs Controls (group I and II): no abnormalities (Figures 2C and D)

Histology of the Backs

On the 30th postoperative day (group III), moderate chronic mixed inflammatory process, with presence of foreign body granulomas, mostly lymphocytes and macrophages and severe fibrosis (Figure 3A and B).

On the 60th postoperative day (group IV) discrete chronic mixed inflammation and intense fibrosis in all cases (Figure 3C and D).

Histologic of the eyelids

On the 30th postoperative day (group I), an intense mixed, proliferative and exudative inflammatory reaction, with a predominance of lymphocytes and macrophages, the presence of foreign body granulomas, dissociation of collagen fibers of the implant within macrophages in all the pieces. The conjunctiva was completely reepithelialized with squamous epithelium with stratified non-keratinized "metaplasia" (Figure 4A and B).

On the 60th postoperative day (group II), a persistence of intense mixed inflammatory process and the beginning of fibrosis formation (Figure 4C and D).

On the 90th postoperative day (group III) chronic mixed inflammatory process starts to decrease and increases the fibrosis formation (Figure 4E and F).

On the 120th postoperatively day (group IV): persistence of chronic mixed inflammatory process and moderate degrees of fibrosis formation (Figure 4G and H).

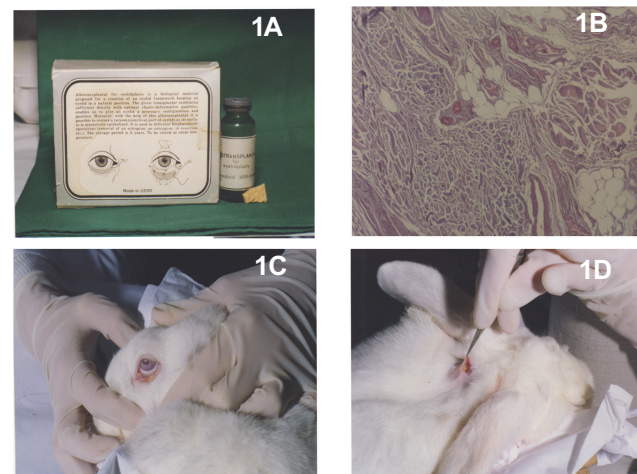


Figure 1: The aim of this study was to comparatively analyze the tissue reaction caused by implantation of "Alloplant™" in the eyelid and backs of rabbits, by light microscopy with qualitative and semi-quantitative analysis.

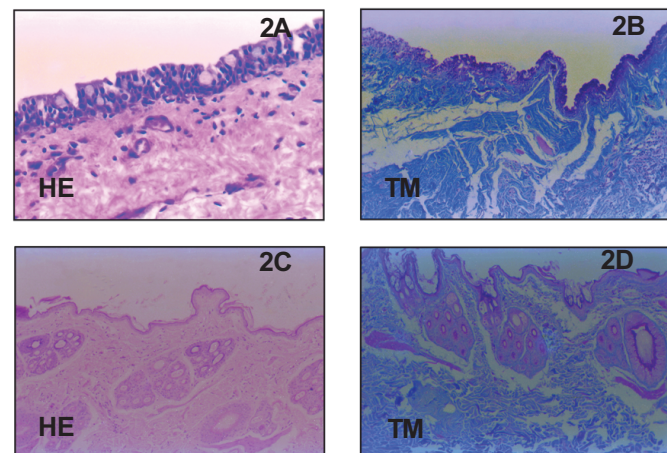


Figure 2: Eyelid controls (2A e 2B) e Back controls (2C e 2D)

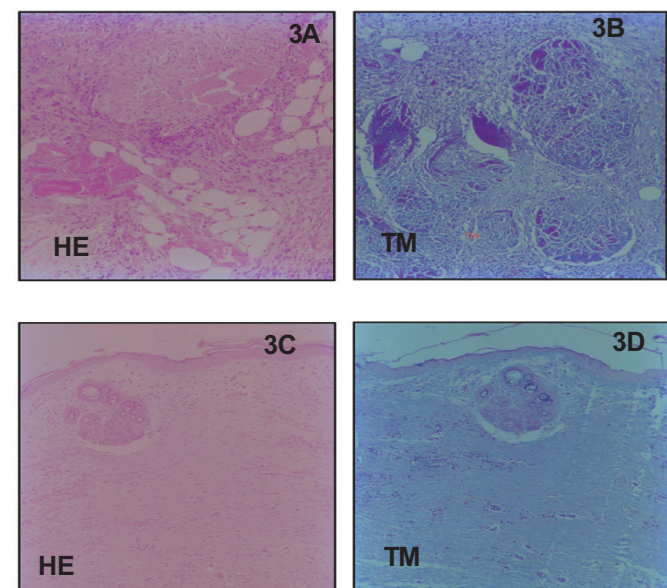


Figure 3: Histology of back 30th PO (3A e 3B) e 60th PO (3C e 3D)

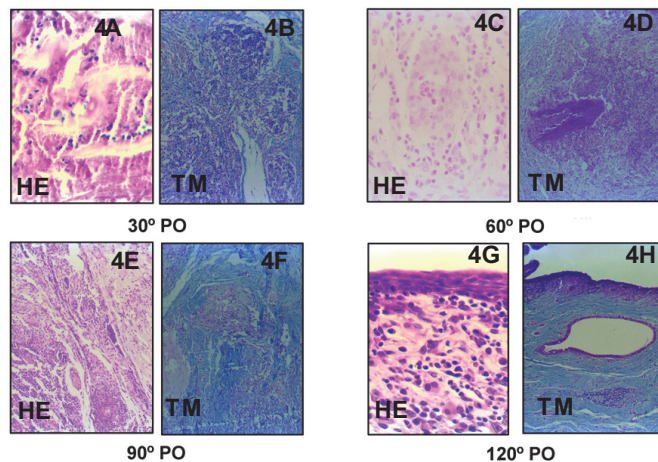


Figure 4: Histologic of the eyelids 30th PO (4A e 4B), 60th PO (4C e 4D), 90th PO (4E e 4F) e 120th PO (4G e 4H)

DISCUSSION

Despite numerous published surgical options, depending on the extent and location of the eyelid defect, using an implant would eliminate the morbidity of the donor site and the lack of adequate amounts of tissue for reconstruction (2).

Among several implant possibilities, "Alloplant™" was chosen, and according to the authors (10) was a material taken from tendons, fascias and plantar region of human cadavers, with similar consistency to the human tarsus and easy handling, allowing its use as a natural tissue regeneration stimulator in any part of the human body (12).

As the literature about "Alloplant™" was scarce and not clarifying, it was decided to put an experimental study that could demonstrate the histological changes at the site of implantation.

The choice of the rabbit as experimental animals was due to the fact that the rabbit eyelid exhibits major histological similarities with human eyelid, and they are docile and easy handling animals.

The implant was placed in the middle third of the lower eyelid in direct contact with the anterior ocular surface (Figure 1C) without conjunctival covering, which allowed the assessment of repair of the conjunctiva at the site and also the traumatic changes caused to the cornea. As occurred in the experimental study of Jordan et al. (6) who use irradiated human tarsal implant in the lower eyelids of monkey in direct contact with the cornea, light superficial punctate keratitis was observed in the first day after surgery, neither of which cases progressed to persistent epithelial defect and corneal ulceration. Histologically, the conjunctiva of the site was completely healed 30 day post operatively.

Tissue was treated with Hematoxylin-Eosin (HE) and also Masson's Tricromium (TM), this last one revealed to be the best coloration to better disclosure of collagen fibers. (15)

The histological inflammatory reaction observed was much more intense and persistent in the eyelid than in the back, possibly because in the back the implant was protected from the external environment, facilitating phagocytosis and hence speed of fibrosis formation, but in both locations the implant caused the same type of reaction: mixed exudative and proliferative inflammatory, with predominance of lymphocytes, macrophages and formation of

foreign body granuloma (Figure 3 C). These findings are very similar to those reported by Muldashev et al. (9), who observed that in the first weeks after surgery there was a major inflammatory reaction with proliferation of fibroblasts "Alloplant™" was being completely reabsorbed and replaced by host tissue growth, but only in the later postoperative (14).

The number of lids was higher than the backs because the back allowed us to assess the antigenicity of the implant, that is, if the rabbits would have previously been sensitized during the eyelid surgery, as demonstrated in the experimental study with preserved duramater by Dias et al. (16).

Russian researchers, with the aid of histochemical electron microscopy, found that inflammatory immune response decreases considerably with the extraction of glycosaminoglycans collagen fibers molecules from the all oimplant which inhibits the migration of lymphocytes, reducing the infiltration of macrophages and fibroblasts by increasing the ability of natural regeneration of normal tissue of adjacent areas. (12,13). The understanding of this process was acquired after this study.

The microscopic aspect observed in the corresponding area on the back implantation was very similar to the eyelid. If there had been prior sensitization at the time of the first implant (17), one would expect a cellular response triggered by the second implant, which would remove the possibility of "Alloplant™" be have as immunologically inactive substance (6,7).

Removal of glycosaminoglycans from collagen fibers of different tissues (fascia, tendons and connective tissue) contributes to this type of implant present low immunological properties (12,13). Thus it could be considered as an alternative choice in the eyelids reconstructions involving the restoration of posterior lamella because it would avoid the use of ear cartilage, nasoscleral, preserved sclera and the hard palate. Also avoid the occlusion, even if temporary one eye and also a second surgical intervention (2).

Some authors employed similar material that could be a good choice in the case in eyelid reconstruction which is the "AlloDerm (Life Cell Corp., Woodlands, Texas, USA) alloderm TM. Consists of acellular human dermis, and can be used both in eyelid reconstruction of the anterior and the posterior lamella (18,19).

CONCLUSION

The Alloplant™ when implanted in the eyelids and backs of rabbits caused an intense mixed exudative and proliferative inflammatory reaction with a predominance of lymphocytes, macrophages and formation of foreign body granuloma. The microscopic findings observed in the correspond in area on the eyelid implant showed histological pattern of more intense inflammation than the back and in both cases the implant was replaced by dense fibrous connective tissue.

The implant site was repithelized with conjunctival epithelium of the non-keratinized stratified squamous type (squamous metaplasia), revealing that the implant was unsuitable for use on the eyelids.

ACKNOWLEDGEMENTS

Professor João Carlos de Miranda Gonçalves (PhD), Professor Yara Juliano (PhD) and Professor Neil Ferreira Novo (PhD) from Universidade Federal de São Paulo, Brazil.

REFERENCES

1. Neubauer H. Total lid replacement by an autologous and homologous combination graft in emergencies. *Klin Monbl Augenheilkd*. 1986;188(2):97-100.
2. Serdar Y, Zühtü D, Caferi TS, Selim Ç. Reconstruction of periorbital region defects: A retrospective study. *Ann Maxillofac Surg*. 2014; 4(1): 45-50.
3. Mason EM, Cruz AA, Soares EC, Velasco EA, Bedran EG, Portellinha W. - Reconstrução palpebral. In: Soares EJ, Moura EM, Gonçalves JR, editores. *Cirurgia plástica ocular*. São Paulo: Roca; 1997. p. 221- 42.
4. Aldave AJ, Maus M, Rubin PA. Advances in the management of lower eyelid retraction. *Facial Plast Surg*. 2002; 15(3):213-24.
5. Anderson RL, Jordan DR, Beard C. Full thickness unipedicle flap for lower eyelid reconstruction. *Arch Ophthalmol*. 1988; 106(1): 122-5.
6. Jordan DR, Tse DT, Anderson RL, Hansen SO. Irradiated homologous tarsal plate banking: a new alternative in eyelid reconstruction. Part I. Technique and animal research. *Ophthal Plast Reconstr Surg*. 1990;6(3):158-67.
7. Jordan DR, Tse DT, Anderson RL, Hansen SO. Irradiated homologous tarsal plate banking: a new alternative in eyelid reconstruction. Part II. Human data. *Ophthal Plast Reconstr Surg*. 1990;6(3):168-76.
8. Shorr N, Perry JD, Goldberg RA, Hoenig J, Shorr J. The safety and applications of acellular human dermal allograft in ophthalmic plastic and reconstructive surgery: a preliminary report. *Ophthal Plast Reconstr Surg*. 2000;16(3):223-30.
9. Muldashev ER, Kal'met'eva MA, Vasil(eva AM. [Antigenic properties of plantar subcutaneous adipose tissue as a homotransplant for eye surgery]. *Oftalmol Zh*. 1976;31(6):456-9. Russian.
10. Muldashev ER. [Use of allografts of fatty tissue and plantar skin for eliminating cicatricial entropion]. *Oftalmol Zh*. 1980;35(5): 302-4. Russian.
11. Gareev EM, Galimova LF, Muldashev ER. [Surgical treatment of eyeball atrophy with biological implant material alloplant: the structure and time course of morphological and physiological changes]. *Vestn Oftalmol*. 1997;113(3):7-11. Russian.
12. Muldashev ER, Muslimov SA, Nigmatullin RT, Kiiko YI, Galimova VU, Salikhov AY, Selsky NE, Bulatov RT, Musina LA. Basic research conducted on alloplant biomaterials. *Eur J Ophthalmol*. 1999;9(1):8-13.
13. Brovkina AF, Stoiukhina AS. [Method of implant insertion in anophthalmic socket]. *Vestn Oftalmol*. 2011;127(1):48-50. Russian.
14. Stoiukhina AS, Kiseleva TN. [Implants in ophthalmology and potential of visual control]. *Vestn Oftalmol*. 2013;129(2):41-5. Russian.
15. Michalany J. *Técnicas histológicas em anatomia patológica: com instruções para o cirurgião, enfermeira e citotécnico*. São Paulo: EPU; 1980. Métodos selecionados de colorações e de impregnações argênticas. p. 123 - 79.
16. Dias AR, Assumpção LF, Jatene FB, Leone EC, Barros MM, Jatene AD. Heterologous implantation of dura mater in the trachea. *Experimental study*. *Rev Assoc Med Bras*. 1981;27(3): 99-102.
17. Duong HV, Westfield KC. Alloplant implant: a novel biomaterial in the management of recalcitrant glaucoma. *Medscape J Med*. 2008;10(7):177.
18. Oliver RF, Grant RA, Hulme MJ, Mudie A. Incorporation of stored cell-free dermal collagen allografts into skin wounds: a short term study. *Br J Plast Surg*. 1977;30(1):88-95.
19. Rubin PA, Fay AM, Remulla HD, Maus M. Ophthalmic plastic applications of acellular dermal allografts. *Ophthalmology*. 1999;106(11):2091-7.

Corresponding Author:

Rua Paulo Bregaro, 260
CEP 04261-001 - São Paulo
phone / fax: 55 - 11 - 22744000