

Clinical experience with the first 40 cases with femtosecond laser cataract surgery technology: safety of the learning curve

Experiência clínica com os primeiros 40 casos de cirurgia de catarata com a tecnologia de laser de femtossegundo: segurança da curva de aprendizagem

Joao Crispim¹, Ricardo Nose¹, Ana Claudia Medeiros A. Garcia¹, Milton Yogi¹, Walton Nose¹

ABSTRACT

Objective: To evaluate the introduction of the femtosecond laser (FSL) to perform the key steps of the traditional cataract surgery process and the operational difficulties and safety of this new technology during routine use in an operating room in Brazil. **Methods:** A retrospective study was conducted using the first cases operated on at a single center using the laser platform LenSx/Alcon with a soft contact lens patient interface. All patients underwent a detailed preoperative assessment. The anterior capsulotomy, nuclear fragmentation, and corneal incisions were created with the FSL; then, the surgery was completed following the standard phacoemulsification procedure. The main outcome measurements were difficulties and complications related to the learning curve and an analysis of postoperative uncorrected distance visual acuity (UDVA). **Results:** Of 31 patients (40 eyes), 9 patients had FSL cataract surgery in both eyes. The mean age was 64 ± 12 years (ranging from 42 to 82), the mean cataract nuclear sclerosis was grading 2 ± 0.6 (ranging from 1 to 4), and the preoperative mean UDVA in logMAR was 0.4 ± 0.2 (ranging from 0.1 to 1.3). Anterior capsulotomy was complete in all patients, and scissors were not needed to cut off any intact portion. The postoperative corneal incisions were not completely linear and showed some irregularities. Laser phaco-fragmentation was effective, with the division of the nucleus into smaller segments easily performed before phacoemulsification. After 1 month, the postoperative mean UDVA in logMAR was 0.1 ± 0.1 (ranging from 0.0 to 0.4) ($P < 0.0001$). **Conclusion:** With increasing surgical cases and experience, the phacoemulsification steps are performed precisely and effectively with FSL pretreatment, resulting in a safe learning curve.

Keywords: Cataract extraction; Refractive surgical procedures; Phacoemulsification; Laser therapy; Learning curve

RESUMO

Objetivo: Avaliar a introdução do laser de femtossegundo (FSL) para realizar etapas fundamentais da cirurgia de catarata tradicional e as dificuldades e segurança desta nova tecnologia na rotina de um centro cirúrgico no Brasil. **Métodos:** Um estudo retrospectivo foi realizado com os primeiros casos operados em um único centro usando a plataforma de laser LenSx/Alcon, sendo utilizado lentes de contato gelatinosa na interface do paciente. Todos os pacientes foram submetidos a uma avaliação pré-operatória detalhada. Capsulotomia anterior, fragmentação nuclear e incisões na córnea foram criados com a FSL, em seguida, a cirurgia foi concluída com procedimento de facoemulsificação padrão. As principais medidas de desfecho foram dificuldades e complicações relacionadas à curva de aprendizado e análise da acuidade visual pós-operatória não corrigida à distância (UDVA). **Resultados:** Dos 31 pacientes (40 olhos), 9 realizaram cirurgia de catarata em ambos os olhos com FSL. A média de idade foi de 64 ± 12 anos (variando de 42 a 82), a média de classificação da catarata através da esclerose nuclear foi $2 \pm 0,6$ (variando de 1 a 4) e UDVA pré-operatória em logMAR foi de $0,4 \pm 0,2$ (variando de 0,1 a 1,3). A capsulotomia anterior foi completa em todos os pacientes e não precisou usar da pinça para cortar qualquer porção intacta. Incisões corneanas pós-operatórias não foram lineares, mostrando ainda algumas irregularidades. A facofragmentação a laser foi eficaz, com a divisão do núcleo em segmentos menores facilmente realizados antes da facoemulsificação. Após 1 mês de pós-operatório, UDVA em logMAR foi de $0,1 \pm 0,1$ (variando de 0,0 a 0,4) ($P < 0,0001$). **Conclusão:** Com o aumento do volume dos casos cirúrgicos e ganho de experiência, passos precisos da facoemulsificação são realizados com o pré-tratamento com o FSL, resultando em uma segura curva de aprendizagem.

Descritores: Extração de catarata; Procedimentos cirúrgicos refrativos; Facoemulsificação; Terapia a laser; Curva de aprendizado

¹ Department of Ophthalmology and Visual Sciences; Universidade Federal de São Paulo – (SP), Brazil.

No specific financial support was available for this study

Institutional review board number: 19247613.10000.5505

Disclosure of potential conflicts of interest

Received for publication 27/03/2015 - Accepted for publication 13/05/2015

INTRODUCTION

Cataract surgery with intraocular lens (IOL) is the most frequently performed ophthalmic surgical procedure worldwide. Phacoemulsification is the dominant form of cataract surgery in developed countries, representing over 90% of the procedures⁽¹⁾. The basic phacoemulsification procedure has remained unchanged over the past 20 years and involves a series of individual steps, including the creation of a corneal incision, capsulorhexis and phacofragmentation and lens implantation.

Since 2001, several FSL systems have been introduced in clinical practice, and over 2 million ophthalmic procedures were performed using FSL, especially for the creation of a corneal flap in Laser-Assisted in Situ Keratomileusis (LASIK). The precision of FSL with reduced side effects exceeds highly sophisticated mechanical devices⁽²⁾. After receiving FDA approval in 2010, FSL has been used in cataract surgery to increase precision during crucial surgical stages⁽³⁾.

We evaluated the introduction of the FSL for performing key steps in the traditional cataract surgery process, including anterior capsulotomy, corneal incisions and fragmentation of the lens, and assessed operational difficulties and safety when introducing this new technology during routine practice in an operating room in Brazil.

METHODS

We conducted a retrospective study of the first cases operated at a single center in Brazil using the laser platform LenSx/Alcon FSL (Alcon, Fort Worth, TX) with a soft contact

lens patient interface. Discussion about the risks and benefits of the procedure was followed by obtaining informed written consent. The study adhered to the tenets of the Declaration of Helsinki and was approved by the local ethics committee. All procedures were performed at the Eye Clinic of São Paulo between June and August 2013.

All patients underwent a detailed preoperative assessment, including slit-lamp biomicroscopy, tonometry, measurement of uncorrected and corrected visual acuity and manifest refraction. Cataract investigations included measurement of axial length and biometry (IOLMaster V7.5, Carl Zeiss Meditec Inc., Jena, Germany); pachymetry, corneal topography, and lens densitometry (Pentacam HR, Oculus, Wetzlar, Germany); and specular microscopy (EM-3000, Tomey, Phoenix, AZ). The intraocular lens (IOL) power was targeted to plano in all eyes studied. Included in this study were patients with visually significant cataract. Exclusion criteria included a history of glaucoma or retinal detachment, corneal disease, irregular corneal astigmatism, abnormal irises, macular degeneration or retinopathy, neuro-ophthalmic disease, or a history of ocular inflammation.

Operative Technique

All procedures were performed with the LenSx laser under topical anesthesia. The disposable patient interface was docked to the eye, and the individual patient treatment was programmed into the laser. The anterior capsulotomy, nuclear-fragmentation, primary and side-port corneal incisions were then created, 180 degrees apart, with the FSL under optical coherence tomography (OCT) image control. Treatment parameters for the LenSx FSL are summarized in table 1.

Table 1

The most commonly used treatment parameters for the LenSx femtosecond laser

	Primary Incision	Side-port Incision	Anterior Capsulotomy	Nuclear Fragmentation
Energy (M)	5.0	5.0	5.0	8.0
Configuration	3 plane internal-trapezoid	single-plane external trapezoid	5.0 mm diameter	4.8 mm of 2 chop/ 2.3 mm of 1 cylinder
Spot/Layer	5.0 / 5.0	5.0 / 5.0	4.0 / 3.0	12.0 / 10.0
Width (mm)	2.4	1.2	-	-
Delta Value	-	-	325 / 325	500 / 800
Up / Down				

After completion of the laser procedure, the patient was transferred to the operating room. The laser-cut main and secondary corneal incisions were opened with a modified Sinsky hook. The anterior capsular button was removed with forceps; then, the surgery was completed with the standard phacoemulsification procedure using the Infiniti Vision System (Alcon). The postoperative regimen included 1 drop of moxifloxacin 1.0% (Vigamox, Alcon), ketorolac tromethamine (Acular, Allergan), and dexamethasone 0.1% (Maxidex, Alcon) 4 times per day for 2 weeks, followed by dexamethasone drops twice per day for 1 week and once daily for the last week. Each patient was followed up at days 1, 7 and 30.

Outcome measurements

The main outcome measurements evaluated were operational difficulties and the safety of this new technology with the first 40 cases performed by a single surgeon (W.N.), complications related to the learning curve, and postoperative uncorrected distance visual acuity (UDVA) after 1 month of follow-up.

Statistical analysis

Statistical analysis was performed with GraphPad Prism version 6 for Mac OS X (GraphPad Software, San Diego, CA, USA). The Wilcoxon test was used to analyze significance within

the preoperative and postoperative UDVA. The level of significance was set at $P < 0.05$.

RESULTS

From 31 patients (20 females and 11 males), 40 consecutive cataract surgeries were performed with the LenSx FSL with IOL implantation were included in this study. Nine patients (6 females and 3 males) had FSL cataract surgery in both eyes, and the mean age was 64 years (± 12 standard deviation (SD), ranging from 42 to 82). At baseline, the mean cataract nuclear sclerosis was grading 2 (± 0.8 SD, ranging from 1 to 4), the mean axial length was 23.97 mm (± 1.44 SD, ranging from 21.67 to 26.91), the mean anterior chamber depth (ACD) was 3.29 mm (± 0.36 SD, ranging from 2.41 to 3.89), the mean preoperative endothelial cell density (ECD) was 2312 (± 261 SD, ranging from 1890 to 2958), and the preoperative mean UDVA in logMAR was 0.4 (± 0.2 SD, ranging from 0.1 to 1.3) (table 2).

Table 2

Demographic and baseline characteristics of all patients

	Mean + SD	Range
Age (years)	64 \pm 12	42 - 82
Cataract NS grade	2 \pm 0.8	1 - 4
Axial Length (mm)	23.97 \pm 1.44	21.67 - 26.01
ACD (mm)	3.29 \pm 0.36	2.41 - 3.89
Preop ECD	2312 \pm 261	1890 - 2958
Preop UCDVA (log MAR)	0.4 \pm 0.2	0.1 - 1.3

NS: nuclear sclerosis; ACD: anterior chamber depth; ECD: endothelial cell density; UDVA: uncorrected distance visual acuity; SD: standard deviation

Capsulotomy

The anterior capsulotomy was complete in all patients, and scissors were not needed to cut off any intact portion. Radial tears were not observed after any procedure. The surgeon (W.N.) determined that all capsulotomies were well centered based on visual inspection with a surgical microscope.

Corneal Incisions

A triplanar main incision and a single-plane side-port incision were made 180 degrees apart, which allows the option to change size and angulation. Postoperative incisions were not completely linear and still showed some irregularities. A modified sinsky hook was necessary to open all incisions through the gas bubble stromal edge. When incisions were limbal, they were very difficult to open. In our sample, we had 3 main and 2 auxiliary incisions with such difficulties. A metal keratome was necessary for those cases.

Phaco-fragmentation

The laser phaco-fragmentation was effective, and the nucleus was easily divided into smaller segments before phacoemulsification. A 2 chop and 1 cylinder parameter was set for all cases (table 1). Cataract removal was performed in all

eyes, and IOL implantation was successful. The IOL was centered in all eyes in the study, and there were no ruptures of the posterior capsule. Cataracts from eyes that received laser fragmentation were easily divided into fragments that required shorter durations of ultrasound energy to complete the phaco cataract removal compared with eyes that did not undergo phaco-fragmentation by laser.

Complications and adverse events

There were no adverse events or complications in the cases analyzed in this study.

Refractive outcomes

Additionally, to evaluate the safety of FSL during cataract surgery, we compared the preoperative and 1 month postoperative UDVA. The mean preoperative UDVA in logMAR was 0.37 (95% confidence interval (CI) of 0.29 to 0.44). Compared with the preoperative UDVA, the postoperative UDVA was 0.10 (95% CI of 0.06 to 0.14) ($P < 0.0001$, Wilcoxon test) (table 3).

Table 3

Comparison of UDVA refractive outcomes

Period	UCDVA in logMAR (n=40) Mean (95% CI)
Preoperative	0.37 (0.29 to 0.44)
Postoperative	0.10 (0.06 to 0.14)
Within group significance (Wilcoxon test)	P < 0.001

UDVA: uncorrected distance visual acuity; CI: confidence interval

We did not compare the preoperative and postoperative ECD because we did not have data for the postoperative ECD. Of all eyes that we retrospectively evaluated, none of them had corneal edema, guttata, any sign of bullous keratopathy or even decreased visual acuity that required a specular microscopy exam in 1 month of postoperative follow-up.

DISCUSSION

The FSL used was the LenSx (Alcon) with the soft contact lens patient interface, which facilitates docking, lowering increased intraocular pressure (an approximate 16 mmHg increase). It performs anterior capsulotomy, nuclear fragmentation and corneal incisions, which facilitates surgery. It has a coupled OCT that provides high-resolution images of the lens thickness, allowing the area of nuclear fragmentation to be resized and informing the shape of the incisions, which can be changed based on the surgeon's criteria (figure 2).

It is important to emphasize the patient's position at the time of docking, which should promote corneal flattening, because this step is considered the most critical step for the FSL in cataract surgery. Most complications that previous papers have reported should be considered when docking is difficult⁽⁴⁻⁶⁾. We believe that patient cooperation, good medical-patient interaction during the procedure, and perfect docking are crucial for a safe learning curve experience. If the dock touches the nose of the patient,

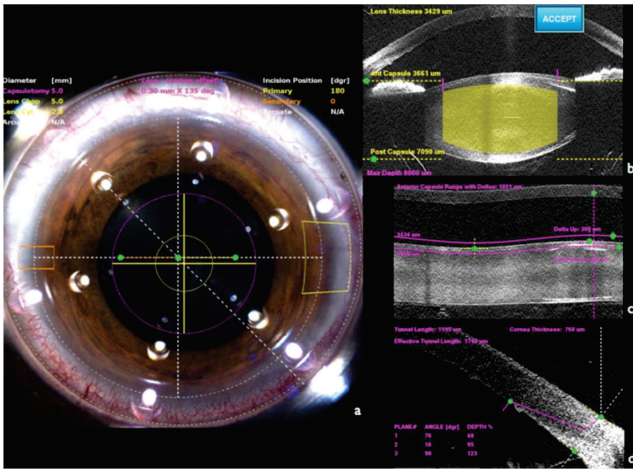


Figure 1: The FSL LenSx in action; a) anterior capsulotomy, nuclear fragmentation and corneal incisions; b, c and d) OCT generating high-resolution image of the lens thickness, anterior capsulotomy, and triplanar corneal incision, respectively

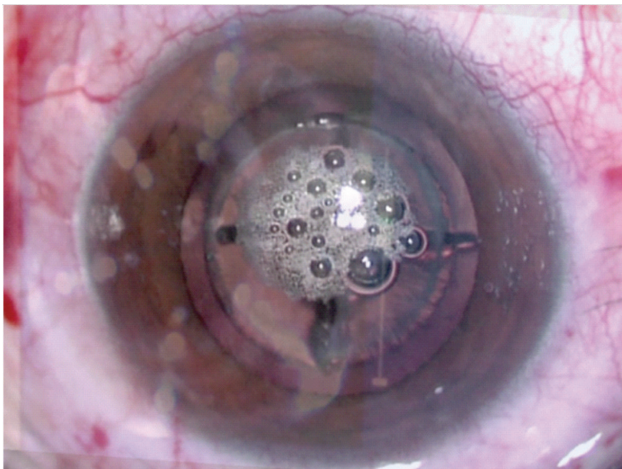


Figure 2: After using the FSL, it is possible to note the incisions, capsulotomy and fragmented lens with air bubbles

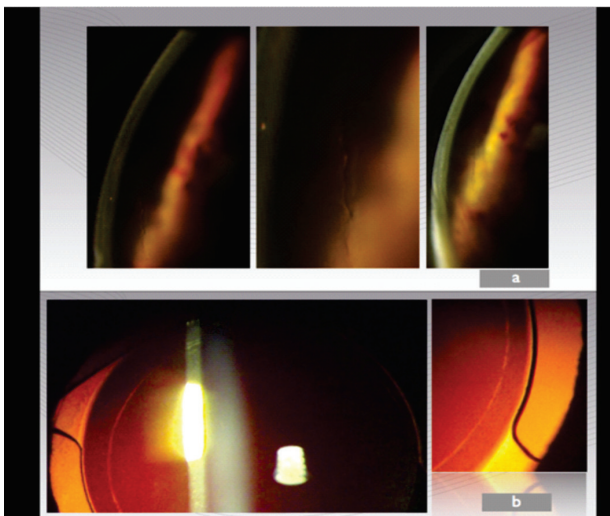


Figure 3. Postoperative: a) incisions were not completely linear and showed some irregularities; b) the capsulotomy was perfect

then surgeon should pay attention to the patient’s position. Parameters, such as vacuum and centralization, can be accessed in real time on the device’s screen, which is programmed with the predetermined main and accessory incisions, anterior capsulotomy and lens fragmentation. If the surgeon has difficulty in programming those parameters, it is recommended to re-dock or even cancel the FSL treatment. Additionally, if the surgeon notices a problem during treatment, such as sudden eye movement, a release of the foot pedal will stop treatment.

A triplanar corneal incision was performed, which allows the surgeon to change size and angulation. After using the FSL, the surgeon uses the appropriate hooks to open incisions, loose the capsulotomy (free floating) and fragment the lens with phaco-aspiration (figure 3). A hydrodissection cannot be performed without removing the air bubbles that are generated during FSL photodisruption; if the volume of bubbles is increased, the viscoelastic removal should occur before the hydromaneuvers to prevent posterior capsule rupture later.

When planning the organization of a surgical center, we recommend having the FSL in an anteroom; the FSL can be operated by an assistant or surgeon assistant who has the capacity to send patients to 2-3 rooms so the main surgeon can finalize the cataract surgery. When the cataract quadrants are well divided, less ultrasound energy is used. Conjunctival hyperemia after coupling with the FSL was not so important and did not bother the chief surgeon (W.N.) or the patients. It can present pupillary contraction in certain cases, in which case the use of adrenaline in the BSS is recommended. Postoperative incisions were not completely linear and showed some irregularities (figure 4).

Of 40 cases, the complications were minimal. When incisions were limbal, they were very difficult to open. In our sample, we had 3 main and 2 auxiliary incisions that presented such difficulties. All fractures were very well done, and there were no cases of posterior capsule rupture. Anterior capsulotomies that were created by the laser were more uniform, precise and predictable than those produced by manual capsulorhexis⁽⁷⁾.

Initial procedures performed on humans further support the viability of the LenSx FSL technology to improve the safety and reproducibility of two of the most important steps in cataract surgery process: anterior capsulotomy and phaco-fragmentation. In contrast to previous attempts to improve the manual capsulorhexis, the laser accuracy in performing capsulotomies is largely independent of the surgeon and may be more flexible in terms of size, shape and positioning^(8,9). In addition of that, manual capsulorhexis can be tough in challenging cases, including white intumescent cataract. Research has been published describing and comparing different techniques⁽¹⁰⁾; however, with the advent of FSL for cataract surgery, safety may be achieved easily with the laser precision, including challenging cases^(11,12).

Cataract surgeries with FSL pretreatment results in a significant reduction in the effective phacoemulsification time, which can be achieved using better surgical techniques and lens fragmentation patterns⁽¹³⁾. While the impact of reduced phacoemulsification energy on the corneal endothelium is still being investigated, we recommend FSL pretreatment especially for those cases with low ECD at baseline, including in patients with previous corneal transplant, mature cataracts and some post-refractive surgeries.

FSL fragmentation with different grid sizes affects the effective phaco time during cataract surgery⁽¹⁴⁾. Although there are standard parameters to use with each FSL platform, it is important to perform a precise preoperative assessment and set

intraoperative parameters based on each case, including energy and delta values for fragmentation (based on lens size and nuclear sclerosis) and anterior capsulotomy, and centering of the capsulotomy and corneal incisions.

Although the study has a small sample size, we do not have any surgical complication to report with these initial cases of the FSL-assisted cataract surgeries. As shown previously with a large sample size, surgical outcomes and the safety of FSL cataract surgery improve significantly with greater surgeon experience, the development of modified techniques, and improved technology⁽¹⁵⁾. The postoperative UDVA was statistically significant better than the preoperative UDVA (table 3), confirming the safety of all procedures.

Unfortunately, we have some limitations to the current study that should be considered. The first limitation is the retrospective data analysis based on chart review. This retrospective nature resulted in the second limitation, which is the absence of postoperative ECD data. However, none of the first 40 cases operated on with the FSL platform had prolonged postoperative corneal edema or guttata at 1 month of follow-up. This finding is why a specular microscopy exam was not required at the 1-month visit. Further clinical research is needed to evaluate the endothelial cell damage in eyes operated with FSL-assisted cataract surgery, especially in those with low ECD, such as Fuchs dystrophy. Another limitation that could be addressed is the lack of a control group. However, our purpose was not to compare the safety of cataract surgery with or without FSL. Further prospective randomized controlled studies should address this issue.

In summary, we conclude that with increasing surgical cases and experience, the precise and effectively steps of phacoemulsification can be performed with FSL pretreatment, resulting in a safe learning curve.

REFERENCES

- Dick HB, Peña-Aceves A, Manns A, Krummenauer F. New technology for sizing the continuous curvilinear capsulorhexis: prospective trial. *J Cataract Refract Surg.* 2008; 34(7):1136-44.
- Durrie DS, Kezirian GM. Femtosecond laser versus mechanical keratome flaps in wavefront-guided laser in situ keratomileusis: prospective contralateral eye study. *J Cataract Refract Surg.* 2005; 31(1):120-6.
- Sutton G, Bali SJ, Hodge C. Femtosecond cataract surgery: transitioning to laser cataract. *Curr Opin Ophthalmol.* 2013; 24(1):3-8.
- Lubahn JG, Kankariya VP, Yoo SH. Grid pattern delivered to the cornea during femtosecond laser-assisted cataract surgery. *J Cataract Refract Surg.* 2014; 40(3): 496-7.
- Nagy ZZ, Takacs AI, Filkorn T, Kránitz K, Gyenes A, Juhász É, Sándor GL, Kovacs I, Juhász T, Slade S. Complications of femtosecond laser-assisted cataract surgery. *J Cataract Refract Surg.* 2014; 40(1): 20-8.
- Abell RG, Davies PE, Phelan D, Goemann K, McPherson ZE, Vote BJ. Anterior capsulotomy integrity after femtosecond laser-assisted cataract surgery. *Ophthalmology.* 2014;121(1): 17-24.
- Dick HB, Gerste RD, Schultz T, Waring GO 3rd. Capsulotomy or capsulorhexis in femtosecond laser-assisted cataract surgery? *J Cataract Refract Surg.* 2013; 39(9):1442.
- Wallace RB III. Capsulotomy diameter mark. *J Cataract Refract Surg.* 2003; 29(10):1866-8.
- Tassignon MJ, Rozema JJ, Gobin L. Ring-shaped caliper for better anterior capsulorhexis sizing and centration. *J Cataract Refract Surg.* 2006; 32(8): 1253-5.
- Kara-Junior N, Santhiago MR, Kawakami A, Carricondo P, Hida WT. Mini-rhexis for white-intumescent cataracts. *Clinics.* 2009; 64(4): 309-32.
- Conrad-Hengerer I, Hengerer FH, Joachim SC, Schultz T, Dick HB. Femtosecond laser-assisted cataract surgery in intumescent white cataracts. *J Cataract Refract Surg.* 2014;40(1):44-50
- Martin AI, Hodge C, Lawless M, Roberts T, Hughes P, Sutton G. Femtosecond laser cataract surgery: challenging cases. *Curr Opin Ophthalmol.* 2014;25(1):71-80.
- Abell RG, Kerr NM, Vote BJ. Toward zero effective phacoemulsification time using femtosecond laser pretreatment. *Ophthalmology.* 2013; 120(5): 942-8.
- Conrad-Hengerer I, Hengerer FH, Schultz T, Dick HB. Effect of femtosecond laser fragmentation of the nucleus with different softening grid sizes on effective phaco time in cataract surgery. *J Cataract Refract Surg.* 2012; 38(11):1888-94.
- Roberts TV, Lawless M, Bali SJ, Hodge C, Sutton G. Surgical outcomes and safety of femtosecond laser cataract surgery: a prospective study of 1500 consecutive cases. *Ophthalmology.* 2013;120(2):227-33.

Corresponding author:

Walton Nose
Rua Botucatu, nº 821
CEP 04023-062 - São Paulo, (SP) Brazil
E-mail: wnose@me.com