

Lipid corneal degeneration after trabeculectomy with mitomicin 0.02%

Degeneração lipídica da córnea após trabeculectomia com mitomicina C 0,02%

Larissa Rossana Souza Stival¹, Luis Fernando Oliveira Borges Chaves¹, Karine Sauter¹, Luiz Arthur Franco Beniz¹, Jordana Sandes Barbosa Soares¹, Francisco Wellington Rodrigues¹, Marcia Cristina Toledo¹, José Beniz¹

ABSTRACT

One patient with a history of trabeculectomy with Mitomicin C 0.02%, but no history of systemic disorders, exhibited unilateral corneal lipid infiltrates, together with deep stromal vascularization. She was treated with a bevacizumab injection and penetrating keratoplasty. No sign of recurrence was noted after one year post-operative.

Keywords: *Trabeculectomy; Mitomicin C; Phospholipids/metabolism; Bevacizumab/therapeutic use; Keratoplasty, penetrating; Cornea/metabolism; Case reports*

RESUMO

Um paciente com história de trabeculectomia com Mitomicina C 0,02%, sem doenças sistêmicas pré-existentes, apresentou infiltrado lipídico corneano unilateral associado à vascularização intraestromal profunda. Injeção subconjuntival de Bevacizumabe foi realizada e posterior ceratoplastia penetrante. Não houve sinais de recorrência em um ano.

Descritores: *Trabeculectomia; Mitomicina C; Fosfolípidios/metabolismo; Bevacizumabe/uso terapêutico; Ceratoplastia penetrante; Córnea/metabolismo; Relatos de casos*

¹ Cornea and Refractive Surgery Service, Centro de Referência em Oftalmologia, Universidade Federal de Goiás – Goiânia (GO), Brazil.

Study carried out at Universidade Federal de Goiás – Goiânia (GO), Brazil.

The authors declare no conflicts of interests.

Received for publication 24/09/2015 - Accepted for publication 16/12/2015

INTRODUCTION

The use of antifibroblastic drugs such as mitomycin C (MMC) improved the outcome of glaucoma filtering surgery⁽¹⁾. The use of MMC can lead to complications including hypotonic maculopathy, extended choroidal detachment and decrease in visual acuity due to a progressive cataract⁽¹⁻²⁾. Once such complications occur, they tend to be extended for a longer period of time because of the strong antifibroblastic effect of MMC. Prevention and treatment of such complications are now considered to present a problem with the use of MMC in this procedure⁽²⁾.

Opacification of the cornea by lipid deposits may be primary (with no evidence of prior corneal vascularization) or secondary (resulting from systemic or local disease). Secondary lipid degeneration of the cornea is not uncommon in diseases of traumatized corneas, especially if vascularization has occurred⁽³⁾.

Corneal neovascularization (NV) associated with lipid deposition is a well-known ocular surface disorder that may lead to cosmetic problems and visual loss⁽⁴⁾. Management of corneal NV in such cases is important, not only because it may induce lipid deposition and alter visual acuity, but also because it worsens the prognosis for subsequent penetrating keratoplasty (PK)⁽⁵⁾. Recently, many ophthalmologists have widely administered anti-vascular endothelial growth factor (VEGF) therapy using bevacizumab as an off-label drug to treat ocular diseases^(6,7).

We describe a patient with glaucoma that was submitted to trabeculectomy with MMC and had no history of systemic disorders, who presented with lipid corneal degeneration over a period of 5 years after the surgery. To the best of our knowledge, this has never been reported before.

CASE REPORT

A 62 year-old woman exhibited progressive opacification of the superior cornea of the left eye 5 years after being submitted to trabeculectomy with subconjunctival mitomycin C 0.02%, at an exposure time of 2 minutes. The right eye presented no ocular abnormalities. Visual acuity was 20/20 in the right eye (OD) and 20/80 in the left eye (OS). Slit-lamp examination revealed a grayish white opacification in the entire corneal thickness and some limbal NV superiorly (Figure 1). Laboratory determination of blood lipidogram was normal.

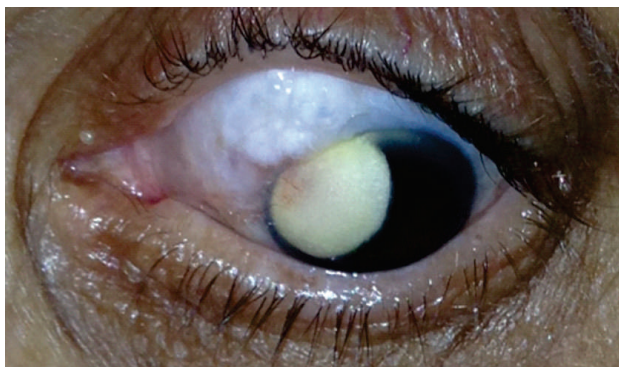


Figure 1: Deep stromal vascularization from the limbus towards the deposits, in the same region of the trabeculectomy.

Under topical anesthesia, we injected subconjunctivally 1.25 mg/0.05 ml of bevacizumab (Avastin; Roche Pharmaceuticals, Basel, Switzerland) at the site of the most severe pathologic vessel growth. Presenting initial improvement of the lipidic deposition size (3 mm) and reduction of NV (Figure 2).

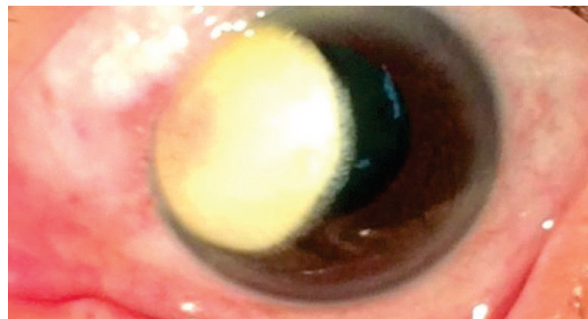


Figure 2: One month after the first bevacizumab injection, corneal vessels regressed

One month later, we performed an 8.5/8.0 mm penetrating keratoplasty in the left eye (Figure 3). Postoperative recovery occurred without complications. After a year, the patient still presented no recurrence. Before and after the procedures, intraocular pressure of OS was normal in all follow-up visits.

Corneal specimen was fixed with 10% buffered formaldehyde, embedded in paraffin, sectioned and stained with hematoxylin-eosin and Alcian Blue. The corneal epithelium showed normal thickness, without edema. The stroma presented increased thickness. Formaldehyde 10% is not the golden standard technique to fix fatty deposits, but it is possible to see some of these laying among the stromal fibers and within cells. Proliferation of small capillaries had occurred (Figure 4).

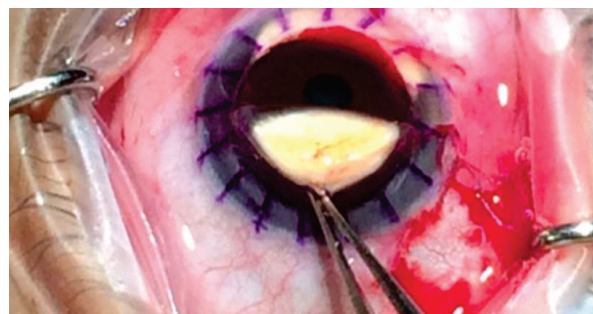


Figure 3: Lipid degeneration and deep stromal vascularization.

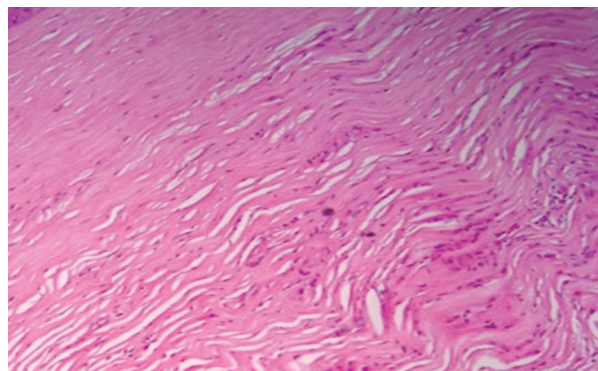


Figure 4: Histopathology of the corneal button (hematoxylin-eosin). Lipid deposits and presence of vessels in deep stroma.

DISCUSSION

For several years, trabeculectomy has been a standard surgical procedure for the management of glaucoma. Despite the high successful rates in lowering the intraocular pressure, several postoperative complications related to this procedure, most notably hyphema, anterior chamber shallowing, overfiltration with hypotony, choroidal detachment, anterior chamber inflammation and endophthalmitis⁽⁸⁾. Trabeculectomy is often associated with the use of peri-operative antimetabolites, toxic to the corneal endothelium. Associated with natural cell loss after intraocular surgery⁽⁹⁾, it could lead to endothelial failure.

The mechanism of action of MMC in the cornea is controversial. The inhibition of keratocyte proliferation observed after photorefractive keratectomy was originally believed to be the main mechanism of MMC, since it was reported to have an antiproliferative effect on cultured human keratocytes. However, since they reported MMC cause apoptosis of cultured human keratocytes, this is now considered its main effect on corneal cells⁽¹⁰⁾.

Corneal NV occurs as a sequel resulting from various causes such as infections, allergies, toxins, anoxia and immune response. Although neovessels facilitate the healing process, they often persist after it is complete, interfering with corneal transparency due to leakage of lipids. Thus, obliteration of the feeding vessels is important for decreasing lipid deposition in the cornea, therefore stabilizing or improving its transparency. Moreover, in cases requiring keratoplasty, pregraft treatment of corneal NV can improve the chances of graft survival⁽¹¹⁾.

In the present study, we observed the efficacy of VEGF inhibition by bevacizumab in a patient with progressive lipid keratopathy associated with corneal NV. We found that it markedly regressed and no progression of lipid deposition was observed. Oh⁽¹¹⁾ found that the regression of corneal NV was more evident after repeated injections of anti-VEGF, suggesting the cumulative effects of the drug. We used one corneal intrastromal injection in addition to a subconjunctival injection because we wanted to increase drug concentration in the deep layers of the cornea, where neovessels are often present in lipid keratopathy. Topical administration of bevacizumab reduce corneal NV in humans and animals⁽¹¹⁾. A study to determine the penetration and concentration of topical bevacizumab in the cornea has not yet been performed.

Corneal lipid degeneration following local vascularization or due to familial hypercholesterolemia happens as a common secondary change, usually found after ulceration, trauma, and herpes keratitis⁽¹²⁾.

In conclusion, we think that this case presented a corneal lipid disorder secondary to neovascularization caused by the trabeculectomy procedure associated with the use of MMC. Lipid degeneration in our case was limited to large aggregates of extracellular lipid microvesicles and cholesterol crystals. Our observation supports the idea that lipid accumulation occurs entirely extracellularly as clusters of lipidic microvesicles. They subsequently form cholesterol crystals, when sterols and esters reach appropriate concentration. Lipidogram was well within normal limits and there was no evidence of hereditary disorders in our patient.

REFERENCES

1. Fukuchi T, Hayakawa Y, Hara H, Abe H. Corneal endothelial damage after trabeculectomy with mitomycin C in two patients with glaucoma with cornea guttata. *Cornea*. 2002;21(3):300-34.
2. Shields MB, Scroggs MW, Sloop CM, Simmons RB. Clinical and histopathologic observations concerning hypotony after trabeculectomy with adjunctive mitomycin C. *Am J Ophthalmol*. 1993;116(6):673-63;
3. Durán JA, Rodriguez-Ares MT. Idiopathic lipid corneal degeneration. *Cornea*. 1991;10(2):166-9;
4. Silva-Araujo A, Tavares MA, Lemos MM, Soares MI, Castro Correia J, Salgado Borges J. Primary lipid keratopathy: a morphological and biochemical assessment. *Br J Ophthalmol*. 1993;77(4):248-50.
5. Bachmann B, Taylor RS, Cursiefen C. Corneal neovascularization as a risk factor for graft failure and rejection after keratoplasty: an evidence-based meta-analysis. *Ophthalmology*. 2010;117(7):1300-1305.
6. Chu HS, Hu FR, Yang CM, Yeh PT, Chen YM, Hou YC, Chen WL. Subconjunctival injection of bevacizumab in the treatment of corneal neovascularization associated with lipid deposition. *Cornea*. 2011;30(1):60-6.
7. Lin CT, Hu FR, Kuo KT, Chen YM, Chu HS, Lin YH, Chen WL. The different effects of early and late bevacizumab (Avastin) injection on inhibiting corneal neovascularization and conjunctivalization in rabbit limbal insufficiency. *Invest Ophthalmol Vis Sci*. 2010;51(12):6277-85.
8. Tamcelik N, Ozdamar A, Kizilkaya M, Devranoglu K, Ustundag C, Demirkesen C. Fungal keratitis after nonpenetrating glaucoma surgery. *Cornea*. 2002;21(5):532-4.
9. Aldave AJ, Rudd JC, Cohen EJ, Rapuano CJ, Laibson PR. The role of glaucoma therapy in the need for repeat penetrating keratoplasty. *Cornea*. 2000;19(6):772-6.
10. Song JS, Kim JH, Yang M, Sul D, Kim HM. Mitomycin-C concentration in cornea and aqueous humor and apoptosis in the stroma after topical mitomycin-C application: effects of mitomycin-C application time and concentration. *Cornea*. 2007;26(4):461-7.
11. Oh JY, Kim MK, Wee WR. Subconjunctival and intracorneal bevacizumab injection for corneal neovascularization in lipid keratopathy. *Cornea*. 2009;28(9):1070-3.
12. Savino DF, Fine BS, Alldredge OC. Primary lipidic degeneration of the cornea. *Cornea*. 1986;5(4):191-8.

Corresponding author

Larissa Rossana Souza Stival
 Rua R-12, n 398, apto 3202, Setor Oeste
 Zip code: 74125-140
 Goiânia (GO), Brazil
 Phone: (+55-62) 81110600,
 Email: larissastival@hotmail.com