

Iridocorneal Endothelial Syndrome: Case Report of Chandler's Variant

Síndrome Iridocorneana Endotelial: Relato de Caso da Variante de Chandler

Carolina Tagliari Estacia¹, Aluisio Rosa Gameiro Filho¹, Paloma Gassen Faccenda¹, Roberta Valadão Negri¹, Daniela Trotta Chianello¹, Marco Antônio Souza Alves¹

ABSTRACT

We report in this study a case of Chandler's Syndrome, an Iridocorneal Endothelial Syndrome variant in a 56 years old patient, female, complaining about low vision in the right side, as well as itching and photophobia in the same side. In the first evaluation, we observed visual acuity of counting fingers at 0,5 meters, corneal swelling with microcystus and conjunctival hyperemia. The left eye was normal. Intraocular pressure was 16mmHg in right eye and 10 mmHg in left eye. We initiated topic treatment with Dorzolamide, Timolol and Dexamethasone, with good control of intraocular pressure. We noticed in corneal specular microscopy the presence of ice cells. In current biomicroscopy it is remarkable the corneal swelling, with central opacity and lens was not visible, as well as the funduscopy is impossible. We confirmed the diagnosis of Chandler' Syndrome based on the clinical findings, and in abnormalities in complementary exams. Nowadays, the patient is being followed in the Ophthalmology department at Hospital Federal Servidores do Estado.

Keywords: *iridocorneal endothelial syndrome; Corneal diseases; Endothelial corneal; Glaucoma; Case reports*

RESUMO

O presente estudo tem por objetivo relatar um raro caso da variante de Chandler da Síndrome Iridocorneana Endotelial em uma paciente de 56 anos. Esta referia baixa acuidade visual em olho direito há 2 anos, acompanhada de fotofobia e prurido. Ao exame oftalmológico, no primeiro atendimento, apresentava em olho direito acuidade visual de conta dedos à 0,5 metro e se observava à biomicroscopia policoria, edema corneano com microcistos e hiperemia conjuntival. O olho esquerdo não apresentava alterações. A pressão intraocular era de 16mmHg no olho direito e 10mmHg no olho esquerdo. Iniciou-se tratamento tópico com dorzolamida, maleato de timolol e dexametasona, sendo então, alcançado o controle da pressão intraocular. Constatou-se no exame de microscopia especular corneana a presença de ice cells. Na biomicroscopia atual, apresenta, no olho acometido, edema corneano com opacidade central, policoria, cristalino não visível e fundo de olho indepassável. Diante da confirmação do diagnóstico de Síndrome de Chandler, pelo quadro clínico compatível e alterações nos exames complementares, a paciente está em acompanhamento no serviço de Oftalmologia do Hospital Federal Servidores do Estado.

Descritores: *Síndrome endotelial iridocorneana; Doenças da córnea; Endotélio corneano/patologia; Glaucoma; Relatos de casos*

¹ Hospital Federal dos Servidores do Estado do Rio de Janeiro, rio de Janeiro, RJ, Brasil.

The authors declare no conflicts of interests.

Received for publication 21/11/2016 - Accepted for publication 21/02/2017.

INTRODUCTION

Chandler's syndrome is a rare condition characterized by abnormalities in the corneal endothelium, iridocorneal angle obstruction, and iris abnormalities, such as iris atrophy. It is one of the variants of iridocorneal endothelial syndrome (essential iris atrophy, Chandler's syndrome and Cogan-Reese's syndrome). It affects middle-aged adults with female predilection, unrelated to family history and usually unilateral.

The aim of the treatment is to avoid complications of the disease such as elevation of intraocular pressure and corneal edema resulting in decreased visual acuity.⁽¹⁾

CASE REPORT

Female patient, 56 year old, with schizophrenia and DM type II, with no other pathological history, with a history of low visual acuity (LVA) in the right eye for 2 years associated to photophobia and pruritus. At the ophthalmologic exam at the time, she presented polycoria in the RE, corneal edema with microcysts and conjunctival hyperemia. The intraocular pressure (IOP) was 16mmHg in the right eye (RE) and 10mmHg in the left eye (LE). Dorzolamide 2% eyedrops was prescribed every 12h, timolol maleate 0.5% every 12h, and Dexamethasone every 8h in the RE, and dexamethasone was gradually withdrawn. Her follow-up was in the service, with control of the intraocular pressure within the desired limits. A specular corneal microscopy showed presence of ice cells in the RE, and it was not possible to perform a cellular count in this eye, and an endothelium with mild polymorphism and pleomorphism and 2477 cells/mm² in the left eye (LE) (Figure 1). Corneal topography in the RE showed important irregularity of the anterior surface of the cornea, observed in the assessment of Plácido rings (there was no possibility of generating topographic map) (Figure 2). The measure of visual acuity without correction in the RE = finger count at 0.5m, and in the LE = 20/40. The refraction in the RE was (+2.00), with no improvement in the visual acuity, and in the LE (+2.00 -0.75%) 20/40. Biomicroscopy (Figure 3) showed a corneal edema +3/+4 in the RE, with central opacity, polycoria, non-visible crystalline, and in the LE clear cornea, nuclear cataract +1/+4, wide anterior chamber (AC), reactive pupil. Fundoscopy was undetectable in the RE, and with no changes in the LE.

Gonioscopy of the right eye was impossible due to edema and corneal opacity; the left eye revealed an open angle with visualization of posterior trabecular pigmentation. The intraocular pressure (IOP) in the RE showed no measurement conditions, and in the LE was of 10mmHg. The clinical condition of the patient and of the exams described above confirmed the diagnosis of Chandler's Syndrome.

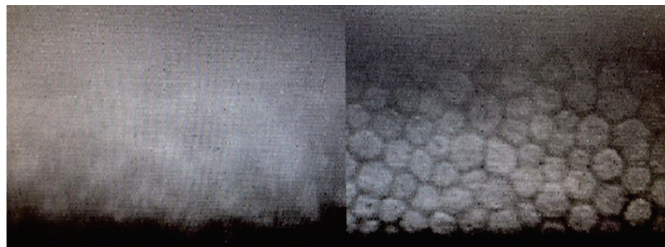


Figure 1. Specular biomicroscopy demonstrating a reduction in the number of cells in the RE compared to the LE

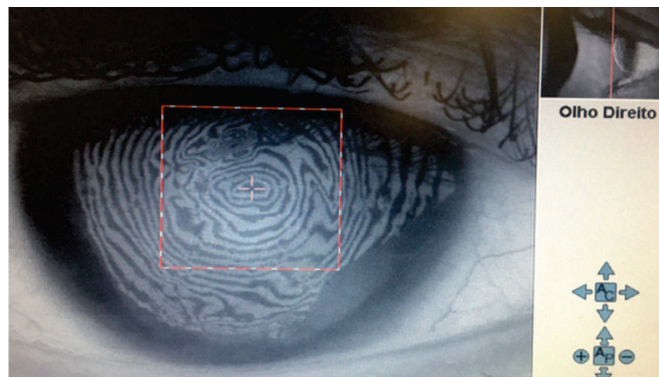

Figure 2. Corneal topography of the RE, diffusely changed by corneal edema, displayed by the irregularity of the Plácido rings.

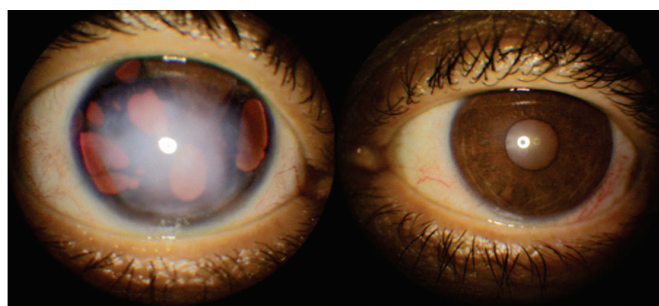


Figure 3. Biomicroscopy

DISCUSSION

Iridocorneal Endothelial Syndrome (ICE SD) is a rare condition characterized by abnormalities in the corneal endothelium, iridocorneal angle obstruction, and iris abnormalities, such as iris atrophy.

This condition was initially described by Harms, in 1903⁽²⁾, as essential progressive iris atrophy. In 1956, Chandler⁽³⁾ described a rare unilateral condition characterized by iris atrophy, corneal edema and glaucoma called Chandler's Syndrome, which was subsequently classified as a subtype of ICE syndrome. In turn, in 1976, Cogan and Reese⁽⁴⁾ reported a similar condition associated to iris nodules, which they called Cogan-Reese Syndrome. Later studies showed that the three clinical conditions presented similar clinical condition and story, and therefore were classified as the spectra of the same syndrome: ICE syndrome, or endothelial iridocorneal syndrome.

The pathological mechanisms of the ICE syndrome are related to the abnormal proliferation of the corneal endothelium, and the migration of the latter, posterior to the Schwalbe line, obstructing the iridocorneal angle, and also anterior, towards the CA, creating an abnormal base membrane which eventually contracts, generating pupillary abnormalities, atrophic damage to the iris, and synechiae among the adjacent structures.

Although already described more than a century ago, there are still doubts about its etiology. In his study, Alvarado⁽⁵⁾ states that corneal endotheliopathy is associated to viral infections, a fact confirmed in other studies associating the syndrome to the Herpes Simplex Virus and the Epstein-Baar virus.⁽⁶⁾ Despite the evidence, the results are still conflicting.

Clinical condition

ICE SD is unilateral and progressive, usually diagnosed in women between the third and fifth decades of life, and occurs almost exclusively in caucasians.(1) In general, patients seek ophthalmological care because they perceive predominantly morning visual haze due to corneal decompensation. They may also complain of constant decreased visual acuity and halos in vision due to glaucoma. Some patients seek medical care when they see changes in the shape or position of the pupils.

Clinical variations

Essential iris atrophy: characterized by atrophy and thinning of the iris stroma, causing holes throughout the iris thickness, as well as precocious formation of anterior synechia leading to pupillary distortions. In addition, there may be formation of holes by iris ischemia. In gonioscopy, anterior peripheral synechiae are present in varying degrees, which are responsible for angular closure, and consequently an increase in the IOP (intraocular pressure).

Chandler's Syndrome: in this variant, the iris changes are less pronounced, and what draws more attention to diagnosis is the corneal edema. When the diagnosis is delayed, iris abnormalities may be more pronounced and with iris holes, which generally do not permeate the entire iris thickness. Glaucoma can occur due to angle obstruction by peripheral synechiae.

Cogan-Reese Syndrome: in the third variant of the syndrome, iris atrophy can be observed; however, the presence of iris nodules is more evident. In their early stages, they are thin and yellowish, and with the progression of the disease they become brownish and increase in size. In general, they are surrounded by iris stroma with fewer crypts and the appearance of entanglement.

Differential diagnosis: although it has a characteristic appearance, ICE SD should have as differential diagnosis any condition that presents corneal edema or unilateral glaucoma in young adults, such as, for example, posterior polymorphic dystrophy, Fuchs endothelial dystrophy, Axenfeld-Rieger syndrome, iris melanoma, and inflammatory iris nodules.

Currently, the use of ultrasound biomicroscopy (UBM) may represent a useful means to detect anterior chamber angle changes, especially in the presence of corneal edema that does not allow visualization by gonioscopy.(7)

Treatment: the goal of the treatment is to prevent complications of the disease, such as corneal edema and glaucoma. Hypertonic solutions can be instilled to improve morning visual haze.

Antiglaucomatous medications are the first line of treatment; however, they can worsen the corneal edema. It is important to note that although there is still controversy regarding the role of the Herpes Simplex virus in the pathogenesis of the syndrome, it is recommended not to use prostaglandin inhibitors to reduce IOP in these patients, since these drugs are related to recurrences of infections by the same.

According to reports in the literature, the rate of IOP control failure with the use of topical medications reaches 60-80%. In these cases, a surgical management to control glaucoma is necessary. Trabeculectomy finds more satisfactory results in patients with Chandler's Syndrome. Boniuk et al. presented a series with nine cases of Chandler's syndrome, five of which underwent trabeculectomy, presenting good results despite the presence of

glaucoma not controlled by medication.(8) In some cases, there is a need for cycloablation procedures.

Patients with good control of IO but with important corneal edema can benefit from penetrating keratoplasty or even DLEK. However, neither procedure eliminates all abnormal endothelial cells, nor prevent the progression of glaucoma, not even of synechiae.

According to the clinical condition described, we observe that the changes in the eye exam are characteristic of Chandler's Syndrome, and among them: an abnormality in the endothelial mosaic with specular microscopy, diffuse corneal edema, controlled glaucoma and corectopia - a clinical condition that needs regular follow-up due to the chronic and progressive character of the disease.(8) In this syndrome, early changes can be observed in specular microscopy by means of endothelial cells of various forms and sizes, since all the endothelial mosaic is altered. This early change in the cell structure is present when only a small portion of the angle in the anterior chamber has synechiae, even before glaucoma develops.(8)

Further studies are needed to determine the incidence of the disease (previously unknown because of rarity), as well as the possible etiology. The best way of handling and treatment remains under discussion, presenting a limited prognosis until the present day.(9)

REFERENCES

1. Sitoula RP. Iridocorneal endothelial syndrome. *J Nobel Med Col.* 2015;4(1):64-5.
2. Harms C. Einseitige spontane Liickenbildung der Iris durch Atrophie ohne mechanische Zerrung. *Klinische Monatsblätter für Augenheilkunde.* 1903;41:522-8.
3. Chandler PA. Atrophy of the stroma of the iris: endothelial dystrophy, corneal edema, and glaucoma. *Am J Ophthalmol.* 1956;41(4):607-15.
4. Cogan DG, Reese AB. A syndrome of iris nodules, ectopic descemet's membrane, and unilateral glaucoma. *Doc Ophthalmol.* 1969;26:424-33.
5. Alvarado JA, Underwood JL, Green WR, Wu S, Murphy CG, Hwang DG, et al. Detection of herpes simplex viral DNA in the iridocorneal endothelial syndrome. *Arch Ophthalmol.* 1994;112(12):1601-9.
6. Tsai CS, Ritch R, Straus SE, Perry HD, Hsieh FY. Antibodies to Epstein-Barr virus in iridocorneal endothelial syndrome. *Arch Ophthalmol.* 1990;108(11):1572-6.
7. Sacchetti M, Mantelli F, Marengo M, Macchi I, Ambrosio O, Rama P. Diagnosis and Management of Iridocorneal Endothelial Syndrome. *Biomed Res Int.* 2015;2015:763093.
8. Patel A, Kenyon KR, Hirst LW, Quigley HA, Stark WJ, Meyer RF, Green WR. Clinicopathologic features of Chandler's syndrome. *Surv Ophthalmol.* 1983;27(5):327-44.
9. Phillips DL, Toral M, Alward WL. Chandler syndrome: A subtle presentation [Interne]. Feb 9, 2015. [cited 2016 Oct 10]. Available from: <http://EyeRounds.org/cases/203-chandlers.htm>.

Corresponding Author:

Carolina Tagliari Estacia
Rua Sacadura Cabral, 178 - CEP:20221-903 - Rio de Janeiro – RJ, Brazil.
E-mail: carolinatag@hotmail.com