

# Straatsma syndrome: two case reports

## *Síndrome de Straatsma: dois relatos de caso*

---

Gabriela Nogueira<sup>1</sup>, Julia Heringer<sup>1</sup>, Luiza Paulo Filho<sup>2</sup>, Nathália Raupp<sup>1</sup>, Eduardo Morizot<sup>1</sup>

### ABSTRACT

*This article reports two cases of Straatsma Syndrome, a rare disease, emphasizing its clinical features that included myopia, strabismus and amblyopia associated with persistent myelinated fibers in the retina. Ophthalmic examination, color retinography and optical coherence tomography were performed.*

**Keywords:** *Anisometropia/diagnosis; Anisometropia/etiology; Anisometropia/physiopathology; Myopia/diagnosis; Myopia/etiology; Myopia/physiopathology; Nerve fibers, myelinated/pathology; Optic nerve diseases/complications; Optic nerve diseases/diagnosis; Optic nerve diseases/physiopathology; Refraction, ocular; Visual acuity; Case reports*

### RESUMO

Este artigo relata dois casos de síndrome de Straatsma, uma doença rara, enfatizando suas características clínicas que incluem miopia, estrabismo e ambliopia associada a persistência de fibras de mielina na retina. Foram realizados exame oftalmológico, retinografia e tomografia de coerência óptica.

**Descritores:** *Anisometropia/diagnóstico; Anisometropia/etiologia; Anisometropia/fisiopatologia; Miopia/diagnóstico; Miopia/etiologia; Miopia/fisiopatologia; Fibras nervosas mielinizadas/etiologia; Fibras nervosas mielinizadas/patologia; Doenças do nervo óptico/complicações; Doenças do nervo óptico/diagnóstico; Doenças do nervo óptico/fisiopatologia; Refração ocular; Acuidade visual; Relatos de casos*

---

<sup>1</sup> Department of Ophthalmology, Instituto Benjamin Constant, Rio de Janeiro, RJ, Brazil.

<sup>2</sup> Department of Ophthalmology, Policlínica de Botafogo, Rio de Janeiro, RJ, Brazil

**Os autores declaram não haver conflito de interesses.**

Recebido para publicação em 14/05/2017 - Aceito para publicação em 17/09/2017.

## INTRODUCTION

The purpose of this study is to report two cases of Straatsma Syndrome, which is characterized by ipsilateral myopia, strabismus and amblyopia associated with persistent myelinated fibers in the retina.<sup>(1-4)</sup> Persistent myelinated fibers is a rare congenital abnormality that affects 0.3-0.6% of the population.<sup>(1)</sup> It appears as a white opaque yellowish lesion that prevents clear visualization of the retinal details.<sup>(1,2)</sup> The visual function is highly variable and will depend on the location of the fibers in the retina and visual association with other pathologies.<sup>(2,5)</sup>

The axial myopia is documented in 35-58% of patients with persistent myelinated fibers and with 83% of myopia higher than 6D.<sup>(1,4,6,7)</sup> The cause for persistent myelination fibers is unknown, but they are known to be histologically similar to oligodendrocyte cells that have been found in the histological sections of these myelinated areas.<sup>(1-3,5,7)</sup> It is believed that astrocytes located in the cribriform act as barriers, preventing the migration of oligodendrocytes to the retina during the process of myelination of the optic nerve.<sup>(1-3,7)</sup> Therapeutic options include lenses for myopia and aggressive treatment for amblyopia, but most of them have a poor visual prognosis. Two patients were diagnosed with Straatsma Syndrome. Ophthalmic examination, color retinography and optical coherence tomography were performed.

O diagnóstico da doença de Behçet pode ser difícil e por vezes atrasado, uma vez que as várias manifestações da doença,<sup>(4)</sup> podem surgir espaçadas por anos.

O envolvimento ocular ocorre em 30-70% dos doentes com Behçet, geralmente nos primeiros 2-3 anos após os sintomas iniciais da doença, apesar de, poder ser o sinal inicial da doença em 10-15%.<sup>(5)</sup>

O acometimento ocular pode ocorrer sob a forma de uveíte e em casos mais raros episclerite e queratite. A uveíte anterior é tipicamente não granulomatosa, com hipopion móvel podendo ocorrer em 1/3 dos doentes. O envolvimento do segmento posterior, mais comum no sexo masculino, é caracterizado por episódios recorrentes de vasculite retiniana oclusiva, que afeta tanto veias como artérias, vitrite e lesões de retinite.

O atingimento ocular é causa significativa de morbidade, podendo provocar cegueira em 25% dos doentes após 10 anos, apesar do tratamento.<sup>(5)</sup>

O tratamento visa o alívio dos sintomas e uma rápida resolução da inflamação, prevenindo ou limitando os danos teciduais, a frequência e gravidade dos episódios para evitar complicações.<sup>(1)</sup>

A escolha da terapêutica a utilizar faz-se de acordo com o órgão envolvido e a extensão e gravidade da doença e o melhor tratamento apenas pode ser planeado num modelo interdisciplinar.

## CASE REPORT

### Case 1

A 5-year-old Brazilian girl was examined and displayed signs of strabismus, low vision and photophobia. Normal psychomotor development for age. She has never worn glasses before. The cover-uncover test showed fixed esotropia in the left eye. Preserved extrinsic motility and isochoric and photoreactive pupils with mild leukocoria in the left eye. The visual acuity test used finger counting. The Teller test showed 3/6 in the right eye and 0.25/30 in the left eye, both at a distance of 64 centimeters. Under cycloplegia, the following refractive errors were noted: +2.00 sph - 0.50 cyl x 180 degrees in the right eye and -15.00 spherical in the left eye. The slit lamp biomicroscopy examination was normal bilaterally. Dilated

fundus examination of the right eye showed regular optical disc, preserved vessels, good macular brightness and applied retina. On the other hand, in the left eye, extensive persistence of myelin fibers affecting the superotemporal and inferotemporal regions of the macula, sparing the fovea, was found.

The patient was diagnosed with high ipsilateral myopia, strabismus, amblyopia and persistent myelinated fibers. It was prescribed -15.00 spherical glasses for the left eye and weight for the right eye, and occlusion was initiated in scheme 5:1.

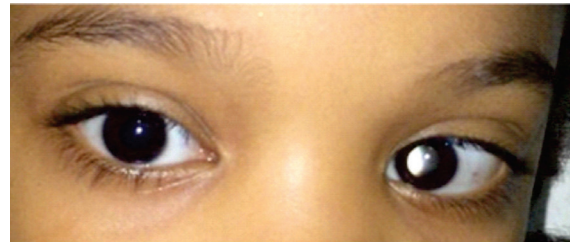

Figure 1: leukocoria left eye

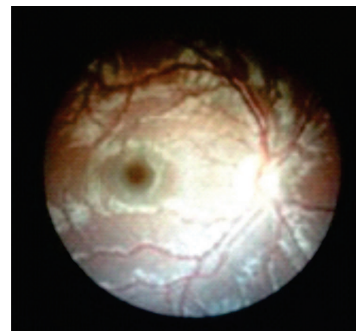

Figure 2: retinography right eye

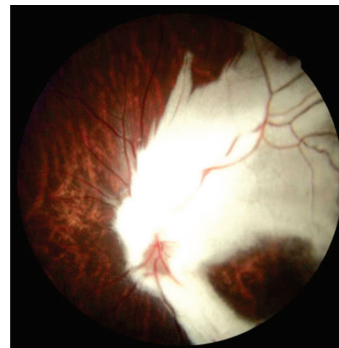


Figure 3: retinography left eye with myelin fibers

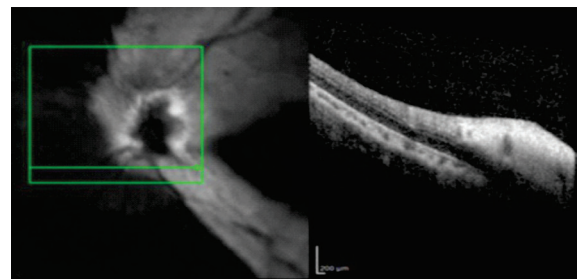


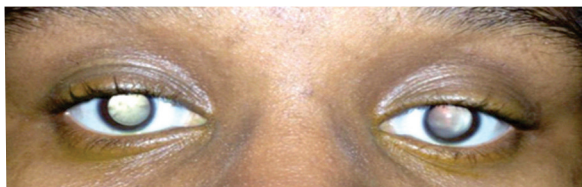Figure 4: OCT left eye

**Case 2**

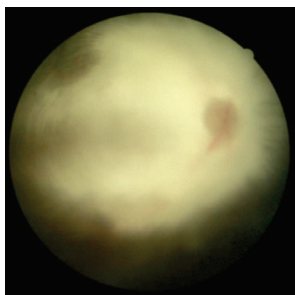
A 20-year-old Brazilian woman came to our clinic complaining of bilateral visual impairment since childhood. The cover-uncover test showed alternating esotropia. Extrinsic motility was preserved in both eyes. The visual acuity test revealed visual acuity of counting fingers in the right eye and 20/400 in the left eye. The refraction test revealed -19.50 sph -0.25 cyl 60 degrees in the right eye and -20.75 sph -3.25 cyl 30 degrees in the left eye. The slit lamp biomicroscopy examination showed leukocoria in both eyes, sutural cataract in the right eye, cortical cataract in the left eye and alterations in the red reflex in both eyes.

Dilated fundus examination revealed an optic disc of difficult evaluation with vascular thinning; opaque, nasal yellowish-white, superior and inferior temporal lesions that prevent retinal visualization, affecting the fovea.

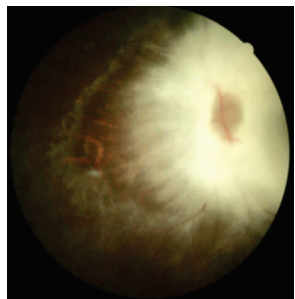The patient was diagnosed with persistent myelinated fibers, high bilateral myopia and strabismus.



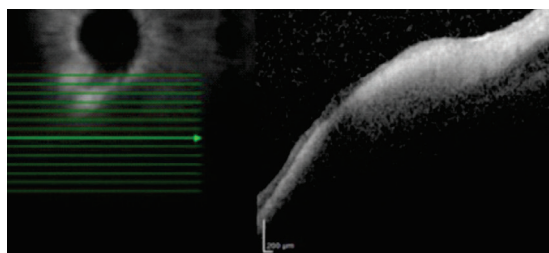
**Figure 5:** leukocoria right eye and left eye



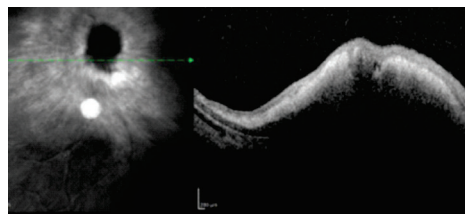
**Figure 6:** retinography right eye



**Figure 7:** retinography left eye



**Figure 8:** OCT right eye



**Figure 9:** OCT left eye

**DISCUSSION**

The diagnosis of persistent myelinated fibers of the retina is based upon clinical findings of the fundus examination, since most patients are asymptomatic.<sup>(1,2,5)</sup> It is rarely bilateral and most rarely regresses.<sup>(1)</sup> It is often associated with myopia and rarely with hypermetropia. Authors suggest that these patients' low vision has organic etiology or is associated with functional amblyopia. They believe myelination around the macula is a major cause of visual impairment and suggest that excessive myelinated fibers in glial cells prevent the transmission of light and retinal nerve impulses to the lateral geniculate nucleus, also causing axial elongation of the eye and the development of myopia. In the axial myopia, the development of cribriform plate takes longer and the myelination may continue into the optic nerve and retina. It is believed that the formation of aberrant retinal fibers is due to a failure to prevent the passage of oligodendrocyte lineages, responsible for myelination of axons in the optic nerve, the cribriform plate or the optic nerve head.<sup>(1-4)</sup> Other ocular and systemic diseases may be associated, including epiretinal membrane, vitreous hemorrhage, vascular disorders, keratoconus, coloboma, among others.<sup>(1-3,5)</sup>

Although most patients have poor visual prognosis, therapeutic options include lenses for myopia and aggressive treatment for amblyopia.<sup>(2,5,6)</sup>

The persistence of myelin fibers is considered an important differential diagnosis of leukocoria along with retinoblastoma.<sup>(5)</sup> Therefore, since Straatsma Syndrome is a rare disease that very often goes undiagnosed because its features are not widely known, it is important to include it as a possible diagnosis when examining a patient with leukocoria.

**REFERENCES**

1. Fanny Campos – Jiménez et al: Síndrome de straatsma. Caso familiar de mielinización de fibras nerviosas. Rev Mexic Oftalmol. 2014;88(1):57-60.
2. Osaguona VB, Uhumwangho OM. Myelinated retinal nerve fibers, myopia, amblyopia and strabismus. Niger Med J. 2014;55( 6):517-8.
3. Jalil N. Triad of myelinated retinal nerve fibers, axial myopia and amblyopia. J Ophthalmic Vis Res. 2010; 5(4):284-5.
4. Shenoy R, Bialasiewicz AA, Al Barwani B. Bilateral hypermetropia, myelinated retinal nerve fibres and amblyopia. Middle East Afr J Ophthalmol. 2011;18(1):65-6.
5. Daniel LF, Teresita JM. Síndrome de mielinización de fibras nerviosas retinales, miopía y ambliopía. Rev Cubana Oftalmol. 2013;26 (2):668-78.

**ERRATA**

In the scientific article “Straatsma syndrome: two case reports”, with the number of DOI 10.5935 / 0034-7280.20170055, published in the Brazilian Journal of Ophthalmology, volume 76, number 5, September / Oc-tober 2017; p. 262-4, on page 263, paragraphs 3 to 8 were incorrectly included in the text, they are not part of the scientific paper.