

# Total remission of Tolosa-Hunt Syndrome with single-dose of infliximab

## *Remissão total da Síndrome de Tolosa-Hunt com dose única de infliximabe*

Luís Armando Vitorino Alves de Souza Gondim<sup>1</sup> <https://orcid.org/0000-0001-6732-0787>

Luís Armando Gondim Guimarães Junior<sup>2</sup> <https://orcid.org/0000-0002-1347-7604>

Edmundo França Lima Júnior<sup>3</sup> <https://orcid.org/0000-0003-4150-1453>

Filipe Moreira Lima<sup>4</sup> <https://orcid.org/0000-0002-1551-1466>

Marcelo Bezerra de Melo Mendonça<sup>5</sup> <https://orcid.org/0000-0002-3998-5164>

### ABSTRACT

*Tolosa-Hunt syndrome is a painful ophthalmoplegia caused by non-specific granulomatous inflammation, corticoid-sensitive, of the cavernous sinus. The etiology is unknown. Recurrences are common. The diagnosis is made by exclusion, and a variety of other diseases involving the orbital apex, superior orbital fissure and cavernous sinus should be ruled out. This study reports a case of a 29-year-old woman, diagnosed with Tolosa-Hunt Syndrome, who presented ophthalmoparesis and orbital pain. She had poor response to corticotherapy and developed collateral effects, so she was treated with single infliximab dose immunosuppression, evolving total remission of the disease.*

**Keywords:** Tolosa-Hunt Syndrome; Ophthalmoplegia; Infliximab; Pain

### RESUMO

A Síndrome de Tolosa-Hunt é uma oftalmoplegia dolorosa causada por uma inflamação granulomatosa não específica, sensível a corticoides, do seio cavernoso. A etiologia é desconhecida. Recorrências são comuns. O diagnóstico é feito por exclusão, devendo ser descartada uma variedade de outras doenças que envolvem o ápice orbitário, fissura orbitária superior e seio cavernoso. O presente estudo trata-se de um relato de caso de uma paciente de 29 anos, diagnosticada com Síndrome de Tolosa-Hunt, que apresentou paresia e dor em região orbital. Obteve resposta pouco efetiva a corticoterapia e desenvolveu efeitos colaterais, por isso foi tratada com dose única de infliximabe, evoluindo com remissão total da doença.

**Descritores:** Síndrome de Tolosa-Hunt; Oftalmoplegia; Infliximabe; Dor

<sup>1</sup> Acadêmico de Medicina, Centro Universitário Maurício de Nassau, Recife, PE, Brasil.

<sup>2</sup> Setor de Uveíte, Serviço Oftalmológico de Pernambuco, Recife, PE, Brasil.

<sup>3</sup> Setor de Catarata, Serviço Oftalmológico de Pernambuco, Recife, PE, Brasil.

<sup>4</sup> Acadêmico de Medicina, Faculdade de Ciências Médicas de Campina Grande, Campina Grande, PB, Brasil.

<sup>5</sup> Setor de Neuro-Oftalmologia, Universidade Federal de Pernambuco, Recife, PE, Brasil.

Institution: SEOPE – Serviço Oftalmológico de Pernambuco, Recife, PE, Brasil.

**The authors declare no conflicts of interests.**

Received for publication 18/02/2019 - Accepted for publication 10/07/2019.

## INTRODUCTION

**T**olosa-Hunt Syndrome (THS) is a rare disease characterized by periorbital or hemcranial pain associated with ophthalmoplegia of one or more cranial nerves and that has a dramatic response to corticosteroid therapy.<sup>(1)</sup> Tolosa initially described the condition in 1954, and Hunt in 1961 attributed it to a stenosis of the cavernous portion of the internal carotid artery due to an idiopathic granulomatous inflammatory process.<sup>(2,3)</sup> Over the last quarter century, there has been no progress in understanding the pathogenesis of Tolosa-Hunt Syndrome.<sup>(1)</sup>

THS is a disease of unknown etiopathogenesis.<sup>(4)</sup> The most affected cranial nerves are the third (79%), sixth (45%), fourth (32%) and the fifth (25%); with involvement of multiple cranial nerves in 70% of the cases.<sup>(5)</sup>

The diagnosis for THS is based on ISH – 2004.<sup>(5)</sup>

1 - One or more episodes of unilateral orbital pain that persists for weeks without treatment.

2 - Paresis of one or more cranial nerves (III, IV or VI) and / or demonstrated granuloma of nuclear magnetic resonance or biopsy.

3 - Paresis occurs next to the beginning of the pain or appears in the following two weeks.

4 - Improvement of pain and paresis 72 hours after the start of corticotherapy.

5 - Other causes should be excluded.

The usual treatment is corticotherapy which often induces remission of the pain and parcial or total recovery of the ophthalmoparesis, but some cases do not respond to corticotherapy. Alternative therapies have been proposed, such as methotrexate, mycophenylate mofetil and radiotherapy. A recent approach is the treatment with infliximab.<sup>(6)</sup>

Infliximab is a chimeric monoclonal IgG1 antibody and tumor necrosis factor alpha (TNF- $\alpha$ ) blocker. TNF- $\alpha$  is an important proinflammatory cytokine associated with chronic inflammatory diseases. Its high activity and augmented signal producing pathways are found in inflammatory diseases where it determines the further activation of other pro-inflammatory components. Because it binds to both the soluble subunit and the membrane-bound precursor of TNF- $\alpha$  infliximab causes a disruption of the interaction of TNF- $\alpha$  with its receptors.<sup>(7)</sup>

Infliximab has demonstrated excellent efficacy in treatment of various immune diseases, including in Tolosa-Hunt Syndrome.<sup>(8)</sup>

This study reports a case of a patient with diagnostic criteria according to the International Headache Society's (IHS) for Tolosa-Hunt syndrome after exclusion of other differential diagnoses. The patient was initially treated with corticotherapy, and evolved with only partial remission of the disease. A single dose infliximab was administered and the patient evolved with total remission of the disease.

## CASE REPORT

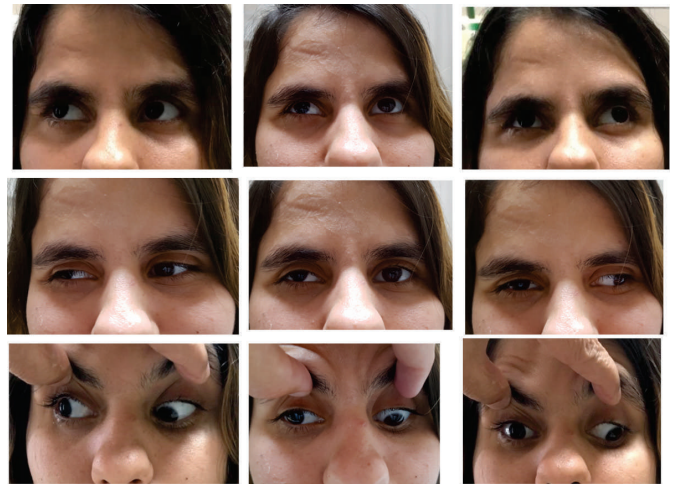R.M.L, 29 years old, went to Ophthalmological Service of Pernambuco complaining about dylopia and pain in the periorbital region of the right eye for 9 days. Physical examination revealed visual acuity 20/20 in both eyes, incomplete right oculomotor nerve paresis, paralytic mydriasis, and upper eyelid ptosis of the right eye (Figure 1). She was affected by hypertropia and excyclotortion of the right eye, "V" anisotropy, which leads to the suposition of associated involvement of the fourth

cranial nerve. Hypoesthesia in the cornea of the right eye due to involvement of the first branch of the trigeminal nerve.

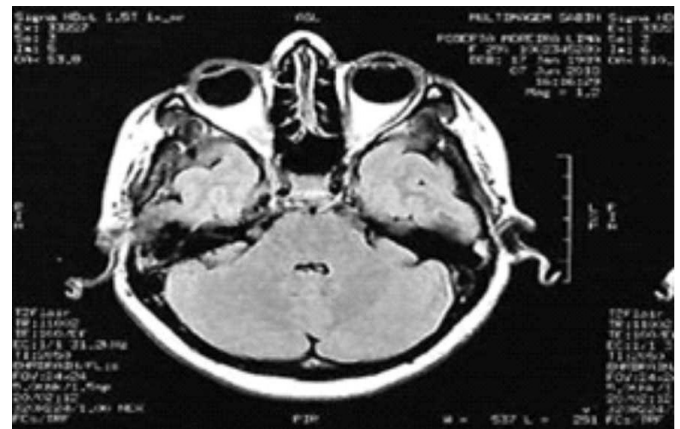
All the following laboratory exams were normal: complete blood count, VSH, PCR, fasting blood glucose, VDRL, FTA-ABS and FAN. The brain magnetic resonance imaging (Figure 2) and the intracranial vessels magnetic resonance angiography were normal (Figure 3).

The patient was treated with pulse therapy of methylprednisolone 1000mg/day for 5 days. It evolved with pain remission, mild improvement of strabismus, persisting exotropia with hypertropia of the right eye. The pulse therapy was followed by oral prednisone 60mg/day during one week and then gradually tapering of the prednisone. There was no further improvement of the dylopia and ophthalmoparesis during the following four weeks and the patient developed colateral effects to corticotherapy such as increasing bodyweight, cushingoid faces and psychic alterations.

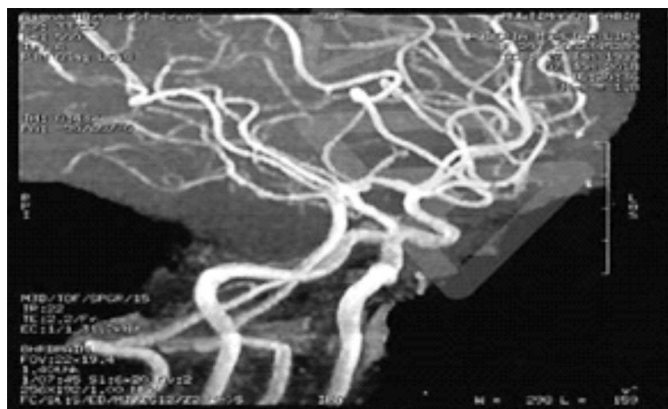
Therefore, prednisone (10mg/day at that time) was suspended and single dose infliximab 400mg was administrated. The patient evolved with rapid remission of all symptoms. Figure 4 shows complete recovering of the strabismus. Treatment was discontinued.



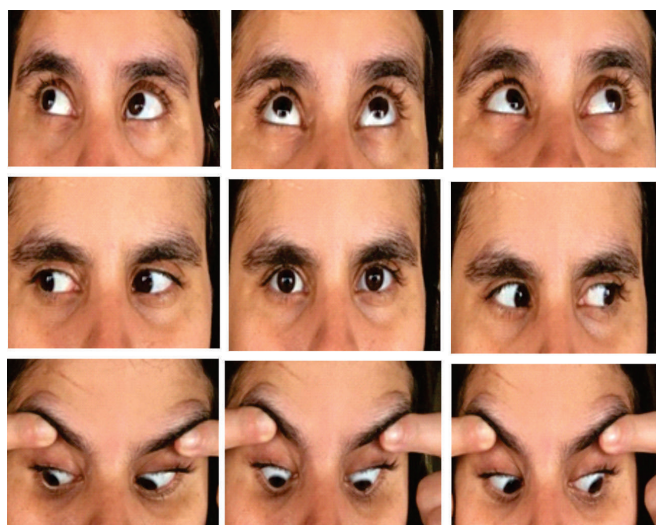
**Figure 1:** First day. Ptosis of upper lid and limitation of adduction, supraduction and infraduction of right eye.



**Figure 2:** Brain and orbits magnetic resonance. Without changes.



**Figure 3:** Intracranial vessels magnetic resonance angiography. Without changes.



**Figure 4:** One week after infliximab, total remission of the condition.

## DISCUSSION

Tolosa-Hunt is a rare syndrome that presents as an acute onset of unilateral painful ophthalmoplegia affecting cranial nerves. Although there is no predilection to gender, it can occur at any age.<sup>(9)</sup>

The syndrome follows an unpredictable course. Usually acute at first, the patient's symptoms usually last from days to weeks. Although spontaneous remissions can occur, recurrences are common, occurring in about half of the patients reported, usually within a range of months or years after the initial presentation and occasionally paralyzes of residual cranial nerves persist. The corticosteroid therapy usually changes the natural course of the disease. Although there is no conclusive evidence to show that steroids decrease the degree or duration of ophthalmoplegia, there is a dramatic reduction in pain, usually within 24 hours.<sup>(1)</sup>

All the diagnostic criteria for THS according to ISH - 2004 were filled in our case.

For diagnosis, it should be ruled out specific granulomatous diseases, such as sarcoidosis and Wegener's granulomatosis. Other differential diagnoses are shown in Table 1.<sup>(1)</sup>

**Table 1**  
**Differential diagnosis of Tolosa-Hunt syndrome**

<b>Trauma</b>	
<b>Vascular</b>	Intracavernous carotid artery aneurysm Posterior cerebral artery aneurysm Carotid-cavernous fistula Carotid-cavernous thrombosis
<b>Neoplasm</b>	Primary intracranial tumor (meningioma, pituitary adenoma, others) Chondroma Metastasis (Nasopharyngeal tumor, myeloma, others) Sarcoma
<b>Infectious</b>	Bacterial sinusitis, periostitis Viral (Herpes zoster) Fungal (Mucormycosis)
<b>Others</b>	Diabetic ophthalmoplegia Giant cell arteritis Sarcoidosis Wegener's granulomatosis Ophthalmoplegic migraine Systemic lupus erythematosus

Almost 40 years ago, Hunt first documented the beneficial effect of corticosteroid therapy on Tolosa-Hunt syndrome. Unfortunately, since then, there is little new information on optimal dosage, duration of treatment or alternative forms of therapy. It is clear that spontaneous remissions can occur, but there is no doubt that corticosteroids greatly reduce periorbital pain. There is no data available on whether treatment accelerates the recovery of associated cranial nerve palsies. Although steroids are generally decreased over weeks to months, in some cases prolonged therapy may be necessary.<sup>(1)</sup>

However, there are occasional cases of THS that do not respond adequately to steroids. Other therapies that have been applied to control THS include methotrexate, mycophenylate mofetil and radiotherapy, but these interventions are not effective in some cases.<sup>(10-12)</sup>

Infliximab has shown good efficacy against several inflammatory diseases including inflammatory bowel disease, rheumatoid arthritis and psoriasis and has been administered in about 3 million patients with these diseases.<sup>(13-15)</sup> In addition, it has also been reported to be useful in patients with Tolosa-Hunt Syndrome.<sup>(16,17)</sup>

In the present case, there was no total recovery of the ophthalmoparesis and additionally the patient developed severe colateral effects of corticotherapy. Therefore, it was decided for suspension of prednisone and administration of infliximab. After a single dose infliximab, the patient evolved with total remission of all symptoms and there was no remission of any of them until present date, after eleven months follow up.

In conclusion, infliximab is a valuable and potent option that may be considered in the management of Tolosa-Hunt patients that do not respond or do not tolerate corticotherapy.

## REFERENCES

1. Kline LB, Hoyt WF. The Tolosa-Hunt syndrome. *J Neurol Neurosurg Psychiatry*. 2001;71(5):577-82. Review.

2. Tolosa E. Periarteritic lesions of the carotid siphon with the clinical features of a carotid infraclinoidal aneurysm. *J Neurol Neurosurg Psychiatry*. 1954;17(4):300-2.
3. Hunt WE, Meagher JN, Lefever HE, Zeman W. Painful ophthalmoplegia. Its relation to indolent inflammation of the cavernous sinus. *Neurology*. 1961;11(1):56-62.
4. Monzillo PH, Saab VM, Protti GG, Costa AR, Sanvito WL. Síndrome de Tolosa-Hunt: análise de seis casos. *Arq Neuropsiquiatr*. 2005;63(3a):648-51.
5. La Mantia L, Curone M, Rapoport AM, Bussone G; International Headache Society. Tolosa-Hunt syndrome: critical literatura review based on IHS 2004 criteria. *Cephalalgia*. 2006;26(7):772-81. Review.
6. Gameiro Filho AR, Faccenda PG, Estacia CT, Correa BS, Curi I. Tolosa-Hunt Syndrome. *Rev Bras Oftalmol*. 2018;77(5):289-91.
7. Duica I, Voinea LM, Mitulescu C, Istrate S, Coman IC, Ciuluvica R. The use of biologic therapies in uveitis. *Rom J Ophthalmol*. 2018;62(2):105-13.
8. Sakurai Y, Namba K, Mizuuchi K, Nomura T, Ishida S. A case of severe panuveitis associated with psoriasis vulgaris successfully treated with infliximab. *Case Rep Ophthalmol*. 2016;7(1):191-4.
9. Singh MK, Marshall B, Hawley J. Painful ophthalmoplegia: a case of Tolosa-Hunt syndrome. *Mil Med*. 2014;179(11):1409-10.
10. Smith JR, Rosenbaum JT. A role for methotrexate in the management of non-infectious orbital inflammatory disease. *Br J Ophthalmol*. 2001;85(10):1220-4.
11. Foubert-Samier A, Sibon I, Maire JP, Tison F. Long-term cure of Tolosa-Hunt syndrome after low-dose focal radiotherapy. *Headache*. 2005;45(4):389-91.
12. Hatton MP, Rubin PA, Foster CS. Successful treatment of idiopathic orbital inflammation with mycophenolate mofetil. *Am J Ophthalmol*. 2005;140(5):916-8.
13. Hanauer SB, Feagan BG, Lichtenstein GR, Mayer LF, Schreiber S, Colombel JF, et al. Maintenance infliximab for Crohn's disease: the ACCENT I randomised trial. *Lancet*. 2002;359(9317):1541-9.
14. Gottlieb AB, Evans R, Li S, Dooley LT, Guzzo CA, Baker D, et al. Infliximab induction therapy for patients with severe plaque-type psoriasis: a randomized, double-blind, placebo-controlled trial. *J Am Acad Dermatol*. 2004;51(4):534-42.
15. Rutgeerts P, Sandborn WJ, Feagan BG, Reinisch W, Olson A, Johanns J, et al. Infliximab for induction and maintenance therapy for ulcerative colitis. *N Engl J Med*. 2005;353:2462-76.
16. Atzeni F, Doria A, Carrabba M, Turiel M, Sarzi-Puttini P. Potential target of infliximab in autoimmune and inflammatory diseases. *Autoimmun Rev*. 2007;6(8):529-36.
17. Sfikakis PP, Theodossiadis PG, Katsiari CG, Kaklamanis P, Markomichelakis NN. Effect of infliximab on sight-threatening panuveitis in Behçet's disease. *Lancet*. 2001;358(9278):295-6.

---

**Corresponding author:**

Luís Armando Vitorino Alves de Souza Gondim  
 Avenida Boa Viagem, 296 - apto. 701- Recife - PE  
 E-mail: l.armandovitorino@gmail.com