

LETTER TO THE EDITOR

PARADOXICAL REACTION DURING TREATMENT OF TUBERCULOUS BRAIN ABSCESS IN A PATIENT WITH AIDS

São Paulo, May 12, 2003

Dear Editor,

A paradoxical worsening of pre-existing lesion or an apparition of new lesions in patients with tuberculosis during appropriate antituberculous therapy has been reported since the early years of modern chemotherapy¹. Such exacerbations have been noted most commonly with lung involvement, pleural effusion, lymphadenitis, and intracranial tuberculomas⁸. In acquired immunodeficiency syndrome (AIDS)-era, paradoxical reactions are related more frequently to concurrent administration of highly active antiretroviral therapy (HAART) with antituberculous therapy³. In these patients, the time from initiation of HAART to the presentation of immune reconstitution inflammatory syndrome is very variable, occurring as few as 10 days to as long as 180 days⁷.

In a recent publication, we reported a case of tuberculous brain abscess in a woman with AIDS¹⁰. We present here her atypical outcome.

One month after she was discharged, the patient returned to us with complains of severe headache and dizziness. She was receiving HAART and antituberculous therapy one and two months ago, respectively. On this new admission, a computed tomography (CT) scan of the brain (Fig. 1C) showed worsening of the prior lesion, with marked enhancing, surrounding severe edema and shift of the midline structures. She underwent trepanation, but only necrotic material was collected and all microbiologic studies were negatives. Some possibilities such as noncompliance or drug resistance were considered. Laboratory parameters disclosed good response to HAART, with both elevation of CD4+ count (55 cells/ μ L to 110 cells/ μ L) and important reduction of viral load (160,000 copies/ μ L to < 400 cop/ μ L). Moreover, her tuberculin skin test, using purified protein derivatives (PPD), was converted from negative to positive. These findings along with the temporary association of symptoms and radiological features with initiation of therapies for tuberculosis and AIDS supported the suspicion of paradoxical reaction. Corticosteroids were started and antituberculous therapy and HAART were maintained. One month after, she was clinically better and another CT scan showed a smaller nodular lesion with residual edema (Fig. 1D).

Tuberculous brain abscess in AIDS patients is considered rare with only 9 documented cases¹⁰, including our patient. On the other hand, only one case of paradoxical emergence of tuberculous brain abscess has been described⁶. To our knowledge, the present case is the first report of transient exacerbation of a pre-existing tuberculous brain abscess in AIDS patients^{7,10}.

Paradoxical reactions with neurological symptoms in AIDS patients have been related mainly with intracranial tuberculomas which developed during treatment of tuberculous meningitis and miliary or pulmonary tuberculosis treatment⁹.

Paradoxical reaction development with involvement of the central nervous system should be considered during the concomitant use of tuberculous therapy and HAART. It may be advisable to delay the administration of HAART after the first 2 months of antituberculous treatment⁴. Although some possible mechanisms were postulated, the exact immunological basis for this transient inflammatory exacerbation remains unclear^{2,7}. Moreover, in clinical practice, some markers of immunologic recovery such as increase in the CD4+ cell count, significant reductions in viral load and convert of PPD may be helpful on the diagnosis approach^{3,4,7}.

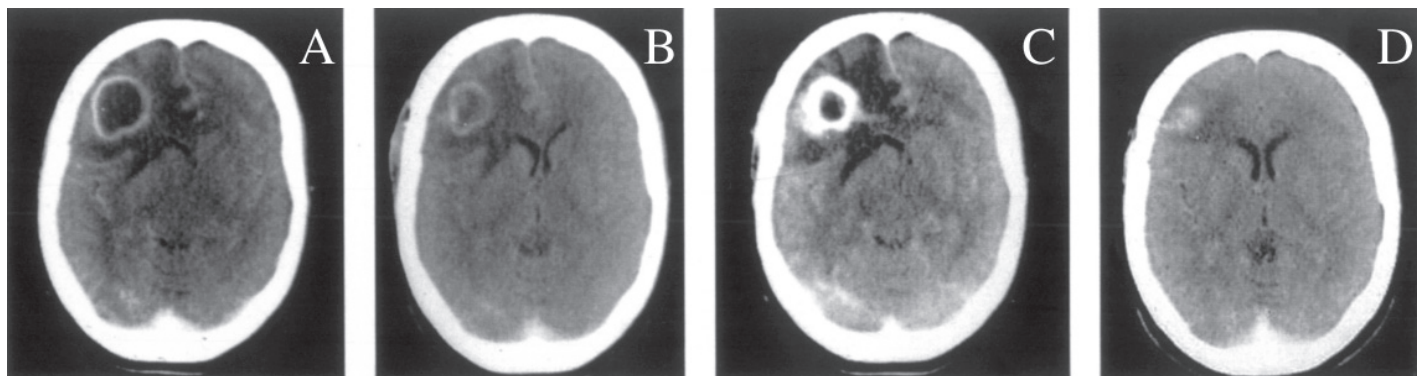


Fig. 1 - A and B were shown in the original report. A, pre-trepanation contrast CT scan showing a large abscess in the right frontal area. B, after one week of trepanation, CT scan demonstrates a marked diminution in the size of the lesion, residual enhancement and a moderate degree of edema. C, two months after trepanation, CT scan reveals worsening of the lesion, with important enhancement and a severe degree of edema. D, one month after, CT scan showing a residual nodular lesion.

Current information seems to indicate that in patients with paradoxical reactions the antituberculous and antiretroviral drugs regimens need not to be altered or discontinued^{3,4,7}. No symptomatic agent has been formally evaluated for efficacy in treating paradoxical reactions. However, if the inflammatory response has compromised central nervous system or has caused substantial systemic symptoms, anecdotal reports suggest that there may be some benefit from treatment with corticosteroids^{5,7,9}. Moreover, surgery control of raised intracranial pressure should be necessary, such as was described in paradoxical reaction associated with tuberculomas⁹. Considering the present case, the role of diagnosis surgery in patient with pre-existing tuberculous brain abscess and suspicion of paradoxical reaction remains unclear, but seems to be unnecessary.

This case report highlights the need to consider paradoxical reaction in the differential diagnosis of AIDS patients with tuberculous brain abscess and worsening of neurological symptoms. Although both longer casuistic and clinical trials are necessary to determine the most appropriate approach to treatment, the use of corticosteroids seems to be useful.

José E. VIDAL(1)
Sérgio CIMERMAN(1)
Roberta SCHIAVON NOGUEIRA(1)
Francisco BONASSER FILHO(1)
Jaques SZTAJNBOK(2)
Paula R. MARQUES DA SILVA(1)
Diogo L.M. LINS(3)
JOÃO F.G.S. COELHO(3)

(1) Departamento de Infectologia, Instituto de Infectologia Emilio Ribas, SP, Brasil.

(2) Unidade de Terapia Intensiva, Instituto de Infectologia Emilio Ribas, SP, Brasil.

(3) Departamento de Neurocirurgia, Instituto de Infectologia Emilio Ribas, SP, Brasil.

Correspondence to: Dr. José E. Vidal, Rua Capote Valente 668, Apto. 96, 05409-002 Sao Paulo, SP, Brasil.
E-mail: jbermudez@emilioribas.sp.gov.br

REFERENCES

1. CHOREMIS, C.B.; PADIATELLIS, C.; ZOUMBOULAKIS, D. & YANNAKOS, D. - Transitory exacerbation of fever and roentgenographic findings during treatment of tuberculosis in children. *Amer. Rev. Tuberc.*, 72: 527-536, 1955.
2. FIUZA DE MELO, F.A. - Reações paradoxais no tratamento da tuberculose. *Rev. Soc. bras. Med. trop.*, 35: 73-76, 2002.
3. NARITA, M.; ASHKIN, D.; HOLLENDER, E.S. & PITCHENIK, A.E. - Paradoxical worsening of tuberculosis following antiretroviral therapy in patients with AIDS. *Amer. J. resp. crit. Care Med.*, 158: 157-161, 1998.
4. NAVAS, E.; MARTIN-DAVILA, P.; MORENO, L. *et al.* - Paradoxical reactions of tuberculosis in patients with the acquired immunodeficiency syndrome who are treated with highly active antiretroviral therapy. *Arch. intern. Med.*, 162: 97-99, 2002.
5. ORLOVIC, D. & SMEGO Jr., R.A. - Paradoxical tuberculous reactions in HIV-infected patients. *Int. J. Tuberc. Lung Dis.*, 5: 370-375, 2001.
6. SEIJO-MARTINEZ, M.; DIZ-AREN, J.; CASTRO-DEL RIO, M.; VILADRICH, A. & GONZALES-CARRERO, J. - Aparición paradójica de tuberculoma y formación de absceso cerebeloso en un paciente con el virus de la inmunodeficiencia humana tratado con triple terapia antiretroviral. *Rev. Neurol.*, 31: 697-698, 2000.
7. SHELBURNE III, S.A.; HAMILL, R.J.; RODRÍGUEZ-BARRADAS M.C. *et al.* - Immune reconstitution inflammatory syndrome: emergence of a unique syndrome during highly active antiretroviral therapy. *Medicine (Baltimore)*, 81: 213-227, 2002.
8. SMITH, H. - Paradoxical responses during the chemotherapy of tuberculosis. *J. Infect.*, 15: 1-3, 1987.
9. TEOH, R.; HUMPHRIES, M.J. & O'MAHONY, G. - Symptomatic intracranial tuberculoma developing during treatment of tuberculosis: a report of 10 patients and review of the literature. *Quart. J. Med.*, 63: 449-460, 1987.
10. VIDAL, J.E.; CIMERMAN, S.; MARQUES DA SILVA, P.R. *et al.* - Tuberculous brain abscess in a patient with AIDS: case report and literature review. *Rev. Inst. Med. trop. S. Paulo*, 45: 111-114, 2003.