

## CASE REPORT

# *Rhipicephalus sanguineus* (ACARI: IXODIDAE) BITING A HUMAN BEING IN PORTO ALEGRE CITY, RIO GRANDE DO SUL, BRAZIL

Márcia Bohrer MENTZ(1), Marcelo TROMBKA(2) Guilherme Liberato da SILVA(1,3) & Carlos Eugênio SILVA(1)

## SUMMARY

We report the finding of a female brown dog tick, *Rhipicephalus sanguineus* (Acari: Ixodidae) on the scalp of a male patient in Porto Alegre, Rio Grande do Sul, Brazil. Human parasitism by this tick is rare and has seldomly been reported in the literature, despite its recognized importance since it can act as a vector of *Rickettsia rickettsii*, the agent of spotted fever.

**KEYWORDS:** Brown dog tick; Diagnosis; Ectoparasite; Vector-borne diseases.

## INTRODUCTION

The brown dog tick (or kennel tick) *Rhipicephalus sanguineus* (Latreille, 1806) (Acari: Ixodidae) has great medical and veterinary significance, since it is a vector and reservoir of many human and animal pathogens<sup>1-5</sup>. Dogs are the main hosts of the adult and pre-adult parasitic stages of the tick. Adults of *R. sanguineus* can also feed on humans and many other mammals, such as goats, sheep, cattle, horses, wild carnivores, cats, hares and hedgehogs; pre-adult ticks have been found in shrews and many rodents<sup>6-11</sup>.

The genus *Rhipicephalus* comprises 17 species that are morphologically similar and show intraspecific variations within populations whose taxonomic status is still uncertain<sup>12</sup>. Nowadays, the molecular approach is used to investigate differences among the species of the *R. sanguineus* complex<sup>13-15</sup>.

Although human parasitism by *R. sanguineus* is unusual, it has already been reported in different parts of the world<sup>16-22</sup>. In Brazil, the first description of human parasitism by this species of ixodid tick was reported in 2005<sup>23</sup>. Other cases have been recorded ever since in the country<sup>24-27</sup>.

The ability of *R. sanguineus* to transmit pathogens such as *Rickettsia rickettsii*, the agent of Rocky Mountain spotted fever, known in Brazil as Brazilian spotted fever (BSF), to humans is little understood<sup>28-33</sup>. On the other hand, infestation by *Rhipicephalus sanguineus* (Latreille) in dogs has increased considerably in urban areas of the State of Rio Grande do Sul<sup>34-36</sup>.

Here, we report the finding of an adult female of *R. sanguineus* on the scalp of an adult male patient in the city of Porto Alegre, Rio Grande do Sul, Brazil.

## CASE REPORT

A 27-year-old male presented with bilateral erythematous macular inflammatory lesions, with a central bite spot, on the posterior region of the thigh (Fig. 1A). The lesions healed spontaneously. A week later, he reported other, similar lesions and minor allergic reactions including redness and swelling in the right ear (Fig. 1B), face (Fig. 1C), right thigh (Fig. 1D), neck, and right hand. Some days later, the patient found a tick on his scalp. He consulted a physician, and no other remarkable findings were seen. Based on the skin lesions and the presence of the tick, serology tests for *Rickettsia* and *Borrelia* were requested, and a presumptive treatment for rickettsia with doxycycline for 21 days was started. The serology tests were negative.

While awaiting the serological results, the patient sent the tick specimen to the Parasitology Laboratory at ICBS-UFRGS for identification. The tick was identified as a female brown dog tick, *Rhipicephalus sanguineus* (Fig. 2A, B), based on the characteristics described by Guimarães *et al.*<sup>37</sup> The patient has improved and remains asymptomatic.

## DISCUSSION

Dantas-Torres & Otranto<sup>6</sup> stated that some populations presently assigned to *R. sanguineus* in different parts of the world could belong

(1) Universidade Federal do Rio Grande do Sul (DEMIP/ICBS-UFRGS), Departamento de Microbiologia, Imunologia e Parasitologia do Instituto de Ciências Básicas da Saúde. Porto Alegre, Brasil.

(2) Hospital de Clínicas de Porto Alegre, Serviço de Neurologia. Porto Alegre, Rio Grande do Sul, Brasil.

(3) Museu de Ciências Naturais (UNIVATES). Laboratório de Acarologia, Centro Universitário. Lajeado, RS, Brasil.

**Correspondence to:** Dr. Márcia Bohrer Mentz, Universidade Federal do Rio Grande do Sul, Departamento de Microbiologia, Parasitologia e Imunologia. Rua Sarmento Leite 500 Farroupilha 90050-170 Porto Alegre, Rio Grande do Sul, Brasil. Fone: 55 51 33084545. Fax: 55 51 33163445. E-mail: mbmentz@gmail.com

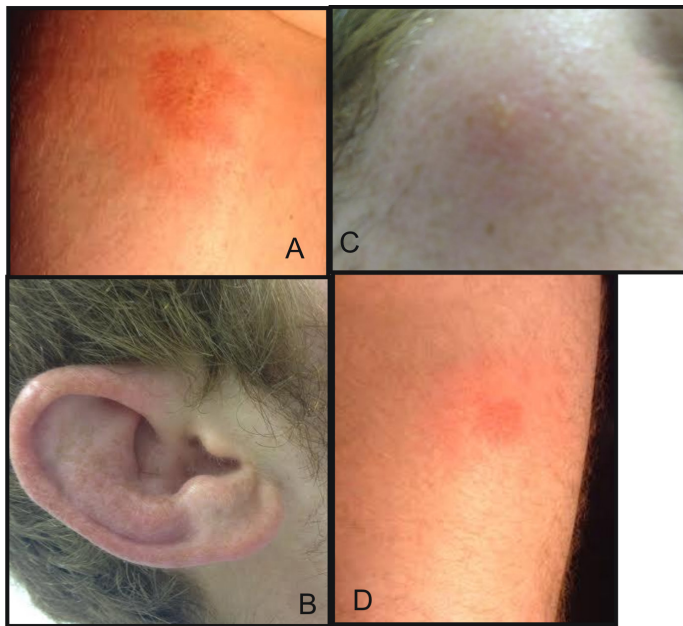


Fig. 1 - A. The patient's skin lesions in the posterior area of the thigh; B. Right ear; C. Face; D. Right thigh.




Fig. 2 - *Rhipicephalus sanguineus*: FEMALE – A. Dorsal view; B. Ventral view.

to different species, and that this possibility may have been overlooked by taxonomists. However, it is also possible that this wide geographical distribution can be attributed to the adaptability of this tick species to different hosts and climate conditions.

Borsoi & Serra-Freire<sup>28</sup> found that *R. sanguineus* was the dominant species in some communities in the State of *Rio de Janeiro*. People in daily contact with dogs parasitized by *R. sanguineus* could be included in the risk group for this type of parasitism<sup>24,25</sup>. These conditions could increase the risk of transmission of *R. rickettsii* to humans in Brazil. Future studies are needed to determine the incidence of *R. rickettsii* in local populations of *R. sanguineus*<sup>29,30,39</sup>.

Information on human parasitism by *R. sanguineus* in Brazil is sparse. In 2005, Dantas-Torres *et al.*<sup>23</sup> provided the first, brief description of human parasitism by this species of tick in Brazil. In the following

year, Dantas-Torres *et al.*<sup>24</sup> investigated the species of ectoparasites in domestic dogs from the metropolitan region of *Recife, Pernambuco* State, and reported that four dog owners were found to be parasitized by ticks identified as *R. sanguineus*. These were the first four cases of human parasitism by this tick species in Brazil. Louly *et al.*<sup>25</sup> described the first case of human parasitism by *R. sanguineus* in the State of *Goiás*.

Several species of ticks are vectors of viruses, protozoa and rickettsia that cause human diseases<sup>4,30,40</sup>. This reinforces the need to increase the knowledge of the parasitic relationship between ticks and humans, as well as for the continuous implementation of control measures against this parasite<sup>17,29,31,32,41</sup>.

In Brazil, a detailed study of the factors leading to human parasitism by ticks is needed, since most studies until now have examined only the species distribution and occurrence.

Brazilian spotted fever (BSF) is an infectious, febrile, and acute disease, with variable severity, which usually has an endemic character. This disease can be difficult to diagnose, especially in the early stages. Because it is multi-systemic, spotted fever can follow different clinical courses, ranging from the classical picture to atypical forms without exanthema. If not treated properly, mortality in the most severe cases reaches 80%<sup>38</sup>.

This is the first report of a *R. sanguineus* tick biting a human being in *Porto Alegre*. In the case reported here, we presume, based on the skin lesions seen in the patient, that the female tick made several attempts to attach without success.

The public-health authorities must evaluate the incidence of *R. sanguineus* in dogs from urban areas, improving the monitoring of the distribution of these dogs and their contact with humans<sup>34</sup>. Future control attempts must consider the limited knowledge of the tick behavior and other biological parameters in the State of *Rio Grande do Sul*.

## REFERENCES

1. Coutinho MTZ, Bueno LL, Sterzik A, Fujiwara RT, Botelho JR, Maria M, et al. Participation of *Rhipicephalus sanguineus* (Acari: Ixodidae) in the epidemiology of canine visceral leishmaniasis. *Vet Parasitol*. 2005;128:149-55.
2. Dantas-Torres F. Biology and ecology of the brown dog tick, *Rhipicephalus sanguineus*. *Parasit Vectors*. 2010;3:26.
3. Montandon CE, Yoshinari NH, Milagres BS, Mazzioli R, Gomes GG, Moreira HN, et al. Evidence of *Borrelia* in wild and domestic mammals from the state of Minas Gerais, Brazil. *Rev Bras Parasitol Vet*. 2014;23:287-90.
4. Parola P, Raoult D. Ticks and tickborne bacterial diseases in humans: an emerging infectious threat. *Clin Infect Dis*. 2001;32:897-928.
5. Uspensky I, Ioffe-Uspensky I. The dog factor in brown dog tick *Rhipicephalus sanguineus* (Acari: Ixodidae) infestations in and near human dwellings. *Int J Med Microbiol*. 2002; 291Suppl 33:156-63.
6. Dantas-Torres F, Otranto D. Further thoughts on the taxonomy and vector role of *Rhipicephalus sanguineus* group ticks. *Vet Parasitol*. 2015;208:9-13.
7. Filippova NA. Ixodid ticks of the subfamily Amblyomminae. Arachnoidea 4(5). Fauna of Russia and neighbouring countries. St. Petersburg: Nauka Publishing House; 1997.

8. Irshad N, Qayyum M. Prevalence of tick infestation and theileriosis in sheep and goats. *Pakistan Vet J*. 2010;30:178-80.
9. Labruna MB. Biologia-ecologia de *Rhipicephalus sanguineus* (Acari: Ixodidae). *Rev Bras Parasitol Vet*. 2004;13(Supl 1):123-4.
10. Telford SR 3rd, Goethert HK. Emerging tick-borne infections: rediscovered and better characterized, or truly "new"? *Parasitology*. 2004;129 Suppl:S301-27.
11. Walker JB, Keirans JE, Horak IG. The genus *Rhipicephalus* (Acari: Ixodidae). A guide to the brown ticks of the world. Cambridge: Cambridge University Press; 2000.
12. Nava S, Estrada-Peña A, Petney T, Beati L, Labruna MB, Szabó MP, et al. The taxonomic status of *Rhipicephalus sanguineus* (Latreille, 1806). *Vet Parasitol*. 2015; 208:2-8.
13. Burlini L, Teixeira KR, Szabó MP, Farnadas KM. Molecular dissimilarities of *Rhipicephalus sanguineus* (Acari: Ixodidae) in Brazil and its relation with samples throughout the world: is there a geographical pattern? *Exp Appl Acarol*. 2010;50:361-74.
14. Nava S, Mastropaolo M, Venzal JM, Mangold AJ, Guglielme AA. Mitochondrial DNA analysis of *Rhipicephalus sanguineus* sensu lato (Acari: Ixodidae) in the Southern Cone of South America. *Vet Parasitol*. 2012;21:547-55.
15. Zahler M, Filippova NA, Morel PC, Gothe R, Rinder H. Relationships between species of the *Rhipicephalus sanguineus* group: a molecular approach. *J Parasitol*. 1997; 83:302-6.
16. Carpenter TL, McMeans MC, McHugh CP. Additional instances of human parasitism by the brown dog tick (Acarina: Ixodidae). *J Med Entomol*. 1990;27:1065-6.
17. Dipeolu OO, Akinboade OA, Ogunji FO. Observations on the epidemiology of house infesting *Rhipicephalus sanguineus* in a household in Lagos, Nigeria. *Bull Anim Health Prod Afr*. 1982;30:29-30.
18. Estrada-Peña A, Jongejan F. Ticks feeding on humans: a review of records on human-biting Ixodoidea with special reference to pathogen transmission. *Exp Appl Acarol*. 1999;23:685-715.
19. Goddard J. Focus of human parasitism by the brown dog tick, *Rhipicephalus sanguineus* (Acari: Ixodidae). *J Med Entomol*. 1989;26:628-9.
20. Harrison BA, Engber BR, Apperson CS. Ticks (Acari: Ixodida) uncommonly found biting humans in North Carolina. *J Vector Ecol*. 1997;22:6-12.
21. Mihalca AD, Kalmár Z, Dumitrache MO. *Rhipicephalus rossicus*, a neglected tick at the margin of Europe: a review of its distribution, ecology and medical importance. *Med Vet Entomol*. 2015;29:215-24.
22. Serra-Freire NM. Parasitismo humano por carrapatos: a necessidade de transformação do paradigma diagnóstico. *Rev Vetores Pragas*. 2009;22:23-7.
23. Dantas-Torres F, Figueredo LA, Brandão-Filho SP. Primeira descrição de parasitismo humano por *Rhipicephalus sanguineus* (Acari: Ixodidae) no Brasil. *Rev Soc Bras Med Trop*. 2005;38 Supl 1:411-2.
24. Dantas-Torres F, Figueredo LA, Brandão-Filho SP. *Rhipicephalus sanguineus* (Acari: Ixodidae), the brown dog tick, parasitizing humans in Brazil. *Rev Inst Med Trop Sao Paulo*. 2006;39:64-7.
25. Louly CCB, Fonseca IN, Oliveira VF, Borges LMF. Ocorrência de *Rhipicephalus sanguineus* em trabalhadores de clínicas veterinárias e canis, no município de Goiânia, GO. *Cienc Anim Bras*. 2006;7:103-6.
26. Serra-Freire NM. Occurrence of ticks (Acari: Ixodidae) on human hosts, in three municipalities in the State of Pará, Brazil. *Rev Bras Parasitol Vet*. 2010;19:141-7.
27. Serra-Freire NM, Sena LMM, Borsoi ABP. Parasitismo humano por carrapatos na Mata Atlântica, Rio de Janeiro, Brasil. *Rev Entomo-Brasilis*. 2011;4:67-72.
28. Borsoi ABP, Serra-Freire NM. Relações parasitárias entre humanos e carrapatos no município de Volta Redonda, Estado do Rio de Janeiro. *Rev UNIABEU*. 2012;5:306-17.
29. Demma LJ, Traeger MS, Nicholson WL, Paddock CD, Blau DM, Eremeeva ME, et al. Rocky Mountain spotted fever from an unexpected tick vector in Arizona. *N Engl J Med*. 2005;353:587-94.
30. Labruna MB. Ecology of rickettsia in South America. *Ann N Y Acad Sci*. 2009; 1166:156-66.
31. Pereira MC, Labruna MB. Febre maculosa: aspectos clínicos epidemiológicos. *Rev Clin Vet*. 1998;12:19-23.
32. Lemos ERS, Machado RD, Pires FDA, Machado SL, Costa LMC, Coura JL. Rickettsiae infected ticks in an endemic area of spotted fever in the State of Minas Gerais, Brazil. *Mem Inst Oswaldo Cruz*. 1997;92:477-81.
33. Rozental T, Bustamante MC, Amorim M, Serra-Freire NM, Lemos ER. Evidence of spotted fever group rickettsiae in state of Rio de Janeiro, Brazil. *Rev Inst Med Trop Sao Paulo*. 2002;44:155-8.
34. Aguiar CLG, Pinto DM, Pappen FG, da Cunha Filho NA, dos Santos TRB, Farias NAR. Parâmetros da fase de vida livre de *Rhipicephalus sanguineus* (Latreille, 1806) (Acari: Ixodidae): adaptado ao clima subtropical. *Arq Inst Biol Sao Paulo*. 2013;80: 375-80.
35. Evans DE, Martins JR, Guglielme AA. A review of the ticks (Acari: Ixodida) of Brazil, their hosts and geographic distribution - 1. The State of Rio Grande do Sul, Southern Brazil. *Mem Inst Oswaldo Cruz*. 2000;95:453-70.
36. Ribeiro VLS, Weber MA, Fetzler LO, Vargas CRB. Espécies e prevalência das infestações por carrapatos em cães de rua da cidade de Porto Alegre, RS, Brasil. *Cienc Rural*. 1997;27:285-9.
37. Guimarães JH, Tucci EC, Barros-Battesti DM. Ectoparasitos de importância veterinária. São Paulo: Ed. Plêiade/FAPESP; 2001.
38. Dantas-Torres F. Rocky Mountain spotted fever. *Lancet Infect Dis*. 2007;7:724-32.
39. Serra-Freire NM. Doenças causadas por carrapatos. In: Marcondes CB. Doenças transmitidas e causadas por artrópodes. São Paulo: Atheneu; 2009. p. 377-402.
40. Gilot B, Laforge ML, Pichot J, Raoult D. Relationships between the *Rhipicephalus sanguineus* complex ecology and Mediterranean spotted fever epidemiology in France. *Eur J Epidemiol*. 1990;6:357-62.
41. Serra-Freire NM, Pinto C. Vetores de riquetsias do Grupo Febre Maculosa na região metropolitana de Campinas, Estado de São Paulo: prevalência e risco de transmissão. *Rev Bras Med Vet*. 2008;30:254-9.

Received: 25 May 2015

Accepted: 28 September 2015