

Hantavirus pulmonary syndrome in children: case report and case series from an endemic area of Brazil

Ana Cláudia Pereira Terças-Trettel^{1,2}, Alba Valéria Gomes de Melo³, Sandra Mara Fernandes Bonilha³, Josdemar Muniz de Moraes⁴, Renata Carvalho de Oliveira⁵, Alexandro Guterres⁵, Jorlan Fernandes⁵, Marina Atanaka², Mariano Martinez Espinosa², Luciana Sampaio⁶, Sumako Kinoshieta Ueda^{7,*}, Elba Regina Sampaio de Lemos⁵

ABSTRACT

Hantavirus Cardiopulmonary Syndrome (HCPS) is an important emergent zoonosis associated with wild rodents in Brazil, where this viral infection in children is generally rare. We present HCPS in a child from the Pantanal Biome and a review of all reported pediatric cases in Mato Grosso State, an endemic area for HCPS in Brazil. The investigation used the Information System for Notifiable Diseases database (SINAN). A 12-year-old boy was hospitalized with fever and respiratory failure and hantavirus IgM and IgG antibodies were detected by ELISA in serum samples. During the period of 1999 to 2016, 32 HCPS pediatric cases confirmed by serology were reported to SINAN with a mortality rate of 34.4%. The possibility of hantavirus infection in children with acute febrile illness associated with respiratory failure should be considered mainly in recognized endemic areas as Mato Grosso State, contradicting a hypothesis that children are more protected from lung involvement.

KEYWORDS: Hantavirus infections. Hantavirus pulmonary syndrome. Children. Febrile acute respiratory failure.

INTRODUCTION

Hantaviruses are emerging viral diseases. Their onset is acute and severe, with a wide spectrum of clinical manifestations that have recently been grouped in two clinical syndromes: hemorrhagic fever with renal syndrome (HFRS), which is endemic in Europe and Asia and hantavirus cardiopulmonary syndrome (HCPS), which typically manifests in the Americas¹⁻⁴.

HCPS is present throughout America, with predominant clinical manifestations in young men living in rural areas⁵⁻¹⁰. From 1993 to 2018, Brazil has confirmed 2,080 cases of HCPS and Mato Grosso State ranks third in incidence, with 307 confirmed cases¹¹.

Cases involving children are rare and are below the overall incidence rates. In the first report of hantavirus infection confirmed by serology, a four-year-old child and her mother were infected in New Mexico in 1993. There was a high seroprevalence to hantavirus associated with rodents caught in the probable site of infection (36.6%)¹². In Europe and Asia, the incidence of hantaviruses in children is sporadic. After the first report in Greece, which was associated with pediatric nephropathy in 1997, other cases were registered¹³⁻¹⁵. As for HCPS, isolated cases in children and

¹Universidade do Estado de Mato Grosso, Tangará da Serra, Mato Grosso, Brazil

²Universidade Federal de Mato Grosso, Instituto de Saúde Coletiva, Cuiabá, Mato Grosso, Brazil

³Secretaria Municipal de Saúde de Cáceres, Mato Grosso, Brazil

⁴Secretaria de Estado de Saúde de Mato Grosso, Cuiabá, Mato Grosso, Brazil

⁵Instituto Oswaldo Cruz, Laboratório de Hantavírus e Ricktesioses, Rio de Janeiro, Rio de Janeiro, Brazil

⁶Hospital Regional de Cáceres Dr. Antônio Fontes, Cáceres, Mato Grosso, Brazil

⁷Secretaria de Estado de Saúde de Mato Grosso, Laboratório Público Central, Cuiabá, Mato Grosso, Brazil

*In Memoriam

Correspondence to: Ana Cláudia Pereira Terças-Trettel
Universidade do Estado de Mato Grosso, Campus de Tangará da Serra, MT358, s/n, Jardim Universitário, CEP 78300-000, Tangará da Serra, MT, Brazil
Tel: +55 65 99967-5203

E-mail: ana.claudia@unemat.br

Received: 21 March 2019

Accepted: 4 July 2019

adolescents have been reported in North America, where most infections probably occurred at home¹⁶⁻¹⁹.

Although HCPS cases in children and adolescents are infrequent, the reports in the literature showed similarities of clinical manifestations when compared to those in adult patients. A review from the United States, published by Ramos *et al.*²⁰, demonstrated the prevalence of hantaviruses in female children and adolescents, with a mortality of 33%. Later, in a similar study, five HCPS cases in children aged six to 14 years old were confirmed²¹. Although no more details were reported, it is noteworthy that these two American children developed HCPS after been bitten by an infected rodent²².

In South America, the first reports of HCPS in children occurred in Argentina, where five individuals with ages between five and 11 years old were identified, with a mortality rate of 60%²³. In Brazil, there were occasional reports, with a few cases in Santa Catarina State, none of which resulted in death²⁴. In Bahia State, a study was conducted in children under 14 years old and a seroprevalence of 13.2% was identified using the *Haantan* antigen, increasing the suspicion of the presence of the Seoul genotype, an old world hantavirus in Brazilian territory²⁵.

Despite being an emerging disease of great importance to public health, children's exposure to specific vulnerabilities leading to hantavirus infection has not been addressed. Thus, while hantavirus cases in children may occur in isolation, it is necessary to consider the possibility of simultaneous infections involving family members that have also been exposed to infected rodents²⁶.

The objective of this report is to describe the first cases in children from the Pantanal Biome and the profile of HCPS in children in Mato Grosso State, Brazil, from 1999 to 2018.

MATERIALS AND METHODS

Case report

This is a report of a HCPS case in a child treated in a public hospital in the city of Cáceres, Mato Grosso State, in March 2016. This State has a geographic area of 903,357.908 km² with a population of 3,033,991 inhabitants and 141 cities, as reported in 2010. There were 27 reported cases of HCPS in children until 2018, ranking the state as third in number of registered HCPS human cases (N = 307)¹¹. Its climate is tropical, hot and relatively humid, with an annual rainfall of 1,700 mm and temperatures ranging from 24 °C to 40 °C. It has typical vegetation of the Pantanal.

Cáceres is a satellite city of great importance to the State, as it has a river port. In addition, it has a milder climate

compared to the rest of the State due to the characteristics of the Pantanal Biome; its main economic activity is livestock (Figure 1).

Study of a series of cases of Hantavirus Pulmonary Syndrome in children

Secondary data of HCPS cases in children in the Mato Grosso State, confirmed from 1999 to 2018, were analyzed to describe their clinical-epidemiologic profile. The data were collected in 2018 by two investigators who consulted document file data (reporting forms) of the technical area of hantavirus from the State Department of Health of Mato Grosso State. The chosen cases were the records of children younger than 14 years, with Mato Grosso State as the probable location of infection.

The records of this study consisted of 32 reporting forms of HCPS cases with specific positive serology (IgM), corresponding to all registered cases in children, in Mato Grosso State. In addition to clinical and laboratory data, information on the place of residence, probable site of infection, history of contact with rodents and other epidemiologic data were also analyzed.

Collected data

The collected data were entered twice and then compared to avoid database discrepancies. After conference, they were digitized and entered into spreadsheets to be analyzed using SPSS, version 20.0 (IBM, New York, USA). The results consisted of tables and figures showing the distribution of relative and absolute frequencies. The map was constructed using Terra View 3.14 (INPE, Brasília, Brasil) for the spatial location of the cases.

The study was approved by the Research Ethics Committee of the University Hospital Julio Muller, Federal University of Mato Grosso, under the protocol N° 965/CEP-HUJM/2010.

RESULTS

Case report

On March 4th, 2016, a 12-year-old male, resident in the city of Cáceres (16°04'33.3''S and 57°40'02.6''W) was admitted to the emergency department of the Regional Hospital with an acute febrile illness associated with dyspnea, cyanosis, blood pressure of 110 x 50 mmHg and 75% oxygen saturation in room air. On admission, the parents reported that the respiratory symptoms had started that day and that the child has been treated with valproic

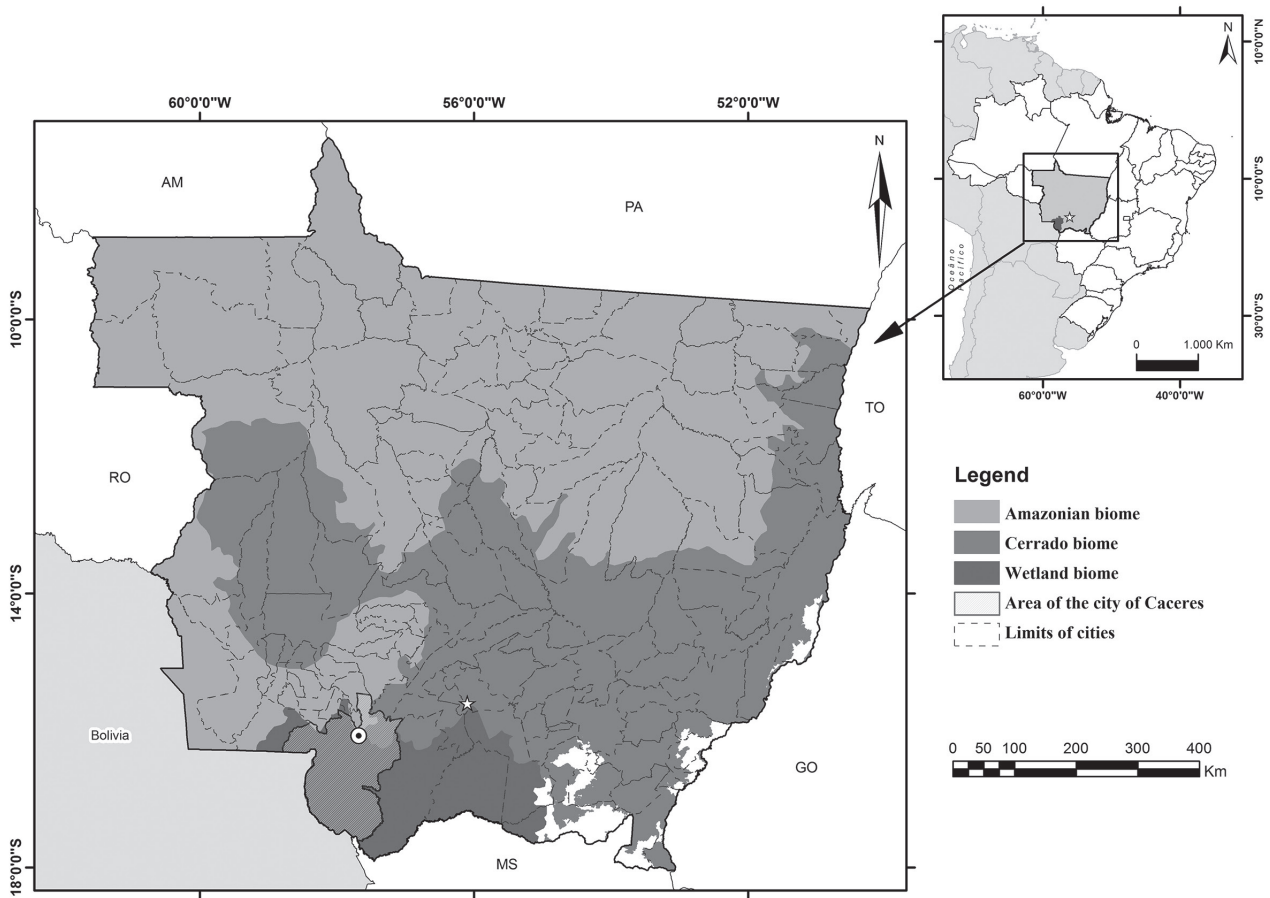


Figure 1 – Brazilian biomes and the geographic location of Cáceres, Mato Grosso State, 2018.

acid (500 mg) for seizures. The results of the requested nonspecific tests showed the following results: hematocrit of 38.6%, leukocytosis (18,900k/mm³) and hyperglycemia (170 mg/dL) (Table 1).

Following the worsening of dyspnea and oxygen saturation (62%), associated with the presence of a diffuse pulmonary infiltrate on the chest radiography, the patient was transferred to the Intensive Care Unity (ICU) where he was sedated and placed on mechanical ventilation. Empiric antibiotic therapy with ceftriaxone and oxacillin was started due to hypothesis of community acquired pneumonia.

The rapid development of a diffuse pulmonary infiltrate increased the possibility of HCPS infection (Figure 2) and blood samples were collected for diagnostic confirmation. After being extubated on the sixth day of hospitalization, the patient was transferred to the pediatric unit and was posteriorly discharged from hospital on March 15th, 2016.

Acute-phase (03/04/2016) and convalescent-phase serum samples (03/23/2016 and 04/20/2016) were evaluated by an enzymatic immunoassay for IgM and IgG anti-hantavirus detection²⁷. Serum samples collected on day one and 19 of illness were IgM reactive (OD 1,579

Table 1 - Laboratory results of the child with HCPS in the Pantanal region of Mato Grosso State, Brazil

Laboratory Exam	03/04/2016	03/06/2016	03/08/2016	03/10/2016
Hematocrit	38.6%	31.0%	29.7%	32.0%
Leukocytes	18.900 k/mm ³	11.600 k/mm ³	10.800 k/mm ³	11.000 k/mm ³
Platelets	353.000 k/mm ³	291.000 k/mm ³	141.000 k/mm ³	415.000 k/mm ³
Lactate	4.5 nmol/L	1.7 nmol/L	1.1 nmol/L	0.7 nmol/L
Creatinine	0.40 mg/dL	0.50 mg/dL	0.40 mg/dL	0.40 mg/dL
Urea	27.0 mg/dL	27.4 mg/dL	36.8 mg/dL	36.0 mg/dL
Glucose	170 mg/dL	100 mg/dL	115 mg/dL	125 mg/dL

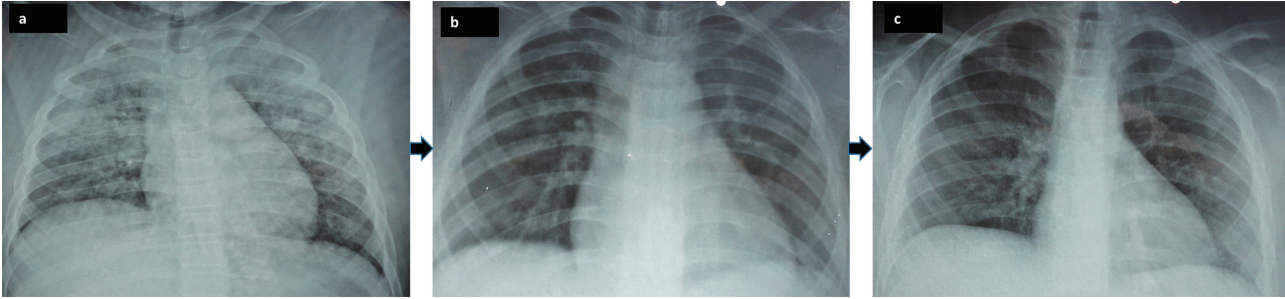


Figure 2 – The evolution of chest X-rays in the child with HCPS during hospitalization in the intensive care unit, in the Pantanal region of Mato Grosso State, 2016. A) Admission – the chest X-ray revealed the presence of a diffuse bilateral pulmonary infiltrate – March 4, 2016; B) Six days after the onset of illness – March 10, 2016; C) Eleven days after the onset of illness – March 15, 2016.

and OD 1,153), whereas the third blood sample was only reactive for IgG antibodies (OD 1,410). Molecular analysis (RT-PCR), described by Guterres *et al.*²⁸ and Tao *et al.*²⁹ was performed with the first two blood samples, but results were negative.

During the epidemiologic investigation, it was verified that the child lived with his parents in an urban area, had no history of leaving the area within 60 days prior to onset of symptoms and, as a carrier of an unidentified syndrome characterized by reduced cognition, he had a continued monitoring of his activities. Although there was no evidence of high-risk conditions associated with rural or wild environment contact, a small farm near the house and uninhabited areas covered by grass 300 meters away from the child's residence were identified. In the patient's residence, the parents reported the presence of domestic animals and a chicken coop, where the child used to feed the animals. His father has also indicated that his son accompanies him to work in a deposit of the local market where rodents are frequently seen.

Study of a series of cases with the Hantavirus Pulmonary Syndrome in children

Since the first registered cases in Mato Grosso in 1999, the state has confirmed 307 cases and 32 of them were in children under 14 years old¹¹. The first HCPS case in a child from Mato Grosso was confirmed by serological testing in March 2001 when a girl from Campo Novo do Parecis, after having contact with a family member that died from HCPS, presented nonspecific clinical manifestations and her serum samples confirmed hantavirus infection during the epidemiological surveillance. Later, in the same city, the second case was confirmed in November 2001. It was a 13-year-old boy, from the rural area, who recovered after admission to the ICU. The patient had a high-risk history as he used to manipulate corn grains to feed animals near his house. In 2005, the first fatal case was reported in a four-year-old girl, residing in Nortelandia municipality,

who died on the same day the respiratory manifestations had started. She experienced high-risk conditions when accompanying her parents in agricultural activities on a small farm.

The spatial distribution of HCPS cases in children is concentrated in the Central North (62.5%) and extreme North (37.5%) regions of Mato Grosso State (Figure 3). The prevalent conditions that favor infections in the Central North region were related to family activities involving agriculture and direct rodent handling. Alternatively, in the extreme North region of Mato Grosso, 11 of the 12 reported cases were indigenous children residing in the Xingu Indigenous Park.

Regarding the children's exposure to high-risk conditions for hantavirus infection, the data confirmed that 27 cases occurred at home during everyday life. Eighteen children (56.2%) had contact with human cases in their families, 16 (50%) were present and/or participated in house cleaning and 13 (40.6%) had direct contact with rodents (Table 2). The other cases were related to parental activities in agriculture, fishing and hunting and subsequent indoor play with other children.

The gender distribution of the 32 HCPS cases in children is equivalent between boys and girls, aged four to 14 years old (mean 10.2, variance 8.387 and amplitude 10 years). As for the ethnicity, the predominant ones were mixed (black and white) and indigenous, with 34.4% each (Table 2).

Eleven children died, with a mortality rate of 34.4%, and the most frequent signs and symptoms were fever (75%), dyspnea (59.4%), cough (46.9%), headache (43.7%) and abdominal pain (43.7%). Twenty-one (59.4%) children were hospitalized, but only 19 remained there for more than 24 hours. During their hospitalization, nonspecific laboratory tests were performed and detected thrombocytopenia in 94.7%, hemoconcentration in 63.1%, leukocytosis in 47.3% and atypical lymphocytes as well as increased urea and creatinine in 26.3% (Table 3). It is noteworthy that the children who did not undergo nonspecific laboratory tests were indigenous children who were hospitalized at their

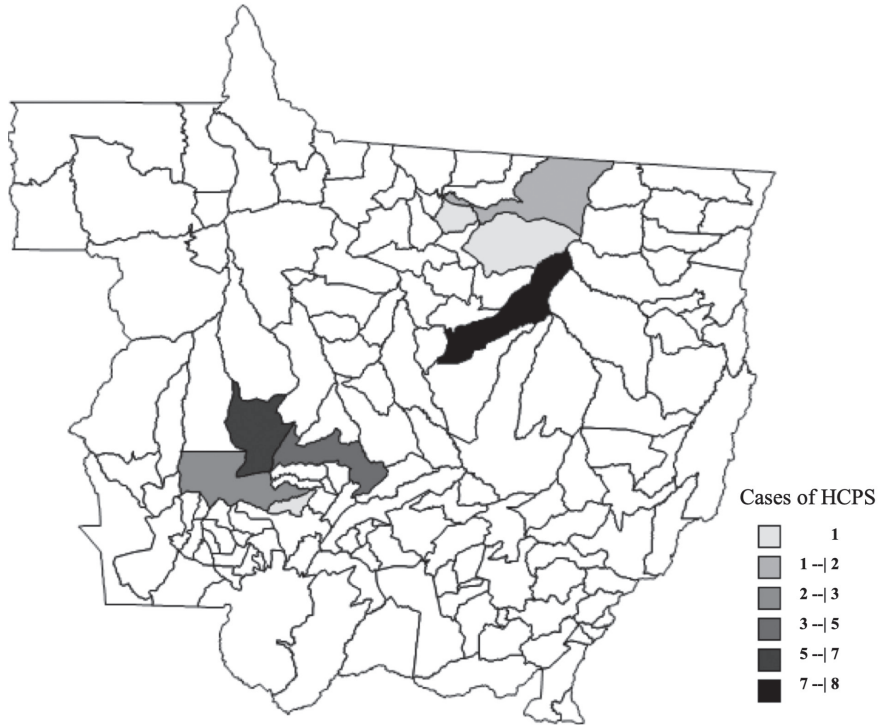


Figure 3 – Distribution by city of the cases of children with HCPS in Mato Grosso State, Brazil, from 1999 to 2018.

Table 2 – Socio-demographic characteristics of the 32 hantavirus cases in children in Mato Grosso State, Brazil, from 1999 to 2018

Independent Variables		Total	
		N	%
Gender	Male	16	50.0
	Female	16	50.0
Ethnicity	White	08	25.1
	Black	02	6.3
	Indigenous	11	34.3
	Mixed (black and white)	11	34.3
Risk condition	Contact with hantavirus cases	18	56.2
	House cleaning	16	50.0
	Direct contact with rodents	13	40.6
	Milling and storage of grains	7	21.8
	Deforestation, plantation and harvesting	5	15.6
	Hunting and fishing	5	15.6
	Sleeping, resting and playing in sheds and stalls	4	12.5
	Infection Environment	House	27
Leisure	5	15.6	

village referral hospital (N = 12), with the exception of one child who was diagnosed during an epidemiological research (N = 1).

The presence of a diffuse pulmonary infiltrate was detected in 84.2% of the 19 children who underwent radiological exams, in addition to one who had a localized pulmonary infiltrate. Clinical therapy was based on ICU assistance and included the use of antibiotics (57.1%), vasoactive drugs (28.6%), and corticosteroids (38.1%). Only seven children required mechanical respiratory support.

DISCUSSION

Since 2001, HCPS cases have been reported yearly in children in Mato Grosso State, which is possibly explained by the awareness and training provided by the State Department of Health of Mato Grosso (SES-MT)³⁰. The result of these actions can be seen in increased clinical suspicion of HCPS in the Pantanal region, where, until 2016, there were no confirmed HCPS cases.

The temporal distribution of hantavirus infections in children in Mato Grosso State follows the pattern of other age groups, occurring every month of the year, except October³⁰. Similar to the USA and Argentina, where most cases occur during summer^{5,6,31}, the other regions of Brazil have a well-defined seasonal variation. In the Southeastern States, most cases occurred during autumn, whereas in the Southern States, most cases occurred during spring and summer^{5,32}. These seasonal differences in temporal distribution may be explained by biological and behavioral

Table 3 – Clinical, laboratory and therapeutic characteristics of the 32 cases of HCPS in children from Mato Grosso State, from 1999 to 2018

Variables	Total		
	N	%	
Signs and symptoms	Fever	24	75.0
	Dyspnea	19	59.4
	Cough	15	46.9
	Headache	14	43.7
	Abdominal pain	14	43.7
	Nausea	13	40.6
	Dizziness	10	31.2
	Asthenia	10	31.2
	Acute breathing insufficiency	8	25.0
	Myalgia	7	21.8
	Chest pain	7	21.8
	Backache	4	12.5
	Hypotension	2	6.2
	Renal insufficiency	2	6.2
	Diarrhea	1	3.1
	Shock	1	3.1
	Cardiac insufficiency	1	3.1
Nonspecific laboratory tests performed	19	59.4	
Thrombocytopenia	18	94.7	
Hemoconcentration	12	63.1	
Leukocytosis	9	47.3	
Increased urea and creatinine	5	26.3	
Atypical lymphocytes	5	26.3	
X-ray	19	59.4	
Diffuse pulmonary infiltrate	16	84.2	
Localized pulmonary infiltrate	1	5.3	
No abnormality	2	10.6	
Hospitalization	21	65.6	
Inter-city transfer	9	42.8	
Use of antibiotics	12	57.1	
Mechanical respiratory support	7	33.3	
Use of vasoactive drugs	6	28.6	
Use of corticosteroids	8	38.1	

Pediatric references: hematocrit 31-41%, leukocytes 6.000-10.000/mm³, creatinine 0.42-0.96 mg/dL, urea 8-36 mg/dL.

factors of reservoir rodents or by the different agricultural crops in these regions³³.

Corroborating the findings of Terças *et al.*³⁰, the spatial distribution of the historical series of HCPS cases in children was also observed in the Central North (62.5%) and

extreme North (37.5%) regions of Mato Grosso. Although this study describes the first case of hantavirus recorded in a child in the Pantanal biome, in this same community, cases of HCPS with probable site of infection located in the Brazilian cerrado region were identified³⁴.

The circumstances of infection experienced by children from each Mato Grosso region are distinct from other ones, considering that they all have a routinely contact with wild rodents. The Central North region of Mato Grosso is devoted to agricultural activities, with extensive farms practicing direct planting and with two circulating hantavirus genotypes, Castelo dos Sonhos (*Oligoryzomys utiairtensis*) and Laguna Negra (*Calomys Callidus*)^{35,36}.

The extreme North region has undergone a continuous process of deforestation in recent years, an event that has caused deep and important environmental changes. In this same scenario, it is worth mentioning that the expansion of agriculture to new areas, as well as certain practices of harvesting and processing of products, leads man into ecological niches where new agents can be found. These practices may still attract wild rodents and other animals, thereby narrowing their relationship with humans^{37,38}. In addition, the rural properties of Mato Grosso underwent changes in the production process between 2000 and 2007, replacing the annual plantation with the small crop system, where soybeans are planted from September and harvested in January and February. After this harvest, the planting of corn or cotton is carried out to be harvested in June and July. Thus, food is available year-round to wild rodents³⁹.

It should be noted that in Campo Novo do Parecis, the municipality with the highest number of HPS cases in the State and in the country, the law 017/2006 created in July 2006, established specific measures for HPS prevention and it is internationally recognized as a public instrument in the prevention and control of HPS, as it established a perimeter of 40 meters between plantations and dwellings in rural areas around the city and urban areas of the municipality³⁰.

The same genotypes that have been previously mentioned were also identified in the cities along the BR 163 highway to the Indigenous Xingu Park. It is also noteworthy that this indigenous area experienced a hantavirus outbreak in 2010, with 18 reported human cases, of which eight were children⁴⁰. In hantavirus studies focused on children reported so far, there is no predominance of gender probably because they occurred sparsely^{12,20-23}. Our findings corroborate those of Ramos *et al.*²⁰ that found a high prevalence in indigenous, but little difference between genders.

The absence of confirmed cases of HCPS in children under four years old may be related to the care and limitations of this age group, reducing their contact with the external environment. Pini⁴¹ claims that different

epidemiological features have been reported in several countries in Latin America. In the historical series of children from Mato Grosso, similar to the American cases, there was a predominance of exposure to infection at home (indoor)^{12,19-21,23,25}. We have also identified direct contact with rodents, especially their handling and touching carcasses or live animals, as a risk factor. This has been previously described by St Jeor²² and, later, in the report of five cases in the United States²¹.

Brazil has the highest mortality rate (39.7%) among American countries, with other countries having a variable average of hantavirus mortality rate: United States (36%), Canada (30%), Panama (17.6%) and Paraguay (11.3%)^{6,7,10}. As for Mato Grosso State, the average mortality rate ranged between 44% and 42.8%³⁰. Among the 32 analyzed cases, a mortality rate of 34.4% was identified, lower than the one described in Argentina (60%) and the USA (67%)^{20,22,23}, but higher than the one reported by the last North American study (20%)²¹.

The clinical characteristics of HCPS in children are slightly different from those of adults. Although there are reports of an increased incidence of sore throat in the United States, this symptom was not found in Mato Grosso²⁰. The most common signs and symptoms identified in this case series were similar to those described by the CDC²¹ in the prodromal phase: fever (75%), dyspnea (59.4%), cough (46.9%), headache (43.7%) and abdominal pain (43.7%). They are also aligned with the results found in Brazilian adults in general and in Mato Grosso^{30,32}.

It is noteworthy that, in the case of HCPS reported in the present study, the signs and symptoms initially described were already present in the cardiopulmonary phase. This may be explained by the patient's cognitive impairment as the parents did not perceive the clinical deterioration until the child's respiratory condition exacerbated.

In this scenario, and in face of a wide variety of other conditions with initial symptoms similar to those of HCPS, it should be emphasized that a differential diagnosis in children based on their epidemiological history is required. Therefore, in Brazil, diseases such as influenza, dengue fever, chikungunya and zika virus infections, in addition to septicemia, spotted fever caused by *Rickettsia rickettsii*, leptospirosis, among others, should be considered. Knowledge of the epidemiological history involving the child's contact with wild rodents and/or suspected HCPS cases in close contact as relatives and neighbors is indispensable⁴².

As for nonspecific exams the blood count shows the presence of hemoconcentration, left shift leukocytosis, the presence of atypical lymphocytes and thrombocytopenia, similar to adult HCPS⁴³.

The radiographic findings typically show the presence of interstitial infiltrates with pulmonary edema and pleural effusion during the cardiorespiratory phase due to an increased vascular permeability². However, these changes in children are marked by the early detection of thrombocytopenia, followed later by leukocytosis and hemoconcentration^{20,21,25}. Pini *et al.*²³ described increased urea and creatinine in children with HCPS in Argentina, whereas the diffuse pulmonary infiltrates are present in most pediatric descriptions^{17,21,23}. The laboratory findings of our historical series corroborate the previously mentioned descriptions, with thrombocytopenia (94.7%), hemoconcentration (63.1%), leukocytosis (47.3%), atypical lymphocytes and increased urea and creatinine in 26.3% of cases and the presence of a diffuse pulmonary infiltrate in 84.2% of cases.

Laboratory monitoring of the patient during and after recovery allowed us to verify the kinetics of nonspecific and specific laboratory results. Thus, it was possible to observe the sequence of events in blood test results from the ICU treatment as well as the antibodies production that followed the trends described in the literature, with high levels of early anti-hantavirus IgM, related to the disease's initial phase, that declined 30 days after the onset of symptoms^{2,11}. IgG antibodies remained negative, with similar titrations, in the two sets of tests from the first to the 28th day after the onset of symptoms. Nevertheless, only the third blood sample collected on the 48th day confirmed seroconversion¹¹. Hantavirus infection has a variable incubation period, making it difficult to determine the exact date of infection; therefore, the patient may have had contact with hantavirus and presented with clinical manifestations later, influencing both, the detection and the antibody concentration^{2,43}.

Cases of HCPS with severe hypoxemic acute respiratory failure require respiratory support and mechanical ventilation that have to be performed if the oxygen saturation drops below 80%^{11,32,34}. In the clinical case described in this study, the use of mechanical ventilation was initiated early in the treatment protocol and was necessary for six days. The case series shows that mechanical ventilations was required in 33.3% of the 32 children with HCPS from Mato Grosso.

CONCLUSION

The description of the series of pediatric HCPS cases was based on secondary data and only reflects the reality of Mato Grosso State from 1999 to 2018. However, the described findings contribute to the knowledge of hantavirus infections in children and calls health professionals attention to the importance of including this emerging zoonosis as a differential diagnosis in children with fever of unknown causes.

After confirming the first case of hantavirus infection in a child in the Pantanal region of Mato Grosso, it is important to intensify surveillance of acute febrile cases in the region, carry out eco-epidemiological studies as and serological research to determine strategies that enable the identification not only of HCPS, but also of virus species circulating in rodent reservoirs.

Finally, considering the importance of hantaviruses from a public health standpoint, it is emphasized that health education activities for both, health professionals and the general public should be maintained and encouraged in order to prevent further human infections and enable early diagnosis, with consequent reduction in deaths in children of Mato Grosso.

ACKNOWLEDGMENTS

Thanks to the direct and indirect contributors of this study, in particular the team of the *Regional Health Office of Cáceres - MT* and the staff of the *Regional Hospital of Cáceres - MT*. To the hantavirus technical professionals team from the State Department of Health of Mato Grosso and from Lacen - MT. To Viviane Karolina Vivi and Thiago Luciano for supporting the transport of samples and to all members of the Hantaviruses and Rickettsioses Laboratory of IOC-FIOCRUZ, Rio de Janeiro.

AUTHORS' CONTRIBUTIONS

Conceptualization: ACPTT, ERS� and MA; methodology: MME, RCO and AG; validation: AVGM, MME, LS, SKU and JF; formal analysis: ACPTT, MME, ERS� and MA; investigation: SB and JMM; resources: MME; writing - original draft preparation: ACPTT; writing - review and editing: ACPTT, ERS� and MA; visualization: ACPTT; supervision: ACPTT, ERS� and MA; project administration: ERS�; funding acquisition: MA.

CONFLICT OF INTERESTS

The authors declare that there is no conflict of interests among them or with any financial organization regarding the material discussed in the present manuscript.

FINANCIAL SUPPORT

This research was funded by *Fundação de Amparo à Pesquisa do Estado de Mato Grosso (FAPEMAT)*, grant N° 005/2015.

REFERENCES

1. Lee HW, Lee PW, Johnson KM. Isolation of the etiologic agent of Korean hemorrhagic fever. *J Infect Dis.* 1978;137:298-308.
2. Nichol ST, Spiropoulou CF, Morzunov S, Rollin PE, Ksiazek TG, Feldmann H, et al. Genetic identification of a hantavirus associated with an outbreak of acute respiratory illness. *Science.* 1993;262:914-7.
3. Pergam SA, Schmidt DW, Nofchissey RA, Hunt WC, Harford AH, Goade DE. Potential renal sequelae in survivors of hantavirus cardiopulmonary syndrome. *Am J Trop Med Hyg.* 2009;80:279-85.
4. Rasmuson J, Andersson C, Norrman E, Haney M, Evander M, Ahlm C. Time to revise the paradigm of hantavirus syndromes? Hantavirus pulmonary syndrome caused by European hantavirus. *Eur J Clin Microbiol Infect Dis.* 2011;30:685-90.
5. Martinez VP, Bellomo CM, Cacace ML, Suarez P, Bogni L, Padula PJ. Hantavirus pulmonary syndrome in Argentina, 1995-2008. *Emerg Infect Dis.* 2010;16:1853-60.
6. MacNeil A, Ksiazek TG, Rollin PE. Hantavirus pulmonary syndrome, United States, 1993-2009. *Emerg Infect Dis.* 2011;17:1195-201.
7. Figueiredo LT, Souza WM, Ferrés M, Enria DA. Hantaviruses and cardiopulmonary syndrome in South America. *Virus Res.* 2014;187:43-54.
8. Montgomery JM, Blair PJ, Carroll DS, Mills JN, Gianella A, Iihoshi N, et al. Hantavirus pulmonary syndrome in Santa Cruz, Bolivia: outbreak investigation and antibody prevalence study. *PLoS Negl Trop Dis.* 2012;6:e1840.
9. Riquelme R, Rioseco ML, Bastidas L, Trincado D, Riquelme M, Loyola H, et al. Hantavirus pulmonary syndrome, Southern Chile, 1995-2012. *Emerg Infect Dis.* 2015;21:562-8.
10. Drebot MA, Jones S, Grolla A, Safronetz D, Strong JE, Kobinger G, et al. Hantavirus pulmonary syndrome in Canada: an overview of clinical features, diagnostics, epidemiology and prevention. *Can Commun Dis Rep.* 2015;41:124-31.
11. Pinto Junior VL, Hamidad AM, Albuquerque Filho DO, Santos VM. Twenty years of hantavirus pulmonary syndrome in Brazil: a review of epidemiological and clinical aspects. *J Infect Dev Ctries.* 2014;8:137-42.
12. Armstrong LR, Bryan RT, Sarisky J, Khan AS, Rowe T, Ettestad PJ, et al. Mild hantaviral disease caused by Sin Nombre virus in a four-year-old child. *Pediatr Infect Dis J.* 1995;14:1108-10.
13. Eboriadou M, Kalvosoglou I, Varlamis G, Mitsiatos G, Papa A, Antoniadis A. Hantavirus nephropathy in a child. *Nephrol Dial Transplant.* 1999;14:1040-1.
14. van der Werff ten Bosch J, Heyman P, Potters D, Peeters S, Cochez C, Piéerard D. Hantavirus Puumala infection as a cause of fever of unknown origin in a child. *Acta Paediatr.* 2004;93:1120-2.
15. Dusek J, Pejcoch M, Kolsky A, Seeman T, Nemeč V, Stejskal J, et al. Mild course of Puumala nephropathy in children in an

- area with sporadic occurrence Hantavirus infection. *Pediatr Nephrol.* 2006;21:1889-92.
16. Khan AS, Ksiazek TG, Zaki SR, Nichol ST, Rollin PE, Peters CJ, et al. Fatal hantavirus pulmonary syndrome in an adolescent. *Pediatrics.* 1995;95:276-80.
 17. Lee BE, Joffe AR, Vaudry W. Hantavirus pulmonary syndrome: report of the first Canadian paediatric case. *Can J Infect Dis.* 1998;9:319-21.
 18. de St Maurice A, Ervin E, Schumacher M, Yaglom H, VinHatton E, Melman S, et al. Exposure characteristics of hantavirus pulmonary syndrome patients, United States, 1993-2015. *Emerg Infect Dis.* 2017;23:733-9.
 19. Ramos MM, Hjelle B, Overturf GD. Sin Nombre hantavirus disease in a ten-year-old boy and his mother. *Pediatr Infect Dis J.* 2000;19:248-50.
 20. Ramos MM, Overturf GD, Crowley MR, Rosenberg RB, Hjelle B. Infection with Sin Nombre hantavirus: clinical presentation and outcome in children and adolescents. *Pediatrics.* 2001;108:E27.
 21. Centers for Disease Control and Prevention. Hantavirus pulmonary syndrome in five pediatric patients: four states, 2009. [cited 2019 Jan 16]. Available from: <https://www.cdc.gov/mmwr/preview/mmwrhtml/mm5850a3.htm>
 22. St Jeor S. Three-week incubation period for hantavirus infection. *Pediatr Infect Dis J.* 2004;23:974-5.
 23. Pini NC, Resa A, del Jesús Laime G, Lecot G, Ksiazek TG, Levis S, et al. Hantavirus infection in children in Argentina. *Emerg Infect Dis.* 1998;4:85-7.
 24. Oliveira RC, Sant'ana MM, Guterres A, Fernandes J, Hillesheim NL, Lucini C, et al. Hantavirus pulmonary syndrome in a highly endemic area of Brazil. *Epidemiol Infect.* 2016;144:1096-106.
 25. Mascarenhas-Batista AV, Rosa ES, Ksiazek TG, Rosa AP, Leduc JW, Pinheiro F, et al. Anticorpos anti-hantavírus em escolares de Salvador, Bahia. *Rev Soc Bras Med Trop.* 1998;31:433-40.
 26. Webster D, Lee B, Joffe A, Sliagl W, Dick D, Grolla A, et al. Cluster of cases of hantavirus pulmonary syndrome in Alberta, Canada. *Am J Trop Med. Hyg.* 2007;77: 914-8.
 27. Raboni SM, Levis S, Rosa ES, Bisordi I, Delfraro A, Lemos E, et al. Hantavirus infection in Brazil: development and evaluation of an enzyme immunoassay and immunoblotting based on N recombinant protein. *Diagn Microbiol Infect Dis.* 2007;58:89-97.
 28. Guterres A, Oliveira RC, Fernandes J, Schrago CG, Lemos ER. Detection of different South American hantaviruses. *Virus Res.* 2015;210:106-13.
 29. Tao Z, Wang Z, Song S, Wen H, Ren G, Wang G. Genetic properties of medium (M) and small (S) genomic RNA segments of Seoul hantavirus isolated from *Rattus norvegicus* and antigenicity analysis of recombinant nucleocapsid protein. *Virus Genes.* 2007;34:23-30.
 30. Terças AC, Espinosa MM, Santos MA. Fatores associados ao óbito por síndrome cardiopulmonar por hantavírus em Mato Grosso, Brasil. In: Guimarães LV, Pignatti MG, Souza DP, organizadores. *Saúde coletiva: múltiplos olhares em pesquisa.* Cuiabá: EdUFMT; 2012. p. 309-25.
 31. Knust B, Rollin PE. Twenty-year summary of surveillance for human hantavirus infections, United States. *Emerg Infect Dis.* 2013;19:1934-7.
 32. Fonseca LX, Oliveira SV, Duarte EC. Magnitude e distribuição dos óbitos por hantavirose no Brasil, 2007-2015. *Epidemiol Serv Saude.* 2018;27:e2017221.
 33. Bayard V, Kitsutani PT, Barria EO, Ruedas LA, Tinnin DS, Muñoz C, et al. Outbreak of hantavirus pulmonary syndrome, Los Santos, Panama, 1999-2000. *Emerg Infect Dis.* 2004;10:1635-42.
 34. Nunes ML, Maia-Elkhoury AN, Pelissari DM, Elkhoury MR. Caracterização clínica e epidemiológica dos casos confirmados de hantavirose com local provável de infecção no bioma Cerrado Brasileiro, 1996 a 2008. *Epidemiol Serv Saude.* 2011;20:537-45.
 35. Travassos da Rosa ES, Medeiros DB, Nunes MR, Simith DB, Pereira AS, Elkhoury MR, et al. Pygmy rice rat as potential host of Castelo dos Sonhos hantavirus. *Emerg Infect Dis.* 2011;17:1527-30.
 36. Travassos da Rosa ES, Medeiros DB, Nunes MR, Simith DB, Pereira AS, Elkhoury MR, et al. Molecular epidemiology of Laguna Negra virus, Mato Grosso State, Brazil. *Emerg Infect Dis.* 2012;18:982-5.
 37. Donalísio MR, Vasconcelos CH, Pereira LE, Ávila AM, Katz G. Aspectos climáticos em áreas de transmissão de hantavirose no Estado de São Paulo, Brasil. *Cad Saude Publica.* 2008;24:1141-50.
 38. Schatzmayr HG. Viroses emergentes e reemergentes. *Cad Saude Publica.* 2001;17 Suppl:209-13.
 39. Arvor D, Dubreuil V, Meirelles MS. Análise da intensificação da agricultura no Mato Grosso à partir de dados TRMM 3B42 e de séries temporais MODIS/EVI. In: *Anais do XIV Simpósio Brasileiro de Sensoriamento Remoto; 2009 Apr 25-30; Natal, RN, Brasil.* p.91-8.
 40. Terças AC, Santos MA, Pignatti MG, Espinosa MM, Via AVG Menegatti JA. Hantavirus pulmonary syndrome outbreak, Brazil, December 2009-January 2010. *Emerg Infect Dis.* 2013;19:1824-7.
 41. Pini N. Hantavirus pulmonary syndrome in Latin American. *Curr Opin Infect Dis.* 2004;17:427-31.
 42. Chate S, Shah I, Doshi H. Hantavirus and tuberculosis co-infection in an Indian child. *Indian J Med Microbiol.* 2017;35:426-8.
 43. Dzagurova TK, Tkachenko EA, Ishmukhametov AA, Balovneva MV, Klempa B, Krugerc DH. Severe hantavirus disease in children. *J Clin Virol.* 2018;101:66-8.