

Images in Infectious Diseases

Melanoacanthoma arising with verruca vulgaris in a patient positive for human immunodeficiency virus.

Felipe Tavares Rodrigues^[1] , Priscilla Filippo Alvim de Minas Santos^[1] 
and Maria de Fátima Guimarães Scotelaro Alves^[1] 

[1]. Universidade do Estado do Rio de Janeiro, Departamento de Dermatologia, Rio de Janeiro, RJ, Brasil.

A 32-year-old man with a history of human immunodeficiency virus (HIV) infection, CD4 cell count of $>400/\mu\text{L}$, and an undetectable viral load copies/mL, presented with verrucous mild itchy lesions on the right lower limb that had appeared 3 years prior (Figure 1). A skin biopsy revealed areas of verruca vulgaris with smaller areas of melanoacanthoma (Figure 2a-b, and Figure 3).

Melanoacanthoma, a rare variation of seborrheic keratosis that exhibits an increased melanocyte concentration, was first described by Mishima and Pinkus in 1960. It is considered benign, with slow-growing melanocytes and keratinocyte proliferation, and is frequently found on the head, neck, or trunk of light-skinned and older patients. It presents as asymptomatic or mildly itchy, pigmented papules, plaques, cutaneous horns, and even verrucous lesions that can be induced by trauma. Differential diagnoses such as verrucous carcinoma, giant condyloma acuminata, and melanoma should be considered. Treatment includes conservative or surgical removal¹⁻³.

Human papillomavirus (HPV) DNA was isolated from seborrheic keratosis of the genital area. A theory states that HIV infection can cause latent HPV overgrowth and contribute to the development of seborrheic keratosis and melanoacanthomas. Moreover, Indamar et al. (2003) described growth factor hyperactivation in patients with HIV infection, which is responsible for Kaposi's sarcoma and could implicate the development of these cutaneous neoplasms³.

We highlight the rarity of this case and the need to rule out other possibilities in the differential diagnosis, mainly in patients living with HIV infection.

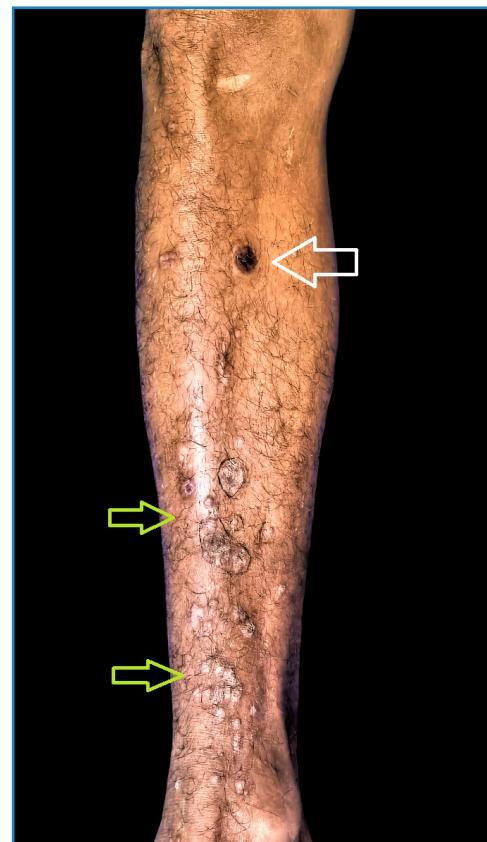

FIGURE 1: Melanocytic lesions, melanoacanthoma (white arrow), and verrucous lesions (green arrows).

Corresponding author: MD. Felipe Tavares Rodrigues. **e-mail:** medftr@yahoo.com.br

Authors' contribution: PFAM: Conception and design of the study, Acquisition of data; FTR: Conception and design of the study, Analysis and interpretation of data, Final approval of the version to be submitted; MFGSA: Conception and design of the study, Acquisition of data, Drafting the article, Final approval of the version to be submitted.

Conflict of Interest: The authors have no conflict of interest.

Financial Support: None.

Received 29 May 2023 • **Accepted** 28 June 2023

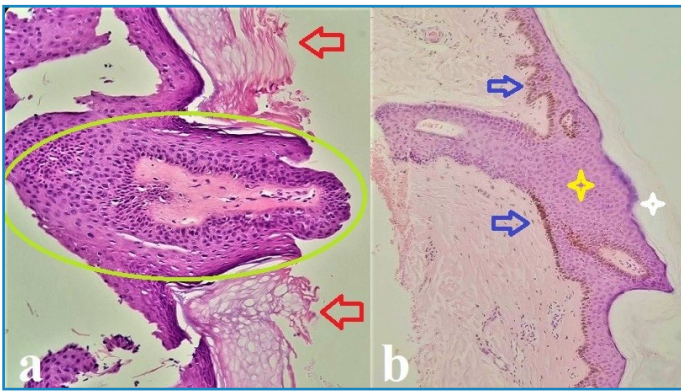


FIGURE 2: **a** - Verruca vulgaris lesions, marked hyperkeratosis (red arrows), and papillomatosis (green circle) (H&E, 40x). **b** - A Melanoacanthoma, marked hyperkeratosis (white star) and acanthosis (yellow star) of keratinocytes, and intense proliferation of melanocytes in the basal layer (blue arrows). (H&E x 40).

REFERENCES

1. Vasani RJ, Khatu SS. Melanoacanthoma: Uncommon presentation of an uncommon condition. *Indian Dermatol Online J.* 2013;4(2):119-21.
2. Trunfio M, Ribero S, Bonora S, Di Perri G, Quaglino P, Calcagno A. Malignant Melanoma in People Living with HIV/AIDS: Can We Know More, Can We Do Better? *AIDS Rev.* 2019;21(2):65-75.
3. Inamadar AC, Palit A. Eruptive seborrheic keratosis in human immunodeficiency virus infection: a coincidence or 'the sign of Leser-Trélat'? *Br J Dermatol.* 2003;149(2):435-6.

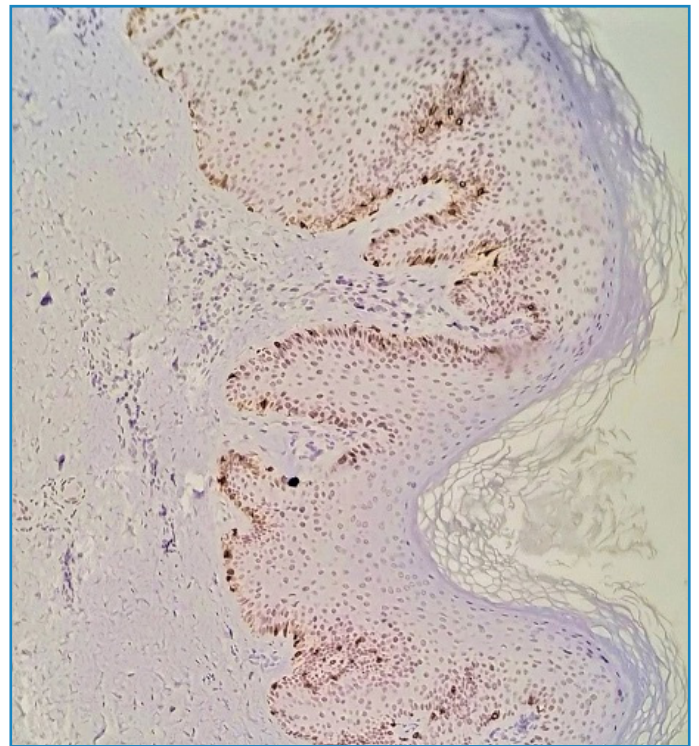


FIGURE 3: Immunohistochemistry showing intense proliferation of Melan-A-labeled brown melanocytes.