

Direct Stent Implantation Using a 5F Guiding Catheter and Transradial Approach

Wilson Miguel Cecim Coelho, José Luiz Balthazar Jacob, José Dalmo de Araujo Filho, Sumaira Fatarone Frederico, Ivone Eduarda Campos Cabbaz
São José do Rio Preto, SP - Brazil

Objective

To assess stent implantation without previous dilation with a conventional balloon catheter to treat coronary artery obstructions, by using low profile guiding catheters and the transradial approach.

Methods

The transradial approach is attractive due to the possibility of avoiding the trauma caused by the balloon, its shorter time of performance, reduced exposure to radiation, and the use of lower quantities of contrast medium than those usually required in this type of procedure.

Results

The initial experience of direct stent implantation with low profile guiding catheters and the transradial approach was analyzed in 45 patients, whose mean age was 65 years. All procedures were successful, with no major complications in the in-hospital phase.

Conclusion

The results obtained with the population studied proved that the transradial approach is safe, effective, and has very few risks of complications.

Key words

direct stent implantation, catheter, transradial

The transradial artery approach for coronary angiography was reported for the first time by Campeau in 1989¹, and, since then, several groups have reported their experiences related to both the diagnosis and treatment through angioplasty using that access²⁻⁷. Some authors^{4,6} have reported lower complication rates with the transradial approach as compared with that with the transfemoral approach, described by Seldinger. Despite the initial favorable results, the transradial approach has a learning curve that hinders its acceptance by most interventional cardiologists. The ratio between the catheter diameter and the caliber of the artery > 1 is also known to determine a poorer prognosis in regard to late thrombosis in the radial artery.

The following factors justify the choice of this approach for direct stent implantation: the lower rate of vascular complications, due to the small caliber of the artery, which is easily compressed; and the greater comfort provided to patients, who can walk immediately after the procedure, thereby avoiding the bed rest imposed by the transfemoral approach.

Dilation of the coronary lesion with a balloon prior to stent implantation has been the technique usually used, because it facilitates the passage and deployment of the stent. This strategy was particularly important for the first-generation stent. In recent years, due to important technological advances, the stents acquired better fixation, a lower profile, and greater flexibility, thereby yielding better performance, allowing their implantation without previous balloon dilation.

This observational and prospective study was designed to assess the safety and efficacy of direct stent implantation without previous balloon dilation, by using a low profile guiding catheter and the transradial approach.

Methods

From February 2001 to October 2002, 56 coronary stents were implanted in 45 (35 males) patients without previous dilation, using a 5F guiding catheter and the transradial approach.

The selection criteria were as follows: patients with single non-calcified lesions in vessels without great tortuosities proximal to the lesion, which could hinder direct stent implantation; and, patients with a wide radial pulse and normal Allen test. This test consists of simultaneous compression of the radial and ulnar arteries, by way of the patient opening and closing his hands rapidly, causing, therefore, ischemia. Then, the ulnar artery is released and the perfusion of the hand is supplied by the this artery. It is worth stressing that the

Instituto de Moléstias Cardiovasculares/IMC and Sociedade Portuguesa de Beneficência

Mailing address: Wilson Miguel Cecim Coelho - Trav. Rui Barbosa, 1382/500 - Cep 66035-500 - Belém, PA, Brazil

E-mail: wmccoelho@terra.com.br

Received: 3/14/03

Accepted: 1/22/03

English version by Stela Maris Costalonga

Table I - Clinical characteristics of the population

Number of patients	45
Male	35
Female	10
Mean age	65 anos
Diabetes	13
Systemic arterial hypertension	26
Smokers	15

procedures were performed by the same operator, who had already performed 106 diagnostic examinations prior to this study, thereby developing a learning curve observed in this technique.

The patients had a mean age of 65 years (46 to 90), and 35 were males. In regard to the clinical findings, 15 patients had stable angina, 25 had unstable angina, 3 had had a myocardial infarction at least 48 hours before and had been referred for elective treatment, and 2 were asymptomatic with positive ischemia provocative tests. Thirteen patients were diabetic, 15 smoked, and 26 were hypertensive. All patients had a normal Allen test (tab. I).

Cannulation of the radial artery was performed with Abocath 20, and, then, 20 mg of mononitrate were administered intra-arterially to prevent spasm. Later, a valvulated sheath (5F 23 cm CORDIS) was placed. Through the sheath, 2,500 units of Liquetaemin were introduced. A 5F guiding catheter (Medtronic Zoom) with a 1.47-mm lumen was used for catheterization of the coronary artery to be treated. Fifteen multilink tetra stents, 12 multilink penta, 22 genic, and 7 express stents were used to treat the following arteries: 25 lesions in the anterior descending artery; 14 lesions in the circumflex artery; 13 lesions in the right coronary; 2 lesions in the left main coronary artery protected with grafts; 1 saphenous vein graft; and 1 diagonal artery. The mean diameter of the arteries was 3.06 mm, and the mean extension of the lesions was 13.11 mm.

The mean pressure of stent deployment was 15.33 atmospheres. All patients received a sufficient intracoronary quantity of Liquetaemin to maintain the activated clotting time at > 250 seconds. Acetylsalicylic acid at the dosage of 325 mg/day and clopidogrel at the dosage of 75 mg/day were administered to the patients who had already been using these drugs. In patients who were not using these drugs, 500 mg of acetylsalicylic acid and

300 mg of clopidogrel were used as the initial dose prior to the procedure. On the day following angioplasty, clopidogrel was maintained at the dosage of 75 mg/day for 28 days, and acetylsalicylic acid was maintained at the dosage of 100 mg/day indefinitely. The sheath was removed when the activated clotting time was below 180 seconds and a compressive dressing was placed on the site. All patients were discharged from the hospital on the following day, except for 1 female patient complaining of dizziness and malaise, who, despite the normal physical examination, was maintained under observation for 1 more day, being then discharged without problems.

Angiography was performed in at least 2 projections, before and after stent implantation. Intracoronary isosorbide mononitrate was administered prior to the measurements performed with digital quantitative analysis before the procedure. That method allows for a precise assessment of the degree of stenosis and the caliber of the artery to be treated. Clinical success was defined as angiographic success without major complications in the in-hospital phase (fig. 1).

Results

The clinical characteristics of the population studied are shown in table I. Eleven patients had 2 arteries treated. Direct stent implantation was successful in all cases with an excellent final result, the entire population studied being free of events in the in-hospital phase. No major complications were observed in the vascular access. Only 1 patient had a minor hematoma, which was clinically treated.

Discussion

The technological advances in percutaneous coronary intervention in recent years have focused special attention to the profile of catheters, thereby aiming at reducing the complications at the access site, enabling the use of arteries of lower caliber, determining greater comfort for patients. With this perspective, the transradial approach has proved to be a very promising alternative⁴. This observational study showed that direct stent implantation using a 5F guiding catheter and the transradial approach is feasible, safe, and effective, achieving a very low complication rate, almost zero.

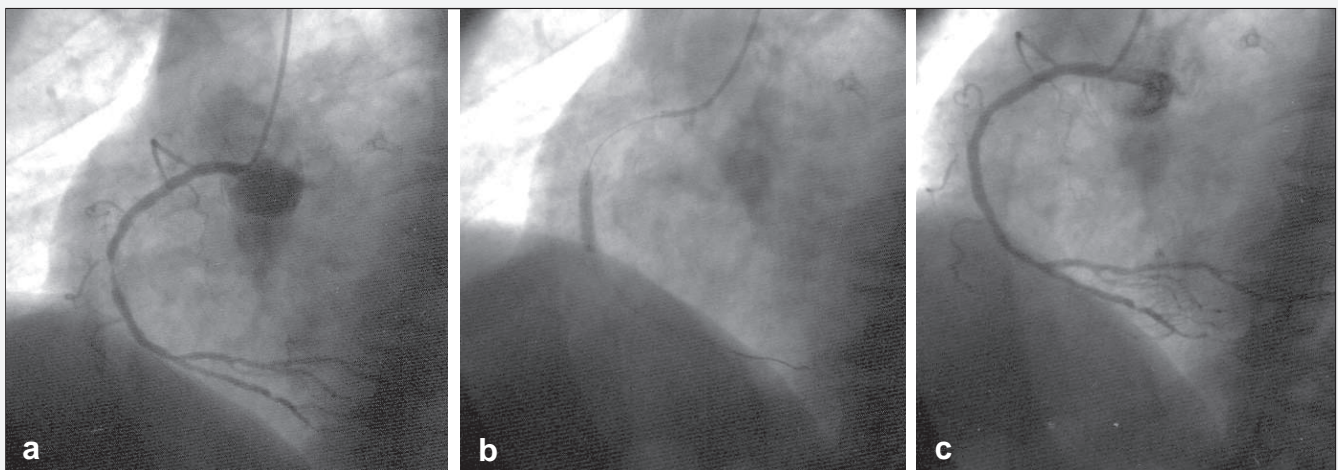


Fig. 1 - Example of direct stent implantation using a 5F guiding catheter: a) severe obstruction of right coronary artery prior to stent implantation; b) stent deployment; c) final result.

Other studies have already demonstrated that direct stent implantation without predilation is a safe and effective technique⁷⁻¹⁰, but the use of a 5F guiding catheter and the transradial approach has been demonstrated only in a series of patients selected with acute ischemic syndromes¹¹.

In some situations, direct stent implantation requires coronary intubation, so that the lesion can be crossed over. The lower

diameter, great flexibility, and smooth tip of the 5F guiding catheter provide easier coronary intubation and a lower risk of complications.

The promising results obtained in the present study may serve as a stimulus for interventional cardiologists to use the transradial approach for stent implantation, aiming at providing a more comfortable treatment for patients, without jeopardizing the result of the procedure.

References

1. Campeau L. Percutaneous radial artery approach for coronary angiography. *Cathet Cardiovasc Diagn* 1989; 16-7.
2. Kiemeneij F, Laarman GJ. Percutaneous trans radial artery approach for coronary Palmatz-Schatz stent implantation. *Am Heart J* 1994; 128: 167-74.
3. Spaulding C, Lefevre T, Funch F et al. Left radial approach for coronary angiography: results of a prospective study. *Cathet Cardiovasc Diagn* 1996; 39: 365-70.
4. Brito JC, Azevedo Jr A, Oliveira A, Sohsten RV, Santos Filho A, Carvalho H. Intervenções coronarianas através da artéria radial. *Arq Bras Cardiol* 2001, 76: 369-73.
5. Morice M-C, Dumas P, Lefevre T, Loubeyre C, Louvard Y, Piechaud JF. Systematic use of transradial approach or suture of the femoral artery after angioplasty: attempt at achieving zero access site complications. *Cathet Cardiovasc Intervent* 2000; 51: 417-21.
6. Choussat R, Black A, Bossi I, Fajadet J, Marco J. Vascular complications and clinical outcome after coronary angioplasty with platelet IIb/IIIa receptor blockade: comparison of transradial vs transfemoral arterial access. *Eur Heart J* 2000; 21: 662-7.
7. Mann T, Cowper PA, Peterson E et al. Transradial coronary stenting: comparison with femoral access closed with an arterial suture device. *Cathet Cardiovasc Intervent* 2000; 49: 150-6.
8. Danzi GB, Capuano C, Fiocca L et al. Stent implantation without predilation in patients with a single, noncalcified coronary artery lesion. *Am J Cardiol* 1999; 84: 1250-3.
9. Wilson SH, Berger PB, Mathew V et al. Immediate and late outcomes after direct stent implantation without balloon predilation. *J Am Coll Cardiol* 2000; 35: 937-43.
10. GertJan L. *, Tamil M., Henk S. et al. Direct coronary stent implantation: safety, feasibility, and predictors of success of the strategy of direct coronary stent implantation. *Cathet Cardiovasc Intervent* 2001; 52: 443-8.
11. Martial H, Rémi S, Quanming Z et al. Mini-invasive strategy in acute coronary syndromes: direct coronary stenting using 5 Fr guiding catheters and transradial approach. *Cathet Cardiovasc Intervent* 2002; 55: 340-3.

ERRATA

No suplemento VIII do volume 82 (junho) 2004 "Contribuição Brasileira à Cardiologia Universal. Subsídio da SBC nos seus 60 anos de atividade", por falhas de revisão, surgiram vários erros, quer em excesso ou escassez de vírgulas e demais sinais ortográficos, quer nos acentos nos nomes dos médicos, autores, sócios da SBC, sobretudo o nome de Radi Macruz, cuja ortografia correta é esta. Esperamos que os leitores saibam perdoar os diversos erros de revisão desse suplemento. Informamos que o texto devidamente corrigido encontra-se no nosso site na Internet.