

# Surgical Treatment of Aortic Valve Disease with Stentless Bovine Pericardium Prosthesis – Immediate Results

Wesley Ferreira de Araújo, Luis Roberto Gerola, Hyoung C. Kin, Armindo Pereira Filho, Guilherme Flora Vargas, Roberto Catani, Enio Buffolo  
*Universidade Federal de São Paulo - Escola Paulista de Medicina - São Paulo, SP - Brazil*

## OBJECTIVE

To present the immediate results and assess the clinical and hemodynamic performance of stentless bovine pericardial bioprostheses in aortic position.

## METHODS

Twenty patients were operated who were indicated for surgery for valve replacement with biological prosthesis. Eleven patients were male; sixteen had aortic stenosis; four, insufficiency; the mean age was  $66.3 \pm 8.8$  years. The surgical technique used was subcoronary implant. Associated procedures were performed in five patients. Postoperative morbidity, mortality and hemodynamic performance were assessed on transthoracic echocardiogram.

## RESULTS

Mean time of cardiopulmonary bypass was  $136.5 \pm 24.41$  minutes and mean anoxic time was  $105.2 \pm 21.62$  minutes. Hospital mortality was 5% (one patient). Mean time of intensive care unit stay was  $3.65 \pm 3.23$  days. Mean postoperatively transvalvular gradient was  $25.39 \pm 7.82$  mmHg. Left ventricle ejection fraction was  $67 \pm 13.49\%$  preoperatively and  $63.24 \pm 16.06\%$  postoperatively ( $p = 0.45$ ). Eleven patients did not present any degree of valve regurgitation, eight presented mild regurgitation and one, mild to moderate regurgitation.

## CONCLUSION

Stentless prostheses can be used for the surgical treatment of aortic valve diseases, with in hospital mortality and morbidity similar to the mortality and morbidity described in the literature for similar procedures, with satisfactory hemodynamic performance.

## KEY WORDS

Aortic valve, valve replacement, bioprosthesis, stentless bioprosthesis, stentless prosthesis.

Despite the advancements made in the last decade as regards valve surgery, we can say that no ideal valve replacement exists to date, and as the possibility of preserving aortic valves is infrequent, surgical treatment almost always implies valve replacement.

The most frequently used prostheses – biological and mechanical – present, respectively, limited durability and requirement of the use of oral anticoagulants. Additionally, these prostheses, because they are supported by rigid rings, generate residual pressure gradients between the left ventricle and the aorta, which may be a problem, especially for patients with small aortic ring and in those with major myocardial hypertrophy<sup>1,2</sup>.

It is a true challenge to find a near ideal aortic valve replacement which presents high durability, with no need of using oral anticoagulants and with a mechanism of functioning that is similar to the normal aortic valve.

Although the use of cryopreserved homografts yields satisfactory results<sup>3-5</sup>, their use is restricted to few centers and they're difficult to obtain. For these reasons the demand for treatment of valve lesions will hardly be met by homografts.

In 1987, David et al<sup>6</sup> started to develop stentless heterologous prostheses which are supported by the aorta wall itself. Because their anatomy is very similar to that of normal aortic valves and because these prostheses lack a supporting ring for valves or leaflets, they generate a smaller pressure gradient between the left ventricle and the aorta and, as a result, there is less hemodynamic stress, which may translate into longer durability<sup>2,7,8</sup>.

The objective of this study is to analyze hospital morbidity and mortality with the use of stentless heterologous bovine pericardial bioprostheses in aortic position and their hemodynamic performance.

## METHODS

We considered twenty patients with severe aortic valve lesion to receive stentless heterologous bovine pericardial bioprostheses (produced by Braile Biomédica®). These patients were referred for surgery but presented counter-indication for mechanical prostheses. From this study we excluded patients with major comorbidities such as severe COPD, dialytic renal failure, peripheral arteriopathy and reoperations. The use of these bioprostheses was authorized by the rules of the Medical Ethics Committee.

Eleven (55%) patients were male, sixteen (80%) patients presented aortic stenosis, and four (20%) presented aortic insufficiency. The age varied between 31 to 75 years, with a mean age of  $66.3 \pm 8.8$  years. Of the patients with aortic insufficiency, three were in functional class (FC) III, and one was in FC II. Of the patients with aortic stenosis, nine had symptoms of syncope, and all presented precordialgia, classified according the criteria of the CCS (Canadian Cardiovascular Society) in FC I, two

patients, FC II, five patients, FC III, seven patients, and FC IV, two patients.

Two patients were diagnosed with atherosclerotic coronary disease, whose lesions caused a lumen obstruction greater than 60%.

Critical mitral stenosis was diagnosed in two patients, one with a valve area of 0.7 cm<sup>2</sup>, and the other with a valve area of 1.2 cm<sup>2</sup>. One patient presented mitral insufficiency associated with aortic lesion.

Left ventricular function was normal in fifteen (75%) of the patients; four (20%) presented mild to moderate dysfunction and only one patient presented severe ventricular dysfunction (ejection fraction equal to 30%).

The patients were operated by longitudinal median sternotomy and the cardiopulmonary bypass circuit was installed with cannulation of the aorta and right atrium. The surgery was performed under hypothermia at 28°.

Myocardial protection was effected using antegrade hypothermic blood cardioplegia, by directly cannulating the coronary ostia. The cardioplegic solution was composed of the perfusate blood itself, cooled to 4°, with potassium (15 mEq/l) only in the first induction, and in subsequent doses (approximately every twenty minutes), only cooled perfusate blood.

*Stentless prosthesis implant* - The use of this type of prosthesis requires aortotomy 1 cm above the sinotubular junction.

The technique employed to implant the prosthesis was the subcoronary technique, in which two planes of suture are performed. The first with simple stitches with Ethibond® 4-0 sutures, passed around the valve annulus, with four to five sutures per commissure, totalling between 12 to 15 sutures. These sutures should be positioned on the same plane, and should not follow the aortic ring until the commissure. Pericardial stentless bioprostheses come in tubular form and we have to section the commissures to perform the second plane of sutures.

After measuring the sinotubular junction and choosing the prosthesis, the sutures of the first plane are passed and the prosthesis is lowered to its position close to the valve annulus and the sutures are tied (fig. 1).

After lowering the prosthesis until it reached the level of the aortic annulus, we positioned the commissures. To this effect, we used U-shaped transfixing Prolene® 5-0 sutures, placed equidistantly from the three commissures. In order to facilitate the exposure of the valve and of the sinuses of Valsalva, and to perform the second plane of suture, we did not tie those commissural stitches.

Then the second suture was continuously performed on the subcoronary plane, with Prolene® 4-0, starting in the inferior part of the coronary ostia, passing around them and then up towards the commissures.

This suture was performed in the three commissures and in the end the U sutures with Prolene® 5-0 were

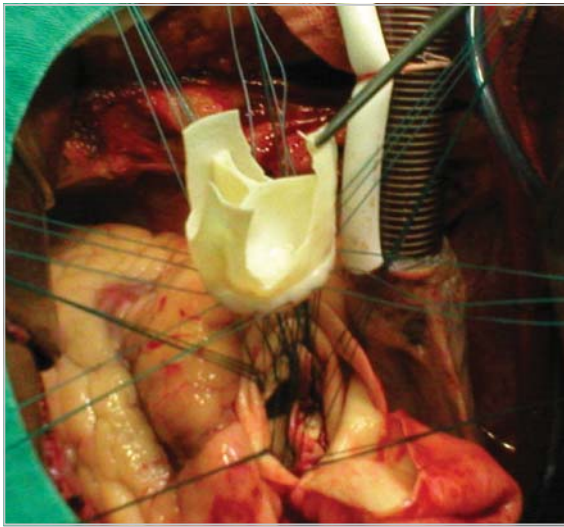


Fig. 1 – Stentless prosthesis being lowered to the aortic annulus.

tied, and the Prolene® 4-0 sutures of the second suture were tied as well.

Finally, the prosthesis should be inspected for distortions and to observe the contact surface between the leaflets of the prosthesis, which is important to prevent the regurgitation of blood into the ventricular cavity.

During the surgery, the left chambers were decompressed using an aspirator positioned in the left ventricle through the right superior pulmonary vein, which also helped to remove the air after the declamping of the aorta.

Once this step was finished, we proceeded to close the aortotomy and finished the surgery in the usual way.

All the surgeries were performed by the same surgeon and the same team.

During the surgery, cardiopulmonary bypass and myocardial anoxic time were assessed (clamping of the aorta), and in the early postoperative period we assessed major clinical morbidities, such as the presence of myocardial infarction, stroke, renal failure, hemorrhage, orotracheal intubation time and length of ICU stay. All patients were submitted to a transthoracic echocardiogram during hospital stay, and this was compared with the one performed preoperatively.

Echocardiographic variables analyzed pre and postoperatively were: the maximum gradient pressure between the left ventricle and the aorta, the ventricular mass index and the left ventricle ejection fraction, in addition to the presence and degree of insufficiency of the prosthesis.

Statistical study - We calculated the mean and standard deviation for continuous variables. Wilcoxon test was applied to compare two dependent or paired samples in time for the same patients. Alpha values < 0.05 or % were considered significance levels.

## RESULTS

Associated procedures were performed in five patients (20%): two were submitted to myocardial revascularization (one had a graft of the left internal thoracic artery into the anterior interventricular artery and [a graft] of the greater saphenous vein from the aorta to the first diagonal branch, and the other received a saphenous vein graft from the aorta to the right coronary); one patient was submitted to mitral commissurotomy and to plasty of the tricuspid valve - the De Vega procedure - and two other patients had their mitral valves replaced with biological prosthesis.

As regards the diameter of stentless bioprostheses, we used one n. 21, four n. 23, ten n. 25, four n. 27 and one n. 29. As regards the mean time of cardiopulmonary bypass and of myocardial anoxia they were respectively  $136.5 \pm 24.41$  and  $105.20 \pm 21.62$  minutes.

Hospital mortality was 5% (one patient). This patient, in addition to valve replacement, was submitted to myocardial revascularization and in the early postoperative period presented a major bleeding from a branch of the saphenous vein, which caused a hemorrhagic shock and cardiorespiratory arrest. Despite emergency thoracotomy and reanimation manouvers, the patient progressed to anoxic encephalopathy, prolonged intubation, respiratory failure, and eventually died on day 15 postoperatively due to multiple organ failure.

There was no case of perioperative infarction or electrocardiographic alterations suggestive of myocardial ischemia.

Two patients (10%) had to be reoperated due to postoperative hemorrhage (these underwent associated procedures): one due to coagulopathy and the other due to bleeding of a saphenous vein branch; this last one died as has been previously described.

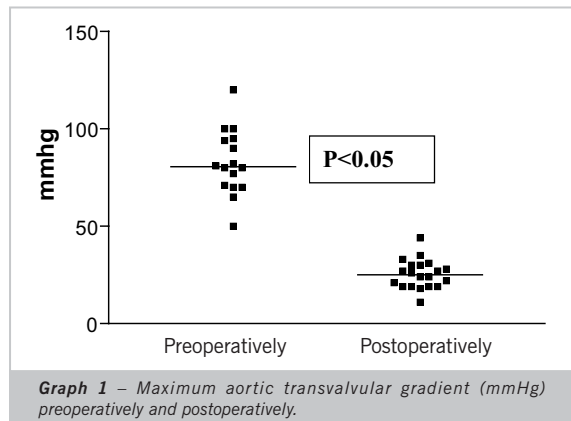
Postoperative hemorrhage varied from 140 to 4,150 ml, with a mean of  $766.8 \pm 584.8$  ml. Patients remained on average  $3.65 \pm 3.23$  days in the ICU, and the mean orotracheal intubation time was 18 hours.

As regards respiratory complications, pulmonary infection was diagnosed in four patients. As regards the thoracic wall, one patient (5%) presented skin and subcutaneous dehiscence, and no case of postoperative mediastinitis was diagnosed in this series.

As regards other clinical complications, three (15%) presented acute atrial fibrillation; two patients underwent chemical cardioversion, and one underwent electrical cardioversion. One patient (5%) developed acute renal failure and required temporary dialytic treatment.

All patients were submitted to bidimensional echocardiographic study before hospital discharge. When the ecocardiographic studies performed in the preoperative period were compared with those of the early postoperative period, we observed that mean transvalvular gradients were  $82.61 \pm 16.76$  mmHg preoperatively and  $25.39 \pm 7.82$  mmHg postoperatively, as shown in

graph 1. Left ventricle ejection fraction was  $67 \pm 13.49\%$  preoperatively and  $63.24 \pm 16.06\%$  postoperatively. As regards left ventricle mass, the mean observed was  $245.5 \pm 132.2$  g preoperatively and  $220.3 \pm 104.3$  g postoperatively, with  $p = 0.27$ .



As regards prosthesis insufficiency, eleven patients did not present any degree of valve regurgitation eight presented mild regurgitation and one presented moderate to severe regurgitation on echocardiogram.

## DISCUSSION

The first successful implant of stentless porcine bioprostheses using the subcoronary technique was performed by Sievers et al<sup>9</sup> in 1985, in a patient with aortic stenosis.

The anatomy of stentless bioprostheses is very similar to the anatomy of the aortic valve, and the rationale for its use was the idea of using the aorta wall itself for support, where the prostheses cusps will be sutured<sup>6</sup>.

There are basically three types of surgery techniques for implant of these bioprostheses, and the most widely used method, which was used with all the patients of this study was subcoronary implant. The other techniques are the replacement of the aorta root and the inclusion (*mini root*) technique. Both of these are more complicated as coronary ostia have to be reimplanted, which may extend the time of cardiopulmonary bypass<sup>10</sup>.

In subcoronary implant, two lines of suture are performed: the first on the subannular level, with separate stitches and the other on the continuous subcoronary level, around the inferior part of the coronary ostia<sup>11,12</sup>.

In the literature there is evidence in favor of this technique, such as the lower incidence of bleeding, shorter time of myocardial ischemia, lower risk of reoperation and lower incidence of valve insufficiency<sup>13</sup>. However, it requires knowledge of the spacial relationships of the aortic annulus and its relationships with adjacent structures, and this technique cannot be used in the cases where there is dilation and when the diameter of the aortic annulus is disproportional to the sinotubular junction, as this represents considerable risk of valve

insufficiency<sup>7</sup>. In these cases the root replacement technique is an option<sup>14</sup>.

As regards indications, stentless bioprostheses may be used in cases where biological prostheses are normally used, especially in elderly patients and young patients with a counter-indication for anticoagulation.

In the literature there are studies showing that stentless bioprostheses are strongly indicated for those patients with severe aortic valve disease associated with left ventricular dysfunction<sup>15</sup> and in the cases of small aortic annulus<sup>1,16</sup>. This is due to the fact that its internal diameter is larger than those of conventional prostheses and allows, in the postoperative period, significantly lower gradient between the left ventricle and the aorta, thus facilitating the work of the left ventricle and favoring its recovery<sup>17</sup>.

In this study, stentless bioprostheses were implanted using the subcoronary technique with morbidity and mortality similar to those described in the literature. Mortality was 5%, and the cause of death was bleeding of a saphenous vein branch in a patient submitted to an associated procedure, i.e. myocardial revascularization. This percentage corresponds to that described in the international literature for similar surgeries<sup>17-21</sup>.

Mean cardiopulmonary bypass and myocardial anoxic times, respectively  $136.5 \pm 24.41$  and  $105.2 \pm 21.62$  minutes, are compatible with those described in the literature<sup>22,23</sup>, since the implant of stentless prostheses may be more time-consuming, as two suture planes are required; in this casuistics, five patients (25%) were submitted to associated procedures for myocardial revascularization or mitral valve replacement. Although the implant of stentless bioprostheses takes longer, this could not be considered an independent risk factor<sup>24</sup>.

As regards early postoperative mediastinal bleeding, the mean observed was  $766.8 \pm 584.8$  ml within 48 hours or more, and five patients presented bleeding in excess of 1,000 ml, of which four had been submitted to associated procedures for myocardial revascularization or mitral valve replacement, and had anoxic and cardiopulmonary bypass times greater than 120 minutes, which may account for the greater bleeding. Two patients (10%) had to be reoperated: one of them had a diagnosis of coagulopathy, and the other had hemorrhage coming from a saphenous vein branch, this latter patient being the one who eventually died in the ICU as described above.

As regards mean extubation time and length of stay in the ICU, which were respectively 18 hours and  $3.3 \pm 3.23$  days, we believe that these times are compatible with the mean age of the patients operated and with the type of procedure performed.

The mean gradient between the left ventricle and the aorta, assessed postoperatively on transthoracic echocardiography was  $25.39 \pm 7.82$  mmHg, slightly higher than the gradients described in the world literature. Studies have been published demonstrating gradients as low as 10 to 15 mmHg at rest<sup>19,25,26</sup>, with no alteration with exercise<sup>27</sup>, and very similar to those observed when





cryopreserved homografts are used<sup>28,29</sup>, which directs our attention to the use of these prostheses, as they show to have better hemodynamic performance and favor the reduction of myocardial hypertrophy and the improvement of ventricular function<sup>30,31</sup>. A possible explanation for the obtainment of slightly lower gradients than those reported in the literature may lie in the differences between the different models of stentless bioprostheses available on the market<sup>32</sup>. In this study, we used Braile Biomédica®'s bioprostheses which are fitted with a thin ring in their base and which may account for the higher gradient observed.

Additionally, in the literature, the most widely used prosthesis was the porcine one, whereas in this study we used the one made with bovine pericardium, which may also influence the higher gradient observed.

In this study, the reduction of ventricular mass was not significant because only the immediate postoperative period was analyzed. Randomized studies show that ventricular mass reduction may occur faster when stentless bioprostheses<sup>33</sup> are used, with no difference, however, as regards other prostheses in the long term<sup>23,26,34</sup>.

A frequent concern following the implant of stentless prostheses is the possibility of valve insufficiency due to the distortion of commissural posts. In this study, eight patients (40%) presented mild regurgitation and only one (5%) presented mild to moderate regurgitation. It is important to observe the aspect of the prosthesis after the implant, checking the leaflet coaptation surface, as this contact may prevent the regurgitation of blood into the ventricular cavity. Some authors recommend the use of intraoperative echocardiography to detect and assess

prosthesis insufficiency and the presence of paravalvular insufficiency (leak)<sup>10</sup>. This is, by the way, more rare when two suture lines are used as we did in this study.

As regards the other comorbidities found in the period analyzed, atrial fibrillation in three patients (15%), ischemic stroke in two (10%), and pulmonary infection in four (20%), the authors believe that they are within the values reported in the literature and are in agreement with the age range of patients and with the procedure carried out. They certainly contributed to a longer stay at the ICU and in hospital, but had no impact on the immediate mortality or on the hemodynamic performance of the prostheses implanted.

Follow-up studies carried out five, eight and ten years after the implant of stentless bioprostheses showed excellent results in terms of prosthesis durability, in addition to the advantages already known, such as: low gradients of the left ventricular outflow tract, large effective valve orifice and regression of ventricular mass<sup>22,35,36</sup>.

We conclude that stentless bovine pericardium bioprostheses can be used to surgically treat aortic valve diseases with hospital morbidity and mortality similar to those described in the literature for other types of prostheses and that their hemodynamic performance is satisfactory, with a low rate of prosthesis insufficiency and low transvalvular gradient.

#### Potencial Conflict of Interest

No potential conflict of interest relevant to this article was reported.

## REFERENCES

- Hvass U, Palatianos GM, Frassani R, et al. Multicenter study of stentless valve replacement in the small aortic root. *J Thorac Cardiovasc Surg.* 1999; 267-72.
- Westaby S, Horton M, Jin XY, et al. Survival advantage of stentless aortic bioprostheses. *Ann Thorac Surg.* 2000; 70: 785-91.
- Gerola LR, Araujo WF, Hyong CK. Homoenxerto aórtico criopreservado no tratamento cirúrgico das lesões da valva aórtica. Resultados imediatos. *Arq Bras Cardiol.* 2004; 83: 280-3.
- Ali A, Lim E, Halstead J, et al. Porcine or human stentless valve for aortic valve replacement? Results of 10-year comparative study. *J Heart Valve Dis.* 2003; 12: 430-5.
- O'Brien MF, McGiffin DC, Stafford EG, et al. Allograft aortic valve replacement comparative clinical analysis of the viable cryopreserved and antibiotic 4° store valve. *J Cardiac Surg.* 1991; 6: 534-43.
- David TE, Ropchan GC, Butany JW. Aortic valve replacement with stentless porcine bioprostheses. *J Card Surg.* 1988; 3: 501-5.
- David TE, Puschmann R, Ivanov J, et al. Aortic valve replacement with stentless and stented porcine valves: a case match study. *J Thorac Surg.* 1998; 116: 236-41.
- Hazekamp MG, Goffin YA, Huysmans HA. The value of stentless biovalve prostheses. An experimental study. *Eur J Cardiothorac Surg.* 1993; 7: 514-19.
- Sievers HH, Lange PE, Bernhard A. Implantation of a xenogeneic stentless aortic bioprosthesis. First experience. *Thorac Cardiovasc Surg.* 1985; 33: 225-6.
- Doty DB, Doty JR. Stentless Aortic valve replacement: bioprostheses. In: Cohn LH, Edmunds LH Jr, Eds. *Cardiac Surgery in the Adult.* New York: MacGraw-Hill; 2003: 889-98.
- Duran CG, Gunning AJ. A method for placing a total homologous valve in the "subcoronary" position. *Lancet.* 1962; 2: 447.
- O'Brien MF. The Cryolife-O'Brien composite aortic stentless xenograft: surgical technique of implantation. *Ann Thorac Surg.* 1995; 60: S410-13.
- Doty DB, Cafferty A, Kon ND, et al. Medtronic Freestyle aortic root bioprostheses: implant techniques. *J Card Surg.* 1998; 13: 369-75.
- Notzold A, Scharfshwerdt M, Thiede L, et al. In-vitro study on the relationship between progressive sinotubular junction dilatation and aortic regurgitation for several stentless aortic valve substitutes. *Eur J Cardiothorac Surg.* 2005; 27: 90-3.
- Collinson J, Henein M, Flather M, et al. Valve replacement for aortic stenosis in patients with poor ventricular function. Comparison of early changes with stented and stentless valves. *Circulation.* 1999; 100 (Suppl 2): II-5.
- Sintek CF, Fletcher AD, Khonsari S. Small aortic root in the elderly: use of stentless bioprosthesis. *J Heart Valve Dis.* 1996; 5 (suppl III): S308.
- Westaby S, Huysmans HA, David TE. Stentless aortic bioprostheses: compelling data from the second international symposium. *Ann Thorac Surg.* 1999; 65: 235-40.
- Fantini FA, Vrandecic MO, Gontijo Filho B, et al. Biopróteses aórticas

- porcinas, modelo convencional e sem suporte ("stentless"): estudo comparativo. *Rev Bras Cir Cardiovasc* 1998 (on line); 13:nº3. Disponível em [www.scielo.com](http://www.scielo.com). ISSN0102-7638.
19. Doty DB, Cafferty A, Cartier P, et al. Aortic valve replacement with Medtronic Freestyle bioprostheses: 5-years results. *Semin Thorac Cardiovasc Surg.* 1999; 11: 35-41.
  20. Santini F, Bertolini P, Montalbano G, et al. Hancock versus stentless bioprostheses for aortic valve replacement in patients older than 75 years. *Ann Thorac Surg.* 1998; 66: 99-103.
  21. Casali G, Auriemma S, Santini F, et al. Survival after stentless and stented xenograft aortic valve replacement: a concurrent, case-match trial. *Ital Heart J.* 2004; 5: 282-9.
  22. Gelsomino S, Frassani R DaCol P, et al. The CryoLife O'Brien stentless porcine aortic bioprostheses: 5-years follow-up. *Ann Thorac Surg.* 2001; 71:86-91.
  23. Cohen G, Christakis GT, Joyner CD, et al. Are stentless valves hemodynamically superior to stented valves? A prospective randomized trial. *Ann Thorac Surg.* 2002; 73: 767-75.
  24. Florath J, Rosendal UP, Mostasawi A, et al. Current determinants of operative mortality in 1,400 patients requiring aortic valve replacement. *Ann Thorac Surg.* 2003; 76: 75-83.
  25. Westaby S, Amaraseena N, Ormerod O, et al. Aortic valve replacement with the freestyle stentless xenograft. *Ann Thorac Surg.* 1995; 60: S422-7.
  26. Williams RJ, Muir DF, Pathi V, et al. Randomized controlled trial of stented and stentless aortic bioprostheses: hemodynamic performance at 3 years. *Semin Thorac Cardiovasc Surg.* 1999; 11: 93-7.
  27. Silberman S, Shaheen J, Merin O, et al. Exercise hemodynamics of aortic prostheses: comparison between stentless bioprostheses and mechanical valves. *Ann Thorac Surg.* 2001; 72: 1217-21.
  28. Gross C, Harringer W, Mair R, et al. Aortic valve replacement: is the stentless xenograft an alternative to the homograft? Early results of a randomized study. *Ann Thorac Surg.* 1995; 60: S418-21.
  29. Dossche K, Vanermen H, Wellens F, et al. Free-hand sewn allografts stentless (Prima-Edwards) and stented (Cesa) porcine bioprostheses: a comparative hemodynamic study. *Eur J Cardiothorac Surg.* 1995; 9: 562-7.
  30. Jin XY, Zhang ZM, Gibson DG, et al. Effects of valve substitute on changes in left ventricular function and hypertrophy after aortic valve replacement. *Ann Thorac Surg.* 1996; 62: 683-90.
  31. Jin XY, Pillai R, Westaby S. Medium-term determinants of left ventricular mass index after stentless aortic valve replacement. *Ann Thorac Surg.* 1999; 67: 411-6.
  32. Cordovil A, Campos Filho O, Moisés VA, et al. Avaliação doppler ecocardiográfica em repouso dos homoenxertos aórticos criopreservados em comparação às biopróteses sem e com suporte. *Rev Bras Ecocard.* 2004; 17: 37-45.
  33. Walther T, Falk V, Langebartels G, et al. Prospectively randomized evaluation of stentless versus conventional biological aortic valves. Impact on regression of ventricular hypertrophy. *Circulation.* 1999; 100 (Suppl 2): II6-10.
  34. Sensky PR, Loubani M, Keal RP, et al. Does the type of prostheses influence early left ventricular mass regression after aortic valve replacement? Assessment with magnet resonance imaging. *Am Heart J.* 2003; 146: 13.
  35. Bach DS, Kon ND, Dumesnil JG, et al. Eight-year after aortic valve replacement with the Freestyle stentless bioprostheses. *J Thorac Cardiovasc Surg.* 2004; 127: 1657-63.
  36. Hvass U, Baron F, Elsebaey A, et al. The Stentless Cryo-Life O'Brien porcine aortic valve at 10 years. *J Heart Valve Dis.* 2004; 13: 977-83.