

# Atypical locations of cerebral hemorrhage in newborns: considerations about two cases\*

*Apresentações de localização atípica de hemorragia no cérebro de recém-nascidos: considerações acerca de dois casos*

Alexandra Maria Vieira Monteiro<sup>1</sup>, Cláudio Márcio Amaral de Oliveira Lima<sup>2</sup>, Érica Barreiros Ribeiro<sup>2</sup>, Fernanda Camurati de Oliveira<sup>3</sup>, Silvia Miranda<sup>4</sup>, Luiz Eduardo Miranda<sup>5</sup>

**Abstract** Retrospective study of two cases of atypically localized cerebral hemorrhage among 777 newborns admitted to the neonatal intensive care unit at Casa de Saúde São José, Rio de Janeiro, RJ, Brazil. Clinical findings and imaging diagnoses were evaluated. The diagnostic effectiveness of ultrasonography was established by correlation with magnetic resonance imaging findings. Multifactorial etiology was observed, besides silent clinical presentation independently from localization. So far the neurological evaluation has satisfactorily progressed although the patients are still too young to allow a definite neurological evaluation.

**Keywords:** Brain; Newborn; Atypical hemorrhage; Posterior fossa hemorrhage; Ultrasonography; Magnetic resonance imaging.

**Resumo** Estudo retrospectivo de dois casos de hemorragia craniana de localização atípica em 777 recém-natos internados na unidade de terapia intensiva neonatal da Casa de Saúde São José, Rio de Janeiro, RJ. Foram avaliados os aspectos clínicos e o diagnóstico por métodos de imagem. Verificamos que a ultrassonografia foi diagnóstica nos dois casos quando comparada com a ressonância magnética. Em relação à etiologia, esta foi multifatorial, e a manifestação clínica silenciosa independente da localização. Até o presente momento, a avaliação neurológica tem tido curso satisfatório, embora os pacientes ainda tenham baixa idade para a avaliação neurológica definitiva.

**Unitermos:** Cérebro; Recém-natos; Hemorragia atípica; Hemorragia na fossa posterior; Ultrassonografia; Imagem por ressonância magnética.

Monteiro AMV, Lima CMAO, Ribeiro EB, Oliveira FC, Miranda S, Miranda LE. Atypical locations of cerebral hemorrhage in newborns: considerations about two cases. *Radiol Bras.* 2009;42(6):403-405.

## INTRODUCTION

Cerebrovascular diseases represent a relevant cause of brain injury in neonates<sup>(1)</sup>. Both location and etiology of cerebral hemorrhage in neonates have already been well known and described in the literature<sup>(2)</sup>. However, the understanding of the etiology of hemorrhages in atypical locations is still

to be achieved. According to the literature, the location of hypoxic lesions in neonates tends to follow the physiological course of the blood circulation, and are predominantly hemorrhagic in preterm newborns with location in the germinal matrix and peri- and/or intraventricular region through the ventriculopetal branches<sup>(2)</sup>. In term newborns, these lesions are predominantly ischemic and located in the basal ganglia and cortical-subcortical regions of the brain through the ventriculofugal circulation<sup>(2)</sup>. Generally, the physiopathology of hypoxic lesions in the neonatal period occurs as a result from the loss of self-regulation with the consequential brain injury with different aspects and degrees, according to the level of development of the cerebrovascular system at the different gestational ages<sup>(3)</sup>.

The utilization of imaging methods in patients of this age range has allowed an early and accurate diagnosis of lesions, with transfontanel ultrasonography (TFUS)

playing the most relevant role as compared with other imaging methods, besides being noninvasive, reproducible, portable and not requiring sedation<sup>(4)</sup>. However, magnetic resonance imaging (MRI) is the gold standard for the diagnosis although the necessity of sedation and refrigerated environment still represent a restriction to its frequent utilization in these patients<sup>(5,6)</sup>.

The present study was aimed at correlating TFUS and MRI findings, determining the hemorrhage location and clinical manifestations, describing possible etiologic factors as well as the neurological development up to the present moment by means of considerations about two cases of atypical presentation of hemorrhage in newborns of a population admitted to a neonatal intensive care unit.

## CASES REPORT

In the period from March/2004 to April/2007, 777 neonates were admitted and sub-

\* Study developed at Casa de Saúde São José (CSSJ-RJ), Rio de Janeiro, RJ, Brazil.

1. PhD, MD, Radiologist at Casa de Saúde São José (CSSJ-RJ), Associate Professor of Radiology, Faculdade de Ciências Médicas da Universidade do Estado do Rio de Janeiro (FCM-UERJ), Rio de Janeiro, RJ, Brazil.

2. MDs, Radiologists, Unit of Magnetic Resonance Imaging - Hospital São José and Clínica Dr. Flávio Althoff, Criciúma, SC, Brazil.

3. MD, Radiologist, Pontifícia Universidade Católica do Rio de Janeiro (PUC-Rio), Rio de Janeiro, RJ, Brazil.

4. MD, Pediatric Neurologist at Neonatal Intensive Care Unit, Casa de Saúde São José (CSSJ-RJ), Rio de Janeiro, RJ, Brazil.

5. MD, Neonatologist, Head for the Neonatal Intensive Care Unit, Casa de Saúde São José (CSSJ-RJ), Rio de Janeiro, RJ, Brazil.

Mailing address: Dr. Cláudio Márcio Amaral de Oliveira Lima. Rua São José, 322, Centro. Criciúma, SC, 88801-520, Brazil. E-mail: cmaol@br.inter.net; cmaolima@gmail.com

Received May 7, 2008. Accepted after revision June 10, 2008.

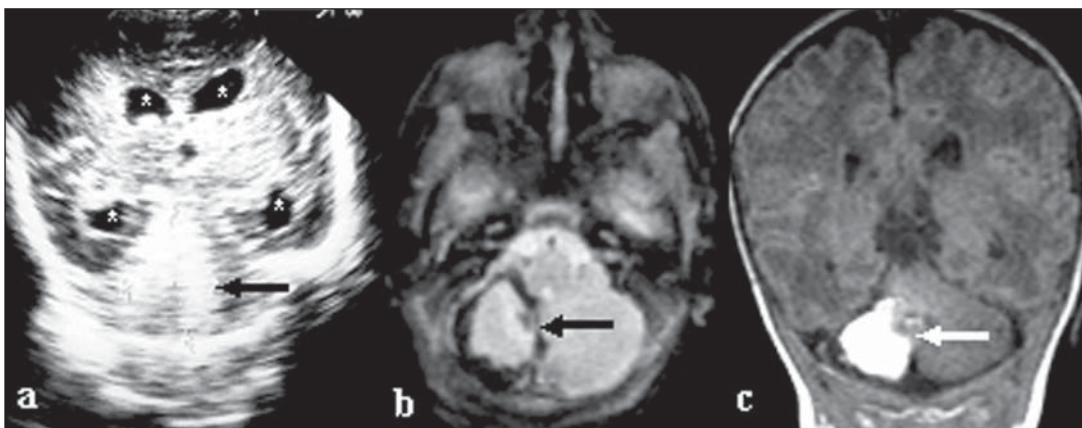
mitted to ultrasonography (US) at the neonatal intensive care unit (ICU) of Casa de Saúde São José, in the city of Rio de Janeiro, RJ, Brazil. Two of these patients underwent TFUS, being diagnosed with atypically localized brain hemorrhage later confirmed by MRI that is the method considered as the gold standard for such diagnosis.

**Case 1** – Female, preterm, underweight (1470 g) newborn of a triplet gestation, with AB blood type, positive Rh factor, membranes rupture during labor, Apgar 3/6, requiring reanimation with positive pressure ventilation through orotracheal tube. Maximum total bilirubin level was 14.5. The patient remained under phototherapy for eight days. Hyaline membrane disease was found and the neonate received a surfactant dose at the first hours of life. Neonatal ICU discharge occurred 31 days after admission, with a weight gain of 790 g

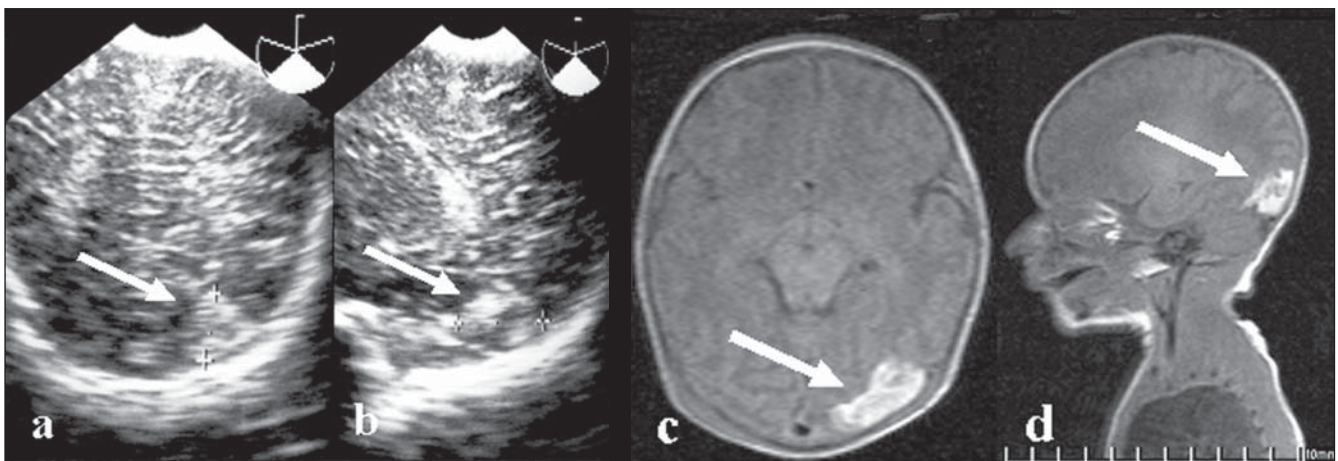
(total weight 2260 g). Echocardiogram was performed at the first day of life, demonstrating patent foramen ovale and persistent arterial canal with no significant clinical repercussion, besides subtle pulmonary artery hypertension. At the second day of life, the neonate was submitted to TFUS that demonstrated symmetrical, bilateral supratentorial ventricular dilatation and a hyperechogenic lesion in the right cerebellar hemisphere, measuring  $2.7 \times 2.1$  cm. At 29 days of life, MRI identified the hematoma in the right cerebellar hemisphere and in the postero-inferior region of the left cerebellar hemisphere, without dilatation of the ventricular system (Figure 1). Magnetic resonance angiography (MRA) was normal.

**Case 2** – Male, term newborn, with birth weight of 2145 g, B blood type, positive Rh factor, normal labor and membrane rupture during the labor at the 37th gesta-

tional week, Apgar 6/8, requiring reanimation with positive pressure mask ventilation. Delayed intrauterine development and early, symptomatic polycythemia. The neonate was admitted to the neonatal ICU because of hypoglycemia. The patients progressed with concussion and hypoglycemia (glycemia of 26 mg/dl). Concussion improved with the hypoglycemia correction. A partial exogenous blood transfusion was performed through umbilical venous catheter. Echocardiogram performed one day after birth demonstrated small, persistent arterial canal with diastolic flow. The patient remained in the ICU for ten days. At the fifth day, TFUS demonstrated an echogenic image with hypoechoic center measuring about 2.0 cm in the left occipital lobe. At the eighth day, cranial MRI with MRA identified hematoma with low fluid level in the left occipital lobe (Figure 2).



**Figure 1.** Coronal TFUS (a), Axial MRI T2-weighted image (b) and coronal T1-weighted image (c) demonstrating hematoma in the right cerebellar hemisphere (arrows). Also, dilatation of the ventricular system (asterisks) is observed at TFUS.



**Figure 2.** Axial (a) and sagittal (b) TFUS, and MRI T1-weighted images in the axial (c) and sagittal (d) planes demonstrating the hematoma in the left occipital lobe (arrows).

## DISCUSSION

According to the literature, atypical location of brain hemorrhage in newborns is found in exactly 0.25% of cases. Ghazi-Birry et al.<sup>(4)</sup> have proposed that such location can be explained by the presence of germinal matrix not only in the caudo-thalamic region, but also in other regions such as occipital and temporal horn of the lateral ventricles, and in the infratentorial cerebellar region. In these locations, the germinal matrix rarely generates bleeding after 32 weeks of gestation since it has already practically disappeared. In atypical cases, it is admitted that persistence of this matrix may occur, therefore increasing the incidence of bleedings<sup>(2)</sup>.

Intracranial hemorrhages are frequent in preterm newborns, with highest prevalence in this age range<sup>(7)</sup>, possibly affecting up to 40% newborns with gestational age < 32 weeks and birth-weight < 1500 g<sup>(5)</sup>. On the other hand, brain hemorrhages are less frequent in term newborns, with prevalence of 26% in asymptomatic newborns after vaginal delivery<sup>(8)</sup>. Frequently, such hemorrhages are associated with apnea, bradycardia and convulsions, with several factors being related to increased risk, particularly peripartum complications such as prolonged labor, use of forceps and fetal underweight<sup>(8)</sup>.

In the present study, the authors could not isolate a single factor, as those described by other authors<sup>(1,3,7,8)</sup> identifying factors such as tocotraumatism, hypoxia, hypoglycemia, hyaline membrane disease and preterm delivery, among others.

Moura-Ribeiro et al.<sup>(9)</sup> have reported that, at this age range, the majority of cerebrovascular diseases present with sometimes severe seizures about 24–48 postnatal hours, even with a generally normal Apgar index; and within few days may progress to hemiparesis, hypotonia, tonus

asymmetry, drowsiness or irritability and also sucking difficulty<sup>(1)</sup>, differently from the present study where a neonate (case 2) initially presented concussion probably related to hypoglycemia. Campos-Castelló et al.<sup>(3)</sup> have also reported the presence of hydrocephalus that may vary according to the extent and time of hemorrhage onset. In the present case, with presentation in the cerebellum (case 1), the authors identified an association with transitory hydrocephalus with spontaneous resolution confirmed by MRI.

As regards imaging diagnosis, several authors<sup>(2,6,9,10)</sup> agree that TFUS should be the initial method of choice in the evaluation of a newborn brain. As far the location in the cerebellum is concerned, the majority of findings was unilateral (71%) with predominance for the right hemisphere (64% at right *versus* 36% at left), in agreement with the results of the present study. Other authors<sup>(4,10)</sup> also report a persistence of lesions at US, on average, for four to six weeks.

It is a consensus that MRI is the gold standard for the diagnosis of cerebral lesions<sup>(6,8)</sup>, also with the assertion of the feasibility of the study by functional MRI to stratify the newborns with highest risk for neurological damage, especially in the presence of an association with risk factors such as US demonstrating intraventricular hemorrhage at birth, among others<sup>(10)</sup>.

Generally, cerebellar hemorrhages develop with hydrocephalus or ataxic syndromes, or even delayed cognitive development with cerebellar atrophy in most of patients who survive<sup>(3)</sup>. In the present study, the patients are still too young to allow a definite neurological evaluation.

## CONCLUSION

Transfontanel ultrasonography was diagnostic for atypical presentation of cere-

bral hemorrhage in newborns as compared with MRI. The clinical presentation was silent and, up to the present moment, the neurological development has been satisfactory, although the low age of the children precludes a definite evaluation.

## REFERENCES

1. Moura-Ribeiro MVL, Pessoto MA, Marba STM. Cerebrovascular disease in neonates: evaluation of four cases. *Arq Neuropsiquiatr.* 1999;57:84–7.
2. Kaske TI, Rumack CM, Harlow CL. Imagens do cérebro de neonatos e crianças. In: Rumack CM, Wilson SR, Charboneau JW, editores. *Tratado de ultra-sonografia diagnóstica.* 2ª ed. Rio de Janeiro: Guanabara Koogan; 1999. p. 1250–7.
3. Campos-Castelló J, Canelón de López MS, Santiago-Gómez R. Accidentes vasculares isquémicos y hemorrágicos cerebrales del recién nacido a término. *Protocolo de estudio y orientaciones terapéuticas.* *Rev Neurol.* 2000;31:632–44.
4. Ghazi-Birry HS, Brown WR, Moody DM, et al. Human germinal matrix: venous origin of hemorrhage and vascular characteristics. *AJNR Am J Neuroradiol.* 1997;18:219–29.
5. Antoniuk S, Silva RVC. Hemorragia periventricular e intraventricular de recién nacidos prematuros. *Rev Neurol.* 2000;31:238–43.
6. Miller SP, Cozzio CC, Goldstein RB, et al. Comparing the diagnosis of white matter injury in premature newborns with serial MR imaging and transfontanel ultrasonography findings. *AJNR Am J Neuroradiol.* 2003;24:1661–9.
7. Farage L, Assis MC. Achados ultra-sonográficos da hemorragia intracraniana em recém-nascidos prematuros. *Arq Neuropsiquiatr.* 2005;63:814–6.
8. Looney CB, Smith JK, Merck LH, et al. Intracranial hemorrhage in asymptomatic neonates: prevalence on MR images and relationship to obstetric and neonatal risk factors. *Radiology.* 2007;242:535–41.
9. Moura-Ribeiro MVL, Ciasca SM, Vale-Cavalcanti M, et al. Cerebrovascular disease in newborn infants: report of three cases with clinical follow-up and brain SPECT imaging. *Arq Neuropsiquiatr.* 1999;57:1005–10.
10. Monteiro AMV, Marchiori E, Lopes JMA. O Doppler colorido na avaliação do fluxo arterial cerebral em recém-natos normais. Influência da sucção ao seio materno. *Radiol Bras.* 1999;32:11–9.