

Minilaparoscopy-assisted transumbilical laparoscopic cholecystectomy

Colecistectomia laparoscópica umbilical assistida por minilaparoscopia

GERALDO JOSÉ DE SOUZA LIMA, TCBC-MG¹; RODRIGO FABIANO GUEDES LEITE, TCBC-MG¹; GUSTAVO MUNAYER ABRAS, ACBC-MG¹; LIVIO JOSÉ SURETTI PIRES, TCBC-MG¹; EDUARDO GODOY CASTRO, ACBC-MG¹.

ABSTRACT

The role of laparoscopy in the modern surgery era is well established. With the prospect of being able to improve the already privileged current situation, new alternatives have been proposed, such as natural orifice endoscopic surgery (NOTES), the method for single transumbilical access (LESS – Laparo-endoscopic single-site surgery) and minilaparoscopy (MINI). The technique proposed by the authors uses a laparoscope with an operative channel like the flexible endoscope used in NOTES. All operative times are carried out through the umbilical trocar as in LESS, and assisted by a minilaparoscopy grasper. This new technic combines, and results from, the rationalization of technical particularities and synergy of these three approaches, seeking to join their advantages and minimize their disadvantages.

Keywords: Surgical Procedures, Operative. Minimally Invasive Surgical. Cholecystectomy. Cholecystectomy, Laparoscopic. Video-assisted Surgery.

INTRODUCTION

The role of laparoscopic surgery in the modern age is well established. With the prospect of improving the already privileged current situation, new alternatives have been proposed, such as surgery through natural orifices (NOTES) and the Laparo-endoscopic single-site surgery (LESS). At the same time, minilaparoscopy (MINI) returned to the agenda with the advent of greater resistance miniaturized grippers.

Among the main indications for minimally invasive techniques, there is cholecystectomy, the most commonly performed surgical procedure in the West¹. The available literature shows no consensus on the best technical alternative to classic laparoscopic cholecystectomy (LC). In the literature review conducted by Gaillard et al., comparing the single-access approaches NOTES with minilaparoscopy, they found that none of these procedures showed benefits superior to LC¹. Sulu et al. compared the cholecystectomies performed by the four-trocar classic laparoscopic access with those carried out by LESS and found no significant advantages of the latter technique². Sinha et al. compared LC with LESS cholecystectomy using multiple transumbilical portals and conventional instruments³. LESS showed results comparable to LC, but

with longer operative time³. In a randomized study, Dabbagh et al. compared cholecystectomies performed by LESS and MINI techniques. Despite displaying the same postoperative complications rates, the minilaparoscopy approach had lower operative time and hospital stay⁴.

In this context, and taking into account the experience of our group in single-access surgery with an endoscope with an operative channel, we set up a fertile environment to the introduction of Laparoscopic Umbilical Monomini Assisted Surgery (LUMAS). In general, this proposed surgical therapy rests on the argument of combining technical features and the synergism of NOTES, LESS and MINI.

TECHNICAL ASPECTS

Patient, surgical team and equipment positions

We place the patient in supine with the legs separated. The surgeon stands between the legs of the patient and his assistant is on his left (patient's right), facing the laparoscopy equipment, positioned to the patient's right at the level of shoulder.

Laparoscopy instruments and accessories

The equipment used were: 1) Endoscope with 11mm diameter and 37.5cm length, with a Palmer-

1 - Serviço de Cirurgia Geral e Laparoscópica do Hospital Madre Teresa, Belo Horizonte, MG, Brasil.

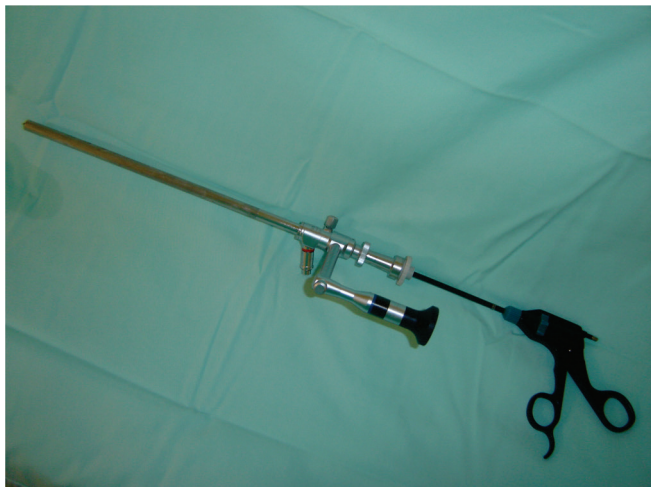

Figura 1. Óptica laparoscópica com canal operatório.

-type 5mm operative channel (Ref: S26034AA, Richard Wolf GmbH, Knitt Knittlingen, Germany) (Figure 1); 2) a 12mm reusable trocar; 3) a 5mm diameter and 43cm in length, curved, rotational, isolated, unipolar Maryland forceps for dissection and grasping; 4) a 5mm in diameter and 43cm in length, curved, rotational, isolated; 5) a 5mm in diameter and 43cm in length, reusable, rotational Hem-o-lok applicator; 6) a 5mm in diameter and 43cm in length, isolated, unipolar Hook clamp; 7) a 5mm in diameter and 43cm in length endoscopic cannula to suction and irrigation; 8) a 3mm in diameter and 36cm long, rotational, isolated grasping forceps (minilaparoscopy).

Operative technique

We conducted a single curvilinear incision of 12mm in the lower umbilical fold. We instilled the pneumoperitoneum through a Veress needle and introduced a 12mm trocar, maintaining the insufflation pressure at 15mmHg. Next, was inserted the Palmer endoscope into the cavity through the umbilical trocar with the Maryland forceps within its working channel. The minilaparoscopy forceps was introduced directly through a 3mm incision at the mid-axillary line level in the right flank under vision and without the need of a trocar (Figure 2). We then percutaneously introduced a 0 multifilament suture with straight needle in the right costal margin, lateral to the midclavicular line. Once inside the cavity, the needle transfixated the gallbladder fundus guided by the Maryland

forceps inside the Palmer endoscope, and then exteriorized near the point of its introduction, exerting the required traction to approach the gallbladder to the abdominal wall and facilitate the exposure of the gallbladder pedicle.

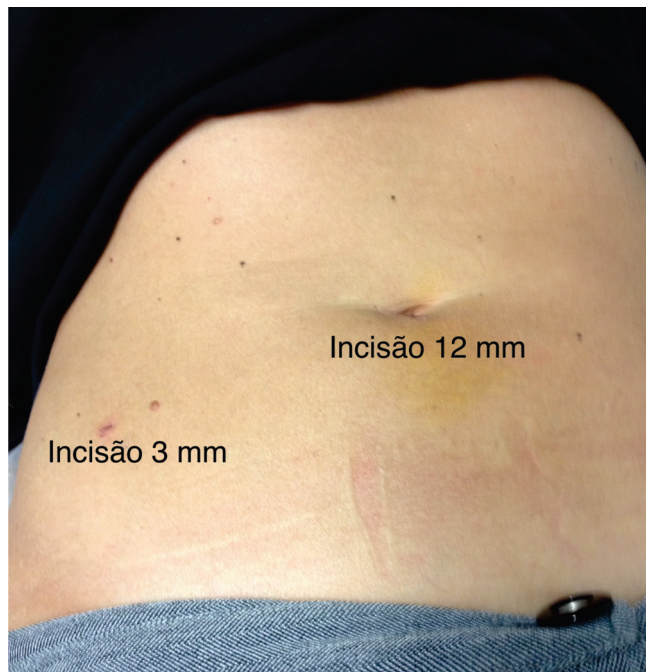


Figura 2. Localização das incisões cirúrgicas.

We performed the dissection of the cystic duct and cystic artery in the usual way with the Maryland forceps, associated with counter-traction of the gallbladder infundibulum exerted by the minilaparoscopy clamp. We ligated the cystic structures with the hem-lok-type clip deployed by a clip applicator entered through the operative channel of the Palmer endoscope. Once ligated, the pedicle elements were cut by curved scissors and we proceeded to release the gallbladder from the liver bed with cautery through the hook (both instruments introduced by the endoscope's working channel) with sustained traction by the minilaparoscopy clamp. Before completing the separation of the gallbladder and liver, we took the advantage of the exhibition to double-check the clips and hemostasis of the bloody area. We extracted the gallbladder through the umbilical trocar, by grasping its neck with the Maryland forceps, after releasing the extracorporeal suture from the gallbladder fundus. We proceeded to the aponeurotic suture of the umbilical trocar orifice with a 0 Vicryl® "X" stitch or continuous suture, depending on the

need to expand the incision. Modern endoscopes provide adequate visibility and their angulation favors the secure identification of the biliary pedicle elements.

DISCUSSION

Minimally invasive surgery has been introducing alternatives to LC, aiming to reduce surgical trauma and achieve better cosmetic results. These alternatives are minilaparoscopy cholecystectomy (C-MINI), Laparo-endoscopic single-site (C-LESS) and removal of the gallbladder through natural orifices (C-NOTES).

C-MINI uses 2mm and 3mm instruments and retains the classic arrangement of four trocars with an 11mm incision in the umbilical level. This approach minimizes the parietal trauma and promotes better aesthetic results compared with LC⁵. However, mini-instruments and the miniaturized endoscope are more fragile and less durable, less effective in grasping and more expensive⁶. However, C-MINI has not been completely abandoned and continued to be improved, becoming less labor intensive and less expensive by dispensing the clamping of pedicle elements and using a 10mm endoscope⁵.

Takur *et al.*, by means of a meta-analysis, compared the C-MINI with LC⁷. Minilaparoscopy tended to lower incidence of adverse events, earlier return to normal activities and better aesthetic results.

LESS requires the expansion of the umbilical incision for the introduction of multiple trocars or devices with three or four ports. The technique enables the use of widely available and regularly used instruments, and potentially minimizes parietal trauma in the case of removal of larger surgical specimens, since it dispenses performing minilaparotomies for the removal of organs. In operations for the extraction of the gallbladder, appendix and uterine attachments, its use becomes therefore controversial, since it would only entail better aesthetic result. Additional disadvantages of this method are the intraabdominal extra collisions of instruments and reduced triangulation.

Bucher *et al.*, when comparing C-LESS with LC in a randomized study, concluded that the single-access route promotes better cosmetic results, less pain and ear-

lier return to normal activities⁸. However, other studies reported higher incidence of parietal and biliary complications related to C-LESS^{9,10}.

NOTES proposes new accesses and ways to perform minimally invasive operations, in an attempt to reduce surgical trauma and eliminate the complications and parietal scarring. However, it requires knowledge and experience in advanced endoscopy and the use of flexible endoscopic equipment and instruments, which hinders their incorporation by most surgeons. Moreover, these procedures generate some degree of contamination of the peritoneal cavity and closing of the viscera still lacks effective known techniques^{11,12}.

These alternative procedures to LC provide better cosmetic results, but do not cause significant advantages over the reduction of postoperative pain, shorter hospital stay, earlier return to normal activities and lower immune response^{13,14}.

In this context, it seems logical to search for less invasive alternatives to achieve objectives other than the aesthetic ones. Our group proposed this tactical option when using the endoscope with an operative channel (Palmer), with minimization of C-MINI, to perform the procedure only with an 11mm umbilical access and another 3mm incision on the right flank.

In the proposed laparoscopic technique (micro-mini cholecystectomy), the forceps introduced through the endoscope operative channel replaces the subxiphoid trocar, the transmural suture replaces the gallbladder fundus tweezers, and minilaparoscopy forceps replaces the gallbladder infundibulum grasper. The Palmer endoscope is manipulated by the surgeon, who performs the main operative times and handles the camera.

The control of gallbladder pedicle elements is made by means of the hem-o-lok clip applicator. The advantages of this clips type compared with the metal ones are: a) they are radiolucent; b) they provide greater security in ligation, since they have a closing system by lock, which is only triggered if the structure is smaller than the clip range; c) they allow to undo a ligation without damaging the structure; d) they withstand higher pressures; e) and one may safely use monopolar cautery near them. The disadvantage of the higher cost of this device is overcome

by the replacement of the disposable trocar, reimbursed by health insurance plans, by the reusable one.

Micromini cholecystectomy, as the C-MINI, is attractive when compared with C-LESS and C-NOTES, since it: a) keeps triangulation and proper trine of the Callot's triangle; b) allows the non-static lateral traction of the gallbladder infundibulum; c) Traction is more accessible from the training point of view; avoids intra and extra-abdominal instruments collisions and reversed hands motion.

The initial investment in the acquisition of an endoscope with an operative channel is offset by the significant number, in our service, of single-access transumbilical video-assisted appendectomies, laparoscopies for diagnosis and lysis of adhesions in gynecological interventions, and for performing classical laparoscopic cholecystectomies and appendectomies, subtracting one of the trocars. In our experience in LESS cholecystectomy, this endoscope minimizes the collision of instruments, since only two trocars are necessary in the umbilical incision, helping to overcome this limiting factor inherent to this method.

Carvalho *et al.* demonstrated, by means of a mathematical model, that the miniaturization of the gras-

pers results in considerable reduction of parietal trauma, compared with the usual 10mm and 5mm trocars¹⁵. Thus, the micromini cholecystectomy justifies its designation, for it dispenses the subxiphoid 3mm and the midclavicular line 2mm portals of the classic C-MINI.

By consulting the literature using the Pubmed platform, we found the description of cholecystectomy performed with an endoscope with an operative channel and single umbilical access, aided by extracorporeal suture manipulated by crochet needles. We believe that when we use the minilaparoscopy forceps we achieved a more effective traction and exposure of the gallbladder, with greater dynamism and comfort^{6,16}.

We believe that the future of minimally invasive surgery is the combination of NOTES, LESS and minilaparoscopy. The micromini uses an endoscope with a working channel, such as the NOTES flexible endoscope, carries out all operative times through the umbilical trocar, as in LESS, and is assisted by a minilaparoscopy clamp. We can therefore say that the technique herein proposed combines, and results from, the rationalization of technical features and the synergism of these three approaches, seeking to aggregate their advantages and minimize their disadvantages, hoping to achieve less invasiveness.

R E S U M O

O papel da videolaparoscopia na era moderna da cirurgia encontra-se bem estabelecido. Com a perspectiva de ser possível melhorar a já privilegiada situação atual, novas alternativas têm sido propostas, como a cirurgia por orifícios naturais (NOTES), o método por acesso único transumbilical (LESS - Laparo-endoscopic single-site surgery) e a minilaparoscopia (MINI). A técnica proposta pelos autores utiliza-se de óptica com canal de trabalho como o endoscópio flexível do NOTES, executa-se todos os tempos operatórios pelo trocarte umbilical, como no LESS, e é assistido por pinça de minilaparoscopia. Esta nova técnica combina e resulta da racionalização de particularidades técnicas e do sinergismo destas três abordagens, buscando agregar suas vantagens e minimizar as suas desvantagens.

Descritores: Procedimentos Cirúrgicos Operatórios. Procedimentos Cirúrgicos Minimamente Invasivos. Colecistectomia. Colecistectomia Laparoscópica. Cirurgia Videoassistida.

REFERENCES

1. Gaillard M, Tranchart H, Lainas P, Dagher I. New minimally invasive approaches for cholecystectomy: review of literature. *World J Gastrointest Surg.* 2015;7(10):243-8.
2. Sulu B, Yildiz BD, Ilingi ED, Gunerhan Y, Cakmur H, Anuk T, et al. Single port vs. four port cholecystectomy-randomized trial on quality of life. *Adv Clin Exp Med.* 2015;24(3):469-73.
3. Sinha R, Yadav AS. Transumbilical single incision laparoscopic cholecystectomy with conventional instruments: a continuing study. *J Minim Access Surg.* 2014;10(4):175-9.
4. Dabbagh N, Soroosh A, Khorgami Z, Shojaeifard A, Jafari M, Abdehgah AG, et al. Single-incision laparoscopic cholecystectomy versus mini-laparoscopic cholecystectomy: a randomized clinical trial study. 2015;20(12):1153-9.

5. Carvalho GL, Silva FW, Silva JS, de Albuquerque PP, Coelho Rde M, Vilaça TG, et al. Needlescopic clipless cholecystectomy as an efficient, safe, and cost-effective alternative with diminutive scars: the first 1000 cases. *Surg Laparosc Endosc Percutan Tech*. 2009;19(5):368-72.
 6. Zomora-Sarabia F, Pérez-Ponce M, Noya-Vicente J, Andrade-Hernández A, González-Pinilla D. Colecistectomia laparoscópica con un sólo puerto umbilical: sin huella: reporte de 3 casos en Venezuela. *Rev venez cir*. 2008;61(4):171-6.
 7. Thakur V, Schlachta CM, Jayaraman S. Minilaparoscopic versus conventional laparoscopic cholecystectomy a systematic review and meta-analysis. *Ann Surg*. 2011;253(2):244-58.
 8. Bucher P, Pugin F, Buchs NC, Ostermann S, Morel P. Randomized clinical trial of laparoendoscopic single-site versus conventional laparoscopic cholecystectomy. *Br J Surg*. 2011;98(12):1695-702.
 9. Garg P, Thakur JD, Singh I, Nain N, Mittal G, Gupta V. A prospective controlled trial comparing single-incision and conventional laparoscopic cholecystectomy: caution before damage control. *Surg Laparosc Endosc Percutan Tech*. 2014;22(3):220-5.
 10. Jørgensen LN, Rosenberg J, Al-Tayar H, Assaadzadeh S, Helgstrand F, Bisgaard T. Randomized clinical trial of single- versus multi-incision laparoscopic cholecystectomy. *Br J Surg*. 2014;101(4):347-55.
 11. Noguera JF, Cuadrado A, Dolz C, Olea JM, García JC. Prospective randomized clinical trial comparing laparoscopic cholecystectomy and hybrid natural orifice transumbilical endoscopic surgery (NOTES) (NCT00835250). *Surg Endosc*. 2012;26(12):3435-41.
 12. Sodergren Mh, Clark J, Athanasiou T, Teare J, Yang GZ, Darzi A. Natural orifice transluminal endoscopic surgery: critical appraisal of applications in clinical practice. *Surg Endosc*. 2009;23(4):680-7.
 13. Cuesta MA, Berends F, Veenhof AA. The "invisible cholecystectomy": a transumbilical laparoscopic operation without a scar. *Surg Endosc*. 2008;22(5):1211-3.
 14. Saad S, Strassel V, Sauerland S. Randomized clinical trial of single-port, minilaparoscopic and conventional laparoscopic cholecystectomy. *Br J Surg*. 2013;100(3):339-49.
 15. de Carvalho GL, Cavazzola LT. Can mathematic formulas help us with our patients? *Surg Endosc*. 2011;25(1):336-7.
 16. Dávila ÁF, Sandoval RJ, Montero PJJ, Dávila ÁU, Dávila ZMR, Alonso RJM, et al. Substitución de puertos por agujas percutáneas en cirugía endoscópica. *Rev Mex Cir Endoscop*. 2004;5(4):172-8.
- Recebido em: 28/01/2016
Aceito para publicação em: 28/04/2016
Conflito de interesse: nenhum.
Fonte de financiamento: nenhuma.
- Endereço para correspondência:**
Geraldo José de Souza Lima
E-mail: geraldos.lima@terra.com.br / cirurgia.geral@hospitalmadreteresa.org.br