

Morphological and immunohistochemical characterization of angiogenic and apoptotic factors and the expression of thyroid receptors in the ovary of tilapia *Oreochromis niloticus* in captivity¹

Fernanda C. Santos², Juneo F. Silva², Jankerle N. Boeloni², Edgar Teixeira³, Eduardo M. Turra², Rogéria Serakides² and Natália M. Ocarino^{2*}

ABSTRACT- Santos F.C., Silva J.F., Boeloni J.N., Teixeira E., Turra E.M., Serakides R. & Ocarino N.M. 2015. **Morphological and immunohistochemical characterization of angiogenic and apoptotic factors and the expression of thyroid receptors in the ovary of tilapia *Oreochromis niloticus* in captivity.** *Pesquisa Veterinária Brasileira* 35(4):371-376. Escola de Veterinária, Universidade Federal de Minas Gerais, Av. Pres. Antônio Carlos 6627, Belo Horizonte, MG 31270-901, Brazil. E-mail: nataliaocarino@gmail.com

Morphological and immunohistochemical characterization of angiogenic and apoptotic factors and the expression of thyroid receptors in the ovary of tilapia *Oreochromis niloticus* in captivity were studied. The morphological evaluation of the ovaries was performed by histological paraffin embedded and stained with HE. The immunohistochemical expressions of CDC47, VEGF, Flk-1, angiopoietin, Tie-2 and thyroid receptor (TR α) were performed by the technique of streptavidin-biotin-peroxidase. Apoptosis was assessed using the TUNEL kit. The relative expression of thyroid hormone receptors (TR α and TR β) was assessed by RT-PCR real time. The nuclear expression of CDC47 increased with the stage of maturation of the oocyte and was observed in the follicle cells. Apoptotic bodies were observed in the follicular cells of atretic follicles and postovulatory follicles from the ovaries of 150g and 350g fish. Expression of VEGF and its receptor Flk-1 was also observed in the follicular cells, and the expression of both increased with the maturity of the oocyte, with a higher intensity observed in the full-grown follicle. The expression of angiopoietin and of its receptor (Tie 2) was discrete and moderate respectively. TR α expression was independent of follicular development. However, the 350 g tilapia exhibited higher expression of TR β compared with the 50 g tilapia. We conclude that the proliferative activity and the expression of VEGF and its receptor increase with follicular maturation and that the TRs expression increases with ovarian maturity in tilapia (*Oreochromis niloticus*).

INDEX TERMS: Angiogenic factor, apoptotic factor, thyroid receptors, ovary, tilapia, *Oreochromis niloticus*, fish, immunohistochemistry.

RESUMO.- [Caracterização morfológica e imuno-histoquímica de fatores angiogênicos e apoptóticos e da expressão de receptores tireoidianos no ovário de tilápia

***Oreochromis niloticus* em cativeiro.]** Foram estudadas as caracterizações morfológica e imuno-histoquímica de fatores angiogênicos e apoptóticos e a expressão de receptores tireoidianos no ovário de tilápia *Oreochromis niloticus* de cativeiro. A avaliação morfológica dos ovários foi realizada por cortes histológicos incluídos em parafina e corados por HE. As expressões imuno-histoquímicas de CDC47, VEGF e seu receptor Flk-1, angiopoietina e seu receptor Tie-2 e receptor tireoidiano (TR α) foram realizadas pela técnica de estreptavidina-biotina-peroxidase. A apoptose foi avaliada utilizando-se kit de TUNEL. A expressão relativa dos receptores de hormônios tireoidianos (TR α e TR β) foi ava-

¹ Received on July 28, 2014.

Accepted for publication on January 25, 2015.

² Laboratório de Patologia, Departamento de Clínica e Cirurgia Veterinárias, Escola de Veterinária (EV), Universidade Federal de Minas Gerais (UFMG), Av. Pres. Antônio Carlos 6627, Belo Horizonte, MG 31270-901, Brazil. E-mails: fernandacsantos.bio@gmail.com, vet_junior@yahoo.com.br, jankerle@gmail.com, eduardoturra@yahoo.com.br, serakidesufmg@gmail.com; *Corresponding author: nataliaocarino@gmail.com

³ Laboratório de Aquicultura, EV-UFMG, Av. Pres. Antônio Carlos 6627, Belo Horizonte, MG 31270-901. E-mail: edgarvet@hotmail.com

liada pela técnica de RT-PCR tempo real. A expressão nuclear de CDC47 aumentou com a fase de maturação do oócito e foi observada nas células foliculares. Corpos apoptóticos foram observados nas células foliculares de folículos atrésicos e folículos pós-ovulatórios de ovários de peixes com 150g e 350g. A expressão de VEGF e do seu receptor Flk-1 foi também observada nas células foliculares, e a expressão de ambos aumentou com a maturidade do oócito, com uma maior intensidade no folículo maduro. A expressão de angiopoietina e do seu receptor (Tie 2) foi discreta e moderada, respectivamente. A expressão de TR α foi independente do desenvolvimento folicular. No entanto, a tilápia de 350g apresentou maior expressão de TR β em comparação com a tilápia de 50g. Conclui-se que a atividade proliferativa e a expressão de VEGF e de seu receptor aumenta com a maturação folicular e que a expressão dos TRs aumenta com a maturidade do ovário em tilápia (*Oreochromis niloticus*).

TERMOS DE INDEXAÇÃO: Fator angiogênico, fator apoptótico, receptores tireoidianos, ovário, tilápia, *Oreochromis niloticus*, peixe, imuno-histoquímica.

INTRODUCTION

The practice of aquaculture has been growing every year, and there is an increasing desire to introduce native fish species in the practice of commercial production. However, several species of migratory fish, which have high commercial value, do not reproduce spontaneously in captivity (Santos et. al. 2008a), which has limited the cultivation of these fish species.

Tilapia (*Oreochromis* sp.) is a highly prolific species, but little is known about its ovarian morphophysiology. The morphology of the female reproductive system is highly variable in teleosts (Tyler 1996). Knowledge of the morphological and physiological characteristics of the ovaries is important for understanding the reproduction of any type of fish. Thus, understanding the reproductive characteristics of tilapia, including the proliferative activity, angiogenesis, apoptosis and expression of thyroid hormones receptors during oocyte development and during ovary maturation, may be important for the development of reproductive techniques that permit the maturation and induction of spawning effectively in the migratory species in captive.

The objective of this study was to characterise morphologically, the ovaries of tilapia with respect to proliferative activity, angiogenesis, apoptosis and expression of thyroid hormone receptors.

MATERIALS AND METHODS

Eighteen tilapia (*Oreochromis niloticus*) with weights of 50g, 150g and 350g grown in captivity and kept in a closed system of recirculating water in the Aquaculture Laboratory (LaQua) from the Veterinary School of *Universidade Federal de Minas Gerais* (UFMG) were used. The system allowed for the on-going maintenance of water quality and temperature at $26 \pm 0.5^\circ\text{C}$. The variables of water quality, dissolved oxygen, pH and temperature were monitored daily, and nitrite and total ammonia levels were measured weekly. The fish were fed a commercial diet with 36% crude protein twice daily in an amount close to 3% of the stored biomass.

The fish were divided into three groups by weight with six

animals per group: group 1 consisted of 50 g fish, group 2 consisted of 150g fish, and group 3 consisted of 350g fish. The weights were chosen to provide the assessment of oocyte development in several stages. The animals were euthanised according to the protocol approved by the ethics committee on animal experimentation (CETEA/UFMG). Fragments of the right and left ovaries were fixed in Bouin's and paraformaldehyde, processed by routine techniques, paraffin embedded and stained with hematoxylin and eosin for morphological analysis, immunohistochemistry and TUNEL, respectively. Morphologic analysis and the maturation stage of the oocytes were determined according to the classification recommended by Bazzoli et. al. (2014). Fragments of the right and left ovaries were also frozen at -80°C to determine the relative expression of thyroid hormone receptors (TR α and TR β) by real-time RT-PCR.

The ovarian follicles were classified according to the stage of development as early and late primary growth, early secondary growth and full-grown follicles, postovulatory follicle and atretic follicles. Morphological analysis was performed descriptively with respect to the classification of the stage of follicular.

Histological sections of the ovaries were subjected to immunohistochemical analysis to evaluate the proliferative and angiogenic activities and expression of thyroid hormone receptor (TR α) using the following antibodies: anti-VEGF (*vascular endothelial growth factor*: sc-152, Santa Cruz Biotechnology, CA, USA), anti-Flk1 (receptor for vascular endothelial growth factor: sc-6251, Santa Cruz Biotechnology, CA, USA), anti-angiopoietin 2 (Santa Cruz Biotechnology, CA, USA), anti-Tie2 (angiopoietin receptor: Santa Cruz Biotechnology, CA, USA), anti-CDC47 (47DC141, Neomarkers, Fremont, CA, USA), and anti-TR α (α thyroid hormone receptor: Abcam, Cambridge, UK).

Biotin-streptavidin peroxidase (Streptavidin Peroxidase, Lab Vision Corp., Fremont, CA, USA) and antigenic recovery techniques with a retrieval solution were employed for 20 minutes. Histological sections were incubated overnight in a humid chamber with primary antibodies and were incubated during the steps of blocking endogenous peroxidase, blocking serum (Ultra Vision Block, Lab Vision Corp., Fremont, CA, USA) and streptavidin peroxidase for 30 minutes. The primary antibodies and their dilutions included anti-VEGF (1:400), anti-Flk1 (1:700), anti-angiopoietin 2 (1:30), anti-Tie-2 (1:100), anti-CDC47 (1:100), and anti-TR α (1:400). Incubation with the secondary antibody (goat biotin, Lab Vision Corp., Fremont, CA, USA) was performed for 45 minutes. The chromogen utilised was diaminobenzidine (DAB substrate system, Lab Vision Corp., Fremont, CA, USA). Sections were counterstained with Harris hematoxylin. The antibodies used were raised in rabbits. To check cross-reaction with the fish tissue, known positive controls were included at the time of reaction. A negative control was obtained by replacing the primary antibodies with IgG. Immunohistochemistry analysis was performed descriptively with respect to the classification of the stage of follicular development and the location of immunoblots.

Apoptotic cells were evaluated by the TUNEL assay using an apoptosis detection kit (TdT-FragEL™ DNA Fragmentation Detection Kit, Calbiochem. San Diego, CA, USA). Antigenic recovery was performed with Proteinase K for 20 minutes at room temperature. The slides were incubated in a humidified chamber at 37°C with TdT for 1 hour and 30 minutes at room temperature to blocking endogenous peroxidase and streptavidin. The slides were incubated for 15 minutes with chromogen DAB. The sections were counterstained with methyl green. The negative control was obtained by replacing TdT with TBS. As a positive control, we employed ovaries with atretic follicles.

Total mRNA was extracted from all experimental groups by adding Trizol reagent (Gibco) according to the manufacturer's

instructions. One microgram of RNA was subjected to cDNA synthesis by using a SuperScript III Platinum Two-Step qPCR kit with SYBR Green (Invitrogen). The qRT-PCR reactions were conducted in a Smart Cycler II thermocycler (Cepheid Inc.). The one-step qRT-PCR amplification started with reverse transcription for 120 sec at 50 °C, followed by PCR with the following parameters: 45 cycles of 15 sec at 95 °C and 30 sec at 60 °C. At the end of each run, the fluorescence data were analysed to obtain the CT values. Gene expression was calculated using the $2^{-\Delta\Delta Ct}$ method, where the values from the samples were averaged and calibrated in relation to β -actin expression. The primers for the tilapia genes were as follows: sense 5'-GCTCAGGGCTCACAGTGGAA-3', antisense 5'-AACGACACGGGTGATGGC-3' for TR α ; sense 5'-GGCAACCACTGGAAGCAGAA-3', antisense 5'-TGATAATTTTTGTAAACTGACTGAAGCT-3' for TR β ; and sense 5'-CAATGAGAGTTCCGTTGC-3', antisense 5'-AGGATTCCATACCAAGGAAGG-3' for β actin. The relative quantification of gene transcripts for TR α and TR β in the 150g and 350g groups was calculated in relation to the 50g group of fish.

The relative expression of the gene transcripts for TR α and TR β were compared using the SNK test after logarithmic transformation of the data. Differences were considered significant if $p < 0.05$.

RESULTS

In the morphological analysis, the oocytes were classified as early and late primary growth, early secondary growth and full-grown follicles, postovulatory follicle and atretic follicles (Fig.1).

The 50g tilapia exhibited ovaries with a predominance of early and late primary growth follicles. However, in 150g tilapia, the oocytes were observed in various stages of maturation, with a predominance of early secondary growth and full-grown follicles. The ovaries of 350g tilapia exhibited a predominance of full-grown follicles, postovulatory follicle and atretic follicles. Immunohistochemistry revealed that the nuclear expression of CDC47 increased with the stage of maturation of the oocyte and was observed in the layer of follicle cells (Fig.2).

Expression of VEGF and its receptor Flk-1 was also observed in the follicular cells, and the expression of both VEGF and Flk-1 increased with the maturity of the oocyte; expression was more intense in the full-grown follicles, where expression was both nuclear and cytoplasmic (Fig.3A and B). The expression of angiopoietin was discrete and was observed in some cells of the theca layer of the early secondary growth and full-grown follicles (Fig.3C). The expression of its receptor, Tie 2, was moderate and was observed in follicular cells and theca cells of early secondary growth and full-grown follicles (Fig.3D).

Positive TR α immunostaining was observed both in the follicular cells and in the theca cells, and its expression was independent of follicular development; early and late primary growth, early secondary growth and full-grown follicles exhibited positive staining throughout the follicular cell (Fig.4A, B and C). Using the TUNEL technique, apoptotic bodies were observed in the follicular cells of atretic follicles and postovulatory follicles in the ovaries of 150g and 350g tilapia (Fig.4D).

The expression of TR α and TR β transcripts in the ovaries from 150g and 350g tilapia were compared to the 50g tilapia. There was no difference between the groups in the

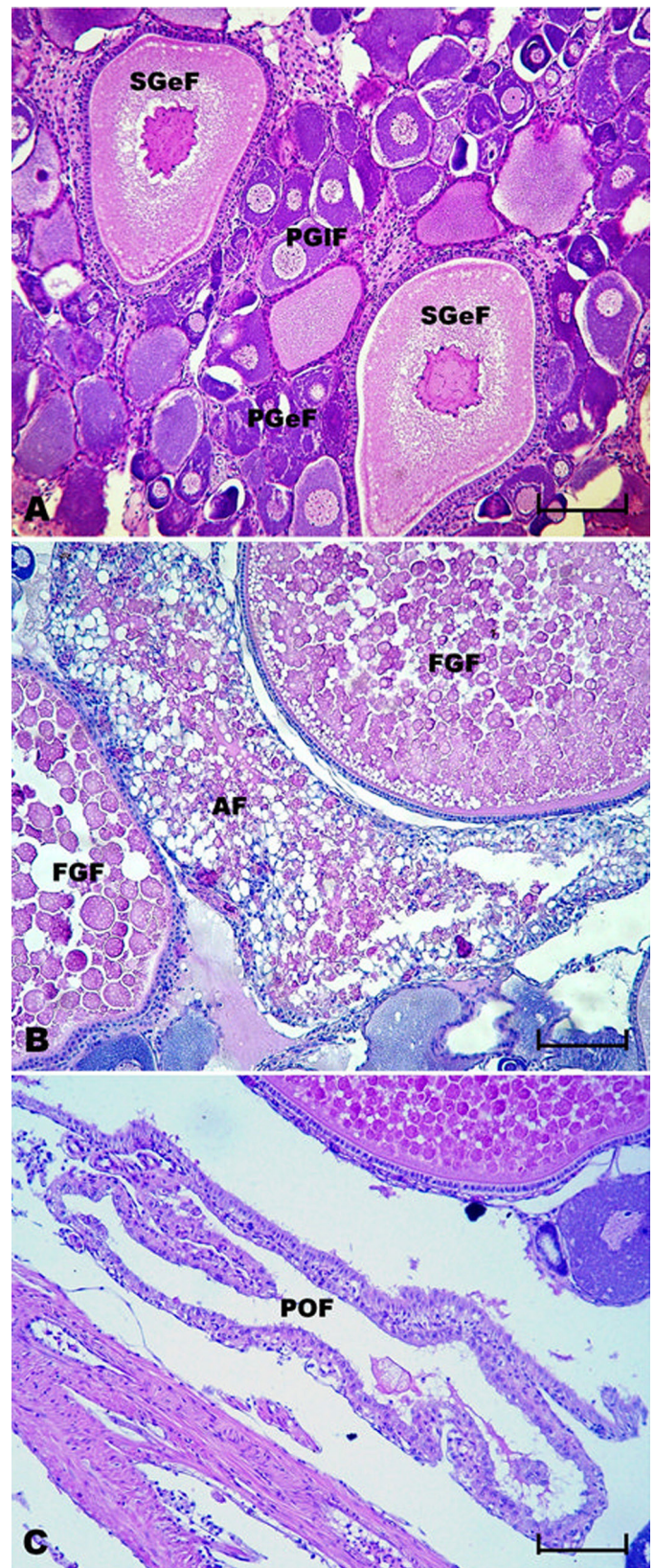


Fig.1. Morphological classification of the different stages of follicular maturation of tilapia (*Oreochromis niloticus*). (A) PGeF: early primary growth follicle; PGIF: late primary growth follicle; SGeF: early secondary growth follicle. (B) Full-grown follicles (FGF); atretic follicle (AF). (C) Postovulatory follicle (POF). HE, (A) Scale bar = 48 μ m. (B and C) Scale bar = 64 μ m.

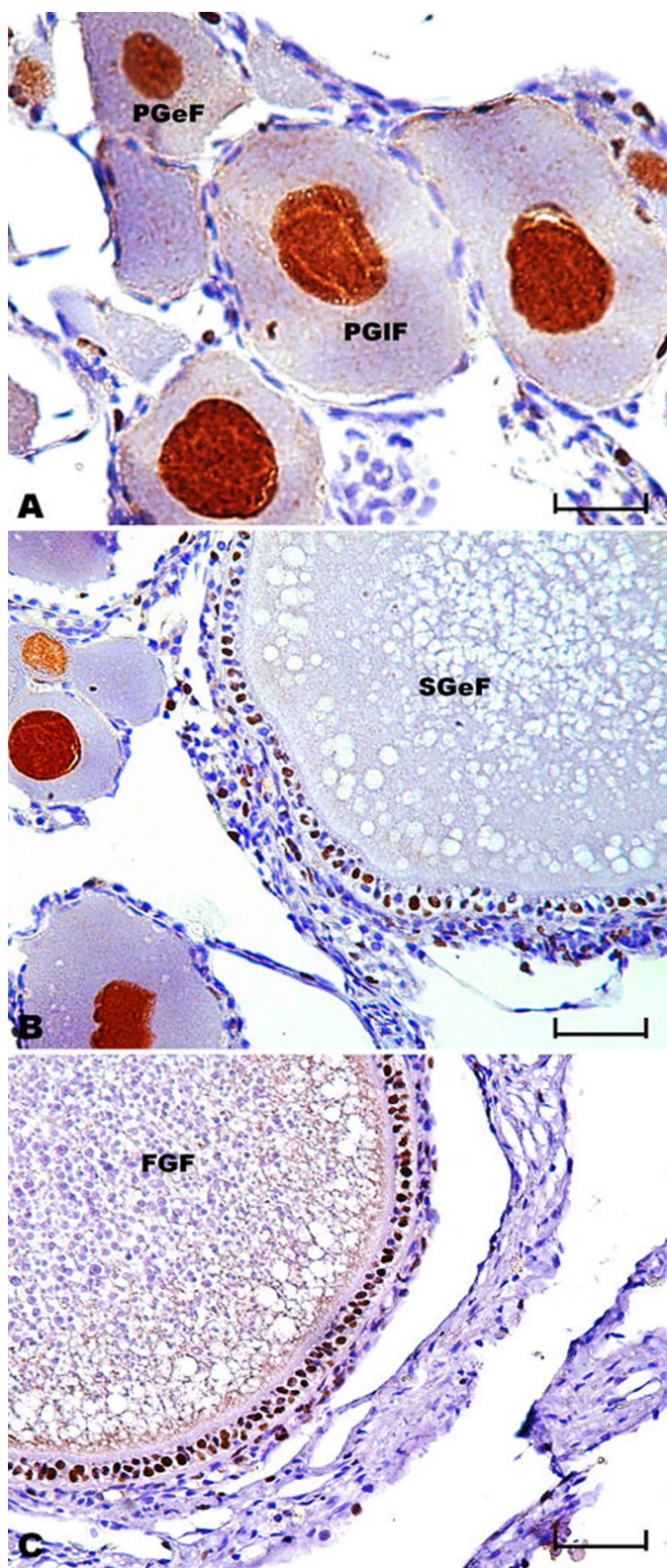


Fig.2. Immunohistochemical expression of CDC-47 in the oocytes of tilapia (*Oreochromis niloticus*) at different stages of follicular maturation. (A-C) Increased expression of CDC47 observed in the layer of follicle cells with advancing maturation of the oocyte: early and late primary growth (A), early secondary growth (B) and full-grown follicles (C). Streptavidin-biotin-peroxidase method, Harris' hematoxylin counterstain. (A) Scale bar = 48 μ m. (B and C) Scale bar = 64 μ m.

expression of TR α (Fig.4); however, the 350g tilapia exhibited higher expression of TR β transcripts compared with the smaller 50g tilapia (Fig.5).

DISCUSSION

The morphological and functional changes that occur during maturation in the ovary involve a number of complex cellular processes, including proliferation, differentiation, apoptosis and angiogenesis (Simpson et. al. 2001). Cell division control protein 47 (CDC47) has been used as a good marker for cell proliferation in mammalian tissues (Freitas et. al. 2007, Silva et. al. 2012). The expression of CDC47 in follicular cells increased with the maturity of the oocyte, which indicates that during follicular development, these cells are characterised by high proliferation rates.

The presence of apoptotic bodies was observed only in atretic follicles, which was likely due to the absence of survival factors in oocytes that induce the activation of the endogenous apoptosis pathways (Quirk et. al. 2004), leading to oocyte atresia. However, in this study, apoptotic bodies were also observed in theca cells and follicular cells from follicles after ovulation. In the mammalian ovary, apoptosis is mainly involved in the removal of oocytes during foetal life and in the removal of granulose cells of the growing follicles during adult life. However, in teleosts, apoptosis is important in the selection and recruitment of follicles for vitellogenesis and in ovarian regression after spawning (Santos et. al. 2008b).

Follicular proliferation and apoptosis are coordinated by a number of hormones, including thyroid hormones (Pam et. al. 2008, Nelson & Habibi 2009). Triiodothyronine (T3) and thyroxine (T4) are known to be essential for growth and development in all vertebrates, including fish (Nelson & Habibi 2006). In mammals and fish, thyroid hormones are essential for normal reproductive function (Power et al., 2001), acting directly on the ovary through specific receptors (TR α and TR β) (Mauro et. al. 1992, Nelson & Habibi 2006). In mammals, there is a vast literature on the effect of thyroid hormones on ovarian function, demonstrating that thyroid hormones stimulate folliculogenesis, inhibit follicular atresia and increase apoptosis in the corpus luteum (Serakides et. al. 2001, Silva et. al. 2004, 2013). However, the results of studies that evaluate the role of thyroid hormones in fish reproduction are variable. These conflicting results are most likely due to the existence of few studies and the variation in reproductive biology and metabolic events involving different species of fish.

Therefore, to clarify the interaction between thyroid hormones and fish reproduction, it is necessary to know in which cells of the oocyte the thyroid hormone receptors are expressed and whether the expression varies according to the gonadal developmental stage. No study has evaluated the expression of receptors for thyroid hormones in different stages of ovarian maturation and follicular development. Interesting, in the present study, the TR α immunostaining was observed to be independent of the stage of follicular development. However, the 350 g tilapia exhibited higher expression of TR β compared with the smaller 50g tilapia. As TR β is a functional receptor; increased expression would serve to increase the cellular response of

Fig.3. Immunohistochemical expression of VEGF, Flk-1, Angiopoetin-2 and Tie-2 in the full-grown follicles of tilapia (*Oreochromis niloticus*). (A) Nuclear and cytoplasmic expression of VEGF in follicular cells. (B) Nuclear and cytoplasmic expression of VEGF receptor (Flk-1) in follicular cells. (C) Expression of the Angiopoetin-2 theca layer. (D) Expression of the Ang-2 receptor (Tie-2) in follicular cells. Streptavidin-biotin-peroxidase method, Harris' hematoxylin counterstain. (A) Scale bar = 64 μ m. (B) Scale bar = 48 μ m. (C) Scale bar = 64 μ m. (D) Scale bar = 48 μ m.

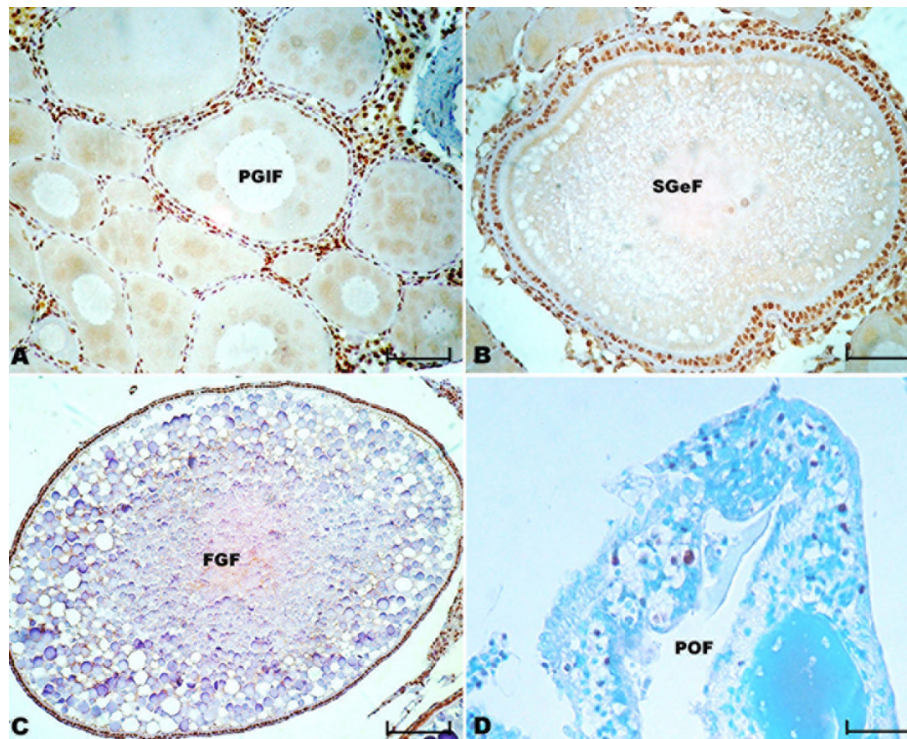
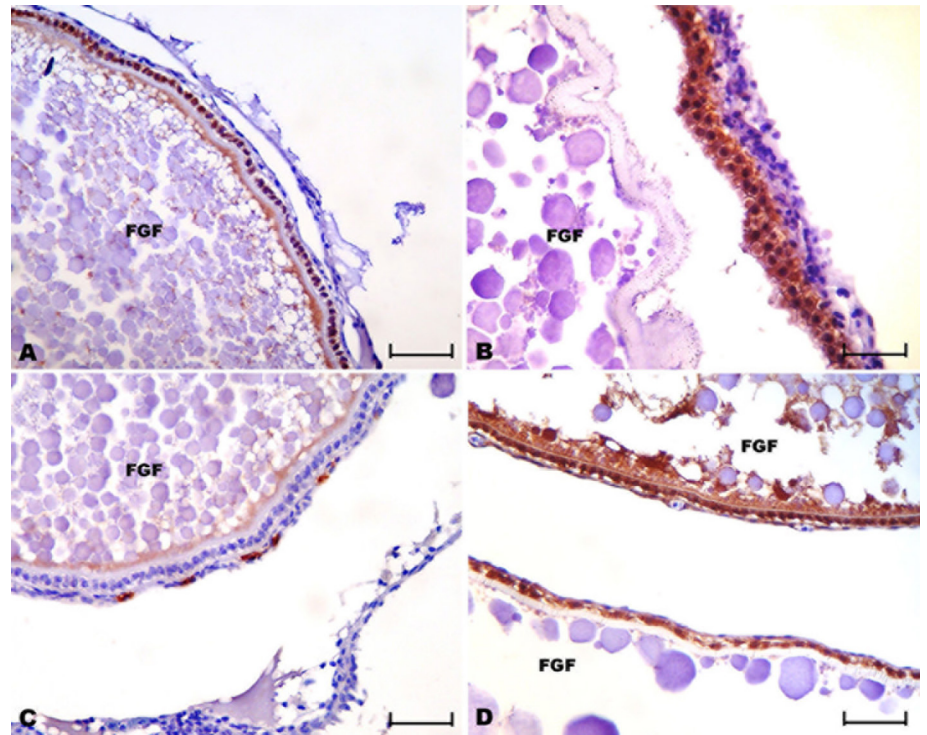


Fig.4. Immunohistochemical expression and TUNEL in the follicles of tilapia (*Oreochromis niloticus*) at different stages of follicular maturation. (A) Expression of nuclear TR α follicular cells and theca layer in the early and late primary growth, (B) early secondary growth, and (C) full-grown follicles. Streptavidin-biotin-peroxidase method, Harris' hematoxylin counterstain. (A) Scale bar= 80 μ m. (B) Scale bar= 64 μ m. (C) Scale bar= 144 μ m. (D) Apoptotic cells in histological sections of the postovulatory follicle. (TUNEL assay, methyl green; Scale bar=80 μ m)

the thyroid hormones.

The TR subtypes are differently regulated by T3 in the gonads, providing evidence for possible tissue-specific regulation (Habibi et. al. 2012). In goldfish, TR α and TR β are down-regulated by T3 in ovarian tissue (Nelson et. al. 2010), with modest differences in expression between reproductive stages (Nelson et. al. 2006). In Atlantic Salmon, treatment with T4 was shown reduce hepatic TR β expression (Mortensen et. al. 2006). In fish, one study demon-

strated the similarity between goldfish and mammals in the mechanisms of TR activation (Habibi et. al. 2012). However, the present study appears to be the first study demonstrating the TH receptor expression in ovaries of the tilapia. However, more studies are needed to study the plasma levels of thyroid hormones in tilapia at different reproductive phases and to correlate this profile with hormonal ovarian expression of the thyroid hormone receptors.

Angiogenesis consists of several activities of endothelial

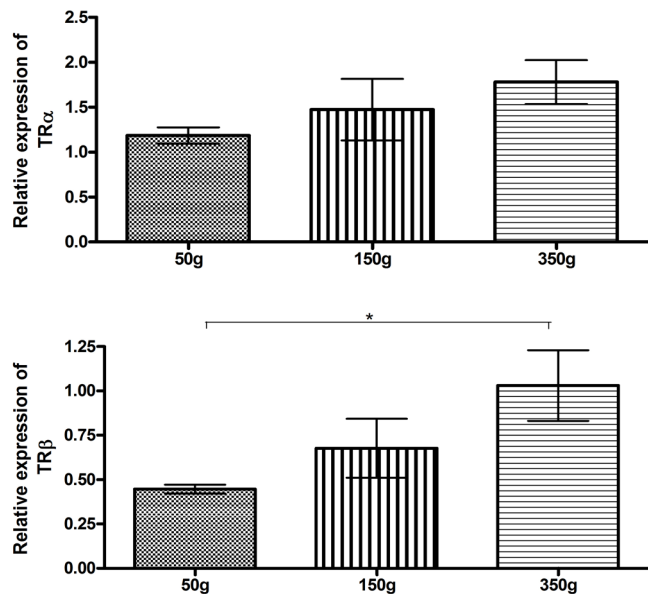


Fig.5. Relative quantification (mean \pm standard deviation) of gene transcripts for TR α and TR β by RT-real-time PCR in samples of tilapia ovaries: 50g, 150g and 350g. Data are expressed in relation to the 50g group. * $p < 0.05$.

cells, including as migration and apoptosis. VEGF and angiopoietin are the main angiogenic factors produced in the ovaries of mammals (Robinson et al. 2009), and these proteins exert their functions through receptor tyrosine kinases Flk-1 and Tie-2, respectively (Shibuya 2008). There are few reports regarding the physiological role of angiopoietin in fish. In zebrafish, angiopoietin-like proteins 1 and 2 function cooperatively and possess antiapoptotic activity (Kubota et al. 2005). In this study, the expression of angiopoietin and the expression of its receptor, Tie 2, were discrete. However, the expression of VEGF and its receptor was increased in mature oocytes. This result is most likely because VEGF-controlled angiogenesis is an important phenomenon in the extrusion process of oocytes and because VEGF increases vascular permeability, which could favour the viability of the yolk.

We conclude that the proliferative activity and the expression of VEGF and its receptor increase with follicular maturation in the ovaries of tilapia (*Oreochromis niloticus*) and that TR expression increases with ovarian maturity.

Acknowledgements.- This study was supported by grants from the Fundação de Amparo à Pesquisa de Minas Gerais (Fapemig), Conselho Nacional de Desenvolvimento Científico e Tecnológico (CNPq) and the Pró-Reitoria de Pesquisa (PRPq) of the *Universidade Federal de Minas Gerais*.

REFERENCES

Freitas E.S., Leite E.D., Souza C.A., Ocarino N.M., Ferreira E., Cassali G.D., Gomes M.G. & Serakides R. 2007. Histomorphometry and Expressions of Cdc47 and Caspase-3 in Hyperthyroid Rats Uteri and Placentas during Gestation and Postpartum Associated with Fetal Development. *Reprod. Fertil. Dev.* 19:498-509.

Habibi H.R., Nelson E.R. & Alan E.R.O. 2012. New insights into thyroid hormone function and modulation of reproduction in goldfish. *Gen. Comp. Endocrinol.* 175:19-26.

Kubota Y., Oike Y., Satoh S., Tabata Y., Niikura Y., Morisada T., Akao M., Urano T., Ito Y., Miyamoto T., Nagai N., Koh G.Y., Watanabe S. & Suda T. 2005. Co-

operative interaction of Angiopoietin-like proteins 1 and 2 in zebrafish vascular development. *Proc. Natl Acad. Sci. USA* 102:13502-13507.

Mauro T., Katayama K., Barnea E.R. & Mochizuki M. 1992. A role for thyroid hormone in the induction of ovulation and corpus luteum function. *Horm. Res.* 37:12-18.

Mortensen A.S. & Arukwe A. 2006. The persistent DDT metabolite, 1,1-dichloro-2,2-bis (p-chlorophenyl) ethylene, alters thyroid hormone-dependent genes, hepatic cytochrome P4503A, and pregnane X receptor gene expression in atlantic salmon (*Salmo salar*). *Environ. Toxicol. Chem.* 25:1607-1615.

Nelson E.R. & Habibi H.R. 2006. Molecular characterization and sex related seasonal expression of thyroid receptor subtypes in golg fish. *Mol. Cell. Endocrinol.* 253:83-95.

Nelson E.R. & Habibi H.R. 2009. Thyroid receptor subtypes: structure and function in fish. *Gen. Comp. Endocrinol.* 161:90-6.

Nelson E.R., Allan E.R., Pang F.Y. & Habibi H.R. 2010. Thyroid hormone and reproduction: regulation of estrogen receptors in goldfish gonads. *Mol. Reprod. Dev.* 77:784-794.

Pam K.X., Amano M., Kurita Y., Shimizu A., Fujinami Y., Amiya N. & Yamamoto K. 2008. Changes in the immunostaining intensities of follicle-stimulating hormone and luteinizing hormone during ovarian maturation in the female japonese flounder. *Fish Physiol. Biochem.* 34:357-365.

Power D.M., Llewellyn L., Faustino M., Nowell M.A., Björnsson B.T., Einarsdóttir I.E., Canario A.V. & Sweeney G.E. 2001. Thyroid hormones in growth and development of fish. *Comp. Biochem. Physiol. C, Toxicol. Pharmacol.* 130:447-459.

Quirk S.M., Cowan R.G., Harman R.M., Hu C.L. & Porter D.A. 2004. Ovarian follicular growth and atresia: the relationship between cell proliferation and survival. *J. Anim. Sci.* 82:E40-52.

Robinson R.S., Woad K.J., Hammond A.J., Laird M., Hunter M.G. & Mann G.E. 2009. Angiogenesis and vascular function in the ovary. *Reproduction* 138:869-881.

Santos H.B., Sato Y., Moro L., Bazzoli N. & Rizzo E. 2008a. Relationship among follicular apoptosis, integrin $\beta 1$ and collagen type IV during early ovarian regression in teleost *Prochilodus argenteus* after induced spawning. *Cell. Tissue Res.* 332:159-170.

Santos J.E., Padilha G.E.V., Bomcompagni-Junior O., Santos G.B., Rizzo E. & Bazzoli N. 2008b. Ovarian follicle atresia is mediated by heterophagy, autophagy, and apoptosis in *Prochilodus argenteus* and *Lepomis taeniatus* (Teleostei: Characiformes). *Theriogenology* 70:1449-1460.

Serakides R., Nunes V.A., Nascimento E.F., Ribeiro A.F.C. & Silva C.M. 2001. Foliculogênese e esteroidogênese ovarianas em ratas adultas hipertireóideas. *Arq. Bras. Endocrinol. Metab.* 45:258-264.

Shibuya M. 2008. Vascular endothelial growth factor-dependent and -independent regulation of angiogenesis. *BMB Reports* 41:278-286.

Silva C.M., Serakides R., Oliveira T.S., Ocarino N.M., Nascimento E.F. & Nunes V.A. 2004. Histomorfometria e histoquímica dos ovários, tubas e útero de ratas hipotireóideas em metaestro-diestro. *Arq. Bras. Med. Vet. Zootec.* 56:628-639.

Silva J.F., Vidigal P.N., Galvão D.D., Boeloni J.N., Nunes P.P., Ocarino N.M., Nascimento E.F. & Serakides R. 2012. Fetal growth restriction in hypothyroidism is associated with changes in proliferative activity, apoptosis and vascularisation of the placenta. *Reprod. Fertil. Dev.* 24:923-931.

Silva J.F., Ocarino N.M., Vieira A.L.S. & Serakides R. 2013. Effects of hypothyroidism on proliferation, angiogenesis, apoptosis and expression of COX-2 in the corpus luteum of female rats. *Reprod. Domest. Anim.* 48:691-698.

Simpson K.S., Byers M.J. & Curry Jr T.E. 2001. Spatiotemporal messenger ribonucleic acid expression of ovarian tissue inhibitors of metalloproteinases throughout the rat estrous cycle. *Endocrinology.* 142:2058-2069.

Tyler C.R. & Sumpter J.P. 1996. Oocyte growth and development in teleost. *Rev. Fish Biol. Fisher.* 6:287-318.