



## Retrospective study of radiographic changes in athletic bulls with orthopedic disorders<sup>1</sup>

Bruno F. Cholfe<sup>2</sup>, José R.B. Silva<sup>3</sup>, Alfredo M. Filho<sup>2</sup>, Caroline G. Souza<sup>2</sup>, Antônio M.T. Filho<sup>2</sup>, Sílvia H.V. Perri<sup>4</sup>, Luiz C. Vulcano<sup>3</sup> and Celso A. Rodrigues<sup>3\*</sup> 

**ABSTRACT.**- Cholfe F.B., Silva J.R.B., Filho A.M., Souza C.G., Filho A.M.T., Perri S.H.V., Vulcano L.C. & Rodrigues C.A. 2019. **Retrospective study of radiographic changes in athletic bulls with orthopedic disorders.** *Pesquisa Veterinária Brasileira* 39(11):858-862. Faculdade de Medicina Veterinária e Zootecnia, Universidade Estadual Paulista "Júlio de Mesquita Filho", Rua Prof. Dr. Walter Maurício Correa s/n, Cx. Postal 560, Distrito de Rubião Júnior, Botucatu, SP 18 618-682, Brazil. E-mail: [celso.a.rodrigues@unesp.br](mailto:celso.a.rodrigues@unesp.br)

The objectives of this study were to demonstrate the lesions that affect athlete bulls and to correlate the disorders with weight, age, affected limb and region of the limb. The present study was accomplished using radiographic images of athletic rodeo bulls collected from the medical and surgical records of the large animal service at the veterinary hospital. Radiographic images were evaluated for 136 bulls that were taken care of at the Veterinary Hospital, ranging in age from 4 to 13 years, with an average weight of 800kg and proven prior physical activity through participation in rodeos. The chi-square or Fisher's exact test was used to assess the association between the studied variables. It was observed that 71.6% of the bulls studied and suffering from lameness had radiographic lesions, predominantly in experienced animals. Enthesopathy in starter and experienced bulls, septic arthritis in starter bulls, and fractures and degenerative joint disease in experienced bulls were the most frequent radiographic lesions diagnosed. The region of limb where the majority of radiographic changes occurred was the digits. Risk factors and occurrence of diseases of the locomotor system in athletic bulls are similar to those in sport equines.

INDEX TERMS: Retrospective study, radiographic changes, athletic bulls, orthopedic disorders, bovine, osteoarthritis, bull, X-ray, joint diseases.

**RESUMO.**- [Estudo retrospectivo das alterações radiográficas de touros atletas com doenças ortopédicas.] O objetivo desse trabalho foi demonstrar quais lesões acometem touros atletas, correlacionando as desordens com peso, idade, membro e região afetada. O presente estudo foi realizado utilizando radiografias de touros atletas de rodeio, após levantamento dos prontuários clínicos e cirúrgicos do serviço

de grandes animais de um hospital veterinário. Foram avaliadas radiografias de 136 touros que haviam sido atendidos em tal hospital, com idade variando de quatro a 13 anos, com média de peso de 800kg e realizavam participação em rodeios. Para avaliar a associação entre as variáveis estudadas foi utilizado o teste exato de Fischer e o Qui-quadrado. Observou-se que 71,6% dos touros estudados que claudicavam, apresentavam lesões radiográficas, predominantemente em animais mais experientes. A entesopatia em todos os animais, artrite séptica nos touros iniciantes, fraturas e doença articular degenerativa nos touros mais experientes, foram as alterações radiográficas mais frequentes. As regiões com maior ocorrência de lesões radiográficas foram os dígitos. Os fatores de risco para ocorrência de doenças no sistema locomotor de touros atletas são diversos, similares aos que ocorrem nos equinos atletas.

TERMOS DE INDEXAÇÃO: Estudo retrospectivo, alterações radiográficas, touros atletas, doenças ortopédicas, bovinos, osteoartrite, touro, raio-x, doenças articulares.

<sup>1</sup> Received on May 24, 2019.

Accepted for publication on July 10, 2019.

<sup>2</sup> Departamento de Cirurgia de Grandes animais, Centro Universitário de Rio Preto (Unirp), Rodovia BR-153 Km 69, São José do Rio Preto, SP 15093-450, Brazil.

<sup>3</sup> Faculdade de Medicina Veterinária e Zootecnia (FMVZ), Universidade Estadual Paulista "Júlio de Mesquita Filho" (Unesp), Rua Prof. Dr. Walter Maurício Correa s/n, Cx. Postal 560, Distrito de Rubião Júnior, Botucatu, SP 18618-682, Brazil. \*Corresponding author: [celso.a.rodrigues@unesp.br](mailto:celso.a.rodrigues@unesp.br)

<sup>4</sup> Departamento de Apoio, Produção e Saúde Animal, Faculdade de Medicina Veterinária, Universidade Estadual Paulista "Júlio de Mesquita Filho" (Unesp), Campus de Araçatuba, Rua Clóvis Pestana 793, Dona Amélia, Araçatuba, SP 16050-680, Brazil.

## INTRODUCTION

The appropriate diagnosis and monitoring of joint lesions should make use of diagnostic aid techniques, in addition to specific clinical examination of the locomotor system. Among these, the radiographic, sonographic, cytological and histopathological techniques can be highlighted (Stanek 1997, Parisi & Shakeri 2007, Ulian 2010). Radiographic and ultrasonographic examination remains the main tools for diagnosis of large animal locomotor system lesions (Parisi & Shakeri 2007, Kofler et al. 2014, Nichols & Lardè 2014).

Considering the importance of radiographic evaluation in cattle, Barnabé (2005) performed a radiographic study of lame cattle, finding foot illnesses according to the following prevalence: degenerative joint disease (28.72%), osteitis (24.22%), periostitis (11.42%), septic arthritis (7.96%) and osteomyelitis (7.26%). The main diseases in cattle in the “free stall” system were digital papillomatous dermatitis, flat sole and heel erosion, while cows in the “tie-stall” system presented sole bleeding, white line disease, heel erosion, double sole, interdigital dermatitis, vertical crack in corneum case, and overgrow toe/weak heels with a greater frequency (Silveira 2009). Borges et al. (2006), while evaluating 70 bovine forelimbs with foot illnesses, found 58% of limbs had osteitis; 32%, aseptic physitis; and 31%, periostitis.

Among the radiographic findings in cattle suffering from septic arthritis, osteolysis at the point of insertion of the deep flexor tendon and osteoperiostitis stand out, with a greater distancing between the articular surfaces of the middle and distal phalanges. In addition to these, irregularities in the articular bone surface are also frequent, with subchondral bone proliferation, periarticular osteophytes and enthesophytes, in the case of the distal portion of the limbs (Pharr & Bargai 1997).

Radiographic findings in degenerative joint disease are characterized by subchondral bone sclerosis, subchondral bone cysts, osteophyte formation, subluxation, articular and intra-articular space narrowing, and periarticular calcification (Bargai et al. 1989, Motta et al. 2017). Periosteal response in cattle is rapid and extensive (Fergusson 1997, Barnabé 2005). This reaction is the result of the spread of septic or traumatic injury to the periosteum. Soft tissue calcification occurs in a few weeks, and periosteal new bone formation results in increased bone diameter, with may lead to animal lameness in acute and chronic (Bargai et al. 1989).

Radiographic examination is an important and efficient tool to assess the changes caused by chronic enthesopathy. Among the many forms of presentation, the changes represented by bone erosions, soft tissue calcification, periosteal neoformation and changes in bone contour stand out (Stanek 1997). The high level of periosteum reactivity in the bovine is an aspect that influences the emergence of radiographic signs of many diseases commonly secondary to trauma and infections. This occurs by stimulating periosteal neoformation in young animals by increasing the radiopacity of the bone. However, these radiographic changes in older animals may be an incidental finding in an animal that has no lameness (Pharr & Bargai 1997). Digits fractures may be traumatic or pathological, open or closed. The pathological usually occur because of extensive bone destruction or in cases of chronic laminitis (Kofler et al. 2014).

Consequently, the objectives of this study were to conduct a retrospective study of radiographic findings of rodeo bulls suffering from lameness and treated at the Veterinary Hospital in order to characterize and quantify the major orthopedic injuries. In addition, the aim is to build a database for research in veterinary medicine for athletic cattle and to correlate the main types of radiographic lesions according to animal weight and age, location in relation to the limb and the region of the affected limb.

## MATERIALS AND METHODS

This study was performed using the radiographic findings of 136 athlete bulls suffering from lameness and treated at the Veterinary Hospital “Dr. Halim Atique”, of the “Centro Universitário de Rio Preto” (Unirp), located in São José do Rio Preto/SP, from 2005 to 2011.

Initially, the study was conducted as a survey of the records of all athlete bulls treated at the Veterinary Hospital from 2005 to 2011. Later, the study was narrowed to a screening of the records in which the animals were subjected to radiographic examination and had historical and clinical evidence of lameness. The screened records were from 136 athlete bulls from different breeds and owners, ranging in age from 4-13 years, with an average weight of 800kg and proven prior physical activity through participation in rodeos.

After review of the animals’ medical records, a case selection was made and the radiographic images were gathered from the collection of the Veterinary Hospital. All analogic radiographs were obtained from the equipment Emik® R 2000. Medical history was taken and physical examination conducted following hospital protocols. Animals were restrained in a chute with a mobile wall (Beckhauser®) and the radiographic examination was performed.

The radiographic diagnosis criteria used considered the normal anatomical relationship, changes caused by disease in the bone surfaces, joints, insertions of ligaments, tendons and joint capsule, following the method described by Bargai et al. (1989) and Steiner et al. (2010).

Radiographic examinations were performed with portable radiographic equipment and radiographic films of dimensions 18cm x 24cm. The projections used were dorsoplantar or palmar and lateromedial, in order to observe the condition of the distal interphalangeal joints, and proximal to observe the metacarpal/metatarsal phalangeal joint. The radiographic technique used for this region was 55kV exposure and duration of 0.5 seconds. In the joint region of the carpus and tarsus articulation, dorsoplantar or palmar and lateromedial projections were used, with radiographic technique of 65-75kV with a duration of 0.5 seconds. For the humeral-radioulnar and femorotibial-patellar joint a lateromedial projection was used, with the radiographic technique of 75-85kV and duration of 6 to 8 seconds.

For statistical analysis the Chi-square or Fisher’s exact test was used to assess the association between the studied variables. Values were considered significant when  $p < 0.05$ . The statistical analysis was performed using the computer program SAS® (Statistical Analysis System).

## RESULTS

The physical containment of animals at the mobile wall stock allowed maintaining them in a standing position, without the need for sedation and proved to be suitable for carrying out radiographic examinations. This restraint provided a rapid

and efficient method of handling the bulls, providing safety to both the animal and the veterinarian.

The projections and radiographic techniques proved effective, allowing the best technical analysis because of the good quality of images.

When the variables of age and type of lesion were compared, a correlation was observed. Experienced animals were most affected by injuries, and the most common were, septic arthritis (Fig.1), osteoperiostitis (Fig.2), enthesopathy (Fig.3), degenerative joint disease and fracture. The beginner bulls were less affected by lesions, with the most common being enthesopathy, septic arthritis, fractures and osteoperiostitis (Table 1).

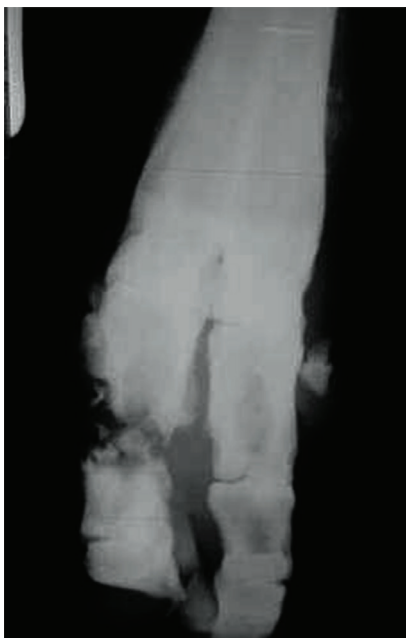

Fig.1. Dorso-plantar radiography evidenced septic arthritis in the proximal interphalangeal joint in the medial foot of right forelimb.

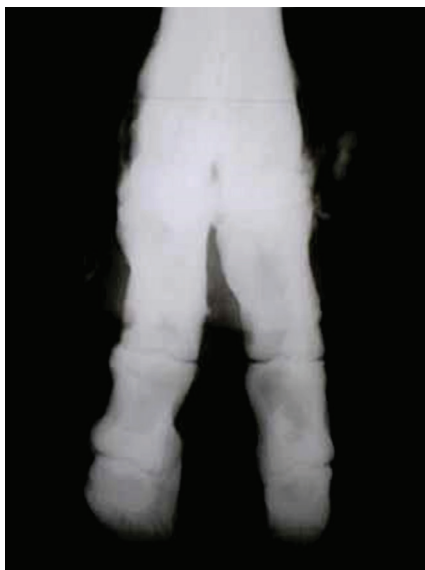

Fig.2. Plantar-dorsal radiography evidenced osteoperiostitis in the 3rd and 4th metatarsi of the left forelimb.

In the analysis of data on the relationship between the affected limb and weight, where we evaluated the categories of age and affected limb, there was a great disparity among the beginner animals in the percentage of animals injured in the forelimb (13.3%) and in the hindlimb (25.8%). In experienced and heavier bulls, the percentage of injuries corresponded to 27.7% in the forelimbs and 32.5% in the hindlimbs.

It was observed that when considering the variables of lesion and area of the affected limb, the most common type of injury in the proximal and distal interphalangeal joint was enthesopathy. While in the metacarpal/ metatarsal phalangeal and carpal joints, osteoperiostitis was the most frequent. In the tarsal joint the most frequent lesions were fractures, which are also more frequent in the humeral-radioulnar joint. Degenerative joint disease was most observed in the femorotibial-patellar joint, while a single case of osteoperiostitis was observed in the 3rd metatarsal joint (Table 2).

## DISCUSSION

There are some reports in the literature of retrospective radiographic studies in cattle, especially in dairy and confined animals (Barnabé 2005, Lima et al. 2009) and in bulls (Motta et al. 2017). However, none of these studies evaluated lesions solely related to athlete bulls. Barnabé (2005), in his radiological study with dairy cattle with lameness, found the following prevalence of foot illnesses: degenerative joint disease (28.72%), osteitis (24.22%), periostitis (11.42%), septic arthritis (7.96%) and osteomyelitis (7.26%). In evaluating the limbs from confined animals for slaughter, there were abnormalities in 51 (25.5%) distal limbs evaluated (Lima et al. 2009). Remembering that dairy cattle were exposed to risk factors like as agglomeration, moisture and high ambient contamination. In the athlete bulls of the current study radiographic changes were noted in 71.5% of animals with historical and clinical evidence of lameness.

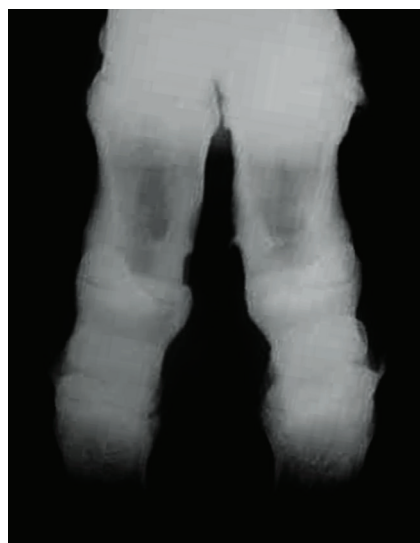


Fig.3. Plantar-dorsal radiography evidenced enthesophytes in the fetlock and distal interphalangeal joint of the medial and lateral foot, and in insertion of proximal interdigital cruciate ligament of medial foot.

**Table 1. Distribution frequency of lesions related of age**

Age		Lesion										Total
		NL	Osteoperiostitis	Enthesophytosis	Septic arthritis	DJD	Fracture	F.B.	C.L.	Ostei./Osteo.	Osteoarthritis	
B	n	19	9	10	10	1	8	-	1	2	-	60
	%	12.6	6.0	6.6	6.6	0.7	5.3	-	0.7	1.3	-	40.3
E	n	24	11	25	5	8	16	1	-	-	1	91
	%	15.9	7.3	16.6	3.3	5.3	10.6	0.7	-	-	0.7	59.7

B = beginners, E = experienced, NL = no lesion, DJD = degenerative joint disease, F.B. = foreign body, C.L. = cysts lesions, Ostei./Osteo. = osteitis/osteomyelitis. Fisher's exact test (P = 0.0407).

**Table 2. Distribution frequency of radiographic images related to affected limb region**

		Affected limb region								Total
		Claw	Fetlock	Carpus joints	Tarsus	Knee	Elbow	3rd metatarsus		
No lesion	n	31	2	-	6	4	-	-	43	
	%	20.5	1.3	-	4.0	2.6	-	-	27.4	
Osteoperiostitis	n	5	8	5	1	-	-	1	19	
	%	3.3	5.3	3.3	0.7	-	-	0.7	13.3	
Enthesophytosis	n	34	1	-	-	-	-	-	35	
	%	22.5	0.7	-	-	-	-	-	23.2	
Septic arthritis	n	12	2	-	1	-	-	-	15	
	%	7.9	1.3	-	0.7	-	-	-	9.9	
DJD	n	1	4	-	1	3	-	-	9	
	%	0.7	2.6	-	0.7	2.0	-	-	6.0	
Fracture	n	13	2	2	5	-	2	-	24	
	%	8.6	1.3	1.3	3.3	-	1.3	-	14.8	
Foreign body	n	-	1	-	-	-	-	-	1	
	%	-	0.7	-	-	-	-	-	0.7	
Cysts lesion	n	-	1	-	-	-	-	-	1	
	%	-	0.7	-	-	-	-	-	0.7	
Osteitis/Osteomyelitis	n	1	1	-	-	-	-	-	2	
	%	0.7	0.7	-	-	-	-	-	1.4	
Osteoarthritis	n	-	-	-	-	1	-	-	1	
	%	-	-	-	-	0.7	-	-	0.7	

DJD = degenerative joint disease. Chi-square test (P < 0.0001).

The frequency of the lesions observed by Lima et al. (2009) were: degenerative joint disease (27.5%), osteitis (19.6%), periostitis (15.7%), septic arthritis of the distal interphalangeal joint (11.8%), deep flexor tendon calcification (7.8%), extensor tendon calcification (5.9%), splinter fracture, arthritis, spondylitis and calcification of the proximal ligament (3.9%). Borges et al. (2006), evaluating 70 animals with foot illnesses, found 58% of limbs had osteitis; 32%, aseptic phytitis; and 31%, periostitis. In this study, it is noteworthy that among the athlete bulls, the experienced animals were the most affected by injuries (with 60.2% affected), among which the most common were enthesopathy (16.6%), fractures (10.6%), osteoperiostitis (7.3%), degenerative joint disease (5.3%) and septic arthritis (3.3%). Beginner animals were least affected by injuries (with 39.2% affected); noteworthy injuries were enthesopathy (6.6%), septic arthritis (6.6%), periostitis (6.0%) and fractures (5.3%). These results are the same as in breeding bulls, where a positive correlation between age and degenerative joint disease was observed (Motta et al. 2017).

The lesions most often found in dairy and beef cattle under confinement system are traditionally associated with environmental risk factors. These factors subject the claw to trauma or humid conditions and anaerobic bacteria (Silveira et al. 2009). However, athlete bulls do high intensity physical activity for a short period of time (8 seconds). Thus, some of the factors differ from those previously described (Nicoletti 2004). Thus, the types of lesions, and their respective locations, better resemble those of performance horses (Ross 2003). Other aspects that explain the high frequency of lesions in the evaluated animals are: trauma related to transportation and rodeo, loading and unloading, fights and nutritional imbalance. To these are added risk factors commonly described for cattle (Ytrehus et al. 2007, Motta et al. 2017).

Possibly the high frequency of enthesophytosis and osteoperiostitis in young animals is due to the high periosteal reactivity associated with trauma and infections (Pharr & Bargai 1997, Nichols & Lardé 2014), which associates to the bovine's increased capacity of periosteal reaction. The radiographic characterization of observed enthesophytosis



and osteophytosis were consistent with those described by other studies (Bargai et al. 1989, Steiner et al. 2010), which report the presence of bone erosions, soft tissue calcification, periosteal neoformation and changes in bone contour. The high prevalence in young animals can still be explained by the greater susceptibility of this age group to detachment micro fractures at the insertion point of tendons and ligaments, predisposing the formation of enthesophytes. The stress on the ligaments, tendons and joint capsule is a major cause of the formation of enthesophytes in horses (Dyson 2003). However, one should carefully evaluate the clinical relevance of this finding, as it might not be the primary cause of lameness. Thus, the presence of enthesophytes and osteophytes in radiographic images of experienced animals can be an incidental finding in animals that do not have lameness, but it reflects the biomechanical stress that these structures had been suffering (Kofler et al. 2014). This consideration was also highlighted by Barnabé (2005), who did not correlate the enthesopathy with lameness in cattle.

In several studies of bovine animal production hindlimbs are most affected by lesions (Fergusson 1997, Nicoletti 2004, Barnabé 2005). The main explanation for this higher incidence of disease in the hindlimb would be due to weight distribution, where the pelvic limbs are responsible for supporting the major portion of the weight (Kofler et al. 2014). This distribution was confirmed in the beginner bulls of this study, which represented 67% of the animals. In this category, there was a wide disparity between the percentage of injuries in the forelimb (13.3%) and hindlimb (25.8%). In experienced and heavier bulls, the percentage of injuries corresponded to 27.7% in the forelimb and 32.5% in the hindlimb.

Another hypothesis for the balance between the percentage of lesions observed between hind- and forelimbs would be a change in weight distribution (Ross 2003). The adult animals, due to athletic activity, visually have higher muscular development in the forelimbs, changing forelimb weight bearing and directly increasing the number of injuries.

Ross (2003) reports that the weight distribution in horses is 60% on the forelimbs and 40 on hindlimbs, so lesions in the forelimbs are more frequent. In horses the rider's weight factor, also has a decisive role' in the occurrence of injuries. However, this factor probably exerts little influence on the incidence of injuries in athlete bulls because the competitor remains briefly mounted on the bull. However, it is observed that only the mainstream rodeo bulls are kept in athletic activity for long periods of time. The presence of extremely muscular forelimbs in athlete bulls and the act of jumping and landing on these limbs result in the distribution and types of injuries that most resemble equine athletes.

## CONCLUSIONS

It was observed that 71.6% of the studied bulls suffering from lameness had radiographic lesion, these being predominant in experient animals. Enthesopathy in young and adult bulls, septic arthritis in young, fractures and degenerative joint disease in adults, were the most frequent radiographic lesions diagnosed. Radiographic lesions found in athlete bulls differ in part from other types of cattle production.

The occurrence of most locomotor system disorders in the rodeo bulls studied were related to intensity of exercise and athletic life.

**Conflict of interest statement.**- The authors have no conflict of interest.

## REFERENCES

- Bargai U., Pharr J.W. & Morgan J.P. 1989. *Bovine Radiology*. Iowa State University, Ames, 198p.
- Barnabé P.A. 2005. Alterações radiográficas nos dedos de bovinos claudicantes. Doctoral Dissertation in Veterinary Surgery, Faculdade de Ciências Agrárias e Veterinárias, Universidade Estadual Paulista, Jaboticabal. 180p.
- Borges N.C., Silva L.A.F., Fioravanti M.C.S., Lima I.R., Costa A.C., Costa A.P.A., Borges J.R.J. & Canola J.C. 2006. A post-mortem radiographic study of the digits of bovine raised in natural grazing environment. Proceedings of XIV International Symposium and VI Conference on Lameness in Ruminants, Montevideo, Uruguai, p.43-44.
- Dyson S.J. 2003. Radiography and radiology, p.154-165. In: Dyson S.J. & Ross M.W. (Eds), *Diagnosis and Management of Lameness in the Horse*. 2nd ed. W.B. Saunders, Philadelphia.
- Fergusson J.G. 1997. Principles of bovine orthopedics, p.35-247. In: Greenough P.R. & Weaver A.D. (Eds), *Lameness in Cattle*. W.B. Saunders, Philadelphia.
- Kofler J., Geissbühler U. & Steiner A. 2014. Diagnostic imaging in bovine orthopedics. *Vet. Clin. N. Am., Food Anim. Pract.* 30(1):11-53, v. <PMid:24534658>
- Lima I.R., Fonseca A.M., Silva L.H., Coelho C.M.M., Canola J.C. & Borges N.C. 2009. Displasia fiseal em bovinos manejados em sistema intensivo. *Anais VIII Congresso Brasileiro de Buiatria, Goiânia, GO*, p.417-422.
- Motta G.A., Girardi A.M., Sabes A.F., Portugal E.S., Nociti R.P., Bueno G.M. & Marques L.C. 2017. Clinical and radiographic changes of carpi, tarsi and interphalangeal joints of beef zebu bulls on semen collection regimen. *Arq. Bras. Med. Vet. Zootec.* 69(6):1357-1366. <<http://dx.doi.org/10.1590/1678-4162-9474>>
- Nichols S. & Lardè H. 2014. Noninfectious joint disease in cattle. *Vet. Clin. N. Am., Food Anim. Pract.* 30(1):205-223. <PMid:24534666>
- Nicoletti J.L.M. 2004. *Manual de Podologia Bovina*. Manole, Barueri, 126p.
- Parisi A.M. & Shakeri M.A. 2007. Abattoir study of radiographic changes of bones and joints of digital region in cattle with abnormal claws. *Veterinarski Arhiv.* 77:187-194.
- Pharr J.W. & Bargai U. 1997. Radiology, p.26-33. In: Greenough P.R. (Ed.), *Lameness in Cattle*. W.B. Saunders, Philadelphia.
- Ross W.M. 2003. Diagnosis of Lameness, p.2-242. In: Dyson S.J. & Ross W.M. (Eds), *Diagnosis and Management of Lameness in the Horse*. W.B. Saunders, Philadelphia. <<http://dx.doi.org/10.1016/B978-0-7216-8342-3.50008-5>>.
- Silveira J.A.S., Albarnaz T.T., Oliveira C.M.C., Duarte M.D. & Barbosa J.D. 2009. Afecções em vacas leiteiras na bacia leiteira de Rondon do Pará. *Pesq. Vet. Bras.* 29(11):905-909. <<http://dx.doi.org/10.1590/S0100-736X2009001100007>>
- Stanek C. 1997. Examination of the locomotor system, p.14-23. In: Greenough P.R. (Ed.), *Lameness in Cattle*. 3rd ed. W.B. Saunders, Philadelphia.
- Steiner A., Geissbühler U. & Stoffel M.H. 2010. *Bovine Radiology: digital diagnostic atlas*. University of Berne, Berne, Switzerland.
- Ytrehus B., Carlson C.S. & Ekman S. 2007. Etiology and pathogenesis of Osteochondrosis. *Vet. Pathol.* 44(4):429-448. <<http://dx.doi.org/10.1354/vp.44-4-429>> <PMid:17606505>