



Partial rupture of the thigh adductor muscle in a dog: case report

[Ruptura parcial do músculo adutor da coxa em um cão: relato de caso]

M.L.A. Mistieri¹, I.C.K. Cruz^{2*}, J.P.E. Pascon¹, F.W. Strey¹,
S. Dill², E.M. Gomes²

¹Universidade Federal do Pampa - Uruguaiana, RS

²Aluno de pós-graduação - Universidade Federal do Pampa - Uruguaiana, RS

ABSTRACT

Muscle injuries are often reported in humans, but uncommon in dogs. The etiology is degenerative or traumatic, and traumatic is more common in athletes. The diagnosis is obtained by a combination of orthopedic physical examination and imaging diagnosis, such as ultrasonography. Therapy aims to optimize healing and avoid complications. The present study reports a case of partial rupture of thigh adductor muscle in a dog presenting acute lameness of the right pelvic limb. Swelling and pain in the medial region of the thigh was noticed. Ultrasound examination confirmed partial rupture of the thigh adductor muscle. The treatment included non-steroid anti-inflammatory, warm compresses, and rest. Ultrasound examinations were useful in this case to evaluate the progression of the lesion, which was rapid and satisfactory.

Keywords: dogs, ultrasound, muscular

RESUMO

Lesões musculares são frequentemente relatadas em humanos, mas pouco diagnosticadas em cães. Podem ocorrer de forma degenerativa ou traumática, sendo essa última a forma mais comum em atletas. O diagnóstico é obtido por exame físico ortopédico associado a exames de imagem, como ultrassonografia. A terapia deve ser instituída de modo a facilitar a cicatrização e evitar as complicações. O presente trabalho tem como objetivo relatar um caso de ruptura parcial de músculo adutor da coxa em um cão que apresentou claudicação aguda em membro pélvico direito, associado à tumefação e dor em região medial da coxa. O exame ultrassonográfico evidenciou ruptura parcial do músculo adutor da coxa. O paciente recebeu terapia anti-inflamatória, e foi indicado uso de compressas quentes e repouso. Foram realizados exames ultrassonográficos para acompanhamento da evolução do quadro, que foi rápida e favorável.

Palavras-chave: cães, ultrassom, muscular

INTRODUCTION

Acute muscle injuries are often reported in humans and usually associated with trauma during sports activities (Fernandes *et al.*, 2011). The ruptures are classified as partial or total and may have tendinous involvement. The etiology could be by trauma, chronic progressive stretching or degenerative (Schmitt, 2013). Lesions of thigh muscles have been described in sport players (Kimmenade *et al.*, 2015; Short *et al.*, 2016). In dogs, however, the most common muscle trauma involves gracilis, iliopsoas, pectinates, semitendinosus, and gastrocnemius

muscles (Cabon and Bolliger, 2014). Any report of thigh adductor muscle rupture was found in this species. Muscle tears are confirmed by ultrasonography or MRI (Waizy *et al.*, 2017). The clinical findings of swelling and local pain associated with history of trauma only suggest nonspecific muscle injury (Kimmenade *et al.*, 2015). The treatment for muscle ruptures varies according to the extent of the injury (partial or total) and may be clinical or surgical.

Muscle lesions are underestimated and rarely diagnosed in the clinical routine of small animals. This note aims to report the clinical, diagnostic, and therapeutic aspects of the partial

Recebido em 22 de março de 2018

Aceito em 13 de junho de 2018

*Autor para correspondência (*corresponding author*)

E-mail: igor_113@hotmail.com

rupture of thigh adductor muscle in a *Bernese Mountain Dog*.

CASUISTRY

A four-month-old *Bernese Mountain Dog*, weighing 16kg, was presented showing pain and acute lameness of the right hind limb after jumping. The orthopedic physical examination revealed lameness grade 3 during the walk and grade 4 (non weight-bearing) at the trot. The dog showed pain on sitting and standing tests. During palpation, intense pain was noticed in the medial region of the right thigh, especially during the rotation and abduction of the hip joint. No signs of crepitation of hip joint were noticed. Asymmetry, muscle atrophy, excoriations or fistulas were not observed.

Lesion in soft tissues (muscles and/or tendons), hip dysplasia, incomplete or complete fracture of

the femur or femoral neck were suspected. However, no radiographic changes were observed in the hip and right femur region, suggesting the involvement of the soft tissue lesion on medial and proximal aspect of right hind limb.

Ultrasound evaluation was performed on trichotomized medial face of the right and left thighs for comparison (Figure 1A and B), from inguinal region to knee joint. A linear multi-frequency transducer (10 and 12MHz) was used and the region was scanned in longitudinal and transverse planes. Loss of continuity in muscle fibers was observed in central area in the affected muscle (Figure 1B), suggesting intramuscular edema, in both assessment plans. Equally, origin and insertion of the muscle, were intact as well as the muscular fascia, confirming the diagnosis of partial rupture of thigh adductor muscle.

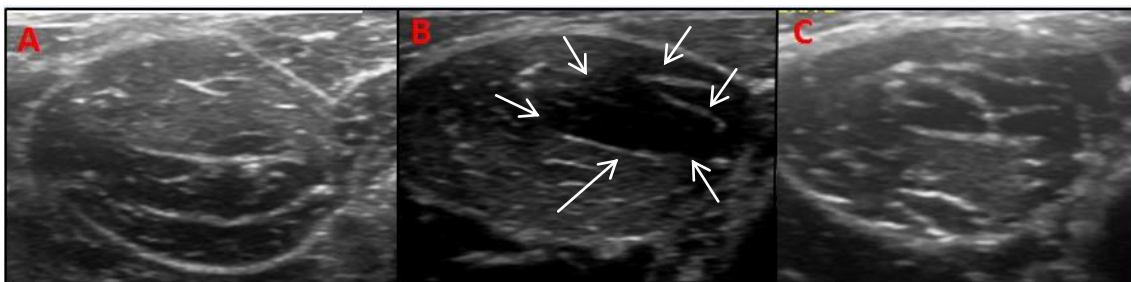


Figure 1. Ultrasound appearance of thigh adductor muscle in dog, transverse plan and linear transducer of 12MHz. A: sonographic aspect of normal thigh adductor (left hindlimb). Notice the echogenicity and homogeneity of the muscular fibers, which are continuous and limited by a hyperechoic fascia. B: Affected thigh adductor muscle (right hindlimb) on first evaluation; delimited hypo echogenic with discontinuity of the fibers is present with intact fascia (arrows). C: thigh adductor muscle of right hindlimb after twenty days of trauma. Reorganization of the muscular fibers is noticeable, showing good healing process.

The treatment involved carprofen (2.2mg/kg/BID) for five days; warm compresses (twenty minutes, TID); anti-inflammatory and ant edematous gel massage (commercial combination of dimethyl sulfoxide, aescin, prednisolone and dexametasone) on the medial aspect of the thigh and resting.

After five days of treatment, the dog presented lameness grade 2 during the walk and trot, and absence of signs of pain when standing. Discreet pain at the sitting test and on palpation of the medial aspect of the right thigh was observed. Ultrasound evaluation showed a slight reorganization of muscle fibers compared to the

initial examination, but intramuscular edema was still noticeable. The therapy was continued for twelve days after the trauma, when no lameness or pain was seen.

Ultrasonographic examination showed a reorganization of the muscle fibers with echogenicity similar to the contralateral thigh adductor muscle and confirming muscle healing (Figure 1C). The therapy was suspended, but controlled exercise for more seven days, with slow and progressive return to daily activities was recommended.

DISCUSSION

Muscle injuries are frequently reported in human athletes. According to Fernandes *et al.* (2011), more than 90% of these lesions are contusions or stretches, but lacerations are seldom diagnosed. According to Dias *et al.* (2001), these lesions may be acute (due to overload) or chronic (excessive use). In dogs, muscular ruptures have already been described in different muscles (Cabon & Bolliger, 2014), however no reports have been found regarding the thigh adductor muscle. In general, these conditions are more prevalent in sports animals due to stress or excessive muscle strength (Steiss, 2002).

Although thigh adductor muscle injuries have been reported in medicine, associated with traumas caused by sports (Kimmenade *et al.*, 2015; Short *et al.*, 2016), similar reports were not found in canines. The patient has presented a history of possible trauma, once the clinical signs appeared acutely after a jump.

It is known that the medial aspect of the thigh of dogs comprises a wide variety of muscles with different functions. In this way, muscle gracilis, pectineus and iliopsoas rupture already have been reported. According to Cabon and Bolliger (2014), the imaging examination is necessary for the definition of the site of the lesion and specific treatment.

The clinical signs of the patient were similar with those described by Cabon and Bolliger (2014). The main findings were lameness, pain, local swelling, and reduction on hip extension. To confirm the clinical suspicion, a radiographic study was carried out in order to discard bone alterations. However, it is known that radiology presents low sensitivity and specificity on diagnosis of muscle lesions (Fernandes *et al.*, 2011). In this sense, ultrasonography (US) plays an important role in providing an accurate information on muscle changes. The exam is quickly performed, with real-time evaluation and without the need for anesthesia. This procedure is indicated for evaluation of inflammatory, degenerative, and traumatic muscular changes (Cabon and Bolliger, 2014).

According to Cabon and Bolliger (2014), the ultrasound findings of a muscle include a hypoechoic pattern with echogenic reticular

areas, limited by a hyperechoic fascia. The muscular fibers are seen uniformly and parallel, in both longitudinal and transverse plans. If an injury is noticed muscle fibers are partially or totally interrupted and muscular limits. Areas with intramuscular hematoma or edema can additionally be detected by ultrasound (Draghi *et al.*, 2013).

At the reported case, discontinuity of muscle fibers and a hypoechoic area with imprecise limits were observed in the central region of thigh adductor area. These findings were very clear when compared with the non-affected hind limb. In addition, ultrasound assessment excluded damages in other muscles such as gracilis, pectineus and iliopsoas.

Clair (2012) describes that the thigh adductor muscle is divided into long adductor and short-magnum adductor. The short-magnum adductor originates from the pubic symphysis and extends to the rough face of the caudal surface of the femur and corresponds to the portion that the lesions were found.

Magnetic resonance imaging (MRI) can be used in addition to the US to confirm the suspicious of muscular rupture. MRI provides more detailed information on the location and extent of the lesions. However, it requires general anesthesia, it is a high cost exam and produces static images, which could make diagnosis difficult in some cases of partial ruptures (Yildis *et al.*, 2010). In the present report, as MRI was unavailable, and the identification of the injured muscle was obtained only by US. The authors believe that despite of it, the diagnosis and follow-up were not impaired. Also, Yildis *et al.* (2010) had previously described that precision and sensitivity of US and MRI in the diagnosis of muscle injuries are similar, and the US is considered the choice method being cheap and easy to access (Fernandes *et al.*, 2001).

Regarding the therapy, Yildis *et al.* (2010) reported systemic use analgesic, anti-inflammatory and muscle relaxant associated with physiotherapy and rehabilitation, using specific exercises and therapeutic ultrasound in thigh adductor rupture in a human athlete. In present report, systemic and topic non-steroid anti-inflammatory drugs (NSAIDs) were prescribed. According to Fernandes *et al.* (2011),

the use of NSAIDs is indicated in the acute phase of muscle injuries. These drugs decrease the cellular inflammatory reaction without affecting healing, tensile strength or muscle contraction ability, and does not delay the formation of myotubules in a short period of administration. Flores *et al.* (2012) emphasize that the use of topical NSAIDs generates high concentration in the dermis and muscle tissue, but with low availability when compared to systemic use, justifying the inclusion of systemic therapy in the present case.

It is recommended to keep the affected limb at rest after trauma, in order to avoid late muscle retraction or formation of a larger muscle gap (Fernandes *et al.*, 2011). In addition, thermotherapy with warm compresses was used. Thermotherapy increases circulation, metabolic rate, and extensibility of soft tissues and, consequently, prevents muscular contracture and reduces pain (Felice & Santana, 2009). According to Fernandes *et al.* (2011), it is indicated in post-acute phases for the treatment of muscular injuries. Due to the good healing progression there was no need for specific physiotherapy.

Finally, it is important to emphasize that the diagnosis and treatment should be instituted as soon as possible once muscular rupture may progress to fibrosis, muscle retraction, liposubstitution or ossifying myositis (Dias *et al.*, 2001). The ultrasound evaluations were also useful to the follow-up of present case. It was able to evaluate the progression of healing and help the clinician on the decision of extend therapy.

CONCLUSION

Adductor thigh muscle rupture may occur in dogs. The orthopedic physical examination and ultrasonography were enough for precise diagnosis and to follow up the evolution of muscular healing.

REFERENCES

CABON, Q.; BOLLIGER, C. Iliopsoas muscle injury in dogs. *vetlearn.com*. 2014. Available in: <<http://www.vetfolio.com/orthopedics/iliopsoas-muscle-injury-in-dogs>> Accessed in: 9 Oct. 2017.

CLAIR, L.E.S. Músculos. In: SISSON, G. *Anatomia dos animais domésticos*. 5.ed. Rio de Janeiro: Guanabara Koogan, 2012. v.2, cap.50, p.1416-1444.

DIAS, E.P.; MARCHIORI, E. *et al.* Avaliação por ressonância magnética das injúrias musculares traumáticas. *Radiol. Bras.*, v.34, p.327-331, 2001.

DRAGHI, F.; ZACCHINO, M.; CANEPARI, M. *et al.* Muscle Injuries: ultrasound evaluation in the acute phase. *J. Ultrasound*, v.16, p.209-214, 2013.

FELICE, T.D.; SANTANA, L.R. Recursos fisioterapêuticos (Crioterapia e Termoterapia) na espasticidade: revisão de literatura. *Rev. Neurociênc.*, v.17, p.57-62, 2009.

FERNANDES, T.L.; PEDRINELLI, A.; HERNANDEZ, A.J. Lesão muscular – fisiopatologia, diagnóstico, tratamento e apresentação clínica. *Rev. Bras. Ortop.*, v.46, p.247-255, 2011.

FLORES, M.P.; CASTRO, A.P.C.R.; NASCIMENTO, J.S. Topical analgesics. *Rev. Bras. Anestesiol.*, v.62, p.244-252, 2012.

KIMMENADE, R.J.L.L.; BERGEN, C.J.A.; DEURZEN, P.J.E.; VERHAGEN, R.A.W. A rare case of adductor longus muscle rupture. Case reports in orthopedics. 2015. Available in: <<http://dx.doi.org/10.1155/2015/840540>>. Accessed in: 29 Aug. 2017.

SCHMITT, B. **Ruptura do tendão calcâneo comum em cão**: Relato de caso. 23f. Monografia (Especialização em Clínica Médica e Cirúrgica de Pequenos Animais) – Fundação Educacional Jayme de Altavila, 2012.

SHORT, S.M.; ANLOAGUE, P.A.; STRACK, D.S. Rehabilitation and return to sport following surgical repair of the rectus abdominis and adductor longus in a professional basketball player: a case report. *J. Orthop. Sports Phys. Ther.*, v.46, p.697-706, 2016.

STEISS, J.E. Muscle disorders and rehabilitation in canine athletes. *Vet. Clin. N. Am. Small Anim. Pract.*, v.32, p.267-285, 2002.

YILDIZ, K.; YAZICI, A.G.; YILDIRIM, Ö.S. Isolated traumatic rupture of the adductor brevis in an amateur soccer player (case report). *Spor Hekimligi Dergisi*, v.45, p.65-70, 2010.

WAIZY, H.; BOUILLON, B.; STUKENBORG-COLSMAN, C. *et al.* Rupture of the tendon of the tibialis anterior muscle. Etiology, clinical symptoms and treatment. *Der Unfallchirurg*. 2017. Available in: <<https://www.ncbi.nlm.nih.gov/pubmed/28980032>>. Accessed in: 18 Jan. 2018.