









**Lumbar paravertebral block in a rabbit (*Oryctolagus cuniculus*)
submitted to pelvic limb amputation – case report**

[Bloqueio paravertebral lombar em coelho (*Oryctolagus cuniculus*) submetido
à amputação de membro pélvico – relato de caso]

E.C. Siepmann¹ , D.C. Alves¹ , H.K. Nishimura¹ , S.K.C. Malta¹ , J. Lunedo¹ ,
L.Y. Tanabe¹ , R.R. Debiage² , F.B. Fukushima³ 

¹Graduate, Hospital Veterinário, Universidade Federal do Paraná, Setor Palotina, Palotina, PR, Brasil

²Graduate, Universidade Federal do Paraná, Setor Palotina, PR, Brasil

³Universidade Federal do Paraná, Setor Palotina, PR, Brasil

ABSTRACT

The concern about pain management in exotic mammals is increasing. However, only a few studies describe locoregional anesthesia techniques in rabbits. Thus, this report aims to describe the lumbar paravertebral block, guided by peripheral nerve stimulation, in a rabbit undergoing mid-femoral amputation. We received a one-year-old rabbit weighing 1.27kg with a history of non-union of the right femur and osteomyelitis. The animal came to us for high pelvic limb amputation. After premedication with ketamine, midazolam, and morphine, the patient was maintained under general anesthesia in a non-rebreathing circuit under spontaneous ventilation with isoflurane vaporized in 0.6 oxygen. Using a peripheral nerve stimulator, we performed the lumbar paravertebral block, positioning the needle between the L5 and L6 vertebrae and injecting 0.2mL/kg bupivacaine. The patient remained stable throughout the procedure, without the need for analgesic rescue with opioids during surgery and postoperatively. The discharge occurred after 24 hours. The lumbar paravertebral block proved efficient for trans and postoperative analgesia for high pelvic limbic amputation in rabbits.

Keywords: pet rabbit, psoas compartment, peripheral nerve stimulation, regional anesthesia

RESUMO

A preocupação quanto ao manejo da dor em mamíferos exóticos é crescente, entretanto existem poucos estudos que descrevem o uso de técnicas de anestesia locoregional em coelhos. Assim, este relato tem por objetivo descrever o bloqueio paravertebral lombar guiado por neurolocalizador em um coelho submetido à amputação mediofemoral. Um coelho de um ano de idade e 1,27kg foi atendido com histórico de não união de fêmur direito e osteomielite, sendo encaminhado para amputação alta do membro pélvico. Após pré-medicação com cetamina, midazolam e morfina, o paciente foi mantido sob anestesia geral em circuito sem reinalação de gases, sob ventilação espontânea com isoflurano vaporizado em 0,6 de oxigênio. O bloqueio do plexo lombar foi realizado pela abordagem paravertebral, com o auxílio de neurolocalizador, sendo a agulha posicionada entre as vértebras L5 e L6 e injeção de 0,2mL/kg de bupivacaína 0,5%. O paciente manteve-se estável durante todo o procedimento, sem a necessidade de resgate analgésico com opioides no trans e no pós-operatório. O paciente recebeu alta médica após 24 horas. O bloqueio lombar paravertebral demonstrou-se eficiente para analgesia trans e pós-operatória no procedimento de amputação alta de membro pélvico de coelho.

Palavras-chave: coelhos domésticos, compartimento psoas, estimulador de nervos periféricos, anestesia regional

INTRODUCTION

The concern about adequate pain management in exotic mammals has been growing lately. In this regard, local anesthetics are the mainstay in analgesic protocols, as they block the generation and conduction of nerve impulses by inhibiting sodium channels, with minimal systemic effects (Otero and Portela, 2018). However, despite the efforts, few studies describe the use of regional anesthesia techniques in domestic rabbits, especially for the pelvic limb (D'ovidio *et al.*, 2014). The increased interest in peripheral blocks relies on their analgesic effects comparable to those of neuraxial blocks, with fewer complications (Caniglia *et al.*, 2011; Campoy *et al.*, 2012).

Cranial dispersion of the local anesthetic and sympathetic blockade with cardiovascular collapse, respiratory depression, apnea, shock, and death are the main complications related to the epidural injection. Additionally, lagomorphs are at higher risk of inadvertent puncture of the subdural space and intoxication by overdose (Otero and Portela, 2018) since the medullary cone extends to the sacral vertebrae (Greenaway *et al.*, 2001), making the lumbosacral puncture not recommended.

Alternatively, pelvic limb analgesia can be achieved by the deposition of the local anesthetic close to the main nerves that emerge from the lumbosacral plexus, formed by the ventral branches of the last lumbar nerves and, in rabbits, by four sacral nerves S1-S4 (Greenaway *et al.*, 2001; Campoy, 2006). The anatomy of the spine and the origin of the nerve roots vary among species. However, the ventral branches of L4, L5, and L6 usually emerge from their intervertebral foramen and move ventrolaterally to penetrate below the transverse processes of the lumbar vertebrae to the psoas compartment - the space between the psoas major and minor muscles, where the femoral nerve (FN) originates (Otero and Portela, 2018).

In domestic animals, the FN provides innervation to the femur, knee, medial portion of the joint capsule, intra-articular structures of the knee, and the skin in the medial aspect of the pelvic limb. Analgesia of practically the entire hind limb can be achieved when performing the lumbar paravertebral block, in the psoas compartment,

given the blockade of the femoral, obturator, and genitofemoral nerves (Campoy, 2006; Otero and Portela, 2018).

Based on the similarity between dog and rabbit neuroanatomy, we report the clinical application of the nerve stimulator-guided psoas-compartment block, also known as the lumbar paravertebral block in a rabbit undergoing high pelvic limb amputation.

CASE REPORT

We received a 1.27kg female rabbit (*Oryctolagus cuniculus*) at the Veterinary Teaching Hospital of the Universidade Federal do Paraná, Setor Palotina (HVP-UFPR), with a history of bone non-union, anatomical deformity, and functional impotence of the right pelvic limb due to a traumatic event as a puppy. The radiographic examination revealed loss of the anatomical shape of the acetabulum, remodeling of the proximal portion of the femur due to exuberant bone callus and bone misalignment, incongruence of the hip joint, an old fracture in the distal portion of the tibia, fibula, and tarsus, in addition to muscle atrophy. After two months, the patient returned with skin discontinuity associated with purulent secretion and oedema of the affected limb, and a new radiographic study suggested an inflammatory/infectious process associated with oedema and a reduction in bone radiopacity. The hematological and serum biochemical were unremarkable. Due to osteomyelitis, the animal came to us for mid-femoral amputation of the right pelvic limb.

After a two-hour fasting, the animal was premedicated with 30mg/kg ketamine (Cetamin®, Syntec, Santana de Parnaíba, SP, Brazil), 1mg/kg midazolam (Midazolam®, Hipolabor, Sabará, MG, Brazil), and 1 mg/kg morphine (Dimorf®, Cristália, Itapira, SP, Brazil), intramuscularly (IM). After 5 minutes, the animal presented mild sedation, allowing catheter placement in the auricular vein and fluid therapy with ringer lactate at 5mL/kg/h. After pre-oxygenation and mask induction with 2.5% isoflurane (Isoforine®, Cristália, Itapira, SP, Brazil), we performed orotracheal intubation with a 2mm uncuffed endotracheal tube, and maintained anesthesia with isoflurane in 0.6 oxygen, through a non-rebreathing circuit (Baraka) under spontaneous ventilation.

The patient was positioned in left lateral recumbency and assessed for heart rate (HR), respiratory rate (RR), oxyhemoglobin saturation (SpO₂), electrocardiography (ECG), rectal temperature (RT), end-tidal CO₂ (EtCO₂), end-tidal isoflurane (EtIso) and invasive blood pressure (SBP, DBP, MAP).

After antisepsis of the right pelvic limb, we approached the lumbosacral plexus using the paravertebral technique, aided by a peripheral nerve stimulator (STIMPOD NMS 450®, Xavant Technology, Silverton, Pretoria, South Africa). We placed the positive electrode on the skin at the level of the right knee joint. The spinous processes of L5 and L6 were located through palpation and marked with a dermatographic pen. We introduced the needle perpendicularly at the midpoint between the anatomical references (Fig. 1), about 2cm lateral to the dorsal line, and adjusted the electrical current to 1.2 mA, 2 Hz, and 0.1ms. After contraction of the quadriceps femoris muscle, we reduced the current to 0.5 and 0.2 mA. In the absence of muscle response at 0.2mA, we readjusted the current to 0.5mA and slowly injected 0.2 ml/kg of 0.5% bupivacaine (Neocaína®, Cristália, Itapira, SP, Brazil). We were able to observe an immediate interruption of the muscle contraction.

The surgery lasted 70 minutes, and the physiological parameters remained within the reference values for the species throughout the amputation procedure (Table 1). We maintained end-tidal isoflurane between 1.2 to 1.9% and defined the need for rescue analgesia as a 10% increase in heart rate, 50% increase in respiratory rate, or 30% increase in systemic blood pressure (D'ovidio *et al.*, 2014) compared to baseline values. There was no need for analgesic rescue during the surgery. Extubation occurred three minutes after discontinuation of the inhaled anesthetic, and recovery was uneventful.

At the end of the surgery, the animal received 0.2mg/kg meloxicam (Maxicam®, Ourofino, Cravinhos, SP, Brazil) and 25mg/kg dipyrone (Dipifarma®, Farmace, Barbalha, CE, Brazil) intravenously, and 3mg/kg of tramadol

(Tramadol Hydrochloride®, União Química, São Paulo, SP, Brazil) intramuscularly for analgesia. We assessed the postoperative pain through the response to surgical wound palpation and the observation of species-specific behavior. Such parameters included appetite, defecation, breathing pattern, body posture, interest in the environment, and level of spontaneous activity (D'ovidio *et al.*, 2014). Two hours and 30 minutes after the end of the procedure, the animal started to feed spontaneously. The discharge occurred after 24 hours, with no signs of pain or discomfort.

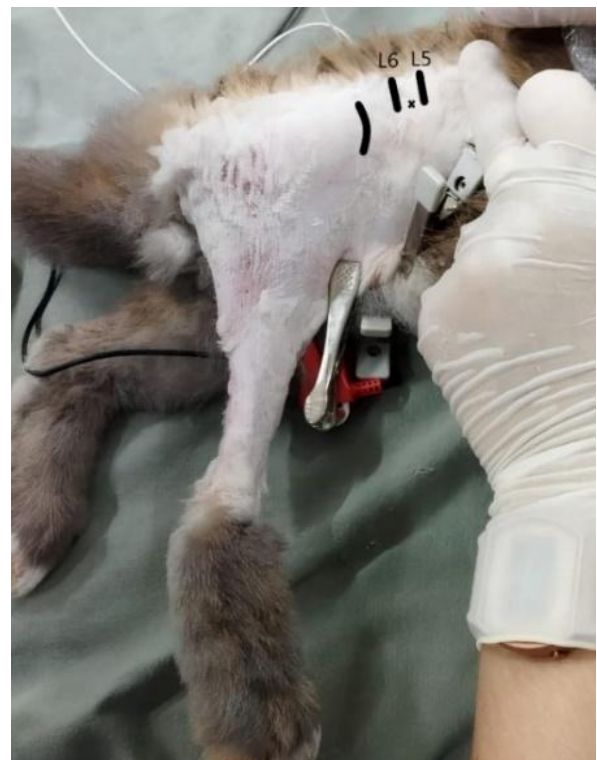

Figure 1. Nerve stimulator-guided lumbar paravertebral block in a rabbit (*Oryctolagus cuniculus*) undergoing mid-femoral amputation. Note the anatomical reference points (L5 and L6) near the iliac crest and the needle insertion site, represented with an X.

Table 1. Physiological and anesthetic parameters in *Oryctolagus cuniculus* submitted to lumbar paravertebral block for limb amputation. T0 corresponds to the baseline period, and the following times are presented in minutes. The evaluated parameters included heart (HR) and respiratory (RR) rates, oxyhemoglobin saturation (SpO₂), systolic (SBP) and mean (MAP) blood pressure, end-tidal CO₂ (EtCO₂), end-tidal isoflurane (EtIso), and rectal temperature (RT)

	T0	T15	T30	T45	T60
HR (bpm)	250	240	237	254	251
RR (mpm)	35	30	22	20	15
SpO ₂ (%)	-	97	98	100	98
SBP (mmHg)	110	100	123	125	108
MAP (mmHg)	98	86	88	106	79
EtCO ₂ (mmHg)	-	12	18	13	8
EtIso (%)	-	1.6	1.6	1.2	1.9
RT (°C)	37.5	37.5	37.3	37.1	37.9

DISCUSSION

This report demonstrates that the lumbar paravertebral block is a viable regional technique in rabbits undergoing high pelvic limb amputation, and it is, to the author's knowledge, the first report of the technique in lagomorphs.

Currently, four different approaches have been described for the femoral nerve block in dogs: the femoral triangle (Mahler and Adogwa, 2008), the three-point lumbar paravertebral block with injections at L4, L5, and L6 (Portela *et al.*, 2010), the pre-iliac approach (Portela *et al.*, 2013), and the one-point lumbar paravertebral block with the injection between L5 and L6 (Campoy, 2006). Given the potential risks of the epidural injection (McCally *et al.*, 2015) and aiming at blocking the proximal portion of the femur to promote analgesia compatible with the surgical stimulation, we opted for the lumbar paravertebral block.

Despite the description of the paravertebral injection of lidocaine with methylene blue at a dose of 0.4mL/kg in the psoas compartment (Campoy *et al.*, 2008), there are no studies that prove the spread of the local anesthetic over the nerve roots of L4 to L6. Portela *et al.* (2010) modified the described technique and achieved incomplete limb desensitization in dermatomes innervated by the sciatic nerve when using 0.2 ml/kg of 0.25% bupivacaine, distributed in three injection points, associated with parasacral block of the sciatic nerve.

In the present report, no nociceptive response occurred during surgical manipulation, even with a small volume (0.2mL/kg) of 0.5% bupivacaine

in a single injection point. This result suggests that, perhaps, the higher concentration of the local anesthetic used in this case promoted desensitization of some nerve fibers of the lumbosacral plexus and that the volume was sufficient to block both the femoral and sciatic nerves since the latter originates at the height of L6 or L5 in rabbits with seven and six lumbar vertebrae, respectively (Greenaway *et al.*, 2001).

Despite the anatomical similarities between domestic animals and rabbits, some differences might impact the performance of local blockade. Greenaway *et al.* (2001) demonstrated that there are variations in the number of thoracic and lumbar vertebrae in the species, with only 45.8% of rabbits having the "typical" configuration, with twelve thoracic and seven lumbar vertebrae (12T/7L). Other patterns were also observed, such as an extra pair of ribs and/or a lumbar vertebra (13T/6L-13T/7L). That is a factor that must be analyzed before extrapolating anatomical references to perform locoregional blocks. In the present case, direct extrapolation was possible since the animal exhibited the typical conformation.

In addition to the cardiorespiratory stability, maintenance of the anesthetic plan was marked by a reduced isoflurane requirement, corroborating the effectiveness of regional blockade. Decreased use of intravenous analgesics contributes to hemodynamic stability and faster anesthetic recovery (Campoy *et al.*, 2008), as observed in the present case, in which extubation occurred within three minutes, and normal behavior resumed a few hours after surgery.

Typically, multimodal anesthesia combines opioid premedication and peripheral nerve block (Portela *et al.*, 2013). However, opioids can interfere with the assessment of the effectiveness of the nerve block. In the present report, the previous use of morphine may have contributed to the analgesic efficacy, which cannot be attributed solely to the nerve block technique.

As it allows the objective identification of the target nerve, the use of a peripheral nerve stimulator contributed to the effectiveness of the technique and reduced the risk of iatrogenic injuries by intraneural injection (D'Ovidio *et al.*, 2014). Other possible complication includes the penetration of the needle into the abdominal cavity, for its excessive deepening in the ventral direction (Portela *et al.*, 2013). In this case, we did not observe any execution-related complications.

CONCLUSION

The nerve stimulator-guided lumbar paravertebral block promoted trans and postoperative analgesia for mid-femoral limb amputation in a domestic rabbit (*Oryctolagus cuniculus*), which we were able to confirm by the reduced isoflurane requirement, absence of analgesic rescue, and fast postoperative recovery.

REFERENCES

- CAMPOY, L. Fundamentals of regional anesthesia using nerve stimulation in the dog. In: GLEED, R.D.; LUDDERS, J.W. (Eds.). *Recent advances in veterinary anesthesia and analgesia: companion animals*. Ithaca: IVIS, 2006. (Document n. A1416.0408). Available in: <https://www.ivis.org/library/recent-advances-veterinary-anesthesia-and-analgesia-companion-animals/fundamentals-of>. Accessed in: 17 Jul. 2021.
- CAMPOY, L.; MARTIN-FLORES, M.; LOONEY, A.L. *et al.* Distribution of a lidocaine-methylene blue solution staining in brachial plexus, lumbar plexus and sciatic nerve blocks in the dog. *Vet. Anaesth. Analg.*, v.35, p.348-354, 2008.
- CAMPOY, L.; MARTIN-FLORES, M.; LUDDERS, J. W. *et al.* Comparison of bupivacaine femoral and sciatic nerve block versus bupivacaine and morphine epidural for stifle surgery in dogs. *Vet. Anaesth. Analg.*, v.39, p.91-98, 2012.
- CANIGLIA, A.; LARENZA, M.P.; PUERTO, D. *et al.* Efficacy of epidural analgesia versus femoral-sciatic nerve block for stifle surgery in dogs. *Vet. Anaesth. Analg.*, v.38, p.1-35, 2011.
- D'OVIDIO, D.; ROTA, S.; NOVIELLO, E. *et al.* Nerve stimulator-guided sciatic-femoral block in pet rabbits (*Oryctolagus cuniculus*) undergoing hind limb surgery: a case series. *J. Exotic Pet Med.*, v.23, p.91-95, 2014.
- GREENAWAY, J.B.; PARTLOW, G.D.; GONSHOLT, N. *et al.* Anatomy of the spinal cord in rabbits. *J. Am. Anim. Hosp. Assoc.*, v.37, p.27-34, 2001.
- MAHLER, S.P.; ADOGWA, A.O. Anatomical and experimental studies of brachial plexus, sciatic, and femoral nerve-location using peripheral nerve stimulation in the dog. *Vet. Anaesth. Analg.*, v.35, p.80-89, 2008.
- MCALLY, R.E.; BUKOSKI, A.; BRANSON, K.R. *et al.* Comparison of short-term postoperative analgesia by epidural, femoral nerve block, or combination femoral and sciatic nerve block in dogs undergoing tibial plateau leveling osteotomy. *Vet. Surg.* v.44, p.983-987, 2015.
- OTERO, P.E.; PORTELA, D.A. *Manual de anestesia regional em animais de estimação*. São Paulo: MedVet, 2018. p.145-153, 290-296.
- PORTELA, D.A.; OTERO, P.E.; BRIGANTI, A. *et al.* Femoral nerve block: a novel psoas compartment lateral pre-iliac approach in dogs. *Vet. Anaesth. Analg.*, v.40, p.194-204, 2013.
- PORTELA, D.A.; OTERO, P.E.; TARRAGONA, L. *et al.* Combined paravertebral plexus block and parasacral sciatic block in healthy dogs. *Vet. Anaesth. Analg.*, v.37, p.531-541, 2010.