









Ophthalmic parameters in adult Pomeranian dogs

[Parâmetros oftálmicos em cães adultos da raça Lulu da Pomerânia]

F.A. Fachini¹ , K.K. Kobashigawa² , G.M. Madruga² , M.R. Filézio¹ ,
N.R.N. Cruz² , P.C. Moraes³ , J.L. Laus³ , F.S. Oliveira³ 

¹ Undergraduate, Universidade Estadual Paulista, Faculdade de Ciências Agrárias e Veterinárias, FCAV/Unesp, Jaboticabal, SP, Brasil

² Graduate, Universidade Estadual Paulista, FCAV/Unesp, Jaboticabal, SP, Brasil

³ Universidade Estadual Paulista, FCAV/Unesp, Jaboticabal, SP, Brasil

ABSTRACT

The objective of this study was to establish ophthalmic parameters in the Pomeranian dog breed. Schirmer tear test (STT), tear breakup time test (TBUTT), Jones test (JT), aesthesiometry, biomicroscopy, tonometry, non-contact specular microscopy (SM), ophthalmoscopy and ultrasonography (US) were carried out 48 eyes of 24 male and female Pomeranian dogs from a breeding kennel. Descriptive statistics was applied for data analysis. Means and standard errors found for STT, TBUT, JT, esthesiometry and tonometry were 24.310±0.448mm/min, 14.570±0.406s., 8.420±1.571min, 3.667±0.157cm and 17.960±0.697mmHg, respectively. For biomicroscopy, 43.75% of the eyes presented caruncle trichiasis, 25% chromodacryorrhea, 25% medial entropion and 10.42% distichiasis. SM showed endothelial cells density of 1958.285±36.760 cells/mm². For hexagonality, endothelial cells area and central corneal thickness were 62.229±2.183%, 519.231±9.853mm², 0.567±0.006mm, respectively. Ophthalmoscopy presented a pattern described in other breeds. Amelanotic fundus was reported in 8.33% of the eyes. The US means and standard errors for axial length of the eyeball, lens thickness, anterior and vitreous chamber depth were 16.859±0.148mm, 6.651±0.081mm, 2.673±0.091mm and 7.485±0.101mm. Mild changes in the lacrimal evaluation parameters were influenced by eyelid changes in STT type I. Increased corneal sensitivity was observed in the breed.

Keywords: anatomy, canine, German Spitz, ophthalmology, racial

RESUMO

O objetivo do estudo foi estabelecer os parâmetros oftálmicos na raça Spitz Alemão anão. Realizaram-se teste lacrimal de Schirmer (TLS), tempo de ruptura do filme lacrimal (TRFL), teste de Jones (TJ), estesiometria, biomicroscopia, tonometria, microscopia especular (MS), oftalmoscopia e ultrassonografia (US) em 48 olhos de 24 cães machos e fêmeas da raça Spitz Alemão anão, oriundos de canil de criação. Aplicou-se estatística descritiva. As médias e erros padrões encontrados para TLS, TRFL, TJ, estesiometria e tonometria foram 24,310±0,448mm/min, 14,570±0,406s., 8,420±1,571min, 3,667±0,157cm e 17,960±0,697mmHg, respectivamente. À biomicroscopia, 43,75% dos olhos apresentaram triquíase de carúncula, 25% cromodacriorréia, 25% entrópio de canto medial e 10,42% distiquíases. À MS, os valores para densidade das células endoteliais, hexagonalidade, área das células endoteliais e espessura corneal central foram 1958,285±36,760 cells/mm², 62,229±2,183%, 519,231±9,853mm² e 0,567±0,006mm, respectivamente. À oftalmoscopia, padrão conforme descrito para cães. Fundo amelanótico foi reportado em 8,33% das retinas. Ao US, os valores identificados para diâmetro axial horizontal, espessura da lente, profundidade das câmaras anterior e posterior foram 16,859±0,148mm, 6,651±0,081mm, 2,673±0,091mm and 7,485±0,101mm. Leves alterações nos parâmetros lacrimais foram influenciadas por alterações palpebrais no TLS tipo I. Sensibilidade corneana aumentada foi identificada na raça.

Palavras-chave: anatomia, cães, Spitz Alemão, oftalmologia, raça

INTRODUCTION

There is a growing popularity of Pomeranian dogs in the current decade, a factor linked to the characteristics of these animals, such as ease of learning, constant activity, dedication to the owner, indifference to the climate and longevity (Fédération Cynologique Internationale, 2013). The maintenance of breeds invariably causes a reduction in genetic diversity and increases the repeatability of specific racial patterns, which favors the chances of genetic disorders, altering expressed phenotypes and impacting health (Mellersh, 2008). The Fédération Cynologique Internationale disqualifies animals of the breed that have entropion or ectropion. Presence of 58% of hereditary retinal degeneration cases has been reported in the breed (Kelawala *et al.*, 2017). There is no data in the literature standardizing the ophthalmic parameters in the studied breed, as well as there is a scarcity in the description of the main pathological and anatomical alterations that can be found more frequently. Thus, the aim of the study was to establish these parameters in Pomeranian dogs, identify breed characteristics and describe possible common pathologies.

MATERIAL AND METHODS

Upon approval by the Ethics Committee for the Use of Animals (CEUA) (protocol n° 000316/19), 48 eyes were studied in 24 Pomeranian dogs (*Canis familiaris*), 12 males and 12 females, aged from 1 to 7.5, mean weight of 3.804 ± 1.324 kg, from the breeding kennel. Those who showed clinical signs of systemic disease or clinical or hematological changes were excluded from the study.

First, Schirmer Tear Test (STT) 1 (Schirmer Tear Test, Drogavet, RP, Brazil) was used, inserted in the conjunctival fornix of the medial third of the lower eyelid for 60 seconds (Ollivier *et al.*, 2007; Andrade, 2008; Kobashigawa *et al.*, 2015). Subsequently tear breakup time test (TBUTT) was evaluated by applying fluorescein sodium (Fluorescein Strips, Ophthalmos, SP, Brazil) and the measurement of the tear film breakup time was analyzed with a cobalt blue filter light and slit lamp, with the aid of a stopwatch (Ollivier *et al.*, 2007; Andrade, 2008; Kobashigawa *et al.*, 2015).

Continuing the evaluation, Jones test (JT) was performed by applying fluorescein sodium without subsequent rinsing and later timing of the passage of the dye through the nasolacrimal system to the ipsilateral nostril. Animals with a positive test were those in which the dye passage occurred between 0 seconds and 30 minutes, and as negative, those that the dye was not seen in the nostrils, after 30 minutes (Ollivier *et al.*, 2007; Maggs, 2008; Martin, 2009; Binder and Herring, 2010; Featherstone and Heinrich, 2013).

Corneal sensitivity was obtained by averaging three consecutive measurements using the Cochet-Bonnet aesthesiometer (C-B) (esthesiometer, Luneau Ophthalmologie, Paris, França) initiating the stimuli at 6cm (Lisbão *et al.*, 2012; Ribeiro *et al.*, 2012; Kobashigawa *et al.*, 2015). Both eyes of each animal were inspected using a slit-lamp biomicroscope (Portable slit-lamp SL-145, Kowa, Tokyo, Japan), with 10x increase. Eyelids, third eyelid, bulbar and palpebral conjunctiva, cornea, anterior chamber and iris were evaluated (Ollivier *et al.*, 2007; Andrade, 2008; Martin, 2009). Intraocular pressure (IOP) was measured by the rebound tonometer (Tonovet Plus, icare, Finlândia), mid-morning and mid-afternoon randomly, with computation of the average of three consecutive measurements (Andrade, 2008).

The non-contact specular microscopy was used (Specular Microscopy SP-300P, Topcon, Japan) under delicate physical restraint to obtain specular images of the central corneal area, considering the density (cells/mm²) (DE), the hexagonality (%) (HEX), corneal endothelial cells area (µm²) (EA) and the central corneal thickness (mm) (CT). The minimum count was 50 cells, and the values were tabulated in Cell Count software and the count was corrected manually (Nagatsuyu *et al.*, 2014; Kobashigawa *et al.*, 2015).

Thirty minutes after instillation of one drop of tropicamide 1% (Tropinom, Genom Oftalmologia®, São Paulo, Brazil), lens were evaluated and images were obtained by ophthalmoscopy (Retinal Camera TCR-50DC, Topcon, Japan) for evaluation of the posterior segment of the eye structures and image recording of the retina and optic disc (Hubbard *et*

Ophthalmic parameters...

al., 1999; Li *et al.*, 2012; Kobashigawa *et al.*, 2015).

Finally, with the use of ultrasound (Ultrasound Ultrascan A/B, Alcon®) and through the transcorneal method, ocular ultrasound images were obtained in a low-light environment, after instillation of tropicamide 1% and tetracaine hydrochloride 1% + phenylephrine hydrochloride 0.1% (Anesthetic Allergan Inc, São Paulo, Brazil) in both eyes. A-mode and B-mode were used simultaneously, using a 20 MHz circular probe and sterile gel (Supra Gel, Adlin Plásticos, LTDA, Jaraguá do Sul, Brazil). Assessments of axial length of the eyeball (AL), lens thickness (L) and lengths of the anterior (AC) and vitreous (VC) chambers were performed (Martin, 2009; Guimarães, 2011; Kobashigawa *et al.*, 2015).

The variables were tested for statistical normality (Microsoft Excel 2016) through the Kolmogorov-Smirnov test. Statistical significance was set at $p < 0.05$, with a 95% confidence interval. Data were represented as mean, standard error and median. Box-plots graphics were constructed to summarize the data distribution.

RESULTS

The means, standard errors and medians were represented in Tab. 1. In the data distribution of STT mean of 24.310 ± 0.448 mm/min and median of 24.500 mm/min were found the specimen that presented eyelid disorder, there was a statistical difference regarding the s that presented medial entropion (25.562 ± 2.828 mm/min).

Table 1. The mean, median and standard error values for Schirmer tear test; breakup time test; Jones test Cochet-Bonnet esthesiometry; intraocular pressure; laser flaremetry; non-contact specular microscopy and the ultrasound measured in 24 eyes of adult Pomeranian dogs from a kennel.

	Mean \pm standard error	Median
STT (mm/min)*	24.310 \pm 0.448	24.500
TBUTT (s)*	14.570 \pm 0.406	14.170
JT (min)	8.420 \pm 1.571	6.840
C-B (cm)*	3.667 \pm 0.157	3.500
IOP (mmHg)	17.960 \pm 0.697	17.330
DE (cells/mm ²)*	1958.285 \pm 36.760	1939.000
HE (%)*	62.229 \pm 2.183	65.000
CT (mm)*	0.567 \pm 0.006	0.573
CA (μ m ²)*	519.231 \pm 9.853	515.800
CV (%)	22.454 \pm 6.002	21.000
AL (mm)*	16.859 \pm 0.148	16.900
LT (mm)	6.651 \pm 0.081	6.840
AC (mm)*	2.673 \pm 0.091	2.650
VC (mm)*	7.485 \pm 0.101	7.560

*Gaussian distribution of the Kolmogorov-Smirnov test ($p < 0,05$)

STT – Schirmer tear test; TBUTT – breakup time test; JT – Jones test; C-B – Cochet-Bonnet esthesiometry; IOP – intraocular pressure; DE – cells density; HE – hexagonality; CT – corneal thickness; CA – endothelial cell area; CV – coefficient of variation; AL – axial length of the eyeball; LT – lens thickness; AC – anterior chamber; VC – vitreous chamber. mm/min – millimeters per minute; s – seconds; min – minutes; cm – centimeters; mmHg – millimeters of mercury; cells/mm² - cells per square millimeter; % - percentage; mm – millimeters; μ m² - square micrometers.

The TBUTT data showed a mean of 14.570 ± 0.406 s and median of 14.170s. In the interval of 0 to 30 minutes, 62.50% (n=30) of the eyes presented positive JT, while 37.50% (n=18) showed negative results. Among the positive

samples, the mean was 8.420 ± 1.571 min and median 6.840 min.

The values observed for aesthesiometry regarding mean and median were 3.667 ± 0.157

cm and 3.500 cm, respectively. Through inspection with the slit lamp, 43.750% (n=21) of the eyes were identified with caruncle trichiasis, 25.000% (n=12) chromodacryorrhea, 25.000% (n=12) medial entropion, 10.420% (n=5) distichiasis, 6.250% (n=3) macular corneal opacity, 4.160% (n=2) presence of an eyelid nodule and 2.080% (n=1) nasal fold trichiasis. The IOP had mean and median of 17.960 ± 0.697 mmHg and 17.330 mmHg, respectively.

In Table 1, the non-contact specular microscopy data regard to the endothelial cell density data, mean of 1958.285 ± 36.760 cells/mm² and median of 1939,000 cells/mm² were identified and, for hexagonality, mean of $62.229\pm 2.183\%$ and median of 65,000% were obtained. The area of endothelial cells showed a mean of

$519.231\pm 9.853\mu\text{m}^2$ and median of $515.800\mu\text{m}^2$. In the central corneal thickness, mean of 0.567 ± 0.006 mm and median of 0.573mm were found. Mean value for coefficient of variation (CV) was $22.454\pm 6.002\%$ and median of 21.000%.

The images obtained at ophthalmoscopy (Fig. 1) present a pattern as described for dogs (Narfström and Petersen-Jones, 2013). The optical disc is located predominantly in a nontapetal area, 66.670% (n=32), followed by the transition area, 20.830% (n=10) and the tapetal area, 4.270% (n=2). 39.580% (n=19) of the samples had yellow tapetal area, 33.330% (n=16) orange, 18.760% (n=9) greenish-yellow and 8.330% (n=4) of the samples were identified with amelanotic fundus.

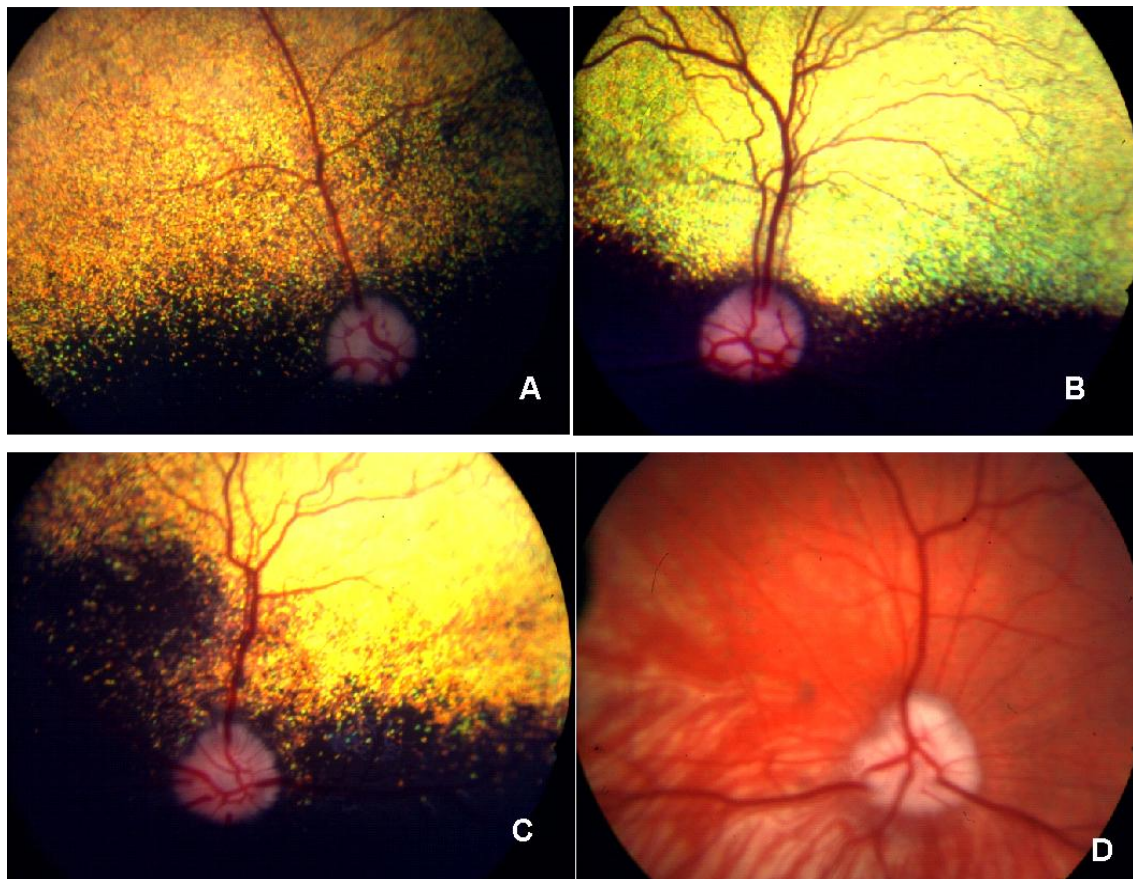


Figure 1. Images of normal eye fundus of adult Pomeranian dogs. In A, the left eye of a male, an orange tapetal fundus and a circular disc at the nontapetal fundus. In B, right eye of a female dog, yellow tapetal fundus, circular disc at the nontapetal fundus. In C, right eye of a female, orange tapetal fundus, triangular disc at the border of the tapetal and nontapetal areas. In D, left eye of a female, with an amelanotic fundus and triangular disc.

Ultrasonographic results in A-mode (Table 1) were identified. The axial length of the eyeball presented mean and median of 16.859 ± 0.148 mm and 16.900mm, respectively. Lens thickness had mean and median of 6.651 ± 0.081 mm and 6.840mm, and anterior chamber depth with mean of 2.673 ± 0.091 mm and median of 2.650mm. Finally, mean and median obtained for vitreous chamber depth was 7.485 ± 0.101 mm and 7.560 mm. There was no statistical difference, except for lens thickness. Regarding B-mode ultrasound images, no changes were identified.

DISCUSSION

Reduction in STT values is described with advancing age of the individual (Hartley *et al.*, 2006) In this study, patients aged over 5 years had mean of 23.550 ± 3.576 mm/min, a value lower than that found for those aged under 5 years, 24.857 ± 2.649 mm/min, but without statistical difference ($p>0.05$). Studies indicate an STT value for young animals 15.930 ± 5.750 mm/min and 15.580 ± 5.900 mm/min, for right and left eye, respectively (Broadwater *et al.*, 2010). In the present study, a mean of 24.310 ± 0.448 mm/min was identified. This value is close to the upper limit for animals with mean age of 4.463 years (Featherstone and Heinrich, 2013). High STT values can correlate with some changes found in the research, such as caruncle trichiasis, chromodacryorrhea, medial entropion and negative test for Jones (Grahn and Sandmeyer, 2013). Accordingly, STT mean in samples with eyelid alterations was higher than STT mean in eyes without eyelid alterations, with statistical significance only for eyes with medial entropion in relation to healthy eyes. This data corroborates with the hypothesis that the conditions found resulted in STT mean of the study close to the upper limit.

The TBUTT value of 14.570 ± 0.406 s was lower than the described reference value of 19.7 ± 5 s (Ollivier *et al.*, 2007). However, it was like that demonstrated in Shih Tzu dogs, 13.66 ± 0.53 s, a brachycephalic breed with multifactorial alterations that corroborate to lower TBUTT, unlike Pomeranian that has mesocephalic cranial conformation (Kobashigawa *et al.*, 2015). It is valid to consider that the aforementioned test has assessment subjectivity, which can interfere with the results obtained.

It is known that, in the Jones test, the average time of fluorescein passage through the nasolacrimal canal is 248 s or 4.13 min to dogs (Binder and Herring, 2010). Dolichocephalic dogs present lower time than mesaticephalic and brachycephalic dogs (Binder and Herring, 2010). Contradictorily, in the present study, mean of $8,420\pm 1,571$ min or 505 s was obtained, values that can be attributed to the changes previously described, since they hinder lacrimal drainage, such as medial corner entropion, in addition to abnormalities of the nasolacrimal duct not detected (Grahn and Sandmeyer, 2013).

Pomeranian dogs had a high mean for C-B, 3.667 ± 0.157 cm, when compared to the values described in Beagles of 1.900 cm, also mesocephalic dogs (Lisbão *et al.*, 2012). This data represents increased corneal sensitivity in the breed, which may derive from adequate corneal innervation (Featherstone and Heinrich, 2013). The results were superior to those found in Shih Tzu dogs (2.395 ± 0.071 cm) (Kobashigawa *et al.*, 2015), agreeing with the already known, brachycephalic breeds have decreased corneal sensitivity, differently from what was observed in dogs in this study (Kafarnik *et al.*, 2008).

Animals with alterations such as entropion are disqualified by the International Federation of Cynology (2013). In this research, mild medial entropion was diagnosed in 25% of the individuals, which, supposedly, indicates the existence of management failures. It is important to consider that alterations like these can lead to more serious changes. Furthermore, it should be noted that the group studied has high genetic variability, since the person responsible for the kennel has a considerable collectives of Pomeranian dogs ($n>100$), in addition to crossbreeding with partner kennels to increase variability.

The use of TonoVet Plus to measure IOP was efficient, given the small diameter of the eyes of the individuals studied and the more accurate precision it provides (Spiessen *et al.*, 2013). The IOP values of 17.960 ± 0.697 in the Pomeranian are according to what has already been described for dogs, from 15.000 to 18.000 mmHg (Featherstone and Heinrich, 2013).

Non-contact specular microscopy demonstrated a hexagonality pattern ($62.229 \pm 2.183\%$) according to the values described (51.000 to 64.000%). The density of endothelial cells ($1958.285 \pm 36,760$ cells mm^2) was lower than that reported by other authors, with mean of 2300.000 cells/ mm^2 to 2500.000 cells/ mm^2 (Gwin *et al.*, 1982; Nagatsuyu *et al.*, 2014; Miyagi *et al.*, 2019). The area of the endothelial cells showed mean of $519.231 \pm 9.853 \mu\text{m}^2$, a higher value than that already reported (426.000 to $475.000 \mu\text{m}^2$) (Nagatsuyu *et al.*, 2014; Miyagi *et al.*, 2019). Regarding the central corneal thickness, the values were close to the mean described in Beagle dogs ($550.810 \pm 62.350 \mu\text{m}$) (Garzón-Ariza *et al.*, 2018). There is a significant diurnal variation in the central corneal thickness. The thickness is greater when the evaluations are performed at 10 am, which may be related to the degree of corneal hydration (Garzón-Ariza *et al.*, 2018). In Pomeranian dogs, samples mean evaluated at 10 am was $0.591 \pm 0.051 \mu\text{m}$, a value higher than the mean of the other time points ($0.560 \pm 0.044 \mu\text{m}$), but not statistically different ($p > 0.05$).

The optic disk in dogs is located in the center of ocular fundus and may be in the tapetal or non-tapetal region, a factor that varies according to the tapetum extension (Narfström and Petersen-Jones, 2013). The study demonstrated a predominance of the optic disc in the non-tapetal area (66.670%), similar to what has been described in another study (Kobashigawa *et al.*, 2015). In a distinct study, subalbinotic pattern fundus was described in 7 eyes, in addition to an optical disc located predominantly at the junction of the non-tapetal area and the tapetal area (Sini *et al.*, 2016), while in this paper 4 specimen (8.330%) of amelanotic fundus were found.

Ultrasonographic measurements are within known normality standards, although there is no variety of studies other than brachycephalic (Kobashigawa *et al.*, 2015; Abreu *et al.*, 2018).

Control or eradication of hereditary ocular disorders is dependent on the ability to diagnose the disorder and its mode of inheritance, considering factors such as the age at which the condition can develop and from which it will no longer develop. When conditions are identified prior to the reproductive age, control is facilitated. The difficulty is trying to persuade

breeders, especially when the condition is not considered severe (Barnett, 1988).

CONCLUSION

Mild changes were observed in parameters of lacrimal evaluation. Considering the values of STT, the parameters were influenced by eyelid changes. Higher corneal sensitivity was noted in this breed. Pathologies such as mild caruncle trichiasis, mild medial corner entropion and chromodacryorrhea were diagnosed.

ACKNOWLEDGMENTS

The authors declare no conflicts of interest. Funded by CAPES, Coordination of Improvement of Higher-Level Personnel (001). Funding sources did not have any involvement in the study design, data analysis and interpretation, or writing and publication of the manuscript. The authors thank the contributions of all the participating dogs and their kennel, veterinarians, and veterinary ophthalmologists.

REFERENCES

- ABREU, T.G.M.; FELICIANO, M.A.R.; RENZO, R. *et al.* Acoustic radiation force impulse elastography of the eyes of brachycephalic dogs. *Arq. Bras. Med. Vet. Zootec.*, v.70, p.1045-1052, 2018.
- ANDRADE, A.L. Semiologia do sistema visual dos animais domésticos. In.: FEITOSA, F.L.P. *Semiologia veterinária*. 2ed. São Paulo: Roca, 2008. p.623-653.
- BARNETT, K.C. Inherited eye disease in the dog and cat. *J. Small Anim. Pract.*, v.29, p.462-475, 1988.
- BINDER, D.R.; HERRING, I.P. Evaluation of nasolacrimal fluorescein transit time in ophthalmically normal dogs and nonbrachycephalic cats. *Am. J. Vet. Res.*, v.71, p.570-574, 2010.
- BROADWATER, J.J.; COLITZ, C.; CARASTRO, S.; SAVILLE, W. Tear production in normal juvenile dogs. *Vet. Ophthalmol.*, v.13, p.321-325, 2010.
- FEATHERSTONE, H.J.; HEINRICH, C.L. The eye examination and diagnostic procedures. In.: GELLAT, K.N.; GILGER, B.C.; KERN, T.J. *Veterinary ophthalmology*. 5ed. Iowa: John Wiley & Sons, 2013. v.1, p.553-570,
- GARZÓN-ARIZA, A.; GUISSADO, A.; GALÁN, A.; MARTÍN-SUARÉZ, E. Diurnal variation in intraocular pressure and central corneal thickness and the correlation between these factors in dogs. *Vet. Ophthalmol.*, v.21, p.464-470, 2018.

Ophthalmic parameters...

- GERMAN Spitz, including Keeshond and Pomeranian. Bélgica: Fédération Cynologique Internationale, 2013. p.1-12. Available in: <http://www.fci.be/Nomenclature/Standards/097g05-en.pdf>. Accessed in: 27 Apr. 2019.
- GRAHN, B.H.; SANDMEYER, L.S. Disease and surgery of the canine nasolacrimal system. In: GELLAT, K.N.; GILGER, B.C.; KERN, T.J. *Veterinary ophthalmology*. 5ed. Iowa: John Wiley & Sons, 2013. v.2, p.894-905.
- GUIMARÃES, P.J. *Padronização e comparação dos valores ecobiométricos e eletrorretinográficos em cães hígdos das raças terrier brasileiro e beagle*. 2011. 49f. Dissertação (Mestrado em Cirurgia Veterinária) – Faculdade de Ciências Agrárias e Veterinárias, Universidade Estadual Paulista, Jaboticabal, SP.
- GWIN, R.M.; LERNER, I.; WARREN, J.K.; GUM, G. Decrease in canine corneal endothelial cell density and increase in corneal thickness as function of age. *Invest. Ophthalmol. Vis. Sci.*, v.22, p.267-271, 1982.
- HARTLEY, C.; WILLIAMS, D.L.; ADAMS, V.J. Effect of age, gender, weight, and time of day on tear production in normal dogs. *Vet. Ophthalmol.*, v.9, p.53-57, 2006.
- HUBBARD, L.D.; BROTHERS, R.J.; KING, W.N. *et al.* Methods for evaluation of retinal microvascular abnormalities associated with hypertension/sclerosis in the atherosclerosis risk in communities study. *Ophthalmology*, v.106, p.2269-2280, 1999.
- KAFARNIK, C.; FRITSCH, J.; REESE, S. Corneal innervation in mesocephalic and brachycephalic dogs and cats: assessment using in vivo confocal microscopy. *Vet. Ophthalmol.*, v.11, p.363-367, 2008.
- KELAWALA, D.N.; PATIL, D.B.; PARIKH, P.V. *et al.* Clinical studies on progressive retinal atrophy in 31 dogs. *Iran J. Vet. Res.*, v.18, p.119-123, 2017.
- KOBASHIGAWA, K.K.; LIMA, T.B.; PADUA, I.R.M. *et al.* Ophthalmic parameters in adult Shih Tzu dogs. *Ciênc. Rural*, v.45, p.1280-1285, 2015.
- LI, Z.; WU, C.; OLAYUWOLA, J.N. *et al.* Telemedicine-based digital retinal imaging vs standard ophthalmologic evaluation for the assessment of diabetic retinopathy. *Conn. Med.*, v.76, p.85-90, 2012.
- LISBÃO, C.B.S.; CORRÊA, M.A.; ORTIZ, J.P.D. *et al.* Effects of the *Ottonia martiana* Miq. (piperaceae) extract on dog's ocular surface. *Arq. Bras. Med. Vet. Zootec.*, v.64, p.577-584, 2012.
- MAGGS, D.J. Cornea and sclera. In: SLATTER, D.N. *Fundamentals of veterinary ophthalmology*. 4ed. Missouri: Elsevier, 2008. p.175-178.
- MARTIN, C.L. Anamnesis and the ophthalmic examination. In: _____. *Ophthalmic disease in veterinary medicine*. Boca Raton: Taylor & Francis Group, 2009. p.11-38.
- MELLERSH, B.C. Give a dog a genome. *Vet. J.*, v.178, p.46-52, 2008.
- MIYAGI, H.; STANLEY, A.A.; CHOKSHI, T.J. *et al.* Comparison of automated vs manual analysis of corneal endothelial cell density and morphology in normal and corneal endothelial dystrophy-affected dogs. *Vet. Ophthalmol.*, v.2, p.44-51, 2019.
- NAGATSUYU, C.E.; ABREU, P.B.; KOBASHIGAWA, K.K. *et al.* Non-contact specular microscopy in aphakic and pseudophakic dogs. *Ciênc. Rural*, v.44, p.682-687, 2014.
- NARFSTRÖM, K.; PETERSEN-JONES, S.M. Diseases of the canine ocular fundus. In: GELLAT, K.N.; GILGER, B.C.; KERN, T.J. *Veterinary ophthalmology*. 5ed. Iowa: John Wiley & Sons, 2013. v.2, p.1308-1310.
- OLLIVIER, F.J.; PLUMMER, C.E.; BARRIE, K.P. The examination and diagnostic procedures. In: GELLAT, K.N.; GILGER, B.C.; KERN, T.J. *Veterinary Ophthalmology*. 4ed. Iowa: Blackwell Publishing, 2007. v.1, p.438-476.
- RIBEIRO, A.P.; SILVA, M.L.; ARAÚJO, R.L. *et al.* Expression of matrix metalloproteinases, type IV collagen, and interleukin-10 in rabbits treated with morphine after lamellar keratectomy. *Vet. Ophthalmol.*, v.15, p.153-163, 2012.
- SINI, K.R.; KELAWALA, D.B.; PATIL, D.B. *et al.* EA. Ocular funduscopy of different canine breeds in India – A clinical study of 70 normal dogs. *Intas Polivet.*, v.17, p.328-333, 2016.
- SPIESSEN, L.V.; KARCK, J.; ROHN, K.; MEYER-LINDENBERG, A. Clinical comparison of the Tonovet® rebound tonometer and the Tono-Pen Vet® applanation tonometer in dogs and cats with ocular disease: glaucoma or corneal pathology. *Vet. Ophthalmol.*, v.18, p.2027, 2013.