


Observations of the coccidian infection, *Eimeria labbeana*-like, in experimentally infected domestic pigeons (*Columba livia domestica*) associated with pathological effects

[Observações da infecção coccidiana, *Eimeria labbeana*-like, em pombos domésticos (*Columba livia domestica*) experimentalmente infectados, associada a efeitos patológicos]

R. Abdel-Gaber¹ , S. Al Quraisy¹ , N. Al-Hoshani², E.M. Al-Shaebi¹ ,
O.B. Mohammed¹ , A. Marey³, M. Dkhil⁴ 

¹Department of Zoology, College of Science, King Saud University, P.O. 2455, Riyadh 11451, Saudi Arabia

²Department of Biology, College of Science, Princess Nourah bint Abdulrahman University, P.O. Box 84428, Riyadh 11671, Saudi Arabia

³Molecular Biotechnology Program, Faculty of Science, Helwan University, Cairo, Egypt

⁴Department of Zoology and Entomology, Faculty of Science, Helwan University, Cairo, Egypt

ABSTRACT

Genus *Eimeria* is a group of obligate Protista parasites within phylum Apicomplexa that causes a major threat to animal production. Little information is available about the coccidia of pigeons. This study was undertaken to study experimental infection in domesticated pigeons, its clinical signs, and pathological interpretation due to *Eimeria* species. *Eimeria labbeana*-like oocysts were used as a model parasite for experimental infection of pigeons. Twenty pigeons were brought and examined for 7 days to ensure they were coccidia-free. Five pigeons were separated into parasite passage. The remaining pigeons were divided into a control group of five pigeons, and ten pigeons were infected with 3×10^4 *E. labbeana*-like oocysts. Infected pigeons showed ruffled feathers, greenish watery diarrhea, weakness, blood-tinged droppings, etc. Pre-patent and patent durations were five and fourteen days of oral inoculation of *Eimeria*. Oocysts shedding began on the 5th-day p.i. and peaked on the 8th-day p.i. There is a significant loss in body weight due to infection. Histopathological examination showed damage to intestinal mucosa with various *Eimeria* developmental stages in the duodenum of the small intestine. This study is considered basic information on the first detection of biology of *Eimeria* species infecting pigeons in Saudi Arabia.

Keywords: Coccidiosis, pigeons, clinical signs, histopathology, parasite stages

RESUMO

O gênero *Eimeria* é um grupo de parasitas protistas obrigatórios do filo Apicomplexa que causam uma grande ameaça à produção animal. Há poucas informações disponíveis sobre coccídios de pombos. Este trabalho foi realizado para estudar a infecção experimental em pombos domesticados, seus sinais clínicos e interpretação patológica devido a espécies de *Eimeria*. Oocistos semelhantes a *Eimeria labbeana* foram usados como modelo de parasita para a infecção experimental de pombos. Vinte pombos foram trazidos e examinados por sete dias para garantir que estivessem livres de coccídios. Cinco pombos foram separados para a passagem do parasita. Os pombos restantes foram divididos em um grupo de controle de cinco pombos, e dez pombos foram infectados com 3×10^4 oocistos do tipo *E. labbeana*. Os pombos infectados apresentaram penas desgrenhadas, diarreia aquosa esverdeada, fraqueza, fezes com coloração de sangue etc. As durações pré-patente e patente foram de cinco e quatorze dias de inoculação oral de *Eimeria*. A liberação de oocistos começou no 5º dia p.i. e atingiu seu pico no 8º dia p.i. Há uma perda significativa no peso corporal devido à infecção. O exame histopatológico mostrou danos à mucosa intestinal com vários estágios de desenvolvimento da *Eimeria* no duodeno do intestino delgado. Este estudo é considerado uma informação básica sobre a primeira detecção da biologia de espécies de *Eimeria* infectando pombos na Arábia Saudita.

Palavras-chave: Coccidiose, pombos, sinais clínicos, histopatologia, estágios do parasita

INTRODUCTION

Pigeons have adapted to life everywhere in close association with human beings (Sari et al., 2008). They harbor several infective stages of various intestinal parasitic diseases, including coccidiosis (Kommu et al., 2016). *Coccidia* is a group of protozoal pathogens that grow and multiply in the epithelial cells of the intestinal tract of pigeons destroying the host tissues (Joseph et al., 2017). There are many *Eimeria* species have been identified from the family Columbidae. There are five species with varying degrees of virulence in pigeons, were *E. labbeana* (Pinto, 1928), *E. columbarum* (Nieschulz, 1935), *E. columbae* (Mittra and Das Gupta, 1937), *E. tropicalis* (Malhotra and Ray, 1961), and *E. labbeana*-like (Yang et al., 2016). The source of infection is fecal matter containing microscopic spores (oocysts) which are transmitted orally with food. The life cycle for *Eimeria* species is monoxenous with a high host specificity (Duszynski et al., 1999). The coccidian spore requires a developmental period (sporulation) in a moist place outside the host with proper humidity and temperature, to produce within itself the minute forms (sporozoites) which can begin the parasitic multiplication within the host (Molta et al., 1999).

Identification of *Eimeria* species can be based not only on the traditional approaches including the morphology, geographic distribution, host species, and pathology (Yang et al., 2014) but also on molecular tools and to describe the genotyping of the specific genes (Yang et al., 2016). Coccidiosis is mostly found in young birds, especially when these are intensively reared and when their hygienic status is poor. Older birds act as carriers and remain healthy (McDougald and Raid, 1991). In young pigeons, the disease is acute with retarded growth, loss of body weight, excretion of blood-streaked feces, fertility disturbances, and mortality (McDougald, 2003; Aleksandra and Pilarczyk, 2014; Abdul Latif et al., 2016; Dong et al., 2018).

Several previous studies have been conducted on coccidiosis of Columbiformes worldwide (Bandyopadhyay et al., 2006; Marques et al., 2007; Sari et al., 2008; Raś-Noryńska et al., 2011; Jamriška and Modrý, 2012; Mahdii and Al-Rubaie, 2013; Aleksandra and Pilarczyk, 2014; Parsani et al., 2014; Kim et al., 2015;

Abdul Latif et al., 2016; Yang et al., 2016; Mohammed et al., 2017; Saikia et al., 2017; Joseph et al., 2017; Alkharigy et al., 2018; Elseify et al., 2018; Kassem et al., 2018; Ramesh et al., 2018; Dong et al., 2018; Gadelhaq and Abdelaty, 2019; Bartosik et al., 2020; Ortúzar-Ferreira et al., 2020; Taroda et al., 2020; Aboelhadid et al., 2021; Al-Agouri et al., 2021; Mahmoud et al., 2021; Oliveira et al., 2021; Salgado-Miranda and Sorano-Vargas, 2021; Alasadiy et al., 2022; Das et al., 2022). However, there is a paucity of information regarding the coccidian infection of pigeons in Saudi Arabia. This study was conducted to study the details of intestinal pathology caused by *Eimeria labbeana*-like in domesticated pigeons.

MATERIALS AND METHODS

A total of 20 white domestic pigeons, *Columba livia domestica* (200-250 gm), were used as experimental animals. Pigeons were purchased from the local animal market in Riyadh, Saudi Arabia. Pigeons were kept in specific pathogen-free conditions at a controlled temperature (23±5 °C), maintained under a 12/12 hr light-dark cycle. Pigeons were housed indoors in well-ventilated cages with *ad libitum* access to food and water. All pigeons were raised following the institution's guidelines on the care and use of animals in research (approval no. KSU-SU-23-45).

Eimeria labbeana-like was used as a model coccidial parasite. Oocysts were passaged in five pigeons. Unsporulated oocysts were collected from pigeon feces, sporulated in 2.5% potassium dichromate, and then washed in buffered phosphate solution (Schito and Barta, 1997). The species composition of coccidia was determined based on the morphological characteristics of oocysts and their sporulation time, according to Eckert et al. (1995). These oocysts were adjusted such that each pigeon was given 3×10^4 sporulated oocysts in 100 µL of physiological saline by oral gavage (Qudoos et al., 2020).

Pigeons were divided into two groups, as follows: the control group (n=5) that was orally gavaged with saline, and the infected group (n=10) with 3×10^4 *E. labbeana*-like. All pigeons were weighed individually, and the body weight gain (BWG) was calculated by subtracting the initial body weight (at day 0 p.i.) from the final

body weight (at day 8 p.i.). On the 8th-day p.i., all pigeons (except five pigeons from the infected group) were euthanized by receiving an intraperitoneal injection of sodium pentobarbital (Blink Health, NY, US), then dissected and necropsied (Saikia *et al.*, 2017). The rest of the pigeons (5 infected pigeons) were followed until the 14th-day to report pre- and patent periods.

Fecal pellets were collected daily from each pigeon within the *E. labbeana*-like infected group. Samples were first examined grossly to establish their consistency and color and the presence of mucus, blood, etc. Oocysts were counted in a McMaster chamber and expressed as the number of oocysts per gram (OPG) of wet feces (Eckert *et al.*, 1995). Additionally, fecal samples were mixed with 2.5% potassium dichromate solution, left at 25-27 °C, and then examined to follow the process of sporulation, according to Levine (1985). Photographs were taken for sporulated oocysts using a Leica DM 2500 microscope (NIS ELEMENTS software, version 3.8) and then measured in micrometers (µm) using ImageJ 1.53e software (Wayne Rasband and contributors, National Institute of Health, USA) and expressed as a range (mean in parentheses).

For histological studies, the duodenum was rapidly removed, fixed in 10% neutral buffered formalin overnight, and then dehydrated in serial dilutions of ethyl alcohol (Bancroft and Stevens, 1982). Samples were cleared in xylene and embedded in paraffin wax. Serial 5 µm thick sections were cut, followed by deparaffinization and staining with routine hematoxylin and eosin (H&E) method, following the standard procedure of Luna (1968).

Dommels *et al.* (2007) scored stained sections of the duodenum for inflammatory lesions, as evidenced by infiltrations of mononuclear cells, neutrophils, eosinophils, and plasma cells, as well as tissue destruction and healing. Every aspect of the inflammatory lesion, tissue damage, and tissue repair was assigned a rating score ranging from 0 (no change from normal tissue) to 3 (lesions involved most locations and all layers). The total histological injury score was calculated by adding the sum of inflammatory lesions (which was doubled to give this criterion greater weight), tissue destruction, and tissue repair scores.

To detect the coccidian endogenous stages, sections were examined and photographed by Leica DM 2500 microscope (NIS ELEMENTS software, version 3.8). Parasite developmental stages were measured in micrometers (µm) using ImageJ 1.53e software (Wayne Rasband and contributors, National Institute of Health, USA) and expressed as a range (mean in parentheses).

Data were analyzed using SPSS v.18 software program (SPSS Inc., Chicago, Illinois, USA) and expressed as mean ± standard deviation (SD). Duncan's test was used to compare differences between groups at a significant level of $p \leq 0.01$.

RESULTS

Experimental infection was carried out in healthy disease-free pigeons for the establishment of the *E. labbeana*-like infection. The change in the physical appearance of the infected pigeons and the microscopic detection of the oocysts during experimental infection of *E. labbeana*-like is shown in Table 1. The pre-patent period began with *E. labbeana*-like infection and ended with the beginning of the oocyst shedding in feces on the 5th-day p.i. The patent period began with the oocyst shedding which increased gradually until it reached a maximum level (1712×10^3 oocyst/g feces) on the 8th-day p.i., then began to decline beginning from the 9th-day p.i. till reaching its minimum level on the 14th-day p.i. (Figure 1).

The sporulation time of oocysts ranged from 24-36 hr. These oocysts were subspherical to spherical shape (Figure 2) measuring about 18.79-21.85 (20.44) × 15.98-16.71 (16.36) in size without oocyst residuum and micropyle. There is a significant reduction in the BWG, on the 8th-day p.i., regarding loss of appetite after the infection with *E. labbeana*-like for infected pigeons in comparison to the control group (Figure 3).

The hematoxylin-eosin sections revealed that *E. labbeana*-like produced dramatic histological alterations in the infected duodenum, with multiple developmental stages of the parasite visible within the parasitophorous vacuole in the duodenal villi (Figure 4). Two merogonic (asexual) stages were observed, multinucleated meront of 6.75-6.92 (6.81) × 3.95-4.51 (4.02) and merozoites (6-8 merozoites/meront) of 2.03-2.45 (2.33) × 0.79-0.85 (0.82). Merozoites were

differentiated into micro- and macrogamonts after invasion of the host epithelial cells. Microgamonts of 8.70-8.96 (8.43) × 6.01-6.79 (6.20) were recognized by a large number of dark small nuclei distributed all over the whole surface of the gamonts. Macrogamonts of 11.31-11.85 (11.45) × 8.04-8.37 (8.11) were spherical, being

provided with a central prominent large nucleus. Developing oocysts were observed with non-differentiated zygotes. Furthermore, the infected pigeons appeared to have a significant inflammatory injury (Figure 5), according to analysis by Dommels et al. (2007).

Table 1. Observations on the experimentally infected pigeons with *E. labbeana*-like

Days after infection	Physical appearance of affected pigeons	Oocyst output
0 day	Pigeons are in healthy status and no alteration is observed	-
1 st day p.i.	Pigeons appeared normal and no alteration was observed	-
2 nd day p.i.	Pigeons appeared normal and no alteration was observed	-
3 rd day p.i.	Pigeons appeared normal and no alteration was observed	-
4 th day p.i.	Pigeons appeared normal and no alteration was observed	-
5 th day p.i.	Pigeons showed slight droopiness, ruffled feathers	+
6 th day p.i.	Pigeons showed slight droopiness, ruffled feathers, lime-color-constipated feces	++
7 th day p.i.	Pigeons showed decreased feed intake and weight, weakness, watery diarrhea	++
8 th day p.i.	Pigeons showed decreased feed intake and body weight, thirst, severe weakness, droopiness, severe weakness, feces of a greenish color	+++
9 th day p.i.	Pigeons showed decreased feed intake and body weight, thirst, severe weakness, droopiness, severe weakness, feces of a greenish color	+++
10 th day p.i.	Pigeons unable to move, severe weakness, blood in droppings	++
11 th day p.i.	Pigeons unable to move, severe weakness, blood in droppings	++
12 th day p.i.	Pigeons showed weakness	++
13 th day p.i.	Pigeons showed weakness	+
14 th day p.i.	Pigeons sacrificed	+

+, minimum shedding; ++ moderate shedding; +++ maximum shedding; - no shedding

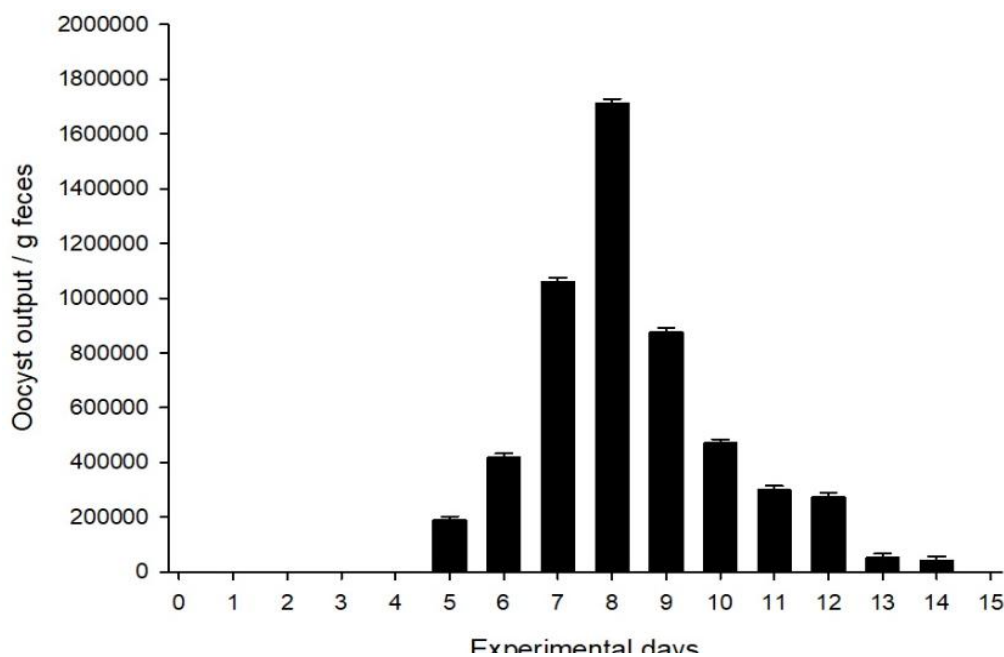


Figure 1. Oocyst output after inoculation of pigeons with *Eimeria labbeana*-like for 14 days.

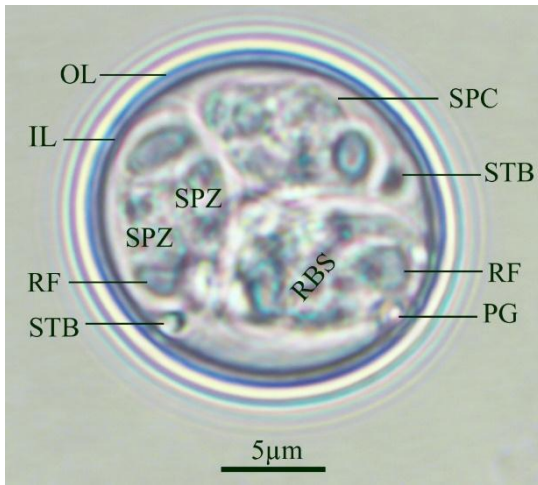


Figure 2. Sporulated oocyst of *Eimeria labbeana*-like infecting pigeons. (Note: OL, outer layer; IL, inner layer; RF, refractile body; STB, stieda body; PG, polar granule; SPC, sporocyst; RBS, residuum of sporocyst; SPZ, sporozoite) Scale bar = 5µm.

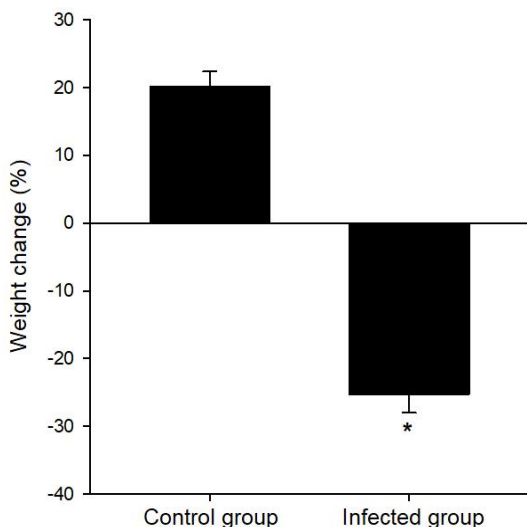


Figure 3. Weight loss due to infection with *Eimeria labbeana*-like in pigeons. * represents significance against the control group.

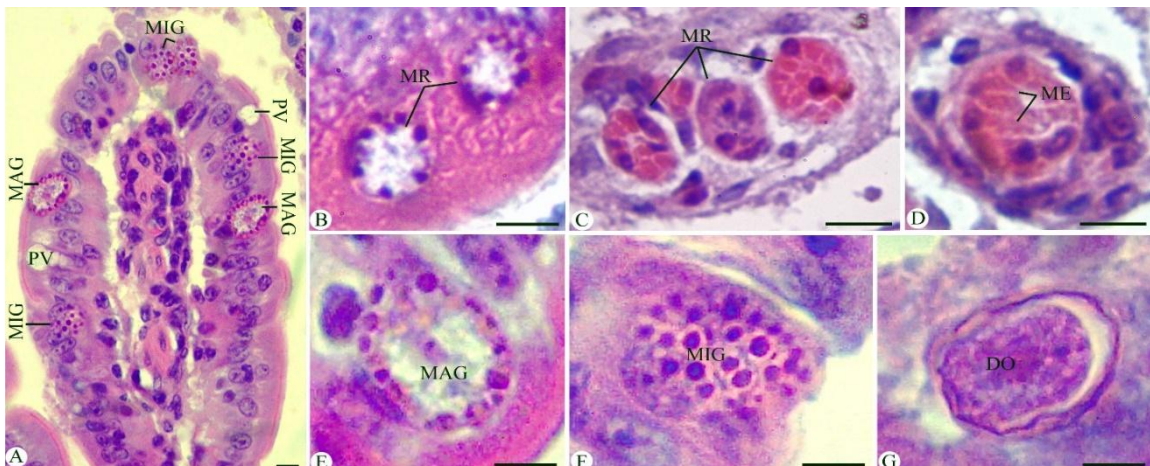


Figure 4. Sections stained with hematoxylin and eosin (H&E) for the infected duodenum with *Eimeria labbeana*-like on the 8th-day p.i. showing different developmental stages. Note: PV, parasitophorous vacuole; MR, meront; ME, merozoite; MAG, macrogamont; MIG, microgamont; DO, developing oocyst. Scale bar = 5µm.

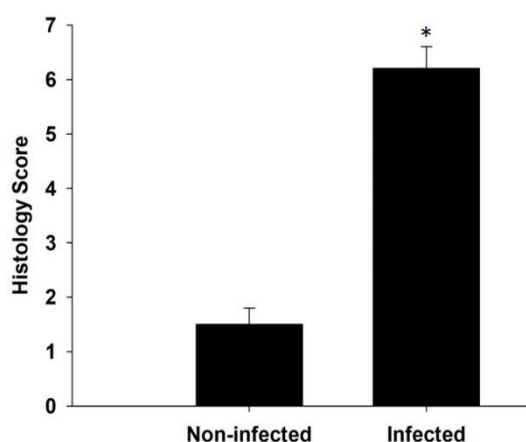


Figure 5. Duodenum histology score of pigeons infected with *Eimeria labbeana*-like. Scores were calculated according to Dommels *et al.* (2007). Values are expressed as mean \pm SD. * Significance against the non-infected (control) pigeons at $p \leq 0.01$.

DISCUSSION

The protozoan *Eimeria* species is emerging as a significant avian pathogen on a global scale (Mohammed *et al.*, 2017). Pigeons are considered reservoirs for various parasitic infections, especially coccidiosis, and transmit them to healthy birds through their plumage and fecal matter (Abdul Latif *et al.*, 2016). However, important gaps remain in our understanding of the epidemiology and pathogenicity of the avian *Eimeria* species. In Saudi Arabia, no studies have been conducted concerning coccidian infections in pigeons. This is the first study to demonstrate the pathological effects of *Eimeria* species among pigeons in Saudi Arabia.

Fecal diagnosis is probably the most common laboratory procedure for parasitic infections which could reveal the presence of parasites in several body systems (Abdul Latif *et al.*, 2016). The results revealed that the fecal examination of pigeons after coccidian infection with *E. labbeana*-like showed the oocyst shedding from the 5th – 14th-day p.i. Burr (1987) stated that numerous coccidian species were observed in birds and these protozoans infected the small intestine and produced the oocysts that were passed out through fecal matter. Oocysts of *Eimeria* species were identified in the fecal samples based on the keys provided by Soulsby (1982). Considering the oocysts' micrometry and

sporulation time, the recovered *Eimeria* species confirmed its identity as *E. labbeana*-like.

The coccidian infection causes a change in the physical appearance of experimentally infected pigeons with *E. labbeana*-like oocysts on the 5th-day p.i., there are similar findings were reported by McDougald (2003), Dalloul and Lillehoj (2005), Bandyopadhyay *et al.* (2006), Josephy *et al.* (2017), Saikia *et al.* (2017), and Sood *et al.* (2018). In this study, the pre-patent period began with the coccidian infection and ended with oocysts shedding in fecal matter on the 5th-day p.i. The oocysts reached the optimum shedding rate in the 8th day p.i. and the patent period extended to the 14th day p.i. This finding is consistent with Saikia *et al.* (2017) stated the highest concentration of oocysts is shed in feces after eight days of infection. In reverse other studies documented the pre-patent period on the 7-8th day p.i. regarding the geographical location and the pigeon species used in the study (Nieschulz, 1925; Bondonis, 1936; Morini, 1950; Stewart, 1957; Srivastava, 1966; Varghese, 1977; Krautwald-Junghanns *et al.*, 2009; Aleksandra and Pilarczyk, 2014).

In addition, Mahdi and Al-Rubaie (2013) and Saikia *et al.* (2017) observed a significant reduction in the body weight of birds affected with *Eimeria* infection, which agreed with our findings. This loss might be due to the consumption of the parasitic *Eimeria* stages to the nutrients inside the epithelial cells of the duodenum and lead to severe alterations (Mahdii and Al-Rubaie, 2013). The description of the endogenous stages is a species-specific character in the genus *Eimeria*, and the recovered ones were nearly identical to those reported in Varghese (1977). Moreover, histological analysis revealed that the inflammatory process occurring in pigeons' gut is strong and exacerbated by *Eimeria* invasion, which accords with Dkhil *et al.* (2013) reported that the developmental *Eimeria* stages invade the gut epithelial cells of the host and results in an inflammatory injury with varying degrees according to the level of *Eimeria* infection.

CONCLUSION

Based on the previous data, it could be concluded that coccidian infection can lead to an increase in mortality rates and has severe economic consequences for domesticated

pigeons. Specific precautions must be taken to monitor coccidiosis in pigeons considering that these birds are in contact with other poultry.

ACKNOWLEDGMENTS

This study was supported by the Researchers Supporting Project (RSP2023R25), King Saud University, Riyadh, Saudi Arabia; and by Princess Nourah bint Abdulrahman University Researchers Supporting Project number (PNURSP2023R437), Princess Nourah bint Abdulrahman University, Riyadh, Saudi Arabia.

REFERENCES

- ABDUL LATIF, A.; FAZAL, S.; MANZOOR, F. *et al.* A comparative study on prevalence of coccidian parasites in broiler chicken (*Gallus gallus domesticus*), Japanese quail (*Coturnix coturnix japonica*) and wild pigeon (*Columba livia*). *Pak. J. Zool.*, v.48, p.295-297, 2016.
- ABOELHADID, S.M.; ARAFA, W.M.; ABDELATY, A.S. *et al.* Remarks on *Eimeria labbeana* infection in domestic pigeons “*Columbia livia domestica*”. *J. Parasit. Dis.*, v.45, p.1145-1151, 2021.
- AL-AGOURI, S.; ALRWAB, N.; AMGAWER, H.; SADAGA, G.; ALSHELMANI, M.I. Prevalence of coccidia in domestic pigeons (*Columba livia domestica* Gmelin, 1789) in Benghazi city, Libya. *Aceh J. Anim. Sci.*, v.6, p.52-56, 2021.
- ALASADIY, D.K.; MAHMOOD, M.; ALHASNAWI, N.A. A comparative study of parasitic infections in domestic and wild pigeons in Iraq. *Arch. Razi Inst.*, v.77, p.709-715, 2022.
- ALEKSANDRA, B.R.; PILARCZYK, B. Occurrence of coccidia infection in pigeons in amateur husbandry. Diagnosis and prevention. *Ann. Parasitol.*, v.60, p.93-97, 2014.
- ALKHARIGY, F.A.; EL NAAS, A.S.; MAGHRBI, A.A.E. Survey of parasites in domestic pigeons (*Columba livia*) in Tripoli, Libya. *Open Vet. J.*, v.8, p.360-366, 2018.
- BANCROFT, J.D.; STEVEN, A.F. (1982) *Theory and practice of histological techniques*. 2.ed. Endinburgh, London: Churchill Living Stone, 1982. p.622-630.
- BANDYOPADHYAY, P.K.; BHAKTA, J.N.; SHUKLA, R. A new *Eimeria* species (Protozoa: Apicomplexa: Sporozoa) from the blue rock pigeon *Columba livia* (Aves: Columbidae). *Zoos' Print J.*, v.21, p.2386-2387, 2006.
- BARTOSIK, J.; ŁOJEK, J.; VETTER, W. *et al.* Prevalence of intestinal parasitic infections of carrier pigeons from central Poland in the years 2012-2019. *Med. Wet.*, v.76, p.714-717, 2020.
- BONDOIS, C.M. *Contribution a l'etude de la coccidiose intestinale du pigeon-voyageur*. 1936. Thesis (Travaux de Labratoire de Zoologie et Parasitologie) - Ecole de Medicine Lille, FR.
- DALLOUL, R.A.; LILLEHOJ, H.S. Recent advances in immunomodulation and vaccination strategies against coccidiosis. *Avian Dis.*, v.49, p.1-8, 2005.
- DAS, M.; KUMAR, R.; LAHA, R.; BHATTACHARJEE, D. Parasites of pigeons (*Columba livia domestica*) in the Hilly region of Meghalaya. *Acta Sci. Vet. Sci.*, v.4, p.27-31, 2022.
- DKHIL, M.A.; DELIC, D.; AL-QURAI SHY, S. Goblet cells and mucin related gene expression in mice infected with *Eimeria papillata*. *Sci. World J.*, v.2013, art. 439865, 2013.
- DOMMELS, Y.E.; BUTTS, C.A.; ZHU, S. *et al.* Characterization of intestinal inflammation and identification of related gene expression changes in *mdr1a(-/-)* mice. *Genes Nutr.*, v.2, p.209-223, 2007.
- DONG, H.; ZHAO, Q.; ZHU, S.; HAN, H.; HUANG, B. Prevalence of *Eimeria* infection in domestic pigeons (*Columba livia domestica*) in Shanghai, China. *J. Vet. Med. Res.*, v.5, p.1155, 2018.
- DUSZYNSKI, D.W.; SCOTT, D.T.; ARAGON, J.; LEACH, A.; PERRY, T. Six new *Eimeria* species from vespertilionid bats of North America. *J. Parasitol.*, v.85, p.496-503, 1999.
- ECKERT J.; BRAUN R.; SHIRLEY M.; COUDERT, P. *Guidelines on techniques in coccidiosis research*. Brussels, Luxembourg: European Commission, 1995.

- ELSEIFY, M.A.; METWALLY, A.M.; MAHMOUD, S.Z.; ABDELRHEEM, E.H. Prevalence of coccidia infection among domestic pigeon (*Columba livia domestica*) and quails (*Coturnix ypsilophora*) in Qena province, Southern Egypt. *Kafrelsheikh Vet. Med. J.*, v.16, p.1-21, 2018.
- GADELHAQ, S.M.; ABDELATY, A.H. The occurrence and distribution pattern of *Eimeria* species among domestic pigeons in Minia, Egypt. *J. Vet. Med. Res.*, v.26, p.164-173, 2019.
- JAMRIŠKA, J.; MODRÝ, D. A new species of *Eimeria* Schneider, 1875 (Apicomplexa, Eimeriidae) from the common wood pigeon *Columba palumbus* Linnaeus, 1758 (Aves: Columbidae). *Acta Protozool.*, v.51, p.329-333, 2012.
- JOSEPH, J.; WAMA, B.E.; AGUZIE, I.O.N.; AKWA, V.Y. Prevalence of coccidial infection in domesticated pigeon (*Columba livia domestica*) in Maiduguri Metropolis Borno State, Nigeria. *Int. J. Med. Sci.*, v.10, p.25-28, 2017.
- KASSEM, H.H.; ABD-AL JALEL, F.; BOJWARI, G.A.S.; MOHAMMED, F.F. (2018) Gastrointestinal parasites of domestic pigeons (*Columba livia domestica*) in Benghazi, Libya. *Global Sci. J. Biol.*, v.1, p.46-52, 2018.
- KIM, S.M.; LEE, S.E.; KIM, N. *et al.* Parasites of feral pigeon (*Columba livia*) by fecal examination from some areas in Seoul, Korea. *Kor. J. Vet. Serv.*, v.38, p.77-81, 2015.
- KOMMU, S.; RAJESHWARI, G.; SREENIVASAMURTHY, G.S. Prevalence of helminthic and protozoan infections in pigeons in and around Hyderabad of Telangana state. *J. Parasite Dis. Diagn. Ther.*, v.1, p.1-3, 2016.
- KRAUTWALD-JUNGHANNS, M.; ZEBISCH, R.; SCHMIDT, V. Relevance and treatment of coccidiosis in domestic pigeons (*Columba livia forma domestica*) with particular emphasis on Toltrazuril. *J. Avian Med. Surg.*, v.23, p.1-5, 2009.
- LEVINE, N.D. *Veterinary protozoology*. Ames, Iowa: Iowa State University Press, 1985. p.178-188.
- LUNA, L.G. *Manual of histologic staining methods of the Armed Forces Institute of Pathology*. 3.e. New York: McGraw-Hill, 1968.
- MAHDII, E.F.; AL-RUBAIE, H.M.A. Study the prevalence of pigeon coccidiosis in Baghdad city. *Iraqi J. Vet. Med.*, v.37, p.106-108, 2013.
- MAHMOUD, W.G.; HASSAN, E.M.; ABDEL HAFEZ, M.S. Effect of medicinal plants against intestinal coccidiosis and capillariasis infecting pigeons. *J. Egypt. Soc. Parasitol.*, v.51, p.51-54, 2021.
- MALHOTRA, M.N.; RAY, H.N. On a new coccidium, *Eimeria tropicalis* n. sp. from the domestic pigeon, *Columba livia intermedia*. *Proc. Ind. Sci. Cong.*, v.48, p.412, 1961.
- MARQUES, S.M.T.; QUADROS, R.M.; SILVA, C.J.; BALDO, M. Parasites of pigeons (*Columba livia*) in urban areas of Lages, Southern Brazil. *Parasitol. Latinoam.*, v.62, p.183-187, 2007.
- MCDUGALD, L.R. Coccidiosis. SAIF, Y.M.; BARNES, H.J.; FADLY, A.M. *et al.* (Eds.). *Poultry diseases*. Iowa, USA: Iowa State Press, 2003. p.974-991.
- MCDUGALD, L.R.; RAID, W.M. *Coccidiosis of poultry*. 9.ed. Ames: State university press, 1991. p.780-719.
- MITRA, A.N.; DAS-GUPTA, M. On a species of *Eimeria* (Coccidia-Sporozoa) from the intestine of a pigeon, *Columba intermedia*. In: INDIAN SCIENCE CONGRESS ASSOCIATION, 24., 1937, [Indian]. *Proceedings...*[s.l.]: [s.n.], 1937. (Abstr.2), p.291.
- MOHAMMED, B.R.; SIMON, M.K.; AGBEDDE, R.I.S.; ARZAI, A.H. Coccidiosis of domestic pigeons (*Columba livia domestica* Gmelin, 1789) in Kano State, Nigeria. *Ann. Parasitol.*, v.63, p.199-203, 2017.
- MOLTA, N.B.; BIU, A.A.; MOHAMMED, M.I. Prevalence of *Eimeria* species among local breeds of chicken in Maiduguri, Northeastern Nigeria. *Ann. Borno*, v.15, p.144-149, 1999.
- MORINI, E.G. La coccidiosis de la paloma. *Rev. Med. Vet. Buenos Aires*, v.32, p.207-228, 1950.
- NIESCHULZ, O. Ueber kokzidien der haustauben. *Zentralbl. Bakteriol. Mikrobiol. Hyg.*, v.134, p.390-393, 1935.
- NIESCHULZ, O.C. Ueber die entwicklung des taubencoccids *Eimeria* a *Tfifferi* (Labbe 1896). *Arch. Protistenk.*, v.51, p.479-494, 1925.

- OLIVEIRA, M.S.; RAMILO, D.W.; MELLO, E.R. *et al.* Supplementary morphological data and molecular analyses of *Eimeria labbeana* (Labbé, 1996) Pinto, 1928 (Chromista: Miozoa: Eimeriidae) from columbiform birds in Portugal. *Parasitol. Res.*, v.120, p.3569-3580, 2021.
- ORTÚZAR-FERREIRA, C.N., OLIVEIRA, M.S., GENOVEZ-OLIVEIRA, F.H.A. *et al.* Coccidia of Columbiformes: a taxonomic review of its Eimeriidae species and *Eimeria columbinae* n. sp. from *Columbina talpacoti* (Temminck, 1809) from Brazil. *Parasitol. Res.*, v.119, p.267-281, 2020.
- PARSANI, H.R.; MOMIN, R.R.; LATEEF, A.; SHAH, N.M. Gastro-intestinal helminths of pigeons (*Columba livia*) in Gujarat, India. *Egypt. J. Biol.*, v.16, p.63-71, 2014.
- PINTO, C. Synonymie de quelques especes du genre *Eimeria* (Eimeridia, Sporozoa). *C. R. Seances Soc. Biol.*, v.98, p.564-1565, 1928.
- QUDOOS, A.; IQBAL, A.; AHMAD, S.S.; KHAN, M.S.; BAYRAM, I. Effects of some alternative plant extracts used as natural coccidiostat for pigeons. *J. Anim. Sci. Prod.*, v.3, p.20-31, 2020.
- RAMESH, S.; SOUNDARARAJAN, C.; SUBAPRIYA, S.; SOKKALINGAM, R.; MUTHUKRISHNAN, S. Incidence of coccidiosis in domestic pigeons (*Columba livia*) – a case report. *Int. J. Curr. Microbiol. Appl. Sci.*, v.7, p.3698-3700, 2018.
- RAŚ-NORYŃSKA, M.; MICHALCZYK, M.; SOKÓL, R. Coccidia infections in homing pigeons of various age during the racing season. *Wiadomości Parazytol.*, v.57, p.165-168, 2011.
- SAIKIA, M., BHATTACHARJEE, K., SARMAH, P.C. *et al.* Prevalence of coccidia in domestic pigeon (*Columba livia domestica*) of Assam, India. *Int. J. Chem. Stud.*, v.5, p.453-457, 2017.
- SALGADO-MIRANDA, C.; SORANO-VARGAS, E. Identification of *Eimeria columbarum* in the Rock pigeon (*Columba livia*) from Toluca City, Mexico. *Huitzil. Rev. Mex. Ornitol.*, v.22, p.e619, 2021.
- SARI, B.; KARATEPE, B.; KARATEPE, M.; KARA, M. Parasites of domestic (*Columba livia domestica*) and wild (*Columba livia livia*) pigeons in Niğde, Turkey. *Bull. Vet. Inst. Pulawy*, v.52, p.551-554, 2008.
- SCHITO, M.L.; BARTA, J.R. Nonspecific immune responses and mechanisms of resistance to *Eimeria papillata* infections in mice. *Infect. Immun.*, v.65, p.3165-3170, 1997.
- SOOD, N.K.; SINGH, H.; KAUR, S.; KUMAR, A.; SINGH, R.S. A note on mixed coccidian and *Capillaria* infection in pigeons. *J. Parasit. Dis.*, v.42, p.39-42, 2018.
- SOULSBY, E.J.L. (1982) *Helminths, arthropods and protozoan's of domesticated animals*. 7.ed. London: Bailliere, Tindall, 1982. 809p.
- SRIVASTAVA, H.K. The morphology of the schizogonous stages of *Eimeria labbeana* Pinto 1928, a parasite of the common pigeon, *Columba livia*. *Indian J. Vet. Sci.*, v.36, p.221-256, 1966.
- STEWART, D. (1957) *Some aspects of the biology of the piogean coccidium, imeria labbeana Pinto, 1928*. 1957. Thesis (PhD) - Boston University, USA.
- TARODA, A.; BARROS, L.D.; SEIXAS, M. *et al.* First molecular detection of *Eimeria* spp. in eared doves (*Zenaida auriculata*) from Brazil. *Ciênc. Agrár.*, v.41, p.1259-1266, 2020.
- VARGHESE, T. Fine structure of the endogenous stages of *Eimeria labbeana*. 5. Schizonts and merogony, with special reference to the rhoptrymicroneme system. *J. Protozool.*, v.24, p.376-382, 1977.
- YANG, R.; BRICE, B.; ELLIOT, A.; LEE, E.; RYAN, U. Morphological and molecular characterisation of *Eimeria paludosa* coccidian parasite (Apicomplexa: Eimeriidae) in a dusky moorhen (*Gallinula tenebrosa*, Gould, 1846) in Australia. *Exp. Parasitol.*, v.147, p.16-22, 2014.
- YANG, R.; BRICE, B.; ELLIOT, A.; RYAN, U. Morphological and molecular characterization of *Eimeria labbeana*-like (Apicomplexa: Eimeriidae) in a domestic pigeon (*Columba livia domestica*, Gmelin, 1789) in Australia. *Exp. Parasitol.*, v.166, p.124-130, 2016.