

FEMORAL ANTEVERSION AND THE NECK-SHAFT ANGLE: RELATIONSHIP WITH HIP OSTEOARTHRITIS

Pedro José Labronici¹, Gabriel Novaes Pillar de Oliveira Castro², Sérgio Ricardo Neto², Hermann Costa Gomes³, Rolix Hoffmann³, Justino Nóbrega de Azevedo Neto³, José Sergio Franco⁴, Tifo Henrique de Noronha Rocha⁵, Sergio Delmonte Alves⁶

ABSTRACT

Objective: To compare the existence of agreement between measurements of anteversion of the femoral neck and the degrees of osteoarthritis and abnormality of the neck-shaft angle in patients with unilateral idiopathic hip osteoarthritis, among three evaluators. **Methods:** Forty-two patients with unilateral hip osteoarthritis were evaluated by means of simple radiography and computed tomography. **Results:** It was observed that there was no significant variation in femoral anteversion between the diseased and healthy hips. There was strongest agreement between observers 1

and 2 in relation to both the diseased hips (cases) and the healthy hips (controls). Moreover, no significant agreement was found between observers 1 and 3 ($p = 0.13$) and between observers 2 and 3 ($p = 0.12$), in relation to the neck-shaft angle of the control hips. **Conclusion:** Although there was no relationship between femoral anteversion and the neck-shaft angle in the patients with unilateral hip osteoarthritis, the present study showed that there was also no relationship with these angular deviations.

Keywords – Femoral Neck; Osteoarthritis; Hip

INTRODUCTION

Despite many investigations, the pathogenesis of primary hip osteoarthritis has still not been precisely determined. The pathogenic factors that cause joint degeneration can be divided into two categories: biological and biomechanical. These factors include: hormonal changes such as female estrogen; vascular defects, leading to cyst formation in bones; biomechanical changes, thereby overloading the joint cartilage; constitutional predisposition; and morphological abnormalities in the joint components that are not shown up through radiographic examination⁽¹⁾.

There are many studies on torsion measurements in the lower-limb bones⁽²⁻¹²⁾. Some authors have maintained the hypothesis that persistent femoral anteversion predisposes towards hip osteoarthritis^(1,7,13,16), while others have not believed this hypothesis⁽¹⁷⁻¹⁹⁾.

The aim of this study was to analyze the existence of anteversion of the femoral neck in patients with unilateral idiopathic hip osteoarthritis, by using computed tomography to compare the healthy side with the compromised side, and also to analyze the degree of osteoarthritis in relation to femoral anteversion and the cervicodiaphyseal angle.

1 - PhD in Medicine from the Federal University of São Paulo – Paulista Medical School. Head of Clinical Medicine of the “Prof. Dr. Donato D’Ângelo” Orthopedics and Traumatology Service, Hospital Santa Teresa, Petrópolis, RJ, Brazil.

2 – Resident Physician in Orthopedics and Traumatology, “Prof. Dr. Donato D’Ângelo” Orthopedics and Traumatology Service, Hospital Santa Teresa, Petrópolis, RJ, Brazil.

3 – Resident Physician in the Hip Group, “Prof. Dr. Donato D’Ângelo” Orthopedics and Traumatology Service, Hospital Santa Teresa, Petrópolis, RJ, Brazil.

4 – Adjunct Professor and Head of the Department of Orthopedics and Traumatology, School of Medicine, UFRJ, RJ, Brazil.

5 – Coordinator of Institutional Development at INTO and Orthopedist in the Pelvis and Acetabulum Group of INTO.

6 – Physician responsible for the Hip Group, “Prof. Dr. Donato D’Ângelo” Orthopedics and Traumatology Service, Hospital Santa Teresa, Petrópolis, RJ, Brazil.

Work performed at the “Prof. Dr. Donato D’Ângelo” Orthopedics and Traumatology Service, Hospital Santa Teresa, Petrópolis, RJ, and at the Petrópolis School of Medicine, Petrópolis, RJ, Brazil.

Correspondence: Av. Roberto Silveira 187 - apto 601 - 25685-040 - Petrópolis, RJ. E-mail: plabronici@globo.com

Work received for publication: July 2, 2010; accepted for publication: November 3, 2010

METHODS

Between January 2008 and February 2010, 42 patients with unilateral hip osteoarthritis were assessed at Hospital Santa Teresa, Petrópolis. Patients with metabolic diseases, sequelae of trauma or infection, rheumatic diseases, avascular necrosis and bilateral osteoarthritis were excluded. Twenty-seven female patients and fifteen male patients were assessed. Their ages ranged from 89 to 42 years, with a mean of 69.7 years. Twenty patients presented osteoarthritis on the right side and 22 on the left side.

The patients were evaluated by three orthopedists separately. Radiographs in anteroposterior view were used to analyze the degree of osteoarthritis using the classification system developed by Busse et al⁽²⁰⁾, on a scale divided from 0 to 3, and to evaluate the cervicodiaphyseal angle (Box 1). Computed tomography scans were analyzed using the method of Jeanmart et al⁽²¹⁾, to evaluate the femoral rotation, from slices through the proximal region of the femur and the femoral condyles. The difference in the torsion angle between the diseased side and the healthy side determined the rotational deformity (Figure 1A and B). Patients with a difference in torsion angle greater than or equal to 15° were considered to have a true rotational deformity.

Table 1 presents the profile of the sample of 42 patients in this study. The presence of angular deformity (femoral anteversion) was based on the differences between the hips (diseased and healthy) and the bilateral femoral condyles, by means of computed tomography.

For consultation purposes, Table 2 provides a description of the degree of arthrosis according to the evaluators.

Box 1 – Osteoarthritis grades according to Busse et al.

Grade	Characteristics
0	Absence of signs of osteoarthritis
1	Slight narrowing of the joint space, small marginal osteophytosis and slight sclerosis of the femoral head or acetabulum
2	Small cysts in the femoral head or acetabulum, increased narrowing of the joint space, moderate loss of sphericity of the femoral head
3	Large cysts, severe narrowing or obliteration of the joint space, severe deformation of the femoral head, avascular necrosis

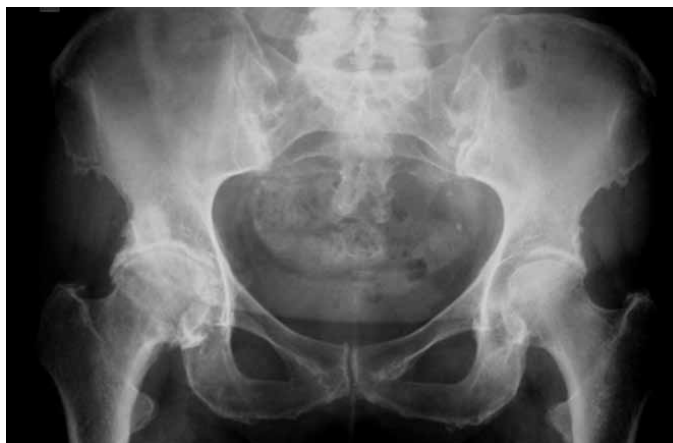

Figure 1A – AP radiograph showing arthrosis in the right femoral coxa.

Table 1 – General description of the sample of 42 patients.

Variable	Category	n	%
Sex	Male	15	35.7
	Female	27	64.3
Diseased side	Right	20	47.6
	Left	22	52.4
Angular deformity (evaluator 1)	Present	2	4.8
	Absent	40	95.2
Angular deformity (evaluator 2)	Present	5	11.9
	Absent	37	88.1
Angular deformity (evaluator 3)	Present	0	0
	Absent	42	100
Age – mean ± SD (median)		69.7 ± 12.0 (71 years)	

SD: standard deviation

Source: Hospital Santa Teresa, Petrópolis, RJ

Table 2 – Degree of arthrosis according to the evaluators.

	Category	n	%
Evaluator 1	Grade I	7	16.7
	Grade II	16	38.1
	Grade III	19	45.2
Evaluator 2	Grade I	7	16.7
	Grade II	13	31.0
	Grade III	22	52.3
Evaluator 3	Grade I	1	2.4
	Grade II	15	35.7
	Grade III	26	61.9

Source: Hospital Santa Teresa, Petrópolis, RJ

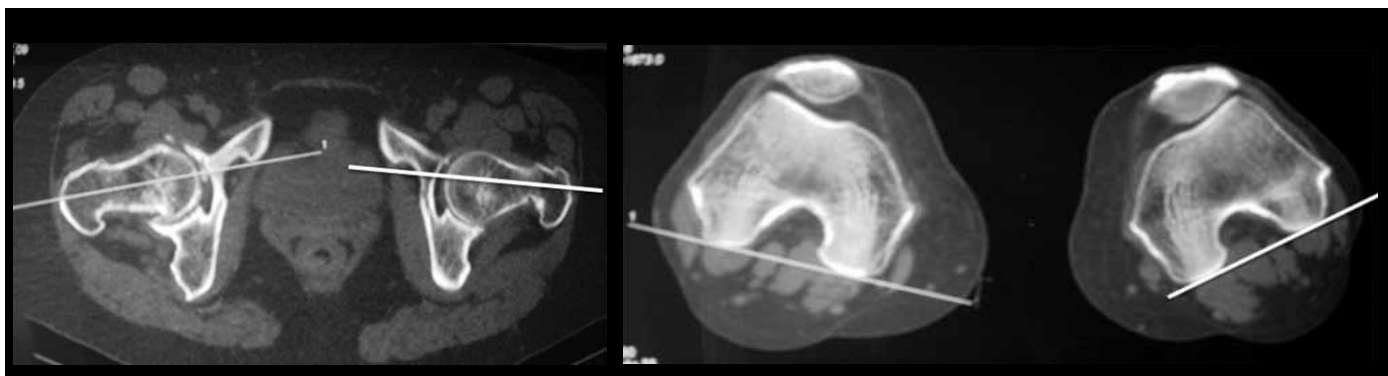


Figure 1B – Computed tomography of the coxofemoral joint and bilateral femoral condyle, with the respective measures.

STATISTICAL EVALUATION

The statistical analysis was composed of the following methods:

- concordance between the observers regarding the measurements of the cervicodiaphyseal angle (CDA) and anteversion of the femoral neck, using computed tomography (CT); this was assessed using the intraclass correlation coefficient (ICC)⁽¹⁾;
- investigation of whether there might be any significant variation in the CDA, on CT, between the diseased hip and the healthy hip; this was done using the Wilcoxon signed rank test;
- investigation of whether there might be any significant difference in the CDA of the diseased hip, between the degrees of arthrosis (I, II and III); this was done by applying the Kruskal-Wallis ANOVA.

Nonparametric methods were used, since the variables did not present normal distribution (Gaussian distribution). The criterion used for determining the significance was the level of 5%. The statistical analysis was processed using the SAS[®] System statistical software.

RESULTS

Our objective was to observe, from analysis on computed tomography, whether there would be concordance between three evaluators in making measurements on the anteversion of the femoral neck (AFN) in the diseased hip (case) and the healthy hip (control), the cervicodiaphyseal angle (CDA) and the relationship with the degree of hip arthrosis.

The interobserver reliability was evaluated by

means of the intraclass correlation coefficient (ICC), which showed that there was significant concordance in the CDA and AFN measurements between the three evaluators. The closer to one (1) that the ICC is, the stronger (or more perfect) the concordance between the observers is. In this case, the observers were similar in numerical terms (quantitative). On the other hand, the closer to zero (0) that the coefficient is, the greater the discordance is, i.e. the measurements would not be reproduced and the differences observed would not be random (0).

Through various studies and simulations, the following can be said:

- ICC \leq 0.20 \rightarrow no concordance
- 0.20 < ICC \leq 0.40 \rightarrow weak concordance
- 0.40 < ICC \leq 0.60 \rightarrow moderate concordance
- 0.60 < ICC \leq 0.80 \rightarrow good concordance
- ICC > 0.80 \rightarrow very good (excellent) concordance

Tables 3 and 4 present the intraclass correlation coefficients (ICC) and their respective descriptive levels (p) for each pair of observers, for CDA and AFN, respectively, in relation to the 42 patients in the study.

It was observed that there was significant concordance between the observers with $p \leq 0.05$. We can say that the strongest concordance (moderate) was between observers 1 and 2, both for the diseased hip (case) and for the healthy hip (control). We can also highlight that there was no significant concordance between observers 1 and 3 ($p = 0.13$) or between 2 and 3 ($p = 0.12$) for the CDA of the control hip.

It was found that there was significant concordance between the observers with $p \leq 0.05$. We can say that the strongest concordance (excellent) was between observers 1 and 2, both for the diseased hip (case) and

Table 3 – ICC for the CDA of the case and control hips.

Variable	Concordance	ICC	p
CDA – case	Obs 1 x Obs 2	0.570	< 0.001
	Obs 1 x Obs 3	0.318	0.012
	Obs 2 x Obs 3	0.411	0.002
CDA – control	Obs 1 x Obs 2	0.576	< 0.001
	Obs 1 x Obs 3	0.148	0.13
	Obs 2 x Obs 3	0.153	0.12

ICC: intraclass correlation coefficient
Source: Hospital Santa Teresa, Petrópolis, RJ

Table 4 – ICC for the AFN of the case and control hips.

Variable	Concordance	ICC	p
AFN – case	Obs 1 x Obs 2	0.934	< 0.001
	Obs 1 x Obs 3	0.492	< 0.001
	Obs 2 x Obs 3	0.550	< 0.001
AFN – control	Obs 1 x Obs 2	0.892	< 0.001
	Obs 1 x Obs 3	0.875	< 0.001
	Obs 2 x Obs 3	0.804	< 0.001

ICC: intraclass correlation coefficient
Source: Hospital Santa Teresa, Petrópolis, RJ

for the healthy hip (control). We can also highlight that the concordance observed for the AFN was much better than the concordance for the CDA.

Tables 5, 6 and 7 present the mean, standard deviation or standard error (SD/SE), median, minimum and maximum for the AFN of the diseased hip (case) and healthy hip (control), the corresponding absolute variation (delta) and the respective descriptive level (p) of the Wilcoxon signed rank test for evaluators 1, 2 and 3, respectively.

The absolute variation in the AFN of the diseased hip to the healthy hip was given by the formula:

DELTA AFN = (AFN of the case hip – AFN of the control hip).

It was observed that there was no significant variation in the AFN, with a mean of 2.05 units ($p = 0.22$) of the diseased hip to the healthy hip, according to evaluator 1.

It was observed that there was no significant variation in the AFN, with a mean of 0.26 units ($p = 0.68$) of the diseased hip to the healthy hip, according to evaluator 2.

Table 5 – Analysis on the AFN for evaluator 1.

Variable	Mean	SD/SE	Median	Minimum	Maximum	p
AFN for cases	12.2	9.4	11	0	50	
AFN for controls	10.2	7.3	10	0	30	
Delta AFN	2.05	1.47	1	-19	46	0.22

SD: standard deviation; SE: standard error only for delta.
Source: Hospital Santa Teresa, Petrópolis, RJ

Table 6 – Analysis on the AFN for evaluator 2.

Variable	Mean	SD/SE	Median	Minimum	Maximum	p
AFN for cases	11.9	9.2	11	0	44	
AFN for controls	11.6	8.2	12	0	30	
Delta AFN	0.26	1.50	-2	-16	40	0.68

SD: standard deviation; SE: standard error only for delta.
Source: Hospital Santa Teresa, Petrópolis, RJ

Table 7 – Analysis on the AFN for evaluator 3.

Variable	Mean	SD/SE	Median	Minimum	Maximum	p
AFN for cases	11,0	7,8	10	0	32	
AFN for controls	10,5	7,3	10	0	28	
Delta AFN	0,55	0,50	0	-10	12	0,15

SD: standard deviation; SE: standard error only for delta.
Source: Hospital Santa Teresa, Petrópolis, RJ

It was found that there was no significant variation in the AFN, with a mean of 0.55 units ($p = 0.15$) of the diseased hip to the healthy hip, according to evaluator 3.

Another objective was to investigate whether there was any difference in the CDA of the diseased hip (case) in relation to the degrees of arthrosis (I, II and III).

Table 8 shows the mean, standard deviation (SD), median, minimum and maximum of the CDA of the diseased hip (case) according to the degree of arthrosis (I, II or III) and the descriptive level (p) of the Kruskal-Wallis ANOVA.

It was observed that there was no significant difference in CDA in the diseased hip (case) between the degrees of arthrosis, for evaluator 1 ($p = 0.22$), evaluator 2 ($p = 0.23$) and evaluator 3 ($p = 0.74$).

Table 8 – Analysis on the CDA of the diseased hip (case) according to the degree of arthrosis.

Variable	Arthrosis	n	Mean	SD	Median	Minimum	Maximum	p
CDA for cases (evaluator 1)	Grade I	7	127.9	6.4	128	118	138	0,22
	Grade II	16	126.5	4.5	126	120	132	
	Grade III	19	130.3	8.0	130	112	148	
CDA for cases (evaluator 2)	Grade I	7	128.4	5.3	128	122	135	0,23
	Grade II	16	129.1	6.1	130	110	138	
	Grade III	19	131.8	4.7	132	122	140	
CDA for cases (evaluator 3)	Grade I	7	128.6	3.4	128	122	132	0,74
	Grade II	16	128.5	5.9	130	112	138	
	Grade III	19	129.4	5.2	130	120	136	

SD: standard deviation

Source: Hospital Santa Teresa, Petrópolis, RJ

DISCUSSION

Anteversion is an anterior component of the cervicodiaphyseal angle. This angle is oriented to a position that provides greater advantage for resisting the forces that act on the joint, and it also enables a mechanical influence to allow a large joint range of motion⁽¹¹⁾.

To analyze rotational deformity, computed tomography has been shown to be an effective method. Several studies have demonstrated the influence of femoral anteversion on the development of hip osteoarthritis. Reikeras et al⁽⁷⁾ showed that anteversion of the femoral neck may be a predisposing factor because of difficulty in adapting the femoral head to the acetabulum. They also raised the hypothesis that increased anteversion may be secondary to the degenerative process of osteoarthritis. However, they observed when they made measurements on older patients, who theoretically would have had the disease for a longer time, that these individuals did not present a rotational difference, compared with younger patients. Halpern et al⁽¹⁶⁾ observed that despite a gait of normal appearance, the compensatory external rotation would contribute towards abnormal rotation of the femoral head in the acetabulum and could be one of the factors leading later on to the development of osteoarthritis. Although several authors have reported that persistence of femoral anteversion might predispose towards development of osteoarthritis^(1,7,13-16), it was observed in the present study that there was no significant difference between the diseased and

healthy hips in the patients with unilateral hip osteoarthritis, from analysis of computed tomography scans (our study was based on the presumption of femoral anteversion of up to 15°). These parameters were reinforced when the criterion of absolute variation (delta) was used, thus suggesting that this deformity may not be the only factor predisposing towards osteoarthritis.

The anteversion angle is not an isolated entity. It is intrinsically related to the cervicodiaphyseal angle, in varus or valgus variations⁽¹¹⁾. Mills et al⁽²²⁾ analyzed radiographs to investigate the anatomy of the hip and the degree of osteoarthritis. They observed that there were a large number of patients with an increased cervicodiaphyseal angle. Laforgia et al⁽²³⁾ observed that there was a direct correlation between hip osteoarthritis and, among other variables, greater cervicodiaphyseal angle. Doherty et al⁽²⁴⁾ observed that greater predominance of the pistol grip deformity with higher cervicodiaphyseal angles in patients with unilateral osteoarthritis could cause hip osteoarthritis. However, a non-spherical femoral head and increased cervicodiaphyseal angle could occur as consequences of osteoarthritis. From an evaluation on 44 patients with unilateral and bilateral hip osteoarthritis, Reikeras and Hoiseth⁽¹³⁾ did not find any difference regarding the cervicodiaphyseal angle. The present study confirmed that, comparing the diseased hip with the healthy side of patients with osteoarthritis, there was no difference in relation to changes to the cervicodiaphyseal angle.

Giunti et al⁽¹⁾ observed that the anteversion angle was significantly greater in the group with osteoarthritis than in the control group, and that the increase was also proportional to the severity of the arthrosis. We also analyzed the relationship between the cervicodiaphyseal angle and the degree of osteoarthritis, and we observed that there was no significant difference in the cervicodiaphyseal angle of the diseased hip (case) and the healthy hip (control), or between the degrees of arthrosis.

CONCLUSION

In analyzing patients with unilateral hip osteoarthritis, this study demonstrated that there was no relationship between the femoral anteversion, cervicodiaphyseal angle and degree of osteoarthritis.

REFERENCES

- Giunti A, Moroni A, Olmi R, Rimondi E, Soldati D, Vicenzi G. The importance of the angle of anteversion in the development of arthritis of the hip. *Ital J Orthop Traumatol*. 1985;11(1):23-7.
- Abel MF, Sutherland DH, Wenger DR, Mubarak SJ. Evaluation of CT scans and 3-D reformatted images for quantitative assessment of the hip. *J Pediatr Orthop*. 1994;14(1):48-53.
- Browning WH, Rosenkrantz H, Tarquinio T. Computed tomography in congenital hip dislocation. The role of acetabular anteversion. *J Bone Joint Surg Am*. 1982;64(1):27-31.
- Chevrot A, Hazebroucq V, Vallée C, Godefroy D, Wybier M, Codert E, et al. [A criterion of validity of the x-ray computed tomographic measurement of femoral neck anteversion]. *Rev Chir Orthop Reparatrice Appar Mot*. 1991;77(5):370-3.
- Murphy SB, Simon SR, Kijewski PK, Wilkinson RH, Griscom NT. Femoral anteversion. *J. Bone Joint Surg Am*. 1987;69(8):1169-76.
- Murray DW. The definition and measurement of acetabular orientation. *J Bone Joint Surg Br*. 1993;75(2):228-32.
- Reikerås O, Bjerkreim I, Kolbenstvedt A. Anteversion of the acetabulum and femoral neck in normals and in patients with osteoarthritis of the hip. *Acta Orthop Scand*. 1983;54(1):18-23.
- Weiner DS, Cook AJ, Hoyt WA Jr, Oravec CE. Computed tomography in the measurement of femoral anteversion. *Orthopedics*. 1978;1(4):299-306.
- Weiner LS, Kelley MA, Ulin RI, Wallach D. Development of the acetabulum and hip: computed tomography analysis of the axial plane. *J Pediatr Orthop*. 1993;13(4):421-5.
- Tönnis D, Heinecke A. Acetabular and femoral anteversion: relationship with osteoarthritis of the hip. *J Bone Joint Surg Am*. 1999;81(12):1747-70.
- Tayton E. Femoral anteversion: a necessary angle or an evolutionary vestige? *J Bone Joint Surg Br*. 2007;89(10):1283-8.
- Maruyama M, Feinberg JR, Capello WN, D'Antonio JA. The Frank Stinchfield Award: Morphologic features of the acetabulum and femur: anteversion angle and implant positioning. *Clin Orthop Relat Res*. 2001;(393):52-65.
- Reikerås O, Høiseith A. Femoral neck angles in osteoarthritis of the hip. *Acta Orthop Scand*. 1982;53(5):781-4.
- Terjesen T, Benum P, Anda S, Svenningsen S. Increased femoral anteversion and osteoarthritis of the hip joint. *Acta Orthop Scand*. 1982;53(4):571-5.
- Wedge JH, Munkacsi I, Loback D. Anteversion of the femur and idiopathic osteoarthritis of the hip. *J Bone Joint Surg Am*. 1989;71(7):1040-3.
- Halpern AA, Tanner J, Rinsky L. Does persistent fetal femoral anteversion contribute to osteoarthritis?: a preliminary report. *Clin Orthop Relat Res*. 1979;(145):213-6.
- Hubbard DD, Staheli LT, Chew DE, Mosca VS. Medial femoral torsion and osteoarthritis. *J Pediatr Orthop*. 1988;8(5):540-2.
- Kitaoka HB, Weiner DS, Cook AJ, Hoyt WA Jr, Askew MJ. Relationship between femoral anteversion and osteoarthritis of the hip. *J Pediatr Orthop*. 1989;9(4):396-404.
- Swanson AB, Greene PW Jr, Allis HD. Rotational deformities of the lower extremity in children and their clinical significance. *Clin Orthop Relat Res*. 1963;27:157-75.
- Busse J, Gasteiger W, Tönnis D. [A new method for roentgenologic evaluation of the hip joint—the hip factor]. *Arch Orthop Unfallchir*. 1972;72(1):1-9.
- Jeanmart L, Baert AL, Wackenheim A. Computer tomography of neck, chest, spine and limbs. In: *Atlas of pathologic computer tomography*. New York: Springer-Verlag; 1983. p. 171-7.
- Mills HJ, Horne JG, Purdie GL. The relationship between proximal femoral anatomy and osteoarthritis of the hip. *Clin Orthop Relat Res*. 1993;(288):205-8.
- Laforgia R, Specchiulli F, Solarino G, Nitti L. Radiographic variables in normal and osteoarthritic hips. *Bull Hosp Jt Dis*. 1996;54(4):215-21.
- Doherty M, Courtney P, Doherty S, Jenkins W, Maciewicz RA, Muir K, et al. Nonspherical femoral head shape (pistol grip deformity), neck shaft angle, and risk of hip osteoarthritis: a case-control study. *Arthritis Rheum*. 2008;58(10):3172-82.