



RBO
REVISTA BRASILEIRA DE ORTOPEDIA

www.rbo.org.br/



Review Article

Child abuse: review of the literature

Bernardo Barcellos Terra,^{1*} Eduardo Antônio de Figueiredo,²
Morena Pretti Espindula de Oliveira Lima Terra,³ Carlos Vicente Andreoli,⁴ Benno Ejnisman⁵

¹Physician and Titular Member of the Shoulder and Elbow Society, Shoulder and Elbow Group, Medical School, Santa Casa de Misericórdia de Vitória ES (EMESCAM), Vitória, ES, Brazil.

²Physician and Titular Member of the Brazilian Shoulder and Elbow Society, Shoulder and Elbow Group, Sports Traumatology Center, Universidade Federal de São Paulo, São Paulo, SP, Brazil.

³Titular Member of the Brazilian Pediatric Society.

⁴PhD in Orthopedics. Head of the Sports Traumatology Center, Universidade Federal de São Paulo, São Paulo, SP, Brazil.

⁵PhD in Orthopedics. Head of the Shoulder and Elbow Group, Sports Traumatology Center, Universidade Federal de São Paulo, São Paulo, SP, Brazil.

Work performed in the Department of Orthopedics and Traumatology, Universidade Federal de São Paulo (DOT-Unifesp/EPM), São Paulo, SP, Brazil.

ARTICLE INFO

Article history:

Received December 03 de 2011

Approved March 12 2012

Keywords:

Femoral fractures

Humeral fracture

Child abuse

A B S T R A C T

Non-accidental injuries in children are an important cause of morbidity and mortality in this population. Fractures are the second most common clinical manifestation of child abuse. The fracture of the femur is associated in more than 60% of child abuse in children younger than 3 years. The objective was to review the literature on child abuse in the major databases and report a rare case of bilateral subtrochanteric femur fractures associated with unilateral humeral fracture in a 28-day newborn. The orthopedic surgeon is often the first physician to evaluate these children, so a high degree of suspicion, and a physical examination and a detailed clinical history is mandatory when evaluating a newborn with musculoskeletal injuries.

© 2013 Sociedade Brasileira de Ortopedia e Traumatologia. Published by Elsevier Editora Ltda. All rights reserved.

* Corresponding author at: Rua Borges Lagoa, 783, 5. andar, Vila Clementino, São Paulo, SP, CEP: 04038-032. Universidade Federal de São Paulo.

E-mail: bernardomed@hotmail.com

Introduction

Greater raising of awareness of child abuse has contributed towards better understanding of this complex problem. It has been estimated that the annual incidence of abuse is between 15 and 40 cases per 1,000 children. Thus, approximately one million children become victims every year and more than 1,200 die as a result of abuse.¹

Despite the severity of the problem, it is highly prevalent. In a systematic review on 32 studies, Kemp et al.^{2,3} concluded that abuse was more common among children under the age of three years, and that multiple fractures were also more common among children who suffered abuse.

In Brazil, no data on the incidence of child abuse has been established. However, according to Ruaro et al.,⁴ recent studies show that among every 1,000 children, ten are victims of abuse and that of these, 2% to 3% die. Thus, the incidence of mortality is similar to that due to leukemia. The literature on abuse among newborns is sparse and there are few studies on children under the age of one year.

Fractures are the second commonest presentation of this condition and orthopedists are often the first physician to evaluate these children.⁵ The objectives of this study were to conduct a review of the literature on this topic and report on a case, never previously reported in the literature, of a 27-day-old newborn who was a victim of abuse, with bilateral subtrochanteric femoral fractures and a unilateral humeral fracture, and to conduct a review of the literature on this topic.

Method

An investigation was conducted in the main databases (Lilacs, Pubmed and Embase) using the following descriptors: non-accidental injury, child abuse, child neglect, femoral fractures and humeral fractures.

The inclusion criteria were that the article needed to have been published within the last 12 years, in the Portuguese, English or Spanish languages, or that they were regarded as classic studies on the topic. Systematic reviews with and without meta-analyses were also included. Studies that did not fulfill these criteria were automatically excluded.

Results

The initial search found 70 studies, which were selected according to their title, in order to read the abstracts. From this reading, 23 studies that met the inclusion criteria were selected for reading in full and for discussion of the proposed objective.

Case report

A 27-day-old newborn was admitted to hospital accompanied by a young mother of 16 years of age, with a history of fever associated with productive coughing, and without any other disorders, according to the mother's report. The case was initially attended by the pediatrics team, who diagnosed pneumonia with criteria of respiratory insufficiency. The newborn was hospitalized and received antibiotic therapy in association with noninvasive ventilatory support. In talking with the mother, it could be seen that she was giving a confused story, without causal links and inconsistent with the patient's clinical condition. At this time during the consultation, the mother denied that the child had suffered any traumatic event, alleging that she had been close to the child at all times. The hospital's social assistance team was put into action and, concomitantly, the guardianship council.

On the fourth day of hospitalization, the orthopedic team was asked to provide an interdisciplinary consultation regarding the child's case, because of bilateral edema on the thighs and because the child was crying a lot if its legs were manipulated.

After detailed orthopedic examination, with imaging examinations, it was determined that the child presented bilateral subtrochanteric femoral fractures associated with a unilateral humeral fracture in the left arm (Figs. 1 and 2), without any neurological and vascular deficits in the limbs. There were no cutaneous and/or ocular lesions. On this day, the mother reported that the child had fallen to the floor in the bathroom and its legs had hit the edge of the bath, thus contradicting her story at the time of hospital admission. The father had not been located.

A small plaster-cast splint was immediately applied to the left arm, extending from the axilla to the palm, and bilateral skin traction was applied to the legs, since the pediatric team asked for any procedure under anesthesia at that moment

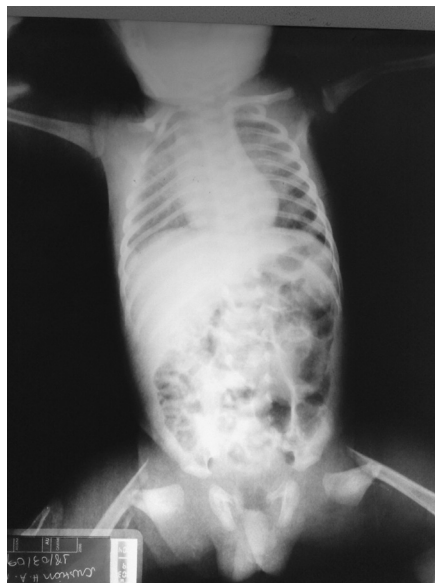

Fig. 1 - Radiograph at the time of admission.

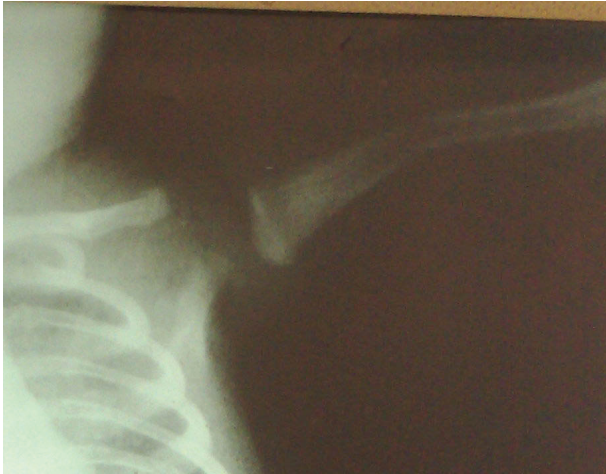

Fig. 2 - Humeral fracture at the time of admission.

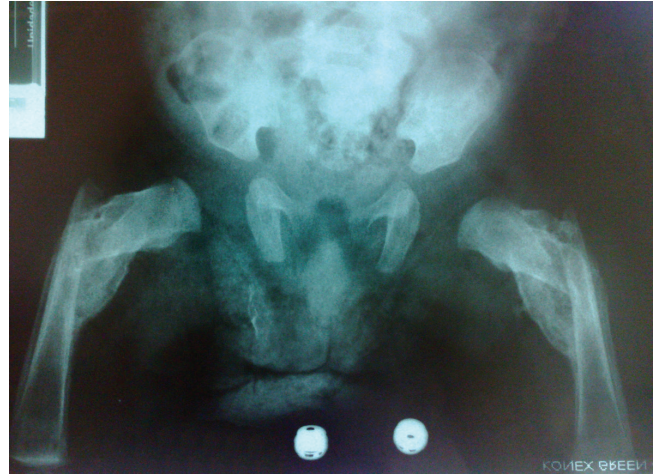

Fig. 4 - Radiograph of the femurs at the age of three weeks.

to be postponed until the child's infectious and respiratory conditions had stabilized.

Over this period, serum samples were collected for tests and metabolic and congenital diseases were investigated. All pathological conditions that form differential diagnoses with child abuse, such as osteogenesis imperfecta, were ruled out.

On the seventh day of hospital stay, the child was subjected to bilateral plaster-cast immobilization from the chest to the malleolus, under sedation and analgesia, in the surgical center.

The child was kept immobilized in the plaster cast for three weeks. The femoral and humeral immobilizations were removed when it was seen that there was no longer any crepitation at the foci of the fractures and a voluminous bone callus had formed bilaterally in the femurs and in the humerus (Figs. 3 and 4). At this time, the patient was no longer on antibiotic therapy and presented normal pulmonary functions.

The child remained hospitalized for a further week, because of the social problems and then, after release, was taken to a shelter institution for children abandoned by their parents.

The child was brought to the outpatient clinic in the second, fourth and sixth months (Figs. 5, 6, 7 and 8), for follow-up

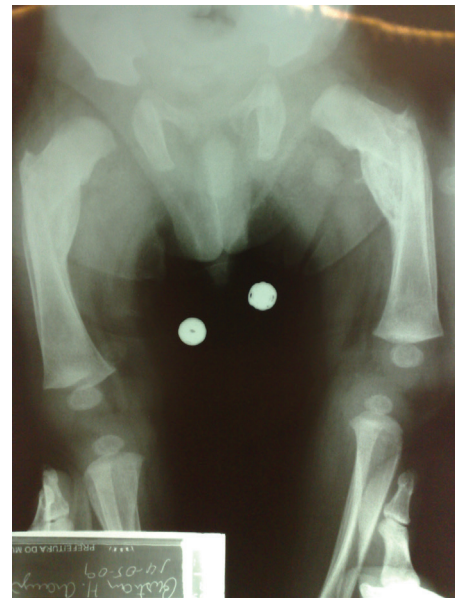

Fig. 5 - Radiograph at the age of two months.

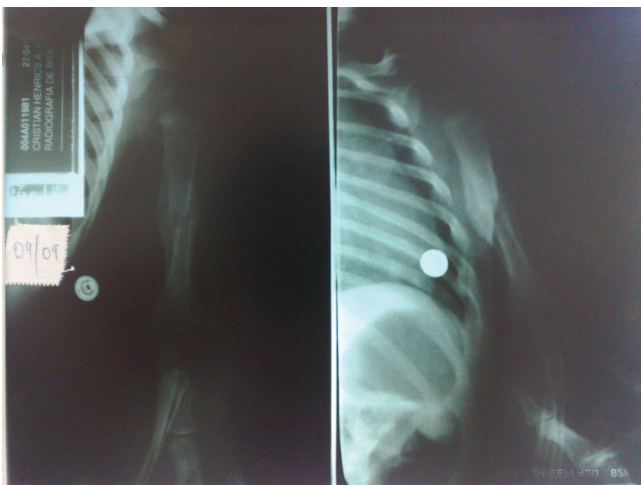


Fig. 3 - Radiograph of the arm at the age of three weeks.

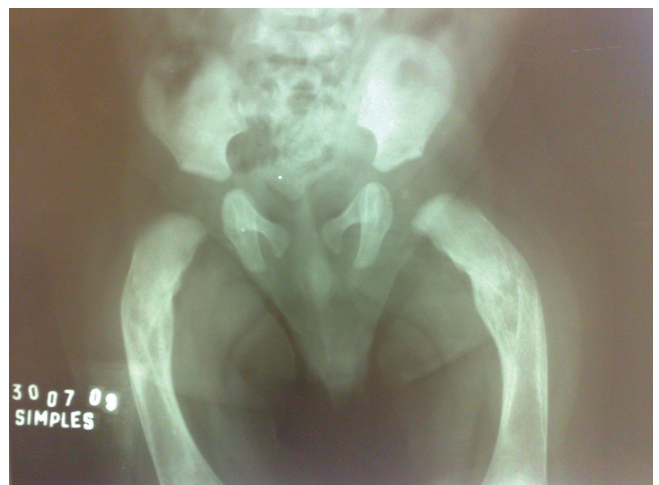

Fig. 6 - Radiograph at the age of four months.

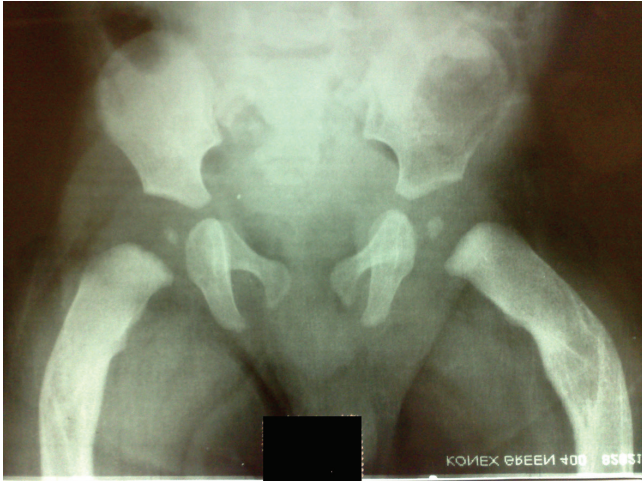

Fig. 7 - Radiograph of the proximal femur at the age of six months.

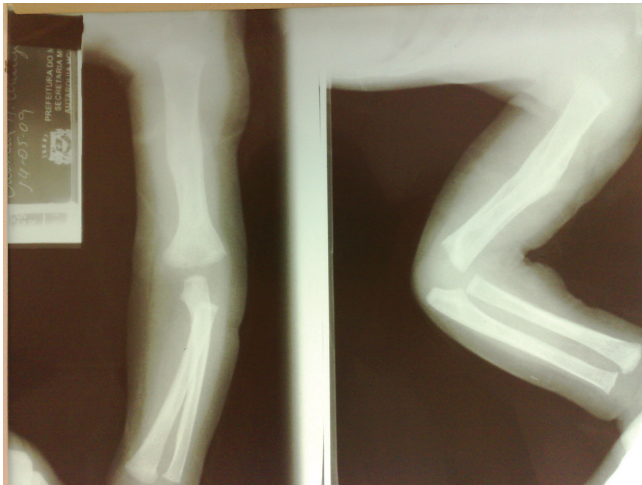

Fig. 8 - Radiograph of the humerus at the age of six months.

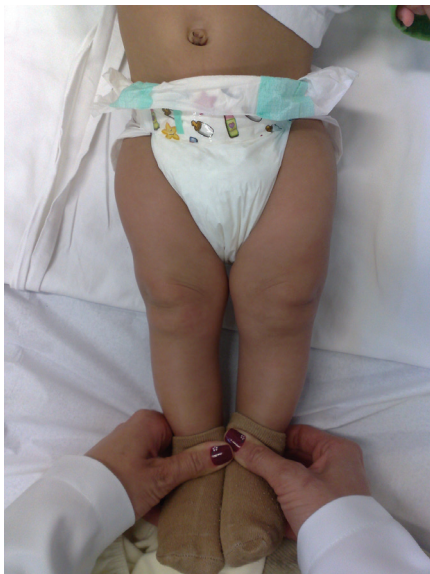

Fig. 9 - Photograph at the age of six months, showing absence of anisomelia or significant deformities.

consultations, through which it could be seen that the child was completely healthy, without anisomelia and/or associated deformities (Fig. 9). From control radiographs, satisfactory evolution of both the femoral and humeral bone consolidation was observed.

Currently, the legal procedures for guardianship of the child are underway and a court hearing to decide on guardianship is awaited.

Discussion

In 1946, Caffey^{6,7} described an association between subdural hematomas and fractures of long bones in infants. In a subsequent report, he confirmed that this process was due to physical abuse. In 1961, the American Academy of Pediatrics established the expression “battered child”, defined as a child who had suffered non-accidental injuries as a result of attitudes or omissions by its parents or other adults responsible for the child.⁸ Legally, children are considered to be individuals up to but not completing 12 years of age and adolescents are considered to be between 12 and 18 years of age.⁹

Child abuse can be defined as any action or omission by the adult caregiver or older adolescent that might result in damage to the child’s physical, emotional, intellectual, moral or social development of the child or adolescent. It can be classified into four types: physical, emotional (psychological), sexual and neglectful (negligence through omission or abandonment).¹⁰ In 2001, the Brazilian Ministry of Health determined that notification of any form of violence against children and adolescents would be mandatory for all healthcare professionals, and that failure to do so would render the healthcare professional liable to a fine of three to twenty reference salaries, with doubling of the fine in the event of recurrence.⁹ It should be emphasized that in these cases the defense of violation of the duty of confidentiality resulting from professional practice would be inapplicable, since this would be communication required by law.⁴

Fractures are the second largest form of presentation after skin lesions, and approximately one third of these presentations are seen by orthopedists at the initial consultation.¹¹ The pattern of non-accidental injuries consists mainly of metaphyseal lesions, multiple fractures at different stages of consolidation, fractures of posterior ribs and fractures of long bones in children under the age of two years.¹²

Fractures of the long bones in very young children may represent one of the main pieces of evidence of physical abuse.¹³ Femoral fractures are associated with abuse syndrome in 60% of the cases affected children under the age of three years¹¹ and up to 85% among children under the age of one year.^{14,15} Bergamaschi et al.¹⁶ studied 35 cases of children under the age of three years who had suffered diaphyseal fractures of the femur. In 50% of the children reassessed, there were indications of physical abuse and negligence, such as triggering of femoral fractures. Anderson reported rates of suspected abuse of 79% and 83% among children under the ages of two years and 13 months, respectively, when femoral fractures were present.¹⁷ In the present case, the infant was 27 days of age on admission to

hospital, which led us to have a high degree of suspicion and diagnostic certainty of close to 100%.

The signs suggestive of child abuse include the presence of multiple acute lesions (ecchymosis, hematoma, excoriation, bites, burns and edema of soft tissues), previous history of abuse, subdural hematoma, behavioral alterations, presence of multiple fractures (especially in the femur, tibia and humerus) and/or fractures at various stages of healing. However, fractures alone frequently occur.¹⁸ In the case reported here, the newborn presented multiple fractures, but all of them were in the acute phase and there were no skin lesions or subdural hematomas.

According to Pfeiffer, a clinical history or physical examination demonstrating signs of frequent lesions that are said to be accidental and an unexplainable delay between the "accident" and seeking medical care are general signs suggestive of physical abuse.¹⁹ In our case, the mother only sought medical care because of the condition of respiratory insufficiency and fever that the child presented, which led us to believe that the trauma had occurred some days before the time of hospital admission.

Dalton et al.¹¹ showed that orthopedists are the main investigators (in absolute numbers) of physical abuse among children with femoral fractures, followed by pediatricians. In the present case, the newborn was initially attended by a pediatrician because of the respiratory condition and secondarily by an orthopedist, who diagnosed the fractures that led to the suspicion of abuse.

Pandya et al.^{5,10} studied 1,485 children who were victims of abuse or accidental trauma. They came to the conclusion that patients under the age of 18 months who presented fractures of the ribs, tibia, humerus or femur were more likely to have suffered abuse, while those over the age of 18 months with fractures of the long bones (femur and humerus) presented greater likelihood of having suffered accidental trauma. Lane et al.²⁰ reported that black children had higher rates of non-accidental lesions than did white children of the same age group, but also reported that those children were more likely to be evaluated and registered due to suspicion of abuse, thus showing that ethnic difference exist in assessment and communication of pediatric fractures due to child abuse.²⁰ In the case presented here, the mother and the newborn were not black.

In a systematic review on 32 studies, Kemp et al.²¹ concluded that fractures resulting from abuse were more common among children under the age of three years, and that multiple fractures were also more common in the group of children who had suffered abuse. They reported that fractured ribs were most likely to result from child abuse (0.71, with 95% CI of 0.42 to 0.91), and that the likelihood of humeral fractures resulting from abuse was 0.54 (0.20 to 0.88) and that of femoral fractures was 0.43 (0.32 to 0.54). They came to the conclusion that during evaluations on individual fractures, the site, the type of fracture and the child's developmental stage could help in diagnosing abuse.

Gholve et al.²² reported on a rare case of femoral neck fracture in a three-year-old girl. They stated that these fractures account for 46% of the fractures of the proximal femur, but

that they account for only 1% of the fractures in children. Jones et al.¹² reported on two cases of growth plate lesions in the proximal femur, in children who had been victims of abuse, and they drew attention to the need to think of the possibility that these lesions could be a consequence of abuse, despite the diagnostic difficulties, given that the center of ossification of the femoral head appears at the age of four months. Thus, this type of fracture in this age group should signal that this lesion is not accidental, as in our case.

In diagnosing battered child syndrome, physicians need to be cautious and make differential diagnoses, particularly with the following pathological conditions: osteogenesis imperfecta, congenital insensitivity to pain, scurvy, congenital syphilis, Caffey's disease, multiple fractures of severe rickets, hypophosphatemia, leukemia, metatarsal neuroblastoma, sequelae of osteomyelitis and septic arthritis.^{3,18,23-25} In the case presented here, all of the abovementioned possibilities were ruled out.

Prasad et al.²⁶ demonstrated that children who were victims of abuse presented worse cognitive function and deficits in motor skills, expression and language reception during their growth. Healthcare professionals therefore have a social commitment towards detecting and notifying suspected cases of child abuse, and should be prepared to identify it. The case presented here has only evolved for 18 months, but apparently does not present any developmental deficit.

Puerperal psychosis is a state of delirium that is frequently hallucinatory, severe and acute. It appears between the second day after delivery and three months afterwards, at the frequency of one or two deliveries in every 1,000, and more often affects primiparous and single mothers. This psychosis does not present any relationship with the mother's age or with her color.²⁷ In the present case, the mother was within the period of occurrence of puerperal psychosis; the child was her first and the father was not present. The mother was sent to the hospital's psychiatry department for investigation and possible treatment.

It is known that approximately 50% of the children who are victims of physical abuse who return home are subsequently beaten again. Of these, 20% end up dying. Therefore, there needs to be a high degree of suspicion in attending children with fractures or skin lesions that are poorly explained by the trauma mechanism, like in the present case report, given that there is no pathognomonic fracture in child abuse cases.²⁰ Physicians who suspect that a case is one of child abuse should immediately communicate this to one of the following three bodies: the guardianship council, a police station or the public attorney's office. All of these institutions have the duty to safeguard and defend the rights of children and juveniles.

Conclusion

Child abuse should always be borne in mind as a differential diagnosis among children who present fractures that are poorly explained by trauma mechanisms, particularly femoral fractures in children who cannot yet walk. The present article reported a rare presentation of this condition; around 30% of such cases are presented to orthopedists initially. These cases

need to be managed by a multidisciplinary team because of the high risk of recurrence of possible death among these children.

Conflicts of interest

The authors declare that there was no conflict of interests in conducting this study.

R E F E R E N C E S

- Kocher MS, Kasser JR. Orthopaedic aspects of child abuse. *J Am Acad Orthop Surg.* 2000;8(1):10-20.
- Kempe CH, Silverman FN, Steele BF, Droegemueller W, Silver HK. Landmark article July 7, 1962: The battered-child syndrome. By C. Henry Kempe, Frederic N. Silverman, Brandt F. Steele, William Droegemueller, and Henry K. Silver. *JAMA.* 1984;251(24):3288-94.
- Kempe CH. Uncommon manifestations of the battered child syndrome. *Am J Dis Child.* 1975;129(11):1265.
- Ruaro AF MT, Aguilar JAG, Hellu JJ, Custódio MD. Síndrome da criança espancada. Aspectos legais e clínicos – Relato de um caso. *Rev Bras Ortop.* 1997;32(10):835-8.
- Pandya NK, Baldwin K, Kamath AF, Wenger DR, Hosalkar HS. Unexplained fractures: child abuse or bone disease? A systematic review. *Clin Orthop Relat Res.* 2011;469(3):805-12.
- Caffey J. Multiple fractures in the long bones of infants suffering from chronic subdural hematoma. *Am J Roentgenol Radium Ther.* 1946;56(2):163-73.
- Caffey J. The classic: multiple fractures in the long bones of infants suffering from chronic subdural hematoma. *Clin Orthop Relat Res.* 2011;469(3):755-8.
- Schleberger R, Schulze H, Kemperdick F. [The battered child syndrome from the orthopedic point of view]. *Z Orthop Ihre Grenzgeb.* 1983;121(1):23-4.
- Estatuto da Criança e do Adolescente. Ministério da Saúde. 3ª ed., 2008 (Série E).
- Pandya NK, Baldwin K, Wolfgruber H, Christian CW, Drummond DS, Hosalkar HS. Child abuse and orthopaedic injury patterns: analysis at a level I pediatric trauma center. *J Pediatr Orthop.* 2009;29(6):618-25.
- Dalton HJ, Slovis T, Helfer RE, Comstock J, Scheurer S, Riolo S. Undiagnosed abuse in children younger than 3 years with femoral fracture. *Am J Dis Child.* 1990;144(8):875-8.
- Jones JC, Feldman KW, Bruckner JD. Child abuse in infants with proximal physeal injuries of the femur. *Pediatr Emerg Care.* 2004;20(3):157-61.
- Rex C, Kay PR. Features of femoral fractures in nonaccidental injury. *J Pediatr Orthop.* 2000;20(3):411-3.
- Schwend RM, Werth C, Johnston A. Femur shaft fractures in toddlers and young children: rarely from child abuse. *J Pediatr Orthop.* 2000;20(4):475-81.
- Forlin E. Maus-tratos na infância e adolescência. Programa de Atualização em Traumatologia e Ortopedia (Proato) Porto Alegre: Artmed/Panamericana Editora; 2004.
- Bergamaschi J, Alcântara T, Santili C, Braga S, Waisberg G, Akkar M. Femoral diaphyseal fractures: an assesmente in children younger than 3 years old. *Rev Bras Ortop.* 2006;15(2):72-5.
- Anderson WA. The significance of femoral fractures in children. *Ann Emerg Med.* 1982;11(4):174-7.
- Dos Santos LM, Stewart G, Meert K, Rosenberg NM. Soft tissue swelling with fractures: abuse versus nonintentional. *Pediatr Emerg Care.* 1995;11(4):215-6.
- Pfeiffer L. Maus-tratos – Crianças sem vínculos, adolescentes sem rumo [monografia]. Curitiba: PUC-PR; 2000.
- Lane WG, Rubin DM, Monteith R, Christian CW. Racial differences in the evaluation of pediatric fractures for physical abuse. *JAMA.* 2002;288(13):1603-9.
- Kemp AM, Dunstan F, Harrison S, Morris S, Mann M, Rolfe K, et al. Patterns of skeletal fractures in child abuse: systematic review. *BMJ.* 2008;337:a1518. Epub Oct 2008.
- Gholve P, Arkader A, Gaugler R, Wells L. Femoral neck fracture as an atypical presentation of child abuse. *Orthopedics.* 2008;31(3):271.
- Paterson CR, Burns J, McAllion SJ. Osteogenesis imperfecta: the distinction from child abuse and the recognition of a variant form. *Am J Med Genet.* 1993;45(2):187-92.
- Paterson CR, McAllion SJ. Osteogenesis imperfecta in the differential diagnosis of child abuse. *BMJ.* 1989;299(6713):1451-4.
- Kratz CP, Schweiger B, Kemperdick H, Gobel U. Childhood multifocal skeletal non-Hodgkin lymphoma is a differential diagnosis of battered child syndrome. *Pediatr Hematol Oncol.* 2003;20(8):575-7.
- Prasad MR, Kramer LA, Ewing-Cobbs L. Cognitive and neuroimaging findings in physically abused preschoolers. *Arch Dis Child.* 2005;90(1):82-5.
- Maldonado MT. Psicologia da gravidez. São Paulo: Saraiva; 2000.