



RBO

REVISTA BRASILEIRA DE ORTOPEDIA

www.rbo.org.br



Original Article

Is it safe the empirical distal femoral resection angle of 5° to 6° of valgus in the Brazilian geriatric population?☆

Fernando Cury Rezende^{a,*}, Márcio de Castro Ferreira^b, Pedro Debieux^c,
Carlos Eduardo da Silveira Franciozi^d, Marcus Vinicius Malheiros Luzo^e,
Mário Carneiro^f

^a Resident Orthopedist in the Knee Group, Department of Orthopedics and Traumatology, Universidade Federal de São Paulo (UNIFESP), São Paulo, SP, Brazil

^b Orthopedist at the Orthopedics and Sports Rehabilitation Center, Hospital do Coração de São Paulo (HCor), São Paulo, SP, Brazil

^c Attending Physician in the Knee Group, Department of Orthopedics and Traumatology, UNIFESP, São Paulo, SP, Brazil

^d PhD from the Department of Orthopedics and Traumatology, UNIFESP; and Attending Physician in the Knee Group, Department of Orthopedics and Traumatology, UNIFESP, São Paulo, SP, Brazil

^e PhD; Affiliated Professor in the Department of Orthopedics and Traumatology, UNIFESP; and Attending Physician in the Knee Group, Department of Orthopedics and Traumatology, UNIFESP, São Paulo, SP, Brazil

^f PhD; Affiliated Professor in the Department of Orthopedics and Traumatology, UNIFESP; and Head of the Knee Group, Department of Orthopedics and Traumatology, UNIFESP, São Paulo, SP, Brazil

ARTICLE INFO

Article history:

Received 15 June 2012

Accepted 3 August 2012

Keywords:

Knee joint

Arthroplasty knee replacement

Osteoarthritis

Panoramic radiography

ABSTRACT

Objective: The purpose of this study is to determine if there is a safe distal femoral resection angle to restore the normal axial alignment of the limb in total knee arthroplasty (TKA) in the Brazilian geriatric population with knee arthrosis.

Method: This study analyzed 99 pre-operative hip-knee-ankle radiographs of osteoarthritic knees of 66 patients (54 women, 12 men) with knee osteoarthritis. The distal femoral cut angle was determined based on the femoral mechanical-anatomical angle (FMA). Mean, median and standard deviation measurements of the distal femoral cut angle were calculated, differentiated by gender and side. The mean result of the distal femoral resection angle was compared to 5.7°, the mean average angle of previous and similar study based on European population of patients with knee arthrosis.

Results: The mean average of the distal femoral resection angle of the study was 6.05 (range 3–9°). The distribution of this angle between genders showed a slight superior average of the male population (6.17°) compared to the female (6.02°), but with no statistically significant difference ($p = 0.726$). There was no statistically significant difference ($p = 0.052$) between the mean average of this study (6.05°) compared to the mean average of the literature (5.7°). However, considering 3° as the limit of acceptable error in the coronal plane, this empirical femoral resection angle would not be appropriated for 19.7% of the population.

☆ Study conducted at the Department of Orthopedics and Traumatology, Universidade Federal de São Paulo, São Paulo, SP, Brazil.

* Corresponding author at: Avenida Onze de Junho, 582, Vila Clementino, São Paulo, SP, Brazil. Tel.: +55 11 2924 6217; fax: +55 11 2924 6217.

E-mail: rezendefernando@hotmail.com (F.C. Rezende).

Conclusion: The distal femoral resection angle of 5–6° is not completely safe for the Brazilian geriatric population.

© 2013 Sociedade Brasileira de Ortopedia e Traumatologia. Published by Elsevier Editora Ltda. All rights reserved.

É seguro o corte femoral distal em artroplastia total do joelho com 5° a 6° de valgo empiricamente na população geriátrica brasileira?

R E S U M O

Palavras-chave:

Articulação do joelho
Artroplastia do joelho
Osteoartrite
Radiografia panorâmica

Objetivo: Determinar se existe um ângulo seguro para o corte femoral distal, para que o membro resulte alinhado após uma artroplastia total de joelho (ATJ), na população geriátrica brasileira com gonartrose.

Método: Foram feitas radiografias panorâmicas de 99 membros inferiores em 66 pacientes consecutivos (54 mulheres e 12 homens) portadores de gonartrose do joelho. O ângulo do corte femoral distal foi determinado pelo encontro entre o eixo mecânico femoral (EMF) e o eixo anatômico femoral (EAF). Foram calculados os valores da média, o desvio padrão e a mediana do ângulo do corte femoral distal desses pacientes diferenciados por sexo e lado. O valor médio do ângulo de corte do fêmur distal ideal aqui obtido foi comparado com o valor médio de 5,7 obtido em estudo prévio semelhante a esse feito com populações europeias de pacientes osteoartrosicos submetidos a ATJ.

Resultados: A média do ângulo formado pelos EAF × EMF, considerado o ângulo do corte femoral distal em uma ATJ, do grupo estudado foi de 6,05 (variação de 3° a 9°). A distribuição desse ângulo entre os sexos evidenciou uma média discretamente superior entre os homens (6,17°) em comparação com as mulheres (6,02°), porém sem significância estatística ($p=0,726$). Não houve diferença estatística ($p=0,052$) entre o valor médio obtido na amostra atual (6,05 - DP 1,27) com o valor médio obtido na literatura (5,7°). Entretanto, se considerarmos aceitável um erro de 3° no plano coronal, 19,7% da população operada se encontrariam fora dessa faixa aceitável se optarmos pelo corte femoral empírico de acordo com o instrumental.

Conclusão: O corte femoral distal na ATJ em 5° ou 6° de valgo não é completamente seguro para a população geriátrica brasileira.

© 2013 Sociedade Brasileira de Ortopedia e Traumatologia. Publicado por Elsevier Editora Ltda. Todos os direitos reservados.

Introduction

The geopolitical increase observed among developing countries, and especially in Brazil over the last decade, has led to a typical and unavoidable inversion of the age pyramid. This has established not only a large but also a growing number of elderly people, which in Brazil has already reached 15 million people.¹ Unfortunately, there is no Brazilian data on the number of arthroplasty procedures per year, but the increasing number of indications that are associated with increasing longevity leads to the supposition that there is a growing need for these procedures.

There is a consensus in the literature that the durability of a knee prosthesis is dependent on the resultant axis of the operated limb,² given that for the procedure to be carried out, the elemental principle used is that the load should be equally distributed between the medial and lateral femoral-tibial compartments.³⁻⁵ Thus, a lower limb is considered to be aligned when its mechanical axis (the line from the center of the femoral head to the center of the ankle,^{4,6-9} known as the Maquet line¹⁰) crosses the center of the knee. The error limit is accepted to be a varus or valgus angular variation of 3°.^{11,12} Achievement of this result depends on making

the bone cuts perpendicularly to the mechanical axis desired, in association with medial-lateral ligament equalization.

In this context, both navigation-assisted surgery and the classic methods using intra or extramedullary guides have been shown to be effective for achieving an aligned limb. The former has been shown to be effective for good results,¹³ but is limited by the high cost and long learning curve. The classical method, which uses an intramedullary guide for the femur and an extramedullary guide for the tibia, which has gained mass usage within our setting, presents results that are notably satisfactory and easily implemented for planning the bone cuts preoperatively.¹² Thus, panoramic radiographs of the lower limbs should be obtained before the operation^{14,15} and the angle of the distal femoral cut should be determined from the meeting points between the mechanical axes and the femoral anatomy.^{3,4} However, these measurements are sometimes neglected,¹⁶ with regard to either preoperative analysis or postoperative assessment, because of the coast or the difficulty in finding radiological centers that do this type of imaging.

Since surgeons may choose to replace surgical planning with values that have been empirically preestablished, they need to have in-depth knowledge of the epidemiological characteristics that are prevalent in their setting, given that the

Table 1 – Inclusion and exclusion criteria of the study.

Inclusion criteria	Exclusion criteria
Radiographic diagnosis of primary osteoarthritis	Secondary osteoarthritis
Six months of conservative treatment	Presence of ipsilateral knee prosthesis
>18 years of age	Presence of ipsilateral hip prosthesis
	Incapacity to stand upright
	Deformity fixed in flexion > 10°

data available in the medical literature are based on mean angles for American and European populations that have previously been studied.^{6,17,18} These populations may not represent the individual anatomy of each patient, or even the anatomy of the average Brazilian population, because of the high degree of miscegenation among these people.¹⁹

The present study had the aim of determining whether there is a safe angle for distal femoral resection to restore the normal alignment of the limb after total knee arthroplasty (TKA), among the Brazilian geriatric population with knee arthrosis.

Material and method

From June 2008 to January 2009, panoramic radiographs were produced on 99 lower limbs in 66 consecutive patients (54 women and 12 men) aged over 60 years, who all had knee arthrosis for which conservative treatment (drugs and physiotherapy) had failed. Thus, they all had a surgical indication for replacement arthroplasty, in accordance with the inclusion and exclusion criteria shown in Table 1. The reason for excluding patients who were incapable of standing upright or who had rigid deformities in flexion was that it was impossible to produce panoramic radiographs in accordance with the standard established for this study.

Before the operation, all the patients underwent panoramic radiography on their lower limbs, performed in the same radiological center. The radiographs were produced with the patients standing upright, with the feet together in the case of patients with varus deformity or the knees together in the case of valgus. The knees were at maximum extension and the lower limbs were at the neutral rotation position, which was ensured by positioning the patella forwards in the direction of the bulb of the X-ray machine.²⁰

The angle of the distal femoral cut was determined from the meeting point between the femoral mechanical axis (FMA)^{3,4} and the femoral anatomical axis (FAA) (Fig. 1). The FAA was defined by the line that crosses the center of the femoral isthmus (given that according to the literature, this is the point that allows the smallest range of angular error^{21,22}) and the center of the intercondylar notch. In turn, the FMA consists of the line that crosses the center of the femoral head (proximally) and the center of the intercondylar notch (distally).

The axes were traced out using a ruler and the angles were measured using a protractor (Desetec® for both instruments), graduated in 0.1 mm and 0.5° divisions. All the measurements

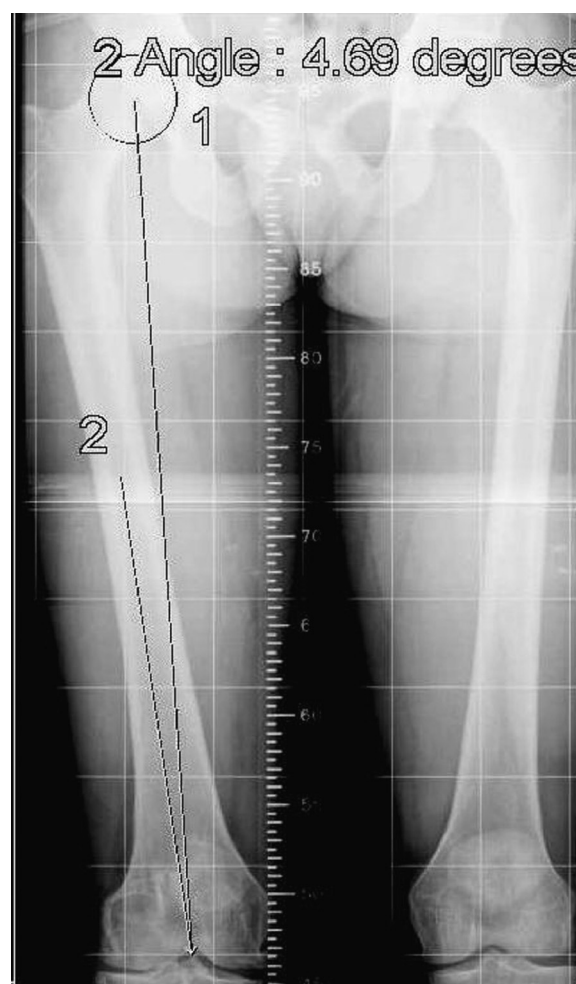

Fig. 1 – Magnification of the femur on a panoramic radiograph on the lower limbs showing the angle of the distal femoral resection determined by the intersection of the femoral mechanical axis (FMA) and the femoral anatomical axis (FAA).

were made by the same external evaluator using the same tools.^{15,17,23}

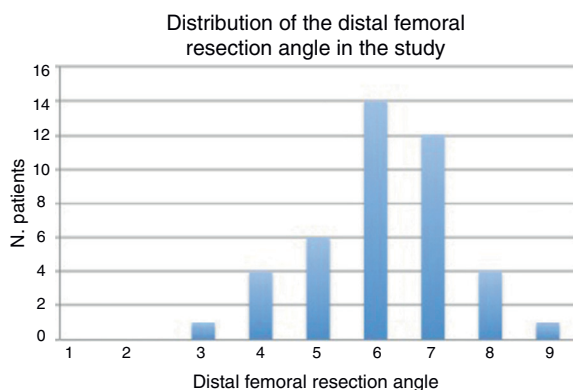
To calculate the sample size, a 95% confidence interval was used, with precision of 0.3. For the purposes of statistical calculations, the unpaired Student's t-test was used. Thus, the mean value for the ideal distal femoral resection obtained here was compared with the mean value of 5.7 that had been obtained in a similar, previous study that was conducted on European populations of osteoarthritic patients who had undergone TKA.¹⁸ The mean, standard deviation and median values for the angle between the FAA and the FMA (angle of the distal femoral cut in TKA), both overall and differentiated according to sex and side, is shown in Table 2.

Results

This study included 99 knees from 66 patients, of which 48 were right knees and 51 were left knees, after applying the inclusion and exclusion criteria (Table 1).

Table 2 – Mean, standard deviation and median values for the angle between the FAA and the FMA (distal femoral resection angle in TKA): overall and differentiated according to sex and side.

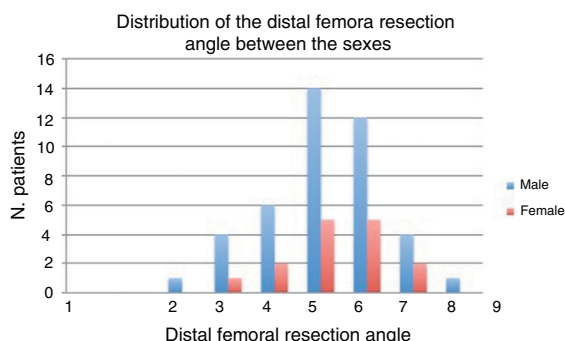
Right							
Female	5.99	1.24	6	3	9	41	0.588
Male	5.71	1.11	6	3.5	7	7	
Total	5.95	1.22	6	3	9	48	
Left							
Female	6.13	1.42	6	3.5	9	39	0.932
Male	6.17	1.11	6	5	8.5	12	
Total	6.14	1.35	6	3.5	9	51	
Mean for both sides							
Female	6.02	1.29	6.1	3	9	54	0.726
Male	6.17	1.2	5.9	4	9	12	
Total	6.05	1.27	6	3	9	66	

**Fig. 2 – Histogram showing the distribution of the distal femoral resection angles in the study.**

The mean angle formed by the FAA and the FMA, which was considered to be the angle of the distal femoral cut in a TKA, was 6.05° (range: 3–9°) in the group studied here (Fig. 2).

The distribution of this angle between the sexes showed that the mean was slightly higher among the men (6.17°) than among the women (6.02°), but without statistical significance (Fig. 3) ($p=0.726$).

Comparison between the mean value obtained in the present sample (6.05; SD 1.27) and the mean value obtained in literature (5.7°) showed that there was no statistical difference between them ($p=0.052$).

**Fig. 3 – Histogram showing the distribution of the distal femoral resection angles between males and females.**

Discussion

In Insall's classical theory of gap balancing,^{3,4} achievement of postoperative mechanical alignment is considered to be fundamental for the longevity of knee prostheses. From this viewpoint, panoramic radiographs become essential for surgical planning and are the most effective means for determining not only the femoral, tibial and whole-limb mechanical axes, but also the effects of support for them, which adds precision to the results.^{15,24} This is in contrast to the theory of McGrory et al.,¹² who advocated planning done only using short films for knees with little deformity, and planning based on the anatomical axes.

Despite all the theories, the questionable practice of replacing preoperative planning with distal femoral bone sectioning at angles measured empirically based on data preestablished in the international literature is well known. Thus, within the Brazilian setting,¹⁶ preoperative planning has become the exception, either because of difficulty in finding radiological centers that are qualified to perform this procedure or because of the inevitable additional cost. Kapandji²⁵ and Maquet²⁶ defined the mean angle between the FAA and the FMA as a valgus angle of 6°; on the other hand, Moreland et al.² found a valgus angle of 4°. In turn, Insall and Easley²⁷ described the same measurement as a valgus angle of 7° and produced an empirical "confidence interval" for this cut, consisting of a valgus angle range of 4–7°, always in relation to the FAA. However, in the present study, for statistical comparison of the mean angle for the distal femoral resection, the valgus angle of 5.7° was used, based on the study by Deakin et al.,¹⁸ which was conducted more recently with methodology and epidemiological analysis that were more appropriate.

The first conclusion from this study was that there is no statistical significance regarding the angle formed between the FAA and the FMA, in comparing a Brazilian population (6.05) with foreign populations (5.7). However, a less perceptible yet more important conclusion was that if empirical femoral resection in accordance with what the instruments showed were to be chosen, this would leave 19.7% of the population operated with insufficient alignment of the lower limb, even if an error of 3° in the coronal plane were to be considered acceptable.^{11,12} These data are convergent with what is seen in the literature, in which an empirical femoral cut at a valgus angle of 6° would only be reproducible from moderate varus

to mild valgus (femoral-tibial angles from varus of 8° to valgus of 1°), which suggests that distal femoral resection with a varus angle >6° should be used for severe varus deformities (femoral-tibial angle > varus of 8°) and a valgus angle <6° for moderate to severe valgus (femoral-tibial angle > valgus of 1°).¹⁸

Analysis on the question of gender showed that there was no statistical difference within the population studied here, which is coherent with what has been found in the general population,^{8,28} but divergent from what was found in the osteoarthritic population of the United Kingdom,¹⁸ in which the mean angle was greater among males. In fact, despite the lack of statistical significance, the absolute mean value for the angle among males was substantially greater (6.17 versus 6.02), which suggests that if the population studied had been larger (which was the most important limitation of the present study), statistical significance might have ensued.

In the light of the above discussion, it can be stated with similar degrees of precision both that empirical femoral resection at a valgus angle of 6° is appropriate for the Brazilian population and that if surgeons do not wish to exclude a significant minority of the population from the possibility of obtaining good results in terms of alignment, they should plan this stage of the procedure in an individualized manner. Obviously, the angle of femoral resection is just one of the many factors that lead to appropriate alignment, which will be added to other such factors in obtaining a good result. An error in the entry point for the guide nail in the intercondylar area, for example, or even placement of a nail that is shorter than what was planned, may alter the resultant value for the distal femoral angle that is obtained, given that for the measured and constructed angles to be the same, the same anatomical axis needs to be used, with proximal and distal points equal to what was planned, which is not always easy to obtain during the operation. Reed and Gollish²⁹ used a mathematical formula based on the divergence of the introduction of the femoral nail guide in relation to the anatomical axis both at the intercondylar point of entry and at the medullary extremity. From this, they demonstrated the potential error in the distal femoral cut and concluded that not only should radiographic preoperative planning be performed, but also, in cases of wide medullary canals, intraoperative radiographs should be produced.

Conclusion

There was no statistically significant difference in the mean angle formed between the FMA and the FAA, between men and women in the Brazilian population. Likewise, there was no statistical difference in the mean value for this angle between the Brazilian population studied here and the European populations of previous studies. The Brazilian mean angle found was 6.05°. Distal femoral resection with a valgus angle of 5–6°, for TKA, is not completely safe for the Brazilian geriatric population.

Conflicts of interest

The authors declare that there were no conflicts of interest.

REFERENCES

1. Perfil dos Idosos Responsáveis pelos Domicílios no Brasil. IBGE (Periódico na Internet). Disponível em: www.ibge.gov.br/home/estatistica/populacao/perfilidoso/default.shtm
2. Moreland JR. Mechanisms of failure in total knee arthroplasty. *Clin Orthop Relat Res.* 1988;49–64.
3. Insall J, Ranawat CS, Scott WN, Walker P. Total condylar knee replacement: preliminary report. In: Insall JN, Scott WN, editors. *Surgery of the knee*. Philadelphia: Churchill Livingstone; 2006. p. 1455–521.
4. Cates HE, Ritter MA, Keating EM, Faris PM. Intramedullary versus extramedullary femoral alignment systems in total knee replacement. *Clin Orthop Relat Res.* 1993;32–9.
5. Insall JN, Binazzi R, Soundry M, Mestriner LA. Total knee arthroplasty. *Clin Orthop.* 1983;178–83.
6. Oswald MH, Jakob RP, Schneider E, Hoogewoud HM. Radiological analysis of normal axial alignment of femur and tibia in view of total knee arthroplasty. *J Arthroplasty.* 1993;8:419–26.
7. Harrington IJ. Static and dynamic loading patterns in knee joints with deformities. *J Bone Joint Surg Am.* 1983;65:247–59.
8. Tang WM, Zhu YH, Chiu KY. Axial alignment of the lower extremity in Chinese adults. *J Bone Joint Surg Am.* 2000;82:1603–8.
9. Cooke TD, Pichora D, Siu D, Scudamore RA, Bryant JT. Surgical implications of varus deformity of the knee with obliquity of joint surfaces. *J Bone Joint Surg Br.* 1989;71:560–5.
10. Jeffery RS, Morris RW, Denham RA. Coronal alignment after total knee replacement. *J Bone Joint Surg Br.* 1991;73:709–14.
11. Akagi M, Oh M, Nonaka T, Tsujimoto H, Asano T, Hamanishi C. An anteroposterior axis of the tibia for total knee arthroplasty. *Clin Orthop Relat Res.* 2004;213–9.
12. McGrory JE, Trousdale RT, Pagnano MW, Nigbur M. Preoperative hip to ankle radiographs in total knee arthroplasty. *Clin Orthop Relat Res.* 2002;196–202.
13. Sparmann M, Wolke B, Czupalla H, Banzer D, Zink A. Positioning of total knee arthroplasty with and without navigation support. A prospective, randomized study. *J Bone Joint Surg Br.* 2003;85:830–5.
14. Ewald FC. The Knee Society total knee arthroplasty roentgenographic evaluation and scoring system. *Clin Orthop Relat Res.* 1989;9–12.
15. Rauh MA, Boyle J, Mihalko WM, Phillips MJ, Bayers-Thering M, Krackow KA. Reliability of measuring long-standing lower extremity radiographs. *Orthopedics.* 2007;30:299–303.
16. Hinman RS, May RL, Crossley KM. Is there an alternative to the full-leg radiograph for determining knee joint alignment in osteoarthritis? *Arthritis Rheum.* 2006;15–55:306–13.
17. Kharwadkar N, Kent RE, Sharara KH, Naique S. 5 degrees to 6 degrees of distal femoral cut for uncomplicated primary total knee arthroplasty: is it safe? *Knee.* 2006;13:57–60.
18. Deakin AH, Basanagoudar PL, Nunag P, Johnston AT, Sarungi M. Natural distribution of the femoral mechanical-anatomical angle in an osteoarthritic population and its relevance to total knee arthroplasty. *Knee.* 2012;19:120–3.
19. Alves-Silva J, da Silva Santos M, Guimarães PE, Ferreira AC, Bandelt HJ, Pena SD, et al. The ancestry of Brazilian mtDNA lineages. *Am J Hum Genet.* 2000;67:444–61.
20. Lonner JH, Laird MT, Stuchin SA. Effect of rotation and knee flexion on radiographic alignment in total knee arthroplasties. *Clin Orthop Relat Res.* 1996;102–6.
21. Engh GA, Petersen TL. Comparative experience with intramedullary and extramedullary alignment in total knee arthroplasty. *J Arthroplasty.* 1990;5:1–8.

22. Nuño-Siebrecht N, Tanzer M, Bobynd JD. Potential errors in axial alignment using intramedullary instrumentation for total knee arthroplasty. *J Arthroplasty*. 2000;15:228-30.
23. Yoshioka Y, Siu D, Cooke TD. The anatomy and functional axes of the femur. *J Bone Joint Surg Am*. 1987;69:873-80.
24. Patel DV, Ferris BD, Aichroth PM. Radiological study of alignment after total knee replacement. Short radiographs or long radiographs? *Int Orthop*. 1991;15:209-10.
25. Kapandji IA. *The physiology of joints*. Philadelphia: Churchill Livingstone; 1970.
26. Maquet P. *Biomechanics of the knee*. Berlin: Springer-Verlag; 1976.
27. Insall JN, Easley ME. Surgical techniques and instrumentation in total knee arthroplasty. In: Insall JN, Scott WN, editors. *Surgery of the knee*. 3rd ed. Philadelphia: Churchill Livingstone; 2001. p. 1578.
28. Hsu RW, Himeno S, Coventry MB, Chao EY. Normal axial alignment of the lower extremity and load-bearing distribution at the knee. *Clin Orthop Relat Res*. 1990: 215-27.
29. Reed SC, Gollish J. The accuracy of femoral intramedullary guides in total knee arthroplasty. *J Arthroplasty*. 1997;12:677-82.