



## Original article

# Radiographic study on the anatomical characteristics of the proximal femur in Brazilian adults<sup>☆</sup>



Tércio Henrique Soares de Farias<sup>a,\*</sup>, Vinícius Quadros Borges<sup>a</sup>,  
Eduardo Soares de Souza<sup>a</sup>, Natália Miki<sup>b</sup>, Fernando Abdala<sup>a</sup>

<sup>a</sup> Hospital Municipal Dr. Cármino Caricchio, São Paulo, SP, Brazil

<sup>b</sup> Departamento de Ortopedia e Traumatologia, Faculdade de Medicina, Universidade Federal de São Paulo (Unifesp), São Paulo, SP, Brazil

## ARTICLE INFO

## Article history:

Received 30 October 2013

Accepted 5 December 2013

Available online 18 February 2015

## Keywords:

Femur/anatomy and histology

Femur/physiology

Radiography

## ABSTRACT

**Objective:** To ascertain the geometry of the femur in the Brazilian population by means of a radiographic study and to correlate the values with regard to sex and right/left side.

**Methods:** Five hundred anteroposterior radiographs of the pelvis of skeletally mature patients (250 of each sex) who did not present any osteoarthritis, fractures or tumoral or infectious lesions were analyzed. The length and width of the femoral neck, length of the femoral axis, neck-shaft angle and femoral offset were measured.

**Results:** The following means were observed: 36.54 mm for the length of the femoral neck; 37.48 mm for the width of the femoral neck; 108.42 mm for the length of the femoral axis; 130.47° for the neck-shaft angle; and 44.4 mm for the femoral offset.

**Conclusion:** The mean values for the main measurements on the proximal femur in Brazilians differed from those of previous studies. It could also be shown that there was a statistically significant mean difference between men and women for all the variables, both on the left and on the right side, and that the men had greater means than the women.

© 2015 Sociedade Brasileira de Ortopedia e Traumatologia. Published by Elsevier Editora Ltda. All rights reserved.

## Estudo radiográfico dos aspectos anatômicos do fêmur proximal dos adultos brasileiros

## RESUMO

**Objetivo:** Verificar a geometria do fêmur da população brasileira por meio de estudo radiográfico e correlacionar os valores quanto ao sexo e ao lado direito/esquerdo.

**Métodos:** Foram analisadas 500 radiografias anteroposteriores de bacia de pacientes esqueleticamente maduros, 250 de cada sexo, sem a presença de osteoartrose, fraturas e

## Palavras-chave:

Fêmur/anatomia e histologia

Fêmur/fisiologia

Radiografia

<sup>☆</sup> Work developed at Dr. Cármino Caricchio Municipal Hospital, São Paulo, SP, Brazil.

\* Corresponding author.

E-mail: [terciohs@yahoo.com.br](mailto:terciohs@yahoo.com.br) (T.H.S. de Farias).

<http://dx.doi.org/10.1016/j.rboe.2015.02.001>

2255-4971/© 2015 Sociedade Brasileira de Ortopedia e Traumatologia. Published by Elsevier Editora Ltda. All rights reserved.

lesões tumorais ou infecciosas. Foram mensurados os valores do comprimento e da largura do colo do fêmur, do eixo femoral, do ângulo colodiafisário e do *offset* femoral.

**Resultados:** Observou-se uma média de 36,54 mm do comprimento do colo do fêmur, 37,48 mm da largura do colo do fêmur, 108,42 mm do comprimento do eixo femoral, 130,47° do ângulo colodiafisário e 44,4 mm do *offset* femoral.

**Conclusão:** Os valores médios das principais medidas do fêmur proximal dos brasileiros diferem de trabalhos prévios. Foi possível evidenciar também que existe diferença média estatisticamente significativa entre homens e mulheres para todas as variáveis, tanto do lado esquerdo quanto do direito, e que os homens tiveram média maior do que as mulheres.

© 2015 Sociedade Brasileira de Ortopedia e Traumatologia. Publicado por Elsevier Editora Ltda. Todos os direitos reservados.

## Introduction

The femoral head projects superomedially and slightly forwards when it articulates with the acetabulum. The head and neck form an angle of 115–140° (mean of 126°) with the long axis of the body of the femur.<sup>1</sup> The angle is greatest at birth and decreases gradually, from around 150° in newborns to around 133° at 15 years of age. It is smaller in women because of the width of the pelvis and greater obliquity of the body of the femur.<sup>2,3</sup>

The femoral head and the acetabulum of the hip bone grow independently but in such a way that they develop congruently. This mechanism is influenced by forces that act externally in these areas. The most important of these are body weight and muscle tension forces, which need to have magnitudes and directions for appropriate interactions. Any change to the compression forces or any joint incongruence will lead to deformities. The pressure, arching and shearing stresses to which the femur is subjected are important in relation to fracture production and also development of various pathological processes.<sup>4-6</sup>

Radiographic studies have suggested that the hip axis and the femoral neck are becoming longer. These changes may increase the risk of fractures through the increased length of the lever arm. Other non-geometric factors that might predispose toward femoral fractures have been widely debated in the literature and these include: advanced age, female sex, osteoporosis, genetic factors (such as Col1a1 Sp1 polymorphism), smoking, alcohol abuse, previous fractures and low estrogen levels. Thus, new analyses on how the geometric pattern might influence pathological conditions of the femur are pertinent.<sup>7-10</sup>

According to American statistics, more than 250,000 hip fractures occur every year and this number is expected to approximately double over the next 30 years.<sup>4</sup> The treatment for most femoral fractures is surgical. Therefore, it is important to know the geometry of the femur, since a large proportion of implants come in standard sizes, selected from a range supplied by manufacturers. For example, the PFN® short nail (AO/ASIF) can provide inclinations of 125°, 130° or 135° between the screws of the neck and the axis of the intramedullary nail. Choosing these implants wrongly may give rise to alterations to the anatomy of the hip joint.<sup>11,12</sup>

Because of the clinical importance of the morphometric aspects of the proximal femur, a wide-ranging survey was

conducted in order to provide data on the geometry of femoral bones among Brazilians.

The aims of the present study were to ascertain the femoral geometry of the Brazilian population by means of radiographic evaluations and correlate the parameters with regard to sex and right/left side.

## Materials and methods

An observational cross-sectional study was conducted, in which patients who had undergone radiography on the pelvis in anteroposterior (AP) view were evaluated. The population comprised of 250 men and 250 women who were attended at the emergency service or in the outpatient clinic or wards of the orthopedics and traumatology service. None of the radiographic images was produced for occupational reasons. The AP radiographs of the pelvis included in this study were from skeletally mature patients who did not present osteoarthritis, fractures or tumoral or infectious lesions.

To obtain the radiographs, the incident ray was directed along the median line, just above the pubic symphysis and the feet were rotated internally at around 15°. The patient was positioned in dorsal decubitus and the ampoule was one meter from the frame. The degree of magnification obtained through the radiographic method was corrected.

The femoral measurements analyzed were as follows:

**Offset** – distance between the center of rotation of the hip and a line traced out perpendicularly through the center of the femoral shaft (Fig. 1).

**WFN** – width of the femoral neck, i.e. the distance at the midpoint of the femoral neck, perpendicular to its axis (Fig. 2).

**LFA** – length of the femoral axis, i.e. the straight-line distance between the extremities of the greater trochanter and femoral head, in the frontal plane (Fig. 2).

**LFN** – length of the femoral neck, i.e. the distance in millimeters between the lower region of the femoral head and the base of the greater trochanter (Fig. 2).

**NSA** – neck-shaft angle created between the neck and shaft, which was measured in the frontal plane by means of goniometry (Fig. 3).

The analysis on the measurements of the radiographic parameters was done by two examiners. To compare all the variables regarding sex, the ANOVA test was used. The

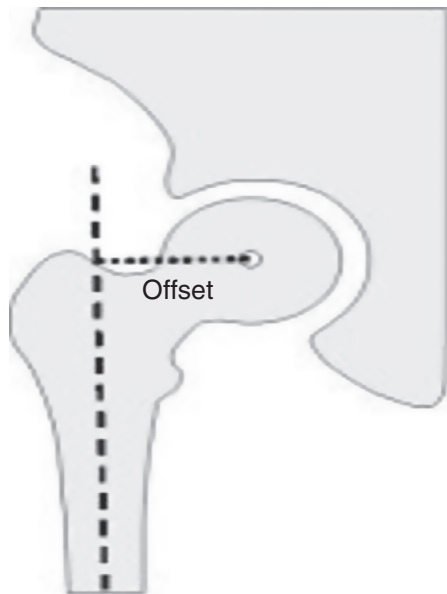

Fig. 1 – Measurement of the offset.

software used in this statistical analysis comprised SPSS V17, Minitab 16 and Excel Office® 2010. The significance level was set at 0.05 (5%) and all the confidence intervals constructed over the course of the study were 95%.

## Results

The right and left sides were compared for all the variables (Table 1). These comparisons were made separately for each gender and for both together (general). Here, the paired Student's t test was used, given that the data were paired, i.e. the same subject provided the study limb and his or her own control.

It could be seen that some of the comparisons between the sides were statistically significant. The results from measuring the width of the femoral neck and offset presented mean differences between the sides for both sexes and in general.

In comparing the lengths of the femoral neck, there was only a statistically significant difference in the general comparison, with a mean of 36.65 on the left side, versus 36.44 on the right side ( $p=0.048$ ).

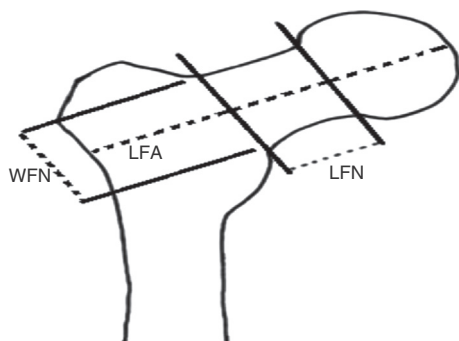


Fig. 2 – Width of the femoral neck (WFN); length of the femoral axis (LFA); length of the femoral neck (LFN).

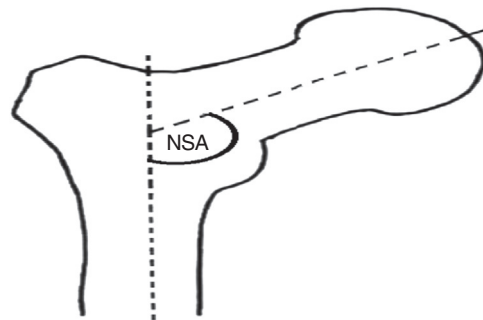


Fig. 3 – Neck-shaft angle (NSA).

On the other hand, regarding the length of the femoral axis, there was only a statistically significant result from comparing the men, such that the mean for the left side was 114.06, versus 114.39 on the right side.

Lastly, regarding the neck-shaft angle, there were statistically significant differences between the sides for the women and in general. It needs to be highlighted that the left side always had a greater mean than the right side.

The sexes were then compared for all the variables. These comparisons were made on the right side and on the left side. The ANOVA test was used here (Table 2).

It could be seen that both for the left side and for the right side, there were statistically significant mean differences between the men and women for the five variables. For example, with regard to the offset on the right side, the mean for the women was 41.97, versus 47.57 for the men, and with regard to the offset on the left side, the mean for the women was 41.53, versus 46.54 for the men ( $p < 0.001$ ). It could be seen that for all the variables on both sides, the men had greater means than the women.

## Discussion

Several aspects of the geometry of the femoral neck have been found to influence the risk of hip fractures. Studies have correlated greater length of the femoral neck and lower values for the neck-shaft angle with greater incidence of hip fractures.<sup>8,13,14</sup>

Population-based studies have shown that, over time, there has been an increase in the length of the femoral neck and a decrease in the width of the neck in the female population and have correlated these changes with an increase in the risk of fractures. This may have contributed toward the one-third increase in the incidence of hip fractures.<sup>15,16</sup>

Few studies evaluating the geometry of the proximal femur have been conducted in Brazil.<sup>17,18</sup> Because of the importance of the morphometric evaluation, a larger sample was recruited for the present study (250 radiographs from men and 250 from women) than was used in previous studies. Moreover, measurements of the femoral offset were included in the present study.

In relation to the length of the femoral neck, the mean difference between the sides was statistically significant ( $p=0.048$ ), but the mean obtained was greater than that observed in the study by Mourão and Vasconcelos,<sup>17</sup> who

**Table 1 – Comparison of the variables with regard to the right and left sides.**

	Female		Male		General	
	Left	Right	Left	Right	Left	Right
<i>Length of the femoral neck</i>						
Mean	34.68	34.55	38.54	38.27	36.65	36.44
Median	34.00	33.00	38.27	38.20	36.10	36.00
SD	5.30	5.42	4.72	4.50	5.37	5.31
Min.	27.40	25.00	30.00	27.00	27.40	25.00
Max.	49.72	48.50	46.82	47.76	49.72	48.60
p-Value	0.355	0.056	0.048			
<i>Width of the femoral neck</i>						
Mean	34.81	34.55	40.61	40.16	37.71	37.25
Median	35.00	34.72	40.00	40.00	38.00	37.00
SD	3.39	2.98	4.24	3.71	4.81	4.45
Min.	24.20	28.60	31.00	32.00	24.20	28.60
Max.	41.16	41.13	51.15	49.36	51.15	49.36
p-Value	<0.001		0.001	<0.001		
<i>Length of the femoral axis</i>						
Mean	102.48	102.68	114.06	114.39	108.27	108.57
Median	104.30	104.00	115.00	1115.00	107.46	108.00
SD	5.91	6.19	7.79	7.23	9.01	8.93
Min.	88.00	85.40	97.00	97.70	88.00	85.40
Max.	120.00	118.00	132.66	134.00	132.66	134.00
p-Value	0.519		0.047	0.051		
<i>Neck-shaft angle</i>						
Mean	129.54	128.42	132.38	131.53	130.96	129.98
Median	129.90	128.10	133.40	132.00	130.00	130.00
SD	9.16	5.09	9.39	5.31	9.37	5.43
Min.	120.00	116.70	120.00	118.80	120.00	116.70
Max.	143.60	144.10	146.00	150.00	146.00	150.00
p-Value	0.023		0.103	0.006		
<i>Offset</i>						
Mean	41.53	41.97	46.54	47.57	44.03	44.77
Median	41.31	42.55	47.00	48.60	44.60	45.00
SD	7.11	6.76	8.33	8.14	8.13	7.98
Min.	30.00	30.00	30.10	32.00	30.00	30.00
Max.	69.10	66.90	68.80	69.13	69.10	69.13
p-Value	0.002		<0.001		<0.001	

found that the mean for the right side was 24.9 mm and for the left side, 24.3 mm. Duthie et al.<sup>15</sup> analyzed Scottish populations at two different times and also found greater lengths of the femoral neck: 34.9 mm and 38.3 mm for men and 32.5 mm and 35 mm for women. They explained this difference in terms of better nutrition during childhood and changes in living standards in general.

Regarding the length of the femoral axis, O'Neill et al.<sup>16</sup> evaluated this in female populations in 1950 and 1990 and found values of 124 mm and 136.2 mm, respectively. In a similar study, Reid et al.<sup>19</sup> found values of 124.0 mm and 130.5 mm, respectively. The values for the length of the femoral axis found in the present study were smaller than those of the studies by O'Neill et al.<sup>16</sup> and Reid et al.<sup>19</sup> This difference can be explained by the different methodologies used, given that in the present study, the pelvic structure was not included in the analysis of the length of the femoral axis. Nor was this done in the study by Mourão and Vasconcellos,<sup>17</sup> who found lengths of 92.1 mm for the right side and 92.0 mm for the left side.

Higher values for the width of the femoral neck in the Brazilian population were found here, in comparison with

the study by Mourão and Vasconcellos,<sup>17</sup> whose values were 26.7 mm ( $\pm 3.1$ ) for the right side and 26.3 mm ( $\pm 3.3$ ) for the left side. Neither of the Brazilian studies found any significant differences between the sides. O'Neill et al.<sup>16</sup> observed that there was a positive correlation between the length and width of the femoral neck and found measurements of 36.6 mm and 39.1 mm for the widths in 1950 and 1990, respectively. Using similar methodology, Reid et al.<sup>19</sup> found mean values for the width of the femoral neck of 38.1 mm from radiographs performed on women in 1950 and 38.6 mm in 1990. They therefore concluded that the width of the femoral neck had increased over the course of time. In the radiographic study by Cheng et al.,<sup>4</sup> the mean values found for the length of the femoral neck for both sexes were 35.1 mm for the left side and 35.5 mm for the right side.

For the neck-shaft angle, the present study found larger values for the left side, with a statistically significant mean difference between the sides. Mourão and Vasconcellos<sup>17</sup> analyzed a Brazilian population and also found a statistically significant difference between the sides, with a neck-shaft angle of 111.2° ( $\pm 5.9$ ) for the right side and 114.2° ( $\pm 5.5$ ) for

**Table 2 – Comparison of the variables in relation to gender.**

	Left		Right	
	Female	Male	Female	Male
<i>Length of the femoral neck</i>				
Mean	34.68	38.54	34.55	38.27
Median	34.00	38.27	33.00	38.20
SD	5.30	4.72	5.42	4.50
Min.	27.40	30.00	25.00	27.00
Max.	49.72	46.82	48.50	47.76
p-Value	<0.001		<0.001	
<i>Width of the femoral neck</i>				
Mean	34.81	40.61	34.55	40.16
Median	35.00	40.00	34.72	40.00
SD	3.39	4.24	2.98	3.71
Min.	24.20	31.00	28.60	32.00
Max.	41.16	51.15	41.13	49.36
p-Value	<0.001		<0.001	
<i>Length of the femoral axis</i>				
Mean	102.48	114.06	102.68	114.39
Median	104.30	115.00	104.00	1115.00
SD	5.91	7.79	6.19	7.23
Min.	88.00	97.00	85.40	97.70
Max.	120.00	132.66	118.00	134.00
p-Value	<0.001		<0.001	
<i>Neck-shaft angle</i>				
Mean	129.54	132.38	128.42	131.53
Median	129.90	133.40	128.10	132.00
SD	9.16	9.39	5.09	5.31
Min.	120.00	120.00	116.70	118.80
Max.	143.60	146.00	144.10	150.00
p-Value	<0.001		<0.001	
<i>Offset</i>				
Mean	41.53	46.54	41.97	47.57
Median	41.31	47.00	42.55	48.60
SD	7.11	8.33	6.76	8.14
Min.	30.00	30.10	30.00	32.00
Max.	69.10	68.80	66.90	69.13
p-Value	<0.001		<0.001	

the left side. Silva et al.<sup>18</sup> found values of 122.5° for the right side and 125.6° for the left side and explained this difference between the limbs with the hypothesis that the dominant limb (the one that would be subjected to more weight-loading) might have a smaller neck-shaft angle than the contralateral limb. In a multicenter prospective study among women over the age of 60 years, using DEXA, Faulkner et al.<sup>6</sup> found that the neck-shaft angle of the control group was 126°. Cheng et al.<sup>9</sup> found a mean value of 125° in a radiographic study on the proximal femur.

The values found for the offset in the present study were 44.03 mm for the left side and 44.77 mm for the right side. We did not find any reports in this regard in the Brazilian specialized literature.<sup>18,20</sup> Ferris et al.<sup>21</sup> analyzed the contralateral femur of patients with subcapital fractures, transtrochanteric fractures and osteoporosis and found mean values of 43 mm ( $\pm 0.4$ ), 38 mm ( $\pm 0.6$ ) and 41 mm ( $\pm 0.6$ ), respectively. This difference can be attributed to the methodology used, among other reasons.

## Conclusion

The mean values of the main measurements of the proximal femur of these Brazilians differed from the values found in previous studies. There was a statistically significant mean difference between the men and women for all the variables, both on the left side and on the right side. The men presented higher values than those of the women.

## Conflicts of interest

The authors declare no conflicts of interest.

## REFERENCES

1. Labricini PJ, Alves SD, Silva AF, Giuberti GR, Hoffmann R. Estudo anatômico do terço proximal do fêmur: impacto femoroacetabular e o efeito CAM. *Rev Bras Ortop.* 2009;44(2):120-4.
2. Testut L, Latarjet A. *Tratado de anatomia humana.* Barcelona: Salvat; 1959.
3. Tardieu C, Damsin JP. Evolution of the angle of obliquity of the femoral diaphysis during growth – correlations. *Surg Radiol Anat.* 1997;19(2):91-7.
4. Pires RE, Prata EF, Gibram AV, Santos L, Belloti JC. Radiographic anatomy of the proximal femur: correlation with the occurrence of fractures. *Acta Ortop Bras.* 2012;20(2):79-83.
5. Rubin PJ, Leyvraz PF, Aubaniac JM, Argenson JN, Estève P, de Roguin B. The morphology of the proximal femur. A three-dimensional radiographic analysis. *J Bone Joint Surg Br.* 1992;74(1):28-32.
6. Faulkner KG, Cummings SR, Black D, Palermo L, Glüer CC, Genant HK. Simple measurement of femoral geometry predicts hip fracture: the study of osteoporotic fractures. *J Bone Miner Res.* 1993;8(10):1211-7.
7. Peacock M, Turner CH, Liu G, Manatunga AK, Timmerman L, Johnston CC Jr. Better discrimination of hip fracture using bone density, geometry and architecture. *Osteoporos Int.* 1995;5(3):167-73.
8. Qureshi AM, McGuigan FE, Seymour DG, Hutchison JD, Reid DM, Ralston SH. Association between Col1a1 Sp1 alleles and femoral neck geometry. *Calcif Tissue Int.* 2001;69(2):67-72.
9. Cheng XG, Lowet G, Boonen S, Nicholson PH, Brys P, Nijs J, et al. Assessment of the strength of proximal femur in vitro: relationship to femoral bone mineral density and femoral geometry. *Bone.* 1997;20(3):213-8.
10. Xu H, Zhou Y, Liu Q, Tang Q, Yin J. Femoral morphologic differences in subtypes of high developmental dislocation of the hip. *Clin Orthop Relat Res.* 2010;468(12):3371-6.
11. Beck TJ, Ruff CB, Scott WW Jr, Plato CC, Tobin JD, Quan CA. Sex differences in geometry of the femoral neck with aging: a structural analysis of bone mineral data. *Calcif Tissue Int.* 1992;50(1):24-9.
12. Simmermacher RK, Bosch AM, Van der Werken C. The AO/Asif-proximal femoral nail (PFN): a new device for the treatment of unstable proximal femoral fractures. *Injury.* 1999;30(5):327-32.
13. Sisk TD. Fractures of hip and pelvis. In: Crenshaw AH, editor. *Campbell's operative orthopaedics.* 7th ed. St. Louis: Mosby; 1987. p. 1719-28.
14. Isaac B, Vettivel S, Prasad R, Jeyaseelan L, Chandi G. Prediction of the femoral neck-shaft angle from the length of the femoral neck. *Clin Anat.* 1997;10(5):318-23.

15. Duthie RA, Bruce MF, Hutchison JD. Changing proximal femoral geometry in north east Scotland: an osteometric study. *BMJ*. 1998;316(7143):1498.
16. O'Neill TW, Grazio S, Spector TD, Silman AJ. Geometric measurements of the proximal femur in UK women: secular increase between the late 1950s and early 1990s. *Osteoporos Int*. 1996;6(2):136-40.
17. Mourão AL, Vasconcellos HA. Geometria do fêmur proximal em ossos de brasileiros. *Acta Fisiátrica*. 2001;8(3):113-9.
18. Silva VJ, Oda JY, Sant'ana DM. Anatomical aspects of the proximal femur of adults Brazilians. *Int J Morphol*. 2003;21(4):303-8.
19. Reid IR, Chin K, Evans MC, Jones JG. Relation between increase in length of hip axis in older women between 1950s and 1990s and increase in age specific rates of hip fracture. *BMJ*. 1994;309(6953):508-9.
20. Caetano EB, Serafim AG, Padoveze EH. Study of the collo-diaphyseal angle of the femur of corpses in the anatomy department of the PUC-SP medical school. *Int J Morphol*. 2007;25(2):285-8.
21. Ferris BD, Kennedy C, Bhamra M, Muirhead-Allwood W. Morphology of the femur in proximal femoral fractures. *J Bone Joint Surg Br*. 1989;71(3):475-7.