



Case Report

Popliteal artery injury during posterior cruciate ligament reconstruction[☆]



Marcos Henrique Frauendorf Cenni^{*}, Bruno Fajardo do Nascimento, Guilherme Galvão Barreto Carneiro, Rodrigo Cristiano de Andrade, Lúcio Flávio Biondi Pinheiro Júnior, Oscar Pinheiro Nicolai

Hospital Mater Dei, Belo Horizonte, MG, Brazil

ARTICLE INFO

Article history:

Received 7 June 2014

Accepted 13 June 2014

Available online 23 April 2015

Keywords:

Popliteal artery

Posterior cruciate ligament

Intraoperative complications

Palavras-chave:

Artéria poplítea

Ligamento cruzado posterior

Complicações intraoperatórias

ABSTRACT

This study reports a case of popliteal artery injury during arthroscopic reconstruction of the posterior cruciate ligament. The evolution of the injury is described and comments are made regarding the anatomy of this artery and potential risks of this surgical technique. This study had the aims of alerting the medical community, especially knee surgeons, regarding a severe surgical complication and discussing the ways of preventing it.

© 2014 Sociedade Brasileira de Ortopedia e Traumatologia. Published by Elsevier Editora Ltda. All rights reserved.

Lesão da artéria poplítea durante a reconstrução do ligamento cruzado posterior

RESUMO

Este trabalho relata uma lesão da artéria poplítea (AP) durante uma reconstrução artroscópica do ligamento cruzado posterior, descreve sua evolução e faz considerações sobre a anatomia dessa artéria e os riscos potenciais dessa técnica cirúrgica. Tem como objetivo alertar a comunidade médica, em especial os cirurgiões de joelho, sobre uma complicação cirúrgica grave e discutir as formas de preveni-la.

© 2014 Sociedade Brasileira de Ortopedia e Traumatologia. Publicado por Elsevier Editora Ltda. Todos os direitos reservados.

[☆] Work developed in the Knee Group of Hospital Mater Dei, Belo Horizonte, MG, Brazil.

^{*} Corresponding author.

E-mail: cenni14@gmail.com (M.H.F. Cenni).

<http://dx.doi.org/10.1016/j.rboe.2015.04.005>

2255-4971/© 2014 Sociedade Brasileira de Ortopedia e Traumatologia. Published by Elsevier Editora Ltda. All rights reserved.

Introduction

Reconstruction surgery on the posterior cruciate ligament (PCL) is a procedure that is well known among knee surgeons for its complexity, technical difficulty and potential risks of injuring the vascular-nervous bundle of the popliteal fossa. The reconstruction techniques can be arthroscopic, open or mixed (of inlay type). Arthroscopic reconstruction is less aggressive toward the patient, but presents greater technical difficulties and risks.¹

Case report

On November 19, 2010, the patient R.J.M. suffered a car accident, with severe multiple trauma, which led him to be kept in the intensive care center for four days. His most significant injuries were a multi-fragment fracture of the left femoral diaphysis, dislocation of the right knee of type KDIII L (tearing of the anterior and posterior cruciate ligaments in association with injury to the posterolateral corner), tearing of the spleen and a variety of abrasions (Figs. 1 and 2).

On November 24, 2010, he underwent intramedullary osteosynthesis with a retrograde nail introduced into the left femur. On December 1, 2010, he underwent acute peripheral repair of the posterolateral injury to the right knee (Fig. 3).

He was released from hospital on December 5, 2010, in a good condition but with an indication for PCL reconstruction, to be performed as a second operation after the peripheral injuries had healed.

On March 2, 2011, he underwent PCL reconstruction arthroscopically, in which a quadruple graft from the gracilis and semitendinosus flexor tendons was used. At the end of the operation, it was noted that the popliteal artery had been injured, given the effusive bleeding through the posteromedial portal and the absence of pulse and distal perfusion in the operated limb.

The vascular surgeon was called in, on an emergency basis. He got the call promptly and arrived in the operating theater after around 50 min. No additional diagnostic tests were requested, given the high degree of suspicion of vascular injury and the need for emergency intervention.

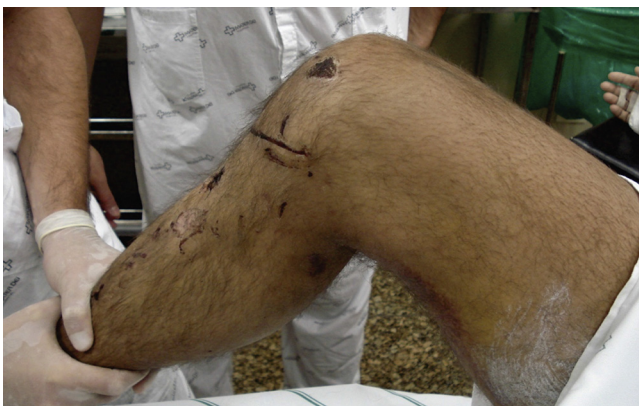

Fig. 1 – Appearance of the limb with posterior fall of the tibia.

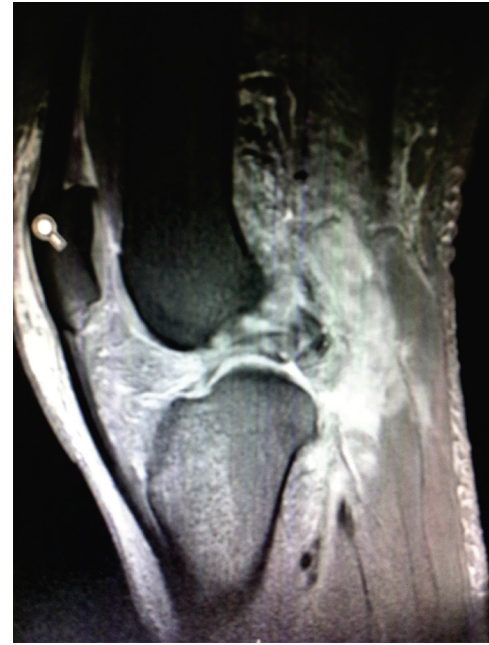

Fig. 2 – Magnetic resonance imaging of the initial lesion, showing the severe ligament injury.

The patient was positioned in ventral decubitus and underwent revascularization surgery with interposition of a graft from the great saphenous vein, by means of Trickey's posterior access. The revascularization was terminated five hours and 45 min after inflation of the tourniquet for the ligament reconstruction surgery (i.e. this was the total duration of ischemia in the limb) and the patient was sent to the intensive care center for postoperative recovery. After a few hours, the patient was returned to the surgical center due to poor perfusion of the right leg. A Foghart catheter was introduced and the patient underwent decompressive fasciotomy of the four compartments of the same leg. The patient was kept in the intensive care center for another three days and was released from hospital in a good condition after 24 days.

After six months of rehabilitation, the patient's condition presented excellent evolution, with satisfactory functional

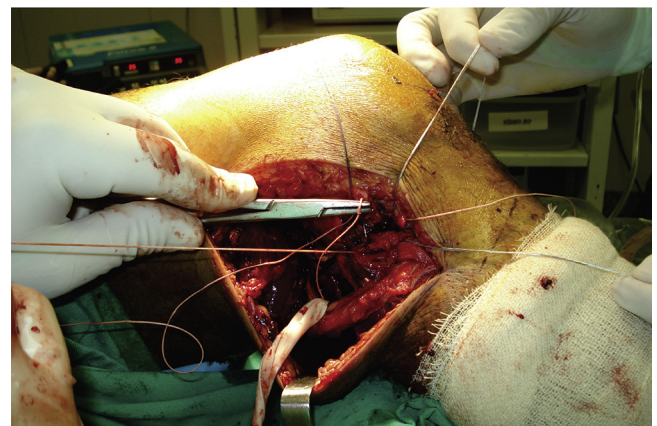


Fig. 3 – Photograph of the acute repair surgery of the posterolateral corner.

recovery and without any clinical signs of posterior instability or poor distal perfusion of the limb affected.

Discussion

Complications relating to arthroscopic surgery are rare. Multicenter studies conducted in the 1980s observed incidences ranging from 0.56% to 1.68%. In 1985, DeLee,² leading the complications committee of the Arthroscopy Association of North America (AANA), coordinated a national survey on 118,590 arthroscopic procedures performed on several joints and observed that 930 cases of complications occurred (0.8%). Among these cases, only nine were vascular complications, all in the knee, and six of them resulted in amputation. Subsequently, Small³ conducted further studies through the same committee of the AANA and observed complication rates from 0.56% to 1.68%.

Thus, vascular complications are very rare, but potentially serious. Out of all knee surgical procedures, PCL reconstruction and total arthroplasty are the ones that present greatest risk, because of the proximity of the surgical instruments to the popliteal vessels.^{1,4} Several studies have drawn attention to the stages of surgical procedures that present risks of vascular injury, such as construction of the posteromedial portal, debridement of the posterior capsule, passage of the tibial tunnel guide and tunnel drilling.

Using magnetic resonance imaging, Kieser⁴ demonstrated that in 93.4% of the patients evaluated, the popliteal artery was located laterally to the midline of the knee. In the remaining patients, it was located in the central area and never medially to this line. The distance from the artery to the posterior edge of the tibia ranged from 2.6 mm to 9.9 mm. These findings confirm that there is a potential risk of injury through passage of the tibial guidewire, which is oriented slightly laterally.

In 2004, Barlett et al.,⁵ at the University of Melbourne, Australia, conducted a study on injuries of the popliteal vessels and evaluated their incidence, anatomical factors and the influence of surgery and previous trauma on the risk of such injuries during procedures on the knee. They demonstrated that in around one third of normal knees (23/60), the popliteal artery came close to the tibia as the knee was flexed. In knees with PCL injuries, this occurred in almost 79% (11/14). They also emphasized that previous injuries or surgical procedures affecting the posterior capsule of the knee could increase the risk of inadvertent injury to the popliteal vessels, which might be adhering to the posterolateral scar tissue. After careful analysis of the case reported here, it was concluded that the laceration of the popliteal artery occurred exactly at the time of debridement of the posterior recess using a shaver, which had been done in an attempt to obtain a good view of the point at which the tibial tunnel emerged.

Matava et al.⁶ used fresh cadavers to study the anatomical relationship between the popliteal arterial and construction of the tibial tunnel. They demonstrated that the tibial guidewire gave rise to a risk of perforation in all the ten models observed, at flexions of 0°, 45° and 90°. Only at flexion of greater than 100° did this risk diminish partially for six of the ten.

In 2003, Wu et al.⁷ reported a case of acute popliteal artery occlusion during PCL reconstruction, with spontaneous resolution in 12 h.

In 2005, Makino et al.⁸ described an occurrence of laceration of the popliteal artery that required vascular repair. The case presented good evolution.

Nemani et al.⁹ reported a case of laceration of the popliteal vein and highlighted some suggestions for avoiding occurrences of this nature, such as: keeping the Arthropump at a lower pressure, to avoid proximity with the popliteal vessels; use of devices to block the tibial guidewire, so as to avoid situations in which it might go beyond the limits of the tibia posteriorly; and use of radioscapy during the passage of the guide and drilling of the tibial tunnel.

The prognosis for popliteal artery injuries depends directly on the duration of ischemia and the magnitude of the soft-tissue injury. When patients are revascularized over a period of less than six hours and no significant musculoskeletal trauma occurs, the risk of amputation becomes minimal, as observed by Khan et al.¹⁰ in 2011. Since our patient was promptly attended to by the vascular surgeon, the total duration of ischemia of five hours and 45 min was a fundamental factor in the good evolution of the condition.

Although rare, popliteal artery injuries may place the patient's lower limb, and even his life, at risk. Intraoperative care needs to be rigorously observed, with safe use of instruments, with radioscopic assistance and always with the presence of a vascular surgeon prepared to perform immediate vascular repair or grafting. If vascular injury occurs, the intervention needs to be immediate, so as to improve the patient's prognosis.

Conflicts of interest

The authors declare no conflicts of interest.

REFERENCES

1. Furie E, Yerys P, Cutcliffe D, Febre E. Risk factors for arthroscopic popliteal artery laceration. *Arthroscopy*. 1995;11(3):324-7.
2. DeLee JC, Committee on Complications of the Arthroscopy Association of North America. Complications of arthroscopy and arthroscopic surgery: results of a national survey. *Arthroscopy*. 1985;1(4):214-20.
3. Small NC, Committee on Complications of the Arthroscopy Association of North America. Complications in arthroscopy: the knee and other joints. *Arthroscopy*. 1986;2(4):253-8.
4. Kieser C. A review of the complications of arthroscopic knee surgery. *Arthroscopy*. 1992;8(1):79-83.
5. Barlett RJ, Roberts A, Wong J. Risk to popliteal vessels in major knee surgery, an anatomical study and survey of vascular surgeons. *J Bone Joint Surg Br*. 2004;86(Suppl 4):468.
6. Matava MJ, Sethi NS, Totty WG. Proximity of the posterior cruciate ligament insertion to the popliteal artery as a function of the knee flexion angle: implications for posterior cruciate ligament reconstruction. *Arthroscopy*. 2000;16(8):796-804.
7. Wu RW, Hsu CC, Wang CJ. Acute popliteal artery occlusion after arthroscopic posterior cruciate ligament reconstruction. *Arthroscopy*. 2003;19(8):889-93.

-
8. Makino A, Costa-Paz M, Aponte-Tinao L, Ayerza MA, Muscolo DL. Popliteal artery laceration during arthroscopic posterior cruciate ligament reconstruction. *Arthroscopy*. 2005;21(11):1396.
 9. Nemani VM, Frank RM, Reinhardt KR, Pascual-Garrido C, Yanke AB, Drakos M, et al. Popliteal venotomy during posterior cruciate ligament reconstruction in the setting of a popliteal artery bypass graft. *Arthroscopy*. 2012;28(2):294-9.
 10. Khan S, Alam S, Ahmed NU. Popliteal artery injury: short term outcome with or without skeletal trauma. *Univ Heart J*. 2011;7(1):16-8.