



Case Report

Transtriquetral perihamate fracture-dislocation: case report[☆]



Frederico Barra de Moraes*, Rodrigo Cunha Ferreira, Stéphanie Zago Geraldino, Renato Silva Farias, Ricardo Pereira da Silva, Mário Yoshihide Kuwae

Universidade Federal de Goiás (UFG), Faculdade de Medicina, Goiânia, GO, Brazil

ARTICLE INFO

Article history:

Received 24 October 2014

Accepted 1 December 2014

Available online 4 July 2016

Keywords:

Carpal bones/injuries

Bone fractures

Dislocations/radiography

Hand trauma/radiography

ABSTRACT

The wrist is a region that is very vulnerable to injuries of the extremities. Among these injuries, fractures of the pyramidal bone (or triquetrum) in association with dislocation of the hamate and carpal instability are uncommon. They are generally correlated with high-energy trauma and may be associated with neurovascular deficits, muscle-tendon disorders, skin lesions or injuries to other carpal bones. Thus, in this report, one of these rare cases of transtriquetral perihamate fracture-dislocation with carpal instability is presented, diagnosed by means of radiography on the right wrist of the patient who presented pain, edema and limitation of flexion-extension of the carpus after trauma to the region. The stages of attending to the case are described, from the initial consultation to the surgical treatment and physiotherapy, which culminated in restoration of the strength and range of motion of the wrist.

© 2015 Sociedade Brasileira de Ortopedia e Traumatologia. Published by Elsevier Editora Ltda. This is an open access article under the CC BY-NC-ND license (<http://creativecommons.org/licenses/by-nc-nd/4.0/>).

Fratura-luxação transtriquetral peri-hamato: relato de caso

RESUMO

O punho é uma região muito vulnerável a traumas de extremidade. Entre tais lesões, as fraturas do piramidal (ou triquetrum), associadas à luxação do hamato e à instabilidade carpal, são pouco frequentes. Geralmente relacionadas a traumatismos de alta energia, podem estar associadas a déficit neurovascular, miotendíneo, lesões de pele ou em outros ossos do carpo. Assim, neste relato, apresenta-se um desses casos raros de fratura-luxação transtriquetral peri-hamato com instabilidade carpal, diagnosticadas por radiografias do punho direito de um paciente que apresentava dor, edema e limitação da flexoextensão do carpo após trauma

Palavras-chave:

Ossos do carpo/lesões

Fraturas ósseas

Luxações/radiografia

Traumatismos da mão/radiografia

[☆] Study conducted at the Universidade Federal de Goiás (UFG), Faculdade de Medicina, Hospital das Clínicas, Departamento de Ortopedia e Traumatologia, Goiânia, GO, Brazil.

* Corresponding author.

E-mail: frederico.barra@yahoo.com.br (F.B. Moraes).

<http://dx.doi.org/10.1016/j.rboe.2016.06.006>

2255-4971/© 2015 Sociedade Brasileira de Ortopedia e Traumatologia. Published by Elsevier Editora Ltda. This is an open access article under the CC BY-NC-ND license (<http://creativecommons.org/licenses/by-nc-nd/4.0/>).

na região. As etapas do atendimento foram descritas desde a consulta inicial até o tratamento cirúrgico e a fisioterapia, que culminaram com a restauração da força e da amplitude de movimento do punho.

© 2015 Sociedade Brasileira de Ortopedia e Traumatologia. Publicado por Elsevier Editora Ltda. Este é um artigo Open Access sob uma licença CC BY-NC-ND (<http://creativecommons.org/licenses/by-nc-nd/4.0/>).

Introduction

Fractures of the pyramidal bone (or triquetrum) in association with dislocation of the hamate and carpal instability are uncommon, usually related to high-energy trauma, and may be associated with neurovascular deficit, skin lesions, myotendinous or even other carpal bones injuries. Early diagnosis and treatment of these injuries can prevent complications.¹ Indeed, the stability of the bone-ligament structure of the carpus is essential for its proper functioning.² This study aimed to report a rare case of transtriquetral perihamate fracture-dislocation and its treatment.

Case report

A 27 year-old male manual laborer, right-handed, presented to the emergency room with severe pain (VAS=7) in the right wrist, edema ++/4+, with limited carpal flexion-extension without skin lesions or neurovascular deficit. He reported having suffered a direct trauma to the right wrist on the same day, which had been crushed between two iron bars at work. Pain was more intense on palpation of the ulnar region of the wrist, with a slight crackle and instability.

Right wrist radiographs were made in true anteroposterior, ulnar deviation, and profile views, which indicated fracture of the pyramidal and instability of the hamate (Fig. 1).

Patient underwent surgery; a dorsal incision was made, followed by an open reduction of the hamate-capitate instability and reduction of pyramidal fracture, which were fixed with Kirschner wires. Capsulorrhaphy and repair of hamate-capitate and lunotriquetral ligaments were also performed (Fig. 2). The wrist was immobilized in a short arm cast for four

weeks, and K-wires were removed after eight weeks. Physical therapy was initiated after the fourth week. Eight months after surgery, patient was asymptomatic, with restored range of motion and strength, comparable to the contralateral side, with a decrease in the last 10° in extension and flexion on the right wrist (Fig. 3).

Discussion

The wrist has a complex anatomy, developed for a highly specialized function, and at the same time it is very exposed to extremity trauma through various mechanisms. The carpal bones and ligaments promote a multiplanar mobility and maintain stability in the various movements performed by the wrist, such as flexion, extension, radial and ulnar deviation, pronosupination, and circumduction.^{3,4}

Trauma mechanism of this injury differs from the theory by Mayfield et al.^{5,6} of progressive perilunate instability in greater arc injuries, where the trauma energy passes through the carpal bones and ligaments from the radial to the ulnar side in stages, which would be explained in stage 3, with lunotriquetral ligament rupture without semilunar dislocation. The injury described in the present patient indicates the existence of a greater arc injury in reverse, from ulnar to radial. The radial carpal bones were spared.⁷

Moreover, it is certain that the patient had carpal instability, which is a disturbance of the static and dynamic balance between joints under physiological loads and movements. This loss of stability, which is related to bone and/or ligament injuries, leads to alterations in the joint anatomical relationships, affecting the biomechanical activity, as well as generating pain and carpal collapse.⁸

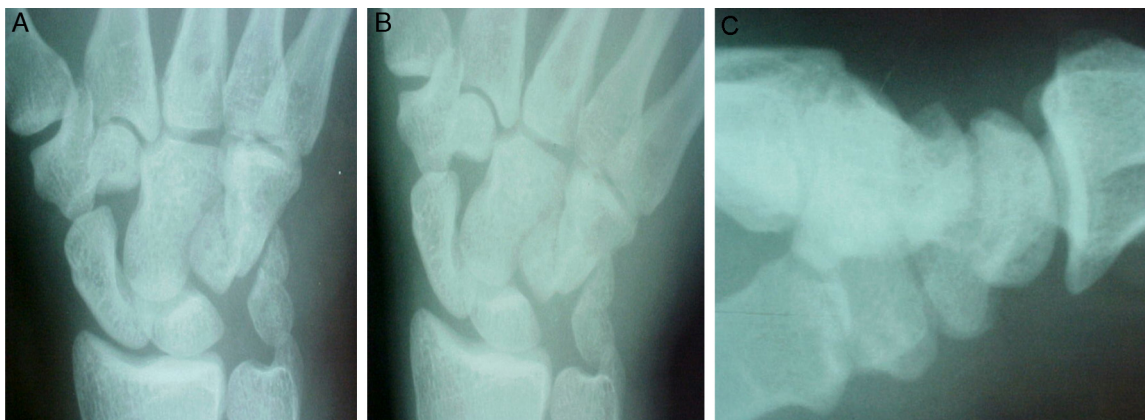


Fig. 1 – Right wrist X-rays in true anteroposterior (A), ulnar deviation (B), and profile incidences (C), showing pyramidal fracture and instability of the hamate.

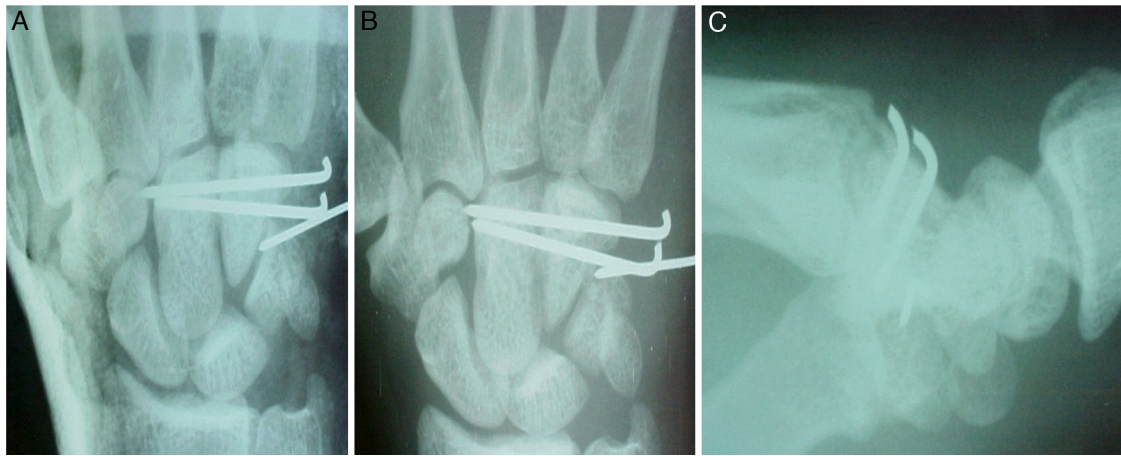


Fig. 2 – Radiographs of the right wrist in anteroposterior incidence with cast immobilization (A), transtriquetral perihamate fracture-dislocation fixed with K-wires (B), and in profile (C), showing good shaft and satisfactory reduction of the lesion.

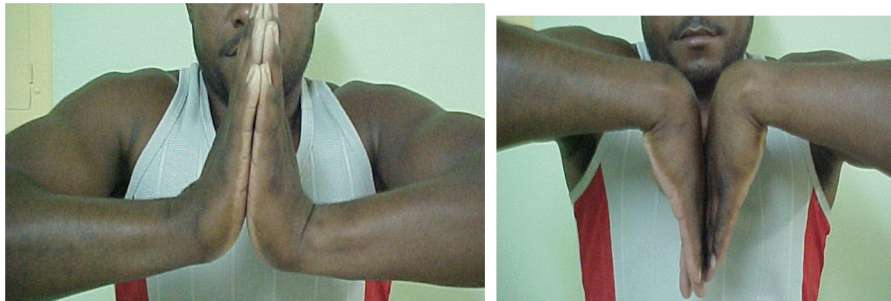

Fig. 3 – Images eight months postoperatively showing restored range of motion and strength, but with a decrease in the last 10° in extension and flexion of the right wrist.

This pattern of carpal injury was studied by Garci-Elias et al.,⁹ who identified longitudinal and axial carpal instabilities, subdivided into three groups: axial-ulnar, axial-radial, and axial-radial-ulnar. Thus, the reported case would be classified as a longitudinal carpal instability, axial-ulnar subtype, specifically transtriquetral perihamate. It is important to note that the cleavage line in the diastasis between the capitate and the hamate may be subtle and the diagnosis may be overlooked.

Wrist X-rays are usually sufficient for the diagnosis of these lesions; in doubtful cases, CT can better assess fracture lines, and magnetic resonance imaging can identify ligament injury.^{8,10} Impairment of the median nerve is frequent and can trigger carpal tunnel syndrome (compression of the median nerve in the carpal tunnel area), characterized by pain with burning, paresthesia, thenar atrophy, and limitation of activity. Nerve decompression is required. Although a closed reduction and immobilization are initially possible, surgical treatment should eventually be performed to restore the anatomy and stability of the carpus, as was done in the case reported.^{3-6,10-13}

Conflicts of interest

The authors declare no conflicts of interest.

REFERENCES

1. Naam NH, Smith DK, Gilula LA. Transtriquetral perihamate ulnar axial dislocation and palmar lunate dislocation. *J Hand Surg Am.* 1992;17(4):762-6.
2. Özçelik A, Günel I, Köse N, Seber S, Omeroğlu H. Wrist ligaments: their significance in carpal instability. *Ulus Travma Acil Cerrahi Derg.* 2005;11(2):115-20.
3. Trumble TE. *Principles of hand surgery and treatment.* Philadelphia: Saunders; 2000.
4. Yeager BA, Dalinka MK. Radiology of trauma to the wrist: dislocations, fracture dislocations, and instability patterns. *Skelet Radiol.* 1985;13(2):120-30.
5. Mayfield JK. Mechanism of carpal injuries. *Clin Orthop Relat Res.* 1980;149:45-54.
6. Mayfield JK, Johnson RP, Kilcoyne RK. Carpal dislocations: pathomechanics and progressive perilunate instability. *J Hand Surg Am.* 1980;5(3):226-41.
7. Leung YF, Ip SP, Wong A, Ip WY. Trans-triquetral dorsal perilunate fracture dislocation. *J Hand Surg Eur.* 2007;32(6):647-8.
8. Sugawara LM, Yanaguizawa M, Ikawa MH, Takahashi RD, Natour J, Fernandes ARC. Instabilidade do carpo. *Rev Bras Reumatol.* 2008;48(1):34-8.
9. Garcia-Elias M, Dobyns JH, Cooney WP 3rd, Linscheid RL. Traumatic axial dislocations of the carpus. *J Hand Surg Am.* 1989;14(3):446-57.
10. Bain GI, McLean JM, Turner PC, Sood A, Pourgiezis N. Translunate fracture with associated perilunate injury: 3 case

- reports with introduction of the translunate arc concept. *J Hand Surg Am.* 2008;33(10):1770-6.
11. Graham TJ. The inferior arc injury: an addition to the family of complex carpal fracture-dislocation patterns. *Am J Orthop (Belle Mead NJ).* 2003;32 Suppl. 9:10-9.
 12. Green DP. Carpal dislocations and instabilities. In: Green DP, editor. *Operative hand surgery.* 3rd ed. New York: Churchill Livingstone; 1993. p. 917-8.
 13. Karolczak APB, Vaz MA, Freitas CR, Merlo ARC. Síndrome do túnel do carpo. *Rev Bras Fisioter.* 2005;9(2):117-22.