



## Case Report

# Total knee arthroplasty with subvastus approach in patient with chronic post-traumatic patellar dislocation<sup>☆</sup>



Jader Joel Machado Junqueira\*, Camilo Partezani Helito, Marcelo Batista Bonadio, Jose Ricardo Pécora, Marco Kawamura Demange

Universidade de São Paulo, Faculdade de Medicina, Instituto de Ortopedia e Traumatologia, São Paulo, SP, Brazil

### ARTICLE INFO

#### Article history:

Received 30 September 2015

Accepted 6 November 2015

Available online 21 June 2016

#### Keywords:

Osteoarthritis

Knee

Arthroplasty

Patellar dislocation

### ABSTRACT

Chronic lateral dislocation of the patella is a rare condition and acquired causes are usually secondary to knee trauma. The neglected chronic dislocation leads to progressive genu valgum and external tibial torsion deformities with subsequent gonarthrosis, which becomes painful and debilitating. There is no consensus regarding treatment of these patients, but total knee arthroplasty (TKA) is a useful therapy in cases of painful symptomatic gonarthrosis. Few reports have shown that subvastus approach and lateral release may be a valid option for TKA, since it allows the correction of valgus deformity and patellar tracking without interrupting vascular blood supply of patella. This article reports a case of TKA and extensor mechanism realignment without patellar resurfacing in a patient with genu valgum and chronic post-traumatic patellar dislocation with satisfactory results after two years of follow-up.

© 2016 Published by Elsevier Editora Ltda. on behalf of Sociedade Brasileira de Ortopedia e Traumatologia. This is an open access article under the CC BY-NC-ND license (<http://creativecommons.org/licenses/by-nc-nd/4.0/>).

### Artroplastia total de joelho por via subvasto em paciente com luxação crônica pós-traumática de patela

### RESUMO

A luxação crônica da patela é uma patologia rara e o trauma sua principal causa adquirida. Quando negligenciada, leva ao genu valgo progressivo, torção externa da tibia e subsequente artrose debilitante. Não existe consenso na literatura com relação ao tratamento desses pacientes, porém a artroplastia total de joelho (ATJ) tem se mostrado um procedimento eficaz em casos de gonartrose sintomática dolorosa. Poucos relatos mostraram que a via subvasto associada à liberação lateral é uma opção válida para ATJ, já

#### Palavras-chave:

Osteoartrose

Joelho

Artroplastia

Luxação de patela

<sup>☆</sup> Work developed in the Knee Group, Institute of Orthopedics and Traumatology, Hospital das Clínicas, Faculty of Medicine, Universidade de São Paulo, São Paulo, SP, Brazil.

\* Corresponding author.

E-mail: [jader.junqueira@yahoo.com.br](mailto:jader.junqueira@yahoo.com.br) (J.J. Junqueira).

<http://dx.doi.org/10.1016/j.rboe.2016.06.005>

2255-4971/© 2016 Published by Elsevier Editora Ltda. on behalf of Sociedade Brasileira de Ortopedia e Traumatologia. This is an open access article under the CC BY-NC-ND license (<http://creativecommons.org/licenses/by-nc-nd/4.0/>).

que permite a correção de deformidades em valgo e da boa excursão patelar, sem interrupção do suprimento sanguíneo. Relatamos um caso de uma paciente com genu valgo e luxação crônica pós-traumática de patela submetida a ATJ associada ao realinhamento do mecanismo extensor, com resultados satisfatórios persistentes após seguimento de dois anos.

© 2016 Publicado por Elsevier Editora Ltda. em nome de Sociedade Brasileira de Ortopedia e Traumatologia. Este é um artigo Open Access sob uma licença CC BY-NC-ND (<http://creativecommons.org/licenses/by-nc-nd/4.0/>).

## Introduction

Chronic lateral dislocation of the patella is a rare condition that is usually congenital or acquired in origin.<sup>1</sup> Acquired causes are usually secondary to recurrent trauma about the knee, in patients who have predisposition for patellar dislocation. Femoral or tibial shaft fracture with valgus or external rotation malunion will exaggerate the valgus vector and increase this predisposition for dislocation.<sup>2</sup>

The neglected chronic patellar dislocation leads to progressive genu valgum and external tibial torsion deformities with subsequent gonarthrosis, which becomes painful and debilitating. Valgus malalignment of the lower extremity, a laterally dislocated patella, and a weak active knee extension are the typical physical findings.<sup>3</sup>

There is no consensus regarding treatment of these patients, but total knee arthroplasty (TKA) is a useful therapy in cases of painful symptomatic gonarthrosis.<sup>4</sup> Surgical reconstruction can be technically demanding and requires attention to restoring the extensor mechanism realignment, soft tissue balancing, good patellar tracking, as well as correction of the bony deformities present in the severe valgus knee.<sup>2,5</sup> Another concern is about the potential for osteonecrosis of the patella due to disruption of its blood supply during medial parapatellar approach and when performing extensive lateral release of the extensor mechanism.<sup>1,3,6</sup>

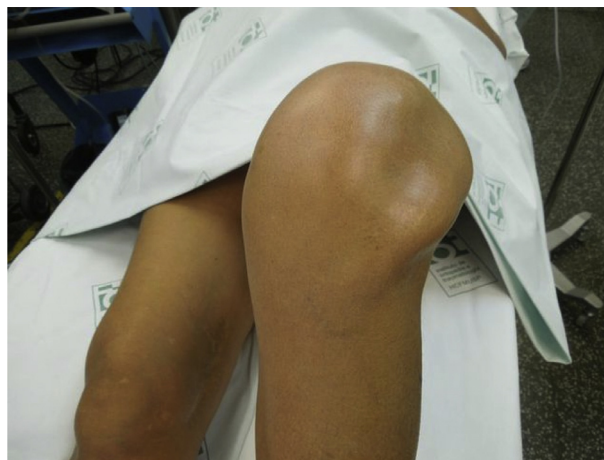Only one report showed that subvastus approach and lateral release may be a valid option for TKA in patients with chronic post-traumatic patellar dislocation since it allows the correction of valgus deformity and patellar tracking without interrupting vascular blood supply of patella.<sup>1</sup>

We report a case of TKA and extensor mechanism realignment without patellar resurfacing in a patient with genu valgum and chronic post-traumatic patellar dislocation.

## Case report

A 59-year-old woman with severe left knee pain, which she had experienced for 10 years, was referred to our Hospital. Pain has gradually worsened over the last 3 years because of a traumatic dislocation of patella. Ambulation and stair climbing were difficult for her but she could walk without support. She has no relevant family history or congenital disease. Conservative treatment with analgesics, anti-inflammatories and physiotherapy for muscle strengthening was not effective.

On examination, there was slight quadriceps atrophy in the left knee, partially reducible valgus deformity, passive range



**Fig. 1 – Preoperative clinical photography showing a completely dislocated patella.**

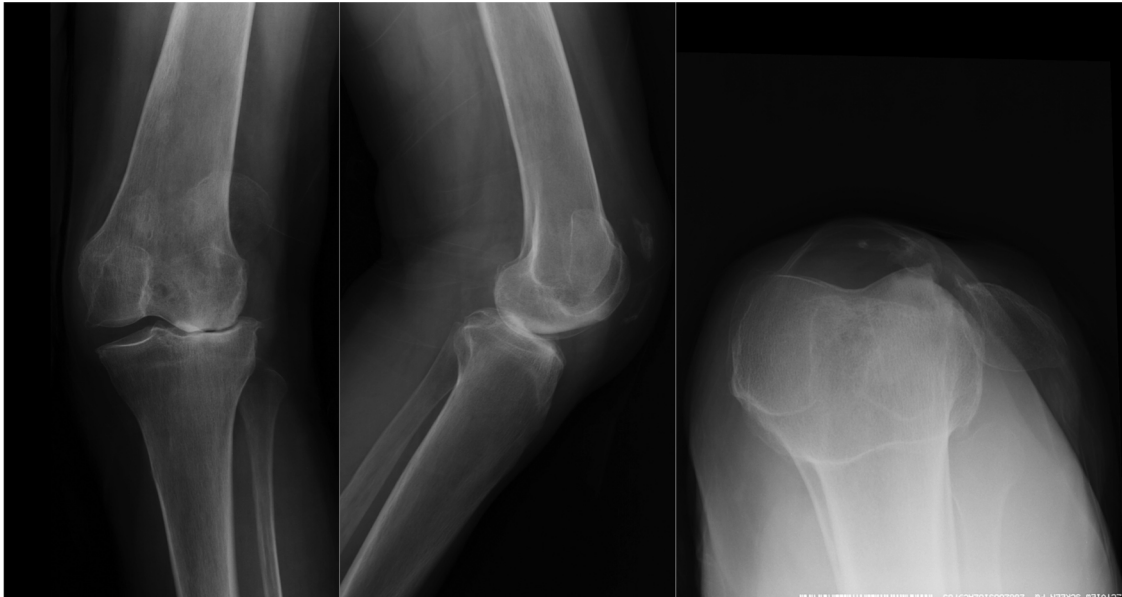
of motion from 0° to 100° with painful crepitus of lateral compartment and extension lag of 10°. The patella was dislocated laterally and it could not be reduced at full extension (Fig. 1). Minimal patellar mobility during flexion and extension was observed. No effusion was palpable and no signs of instability or ligamentous deficiency were observed.

A standing anteroposterior radiograph of the knee showed valgus deformity and osteoarthritic changes in all compartments with almost complete loss of the lateral joint space; lateral radiograph revealed that the patella was not in the anterior portion of the knee; skyline view radiograph showed a completely dislocated patella and its direct contact with the outer border of the lateral femoral condyle (Fig. 2).

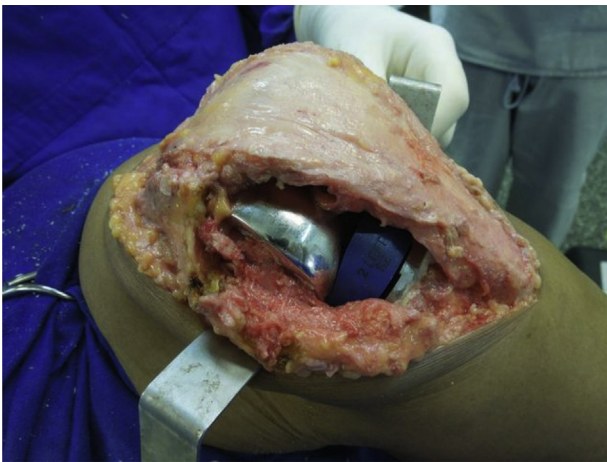
## Surgical technique

She underwent a TKA on the left knee (Medial Pivot, Wright Medical Technology, Inc.). A midline longitudinal skin incision was made over the patella in a subvastus approach with the objective to protect patellar circulation. The patella was located in the lateral gutter of the knee and the lateral femoral condyle was hypoplastic.

Distal femur was cut perpendicular to the mechanical axis (5° valgus), and tibia was cut perpendicular to its the long axis. Femoral component rotation was set based on the posterior condylar axis, biepicondylar line and Whiteside line. Tibial component was also slightly externally rotated relative to tibial anterior tubercle. Patella resurfacing was not performed because of its thickness (9 mm).



**Fig. 2 – Preoperative anteroposterior, lateral and skyline radiographs of the left knee.**



**Fig. 3 – Intraoperative photography showing the patella centrally placed in the groove of the femoral component.**

An extensive lateral release was performed beginning proximally in vastus lateralis and extending distally to the tibial tuberosity obtaining a patellar tracking centered in the femoral groove (Fig. 3). Iliotibial band was also lengthened with the use of pie-crusting technique. Distal realignment by tibial tubercle transfer was not necessary. Total surgical time was 95 minutes.

The patient was allowed immediate weight bearing on first postoperative day. Rehabilitation program included quadriceps strengthening exercises and gradually increasing knee motion from full extension to 120° flexion with no extensor lag.

At 2 years postoperatively follow up, the patient was satisfied with the surgery and pain free during active knee motion and weight bearing activities (Fig. 4). The patient's

Knee Society score (KSS)<sup>7</sup> improved from preoperative values of 49 to 93 postoperatively.

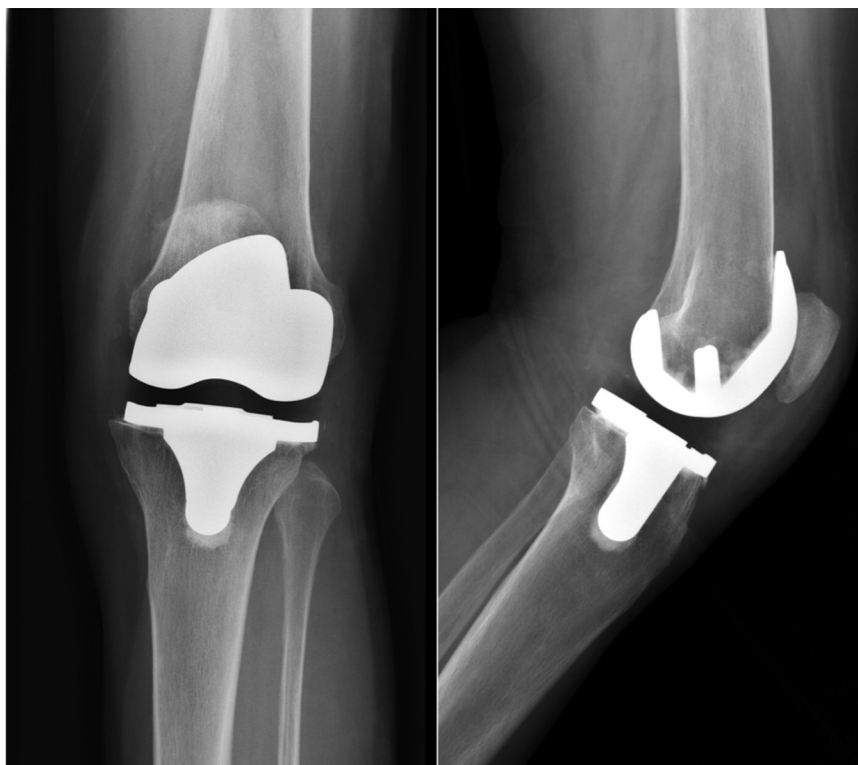A Technetium-99 m methylene diphosphate bone scan was done to assess the patellar viability and showed hypercapture on the left patella with preserved vascularization after 2 years postoperatively (Fig. 5).

## Discussion

Considerable functional disability is associated with chronic post-traumatic patellar dislocation. There is no consensus regarding treatment of neglected patients and there are only very few reports in literature, but TKA is a useful therapy in patients that have developed painful symptomatic gonarthrosis.<sup>4</sup> TKA in this group of patients requires major problems to be addressed: dislocated extensor mechanism and valgus deformity.<sup>2</sup>

Many techniques of proximal (V-Y quadricepsplasty, Z-plasty, Vulpius technique) and distal realignment have been described and are usually required to relocate the patella and realign the extensor mechanism.<sup>3-5</sup> Some authors<sup>8</sup> reported total knee arthroplasty without an attempt to relocate the extensor mechanism as a surgical option, but the effects of neglecting patellar stability on component survival and functional results at long-term follow-up are unknown. In our case isolated lateral release was performed from the muscle fibers of the vastus lateralis to the tibial tuberosity with a satisfactory patellar tracking.

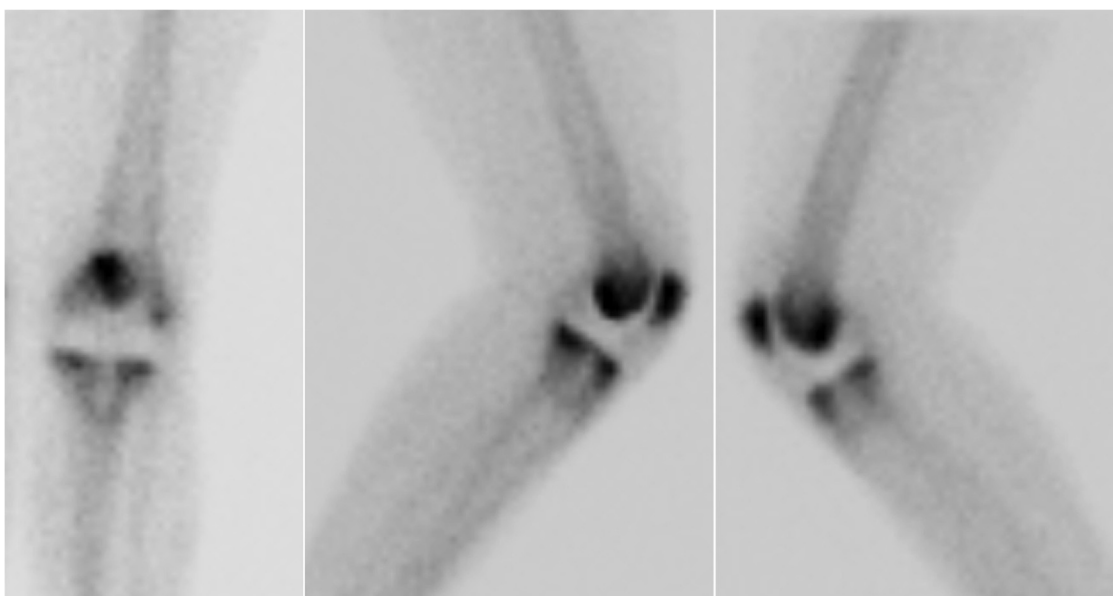
Another concern is the potential for osteonecrosis of the patella due to the extensive release of the extensor mechanism<sup>3,6</sup> with transection of the lateral geniculate arteries (superior and inferior) or due to medial parapatellar approach, which separates the vastus medialis from the patella and results in the loss of the vascular supply by the medial geniculate arteries (superior and inferior) or descending geniculate artery.<sup>1</sup> In our case we performed the



**Fig. 4 - Radiographs of the last follow-up evaluation: anteroposterior and lateral views of the left knee.**

subvastus approach, which permits preservation of the descending geniculate artery, similar that previously described by In et al.,<sup>1</sup> associated with a controlled lateral release, achieving an adequate patellar tracking. One alternative that could also improve tracking would be resurfacing the patella, but due to its small thickness it was left intact.

Even though our case has two-year follow up it might be not enough time to address all possible patello-femoral complications. Noorpuri and Maqsood<sup>6</sup> found a patellar necrosis seven years after a TKA and Helito et al.<sup>9</sup> reported a migrated patella nine years after TKA, that is why surgeons must do a periodic radiographic control of these patients.



**Fig. 5 - Technetium-99 m bone scan showed preserved patellar viability. Anterior, medial and lateral views of the left knee.**

---

**Conflicts of interest**

The authors declare no conflicts of interest.

**REFERENCES**

---

1. In Y, Kong CG, Sur YJ, Choi SS. TKA using the subvastus approach and lateral retinacular release in patients with permanent post-traumatic patellar dislocation: a report of two cases. *Knee Surg Sports Traumatol Arthrosc.* 2009;17:254–9.
2. Bullek DD, Scuderi GR, Insall JN. Management of the chronic irreducible patellar dislocation in total knee arthroplasty. *J Arthroplasty.* 1996;11:339–45.
3. Dao Q, Chen DB, Scott RD. Proximal patellar quadricepsplasty realignment during total knee arthroplasty for irreducible congenital dislocation of the patella. *J Bone Joint Surg Am.* 2010;92:2457–61.
4. Yamanaka H, Kawamoto T, Tamai H, Suzuki M, Kobayashi T, Eguchi Y, et al. Total knee arthroplasty in a patient with bilateral congenital dislocation of the patella treated with a different method in each knee. *Case Rep Orthop.* 2015;2015:890315.
5. Matsushita T, Kuroda R, Kubo S, Mizuno K, Matsumoto T, Kurosaka M. Total knee arthroplasty combined with medial patellofemoral ligament reconstruction for osteoarthritic knee with preoperative valgus deformity and chronic patellar dislocation. *J Arthroplasty.* 2011;26:505.e17–20.
6. Noorpuri BS, Maqsood M. Osteonecrosis of the patella and prosthetic extrusion after total knee arthroplasty. *J Arthroplasty.* 2002;17(5):662–3.
7. Insall JN, Dorr LD, Scott RD, Scott WN. Rationale of the Knee Society clinical rating system. *Clin Orthop Relat Res.* 1989;13–4.
8. Pradhan RL, Watanabe W, Itoi E, Yamada S, Shimada Y, Sato K. Total knee arthroplasty in bilateral congenital dislocation of the patella – a case report. *Acta Orthop Scand.* 2001;72:422–4.
9. Helito CP, Gobbi RG, Tirico LEP, Pecora JR, Camanho GL. Loosening of the patellar component and extra-articular and transcutaneous migration after TKA. *Orthopedics.* 2014;37:e211–3.