



Case Report

Elastic suture (shoelace technique) for fasciotomy closure after treatment of compartmental syndrome associated to tibial fracture[☆]



Paulo Sergio Martins Castelo Branco*, Mauricio Cardoso Junior, Isaac Rotbande, José Antonio Fraga Cirauo, Celso Ricardo Correa de Melo Silva, Paulo Cesar dos Santos Leal

Casa de Saúde Nossa Senhora do Carmo, Rio de Janeiro, RJ, Brazil

ARTICLE INFO

Article history:

Received 6 October 2015

Accepted 14 December 2015

Available online 2 December 2016

Keywords:

Fascia/surgery

Fractures, bone

Tibia

Sutures/utilization

Palavras-chave:

Fáscia/cirurgia

Fraturas ósseas

Tíbia

Sutura/utilização

ABSTRACT

This article reports the use of elastic suture as an adjuvant in surgical wound closure caused by decompressive fasciotomy after compartment syndrome associated with a compound fracture of the tibia. Widely used in other medico-surgical specialties, this technique is unusual in orthopedics surgery, but the simplicity of the procedure and the successful outcome observed in this case allows for its consideration as indicated for situations similar to that presented in this study.

© 2016 Published by Elsevier Editora Ltda. on behalf of Sociedade Brasileira de Ortopedia e Traumatologia. This is an open access article under the CC BY-NC-ND license (<http://creativecommons.org/licenses/by-nc-nd/4.0/>).

Sutura elástica no fechamento de fasciotomia para tratamento de síndrome compartimental associada à fratura da tíbia

RESUMO

Relata-se neste trabalho o uso da sutura elástica como adjuvante no fechamento de ferida cirúrgica provocada por fasciotomia descompressiva após síndrome do compartimento associada a fratura exposta de tíbia. Muito usada em outras especialidades médico-cirúrgicas, a técnica não é habitual em ortopedia; entretanto, a simplicidade do procedimento e o resultado satisfatório observado neste caso permite reputá-la como indicada para situações similares à apresentada neste trabalho.

© 2016 Publicado por Elsevier Editora Ltda. em nome de Sociedade Brasileira de Ortopedia e Traumatologia. Este é um artigo Open Access sob uma licença CC BY-NC-ND (<http://creativecommons.org/licenses/by-nc-nd/4.0/>).

[☆] Study conducted at Casa de Saúde Nossa Senhora do Carmo, Rio de Janeiro, RJ, Brazil.

* Corresponding author.

E-mail: p.castelobranco@ig.com.br (P.S. Branco).

<http://dx.doi.org/10.1016/j.rboe.2016.11.004>

2255-4971/© 2016 Published by Elsevier Editora Ltda. on behalf of Sociedade Brasileira de Ortopedia e Traumatologia. This is an open access article under the CC BY-NC-ND license (<http://creativecommons.org/licenses/by-nc-nd/4.0/>).

Introduction

The elastic suture allows progressive closure of lesions, encompassing all its levels, restoring normal anatomy and all containment and resistance functions of the skin layers without new morbidity factors for the patient. It was first used to bring together the edges of a fasciotomy after compartmental syndrome in the upper limb.¹

This study aimed to report the use of elastic suture for surgical wound closure in a fasciotomy after compartmental syndrome in a leg with traumatic fractures of the proximal third of the tibia and fibula associated with vascular injury.

Case report

Male patient, 30 years old, who had been struck by a passenger vehicle, suffered open fractures of the tibia and fibula. He underwent surgical debridement and lavage, and transarticular external fixation from the femur to the tibia in a public hospital of the State of Rio de Janeiro, and was then transferred to our institution.

During clinical and orthopedic examination, the patient presented mild pain, swelling ++++/4+, suture on the anterior aspect of the leg, with normal capillary perfusion and thin pulse in the affected limb. Routine lower limb and trauma X-rays were made, as well as a CT scan of the injured limb. The images disclosed isolated leg injuries, with comminuted fractures of the proximal third of the tibia and fibula, which were aligned, stabilized, and maintained by a transarticular external fixator (Fig. 1). Laboratory tests indicated alterations from the normal parameters for the following items: neutrophils, 9128; reactive C protein, 34.4; and creatine kinase, 3940.

Over the course of a few hours, the patient developed progressive and severe pain that did not resolve with analgesic use, paresthesia of the ipsilateral hallux, edema, and tense shiny skin. Decompressive fasciotomy was performed. During the surgery, disruption of the tibiofibular trunk was observed and ligated. The fasciotomy was not directly sutured, and the incision site was protected with occlusive dressings (Fig. 2). The patient was then transferred to the intensive care unit for rhabdomyolysis treatment.

The vascular surgery department was consulted and an arteriography of the limb was performed, which showed disruption of tibiofibular trunk compatible with the trauma (Fig. 3); it was observed that the posterior tibial and fibular arteries were perfused by retrograde flow.

Seven days after fasciotomy, the patient presented a clean wound, without signs of infection. At that moment, the elastic suture system was positioned. An elastic band for vascular surgery was attached to the skin with metal clips, which were applied with surgical stapler 0.5 cm from the incision edges, starting at the proximal apex and continuing toward the distal vertex. The wire was attached to one side and passed through the incision to be attached on the opposite side, in a sequence that resembles a zigzag from the proximal to the distal regions – the shoelace technique. After 7 days, an overall approximation of the wound edges was observed; when the elastic

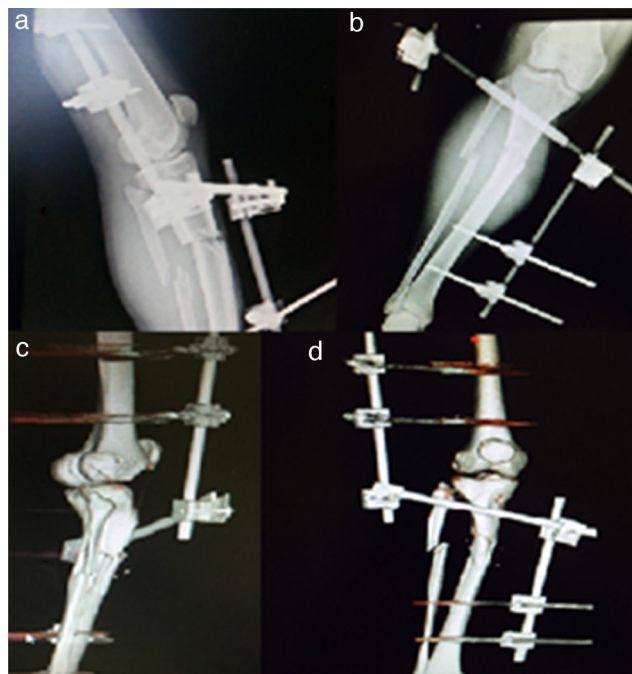

Fig. 1 – (a) Plain lateral view radiograph; (b) plain anteroposterior radiography; (c) lateral view 3D reconstruction CT scan; (d) anteroposterior 3D reconstruction CT scan.

wire and the metal clips were removed, permanent suture was made with nylon 2-0 thread (Fig. 4A-D).

The final treatment of the fracture was conducted with a hybrid external fixator (Fig. 5).

Discussion

The identification of compartment syndrome is not always easy, as peripheral perfusion and arterial pulses are usually observed, not representing good parameters for clinical suspicion. In laboratory tests, an increase in creatine kinase (CK) is observed, which indicates myoglobinuria and suggests the diagnosis.² Fracture of the tibial shaft is one of the most frequent causes of compartment syndrome.³ The repair of its surgical wounds is performed with grafts or large skin flaps; this leads to new wounds, which also demand

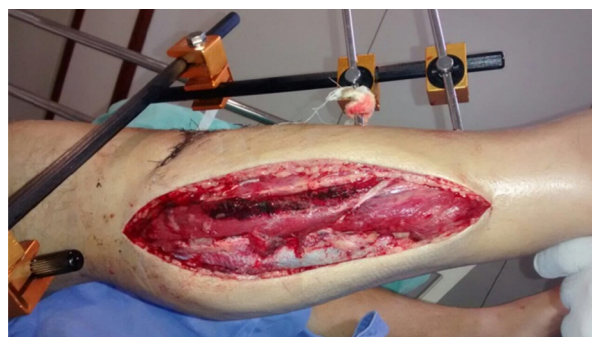

Fig. 2 – Decompressive fasciotomy.

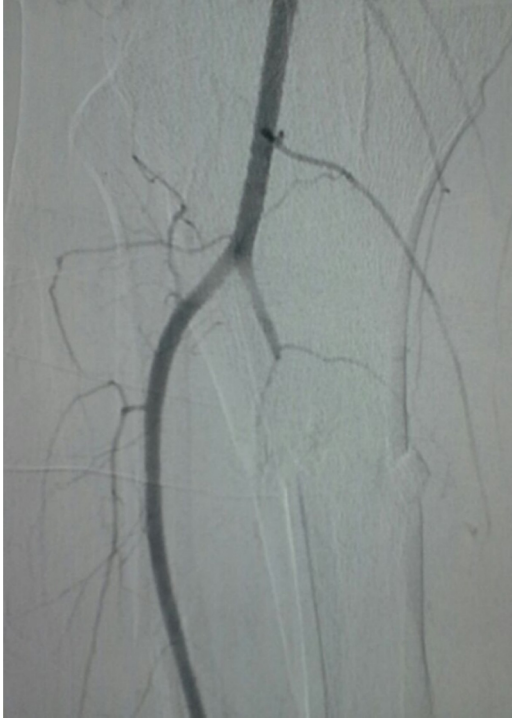

Fig. 3 – Arteriography disclosing vascular injury.

treatment. These measures are accompanied by pain, increased incidence of infections, scar retraction, rejection, and failure.⁴ Proximal fractures of the tibia present increased risk for compartment syndrome.⁵ This condition is more frequent in cases with vascular injury and is characterized by increased blood pressure in regions surrounded by inelastic muscle fascia, altering the local microcirculation and undermining tissue viability. Compartment syndrome is an

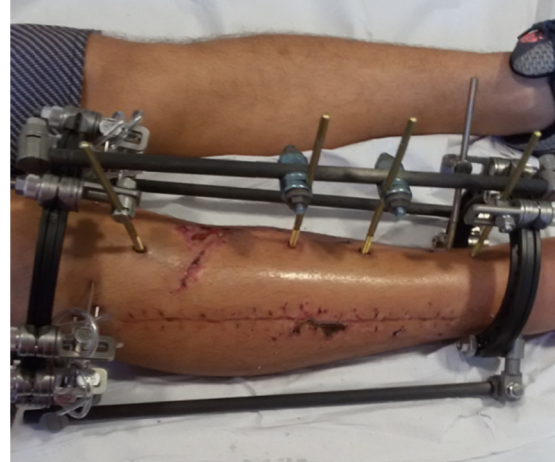


Fig. 5 – Wound aspect 25 days after elastic suture.

orthopedic emergency; decompression fasciotomy is a therapeutic resource for damage control and reducing the risk of severe sequelae.⁶

Severe pain is the earliest objective clinical finding,⁷ and increased pressure and turgid compartment may be observed at palpation. Its severity is associated to the speed in which the pressure increases, its duration and the degree of tissue microcirculation impairment.⁸

The fasciotomy incision represents itself an injury to the patient; furthermore, it increases the risk of infections and the length of hospital stay. Several procedures have been described for closing this type of incision, using various types of materials; there are even reports on the use of properly sterilized common elastic string fixated to the skin adjacent to the incision with surgical suture, providing good approximation of the wound edges in just 5 days after the procedure, with full

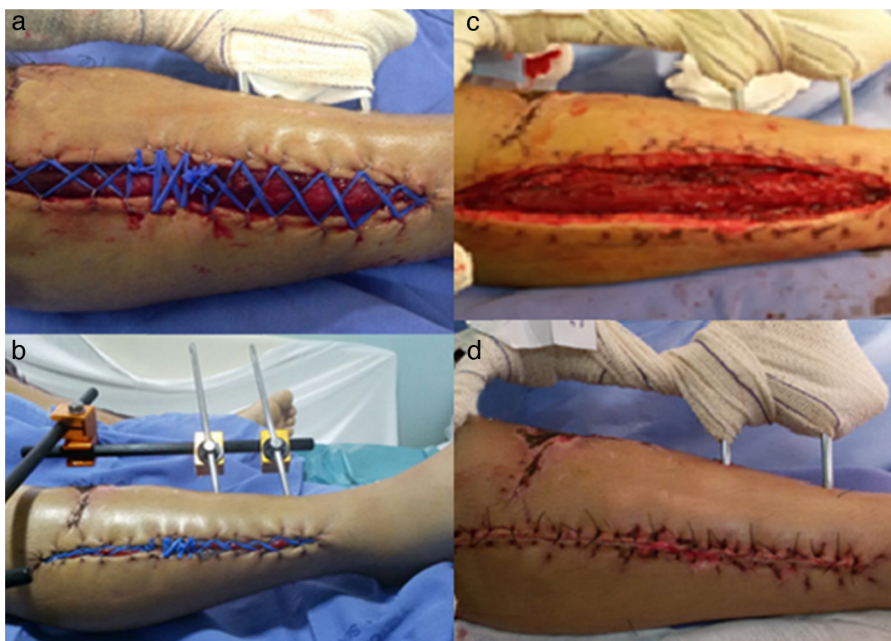

Fig. 4 – (a) Zero-hour elastic suture; (b) 48 h of elastic suture; (c) skin aspect after removal of the elastic suture kept for 7 days; (d) 0-h secondary suture after removal of elastic suture.

closure of the skin 20 days after surgery, without the need for secondary skin suture.⁹ In the present case, the elastic suture effectively assisted the definitive closure of the fasciotomy incision allowing a secondary suture, and waived the need for an autograft skin, being a feasible, easy-to-perform, and low-cost technique.

There is an association between tibial fractures and the development of compartment syndrome. Differential diagnosis from early recognition of signs and symptoms is necessary for initiating appropriate therapy, which improves prognosis and reduces the morbidity rate. Leg fasciotomy closure¹⁰ with elastic suture is cheaper method and contributes to a shorter hospital stay when compared to the vacuum technique.¹¹

Conflicts of interest

The authors declare no conflicts of interest.

REFERENCES

1. Raskin KB. Acute vascular injuries of the upper extremity. *Hand Clin.* 1993;9(1):115-30.
2. Ernest CB, Brennaman BH, Haimovici H. Fasciotomia. In: Haimovici H, Ascer E, Hollier LH, Strandness DE Jr, Towne JB, editors. *Cirurgia vascular: princípios e técnicas.* 4ª ed. São Paulo: Di Livros; 2000. p. 1290-8.
3. McQueen MM, Gaston P, Court-Brown CM. Acute compartment syndrome. Who is at risk? *J. Bone Joint Surg Br.* 2000;82(2):200-3.
4. Cipolla J, Stawicki SP, Hoff WS, McQuay N, Hoey BA, Wainwright G, et al. A proposed algorithm for managing the open abdomen. *Am Surg.* 2005;71(3):202-7.
5. Camacho SP, Lopes RC, Carvalho MR, Carvalho ACF, Bueno RC, Regazzo PH. Análise da capacidade funcional de indivíduos submetidos a tratamento cirúrgico após fratura do planalto tibial. *Acta Ortop Bras.* 2008;16(3):168-72.
6. Blanco MG, López AA, Lorenzo YG. Síndrome compartimental agudo en lesiones de la tibial. *Arq Med Camagüey.* 2008;4(12):1-10.
7. Kojima KE, Ferreira RV. Fraturas da diáfise da tibia. *Rev Bras Ortop.* 2011;46(2):130-5.
8. Sayum Filho J, Ramos LA, Sayum J, Carvalho RT, Ejnisman B, Matsuda MM, et al. Síndrome compartimental em perna após reconstrução de ligamento cruzado anterior: relato de caso. *Rev Bras Ortop.* 2011;46(6):730-2.
9. Petroianu A, Sabino KR, Alberti LR. Closure of large wound with rubber elastic circular strips – case report. *Arq Bras Cir Dig.* 2014;27(1):86-7.
10. Pitta GBB, Santos TFA, Santos FTA, Costa Filho EM. Síndrome compartimental pós-fratura de platô tibial. *Rev Bras Ortop.* 2014;49(1):86-8.
11. Kakagia D, Karadimas EJ, Drosos G, Ververidis A, Trypsiannis G, Verettas D. Wound closure of leg fasciotomy: comparison of vacuum-assisted closure versus shoelace technique. A randomised study. *Injury.* 2014;45(5):890-3.