



Original article

Neurotrophin expression and histomorphometric evaluation in Wistar rats subjected to neural mobilization after compression of the median nerve[☆]



Marieli Araujo Rossoni Marcioli^a, José Luis da Conceição Silva^b,
Lucinéia de Fátima Chasko Ribeiro^c, Rose Meire Costa Brancalhão^c,
Gladson Ricardo Flor Bertolini^{c,*}

^a Universidade Estadual do Oeste do Paraná (Unioeste), Cascavel, PR, Brazil

^b Programa de Ciências Farmacêuticas, Universidade Estadual do Oeste do Paraná (Unioeste), Cascavel, PR, Brazil

^c Programa de Biociências e Saúde, Universidade Estadual do Oeste do Paraná (Unioeste), Cascavel, PR, Brazil

ARTICLE INFO

Article history:

Received 16 January 2017

Accepted 16 March 2017

Available online 4 April 2018

Keywords:

Nerve regeneration

Histology

Intercellular signaling peptides and proteins

Exercise

Median nerve

ABSTRACT

Objective: To evaluate the neurotrophin mRNA expression and axon count in the median nerve of Wistar rats submitted to neural mobilization (NM) after nerve compression.

Methods: Eighteen animals were randomly divided into G1 (nerve compression only), G2 (NM for 1 min), and G3 (NM for 3 min). For NM, the animals were anesthetized and the right scapula received the mobilization, adapted as indicated for humans, on alternate days, from the third to the 13th postoperative (PO) day, totaling six days of therapy. On the 14th PO day, animals were anesthetized and euthanized. Fragments of the median nerve, distal to the compression procedure, were removed for histomorphometric analysis and expression of neurotrophins, nerve growth factor (NGF), and brain-derived neurotrophic factor (BDNF) by RT-PCR.

Results: Histomorphometric analysis revealed differences in the number of axons in the injured side, which was significantly lower in the injured limb nerve compared to the control limb, whereas the RT-PCR analysis showed no significant differences in the expression of NGF or BDNF.

Conclusion: NM treatment did not affect median nerve regeneration, which maintained normal recovery rates.

© 2017 Sociedade Brasileira de Ortopedia e Traumatologia. Published by Elsevier Editora Ltda. This is an open access article under the CC BY-NC-ND license (<http://creativecommons.org/licenses/by-nc-nd/4.0/>).

[☆] Study conducted at Universidade Estadual do Oeste do Paraná (Unioeste), Cascavel, PR, Brazil.

* Corresponding author.

E-mail: gladsonricardo@gmail.com (G.R. Bertolini).

<https://doi.org/10.1016/j.rboe.2018.03.006>

2255-4971/© 2017 Sociedade Brasileira de Ortopedia e Traumatologia. Published by Elsevier Editora Ltda. This is an open access article under the CC BY-NC-ND license (<http://creativecommons.org/licenses/by-nc-nd/4.0/>).

Expressão de neurotrofinas e avaliação histomorfométrica em ratos Wistar submetidos à mobilização neural após compressão do nervo mediano

R E S U M O

Palavras-chave:

Regeneração nervosa
Histologia
Peptídeos e proteínas de sinalização intercelular
Exercício
Nervo mediano

Objetivo: Avaliar a expressão de RNAm de neurotrofinas e a contagem de axônios no nervo mediano de ratos Wistar submetidos à mobilização neural (MN) após compressão nervosa. **Métodos:** Foram divididos aleatoriamente 18 animais em G1 (apenas compressão nervosa), G2 (MN por 1 minuto) e G3 (MN por 3 minutos). Para a MN, os animais foram anestesiados e o membro escapular direito recebeu a mobilização, adaptada da forma indicada para humanos, em dias alternados, do terceiro ao 13º dia de pós-operatório (PO), em seis dias de terapia. No 14º dia PO, os animais foram anestesiados e eutanasiados. Fragmentos do nervo mediano, distais ao procedimento de compressão, foram retirados para análise histomorfométrica e de expressão das neurotrofinas, fator de crescimento do nervo (NGF) e fator de crescimento derivado do cérebro (BDNF) por RT-PCR.

Resultados: A análise histomorfométrica evidenciou diferenças no número de axônios nos lados lesionados, que foi significativamente menor no nervo do membro lesado comparado com o membro controle; por sua vez, a análise por RT-PCR não apontou diferenças significativas na expressão de NGF e nem de BDNF.

Conclusão: O tratamento de MN não afetou a regeneração do nervo mediano, que manteve índices normais de recuperação.

© 2017 Sociedade Brasileira de Ortopedia e Traumatologia. Publicado por Elsevier Editora Ltda. Este é um artigo Open Access sob uma licença CC BY-NC-ND (<http://creativecommons.org/licenses/by-nc-nd/4.0/>).

Introduction

Carpal tunnel syndrome (CTS) is the most common peripheral nerve compression; its incidence is high, being more prevalent in women and the elderly. It presents as a compression of the median nerve when it passes under the transverse carpal ligament,¹ which initially causes blockage of the venous flow followed by an inflammatory reaction, fibrosis, demyelination, and axonal loss. In addition, an increase in the expression of prostaglandin E2, vascular endothelial growth factor, and interleukin 6 is observed. The clinical signs and symptoms of CTS are numbness and paresthesia in the first three fingers and in the radial side of the fourth finger, together with nocturnal arousal due to pain, besides muscle weakness, and atrophy.²

Carpal tunnel decompression surgery is performed in severe and refractory cases. Conservative treatment is used in mild and moderate ones¹ and presents as advantages the reduced number of complications and its lower cost. Non-surgical treatment include the use of a splint, non-hormonal anti-inflammatory drugs, local corticosteroid injections, in addition to physical therapeutic resources such as ultrasound, low-power laser, and exercise.²

The European Guideline for the treatment of CTS indicates that the approach must be multidisciplinary, and that therapeutic exercises such as neural mobilization (NM) can be considered a treatment option.³ The technique has been shown to produce changes in the peripheral nerve excursion⁴ that can prevent or reduce intraneural edema and, thus, rehabilitate normal nerve function.⁵ Although it is already widely used

among physical therapists, the literature does not yet provide evidence of its positive repercussion in the treatment of CTS.⁶

Wallerian degeneration is observed in cases of severe nerve compression, leading to morphological alterations⁷ and subsequent production of neurotrophins.⁸ Neurotrophic factors (such as nerve growth factor [NGF] and brain-derived neurotrophic factor [BDNF]) regulate neuron survival, development, differentiation, and regeneration. They are released by Schwann cells after axonotmesis, and complete neuronal regeneration depends on their expression and trophic conditions favorable to protein synthesis.⁹

Considering some controversies regarding the efficacy of NM directly on the median nerve, the present study checked its effects on the number of axons and in the expression of neurotrophins (NGF and BDNF) in two different times of application of the technique in rats submitted to a nerve compression model.

Material and methods

The present research was experimental. The project was conducted according to the international guidelines of research ethics in animal studies and approved by the Committee of Ethics in Animal Use (opinion No 1012/12). Eighteen male Wistar rats, 14 ± 2 weeks old, were kept on a 12 h photoperiod, 23 ± 1 °C, with water and food *ad libitum*. The animals were randomly divided into three groups: G1 ($n=6$) – submitted to neural compression without treatment (only anesthetized); G2 ($n=6$) – submitted to neural compression and treated with NM for 1 min; G3 ($n=6$) – submitted to neural compression and treated with NM for 3 min.

Median nerve compression

The model presented by Chen et al.¹⁰ was used for median nerve compression, which was made with chromed Catgut 4.0 suture line in 4 points, with an approximate distance of 1 mm, on the medial nerve, in the proximal region of the right elbow. For the surgical nerve compression procedure, the animals were previously anesthetized with a ketamine (50 mg/kg) and xylazine (10 mg/kg) solution.

Median nerve mobilization

For NM (G2 and G3), the animals were anesthetized and the treatment was performed on the right scapular limb, as adapted from the treatment in humans. The animal was placed in dorsal recumbent position, with lateral cervical flexion to the left, depression of the shoulder girdle and slight abduction, external rotation and supination, with maximum extension possible at the elbow and wrist until a resistance to movement was observed. In this position, repeated oscillations of wrist flexion-extensions were made for 1 min (G2) or 3 min (G3). Six sessions were performed on alternate days between the third and 13th postoperative (PO) days.¹¹ On the same days of treatment of G2 and G3, the G1 animals were anesthetized and placed back into their boxes, without undergoing the protocol.

Histomorphometric assessment

At the end of the treatment period, on the 14th PO day, the animals were anesthetized and two fragments of the median nerve were dissected and removed from the region distal to the compression procedure. A nerve fragment of the contralateral limb was also removed for comparison with the injured side; the animals were later euthanized by decapitation. The fragments were fixed in 10% formalin and processed for inclusion in histological paraffin. The material was cross-sectioned into 5 µm-thick slices, and stained with hematoxylin and eosin.

Images of four visual fields were captured in the upper left and right and lower right and left quadrants using a 100× lens, according to the recommendations of Geuna et al.¹² The images were analyzed with the Image-Pro-Plus 6.0 software, in which the number of axons in each quadrant was counted, in an area of 23,184 µm². The animals were subdivided into those that presented normality characteristics (with the presence of myelin sheath and axon) and those that presented degeneration characteristics.

Expression of NGF and BDNF neurotrophins

The distal nerve fragments, stored at -80 °C, were homogenized to isolate the total RNA, using the Trizol reagent (Invitrogen) according to the manufacturer's recommendations. The total extracted RNA was dissolved in water treated with diethylpyrocarbonate (DEPC), quantified at 260/280 nm in a spectrophotometer (Genesys 10S UV-VIS, Thermo Scientific, USA) and subjected to the reverse transcription procedure by RT-PCR technique, according to the scheme shown below. The cDNA was synthesized with the

enzyme Superscript II (Invitrogen) according to the manufacturer's protocol. After cDNA synthesis, PCR amplification was performed; PCR reactions were performed with 2 µl cDNA with the primers G3PDH (control - T°C 53 °C), NGF (T°C 60 °C), and BDNF (T°C 53 °C). The annealing temperatures in parentheses were specific for the primers. A total of 35 PCR cycles (94 °C, annealing temperature: 72 °C) were performed. G3PDH was considered a control gene. The following primer pairs were used: BDNF: 5'AATCCCATGGGTTACACGAA3' and 5'AAGTTGTGCGCAAATGACTG3'; NGF: 5'ATCCACCCACCCAGTCTTCCACAT3' and 5'GGCAGCCTGTTTGTCTGCTGTTGT3'; GAPDH: 5'CCTCTGAAAAGCTGTGGCGT3' and 5'TTGGAGGCCATGTAGGCCAT3

PCR products were separated by 1% agarose gel electrophoresis and visualized by an ultraviolet transilluminator (UVP-USA).

Data analysis

The results were expressed and analyzed through the descriptive and inferential statistics, using the Bioestat 5.0 software. Factorial analysis of variance (ANOVA) was used, and the right and left sides were considered as blocks; the level of significance was set at 5%.

Results

Regarding the axon count, no difference was observed between the treatments ($F=2.97$, $p=0.06$), though differences were observed between the injured and contralateral nerves ($F=9.31$, $p=0.004$), without interaction ($F=0.81$, $p=0.54$). For those animals that presented degeneration, the results were similar, with no differences between the groups ($F=2.13$, $p=0.13$), while differences were observed between the sides ($F=6.25$, $p=0.01$), but without interaction ($F=2.68$, $p=0.08$; Table 1).

Regarding the gene expression of NGF and BDNF, no difference was observed between the groups (Fig. 1). G3PDH (control) gene amplification was observed, demonstrating the constitutive expression of this gene; however, the NGF and BDNF genes were not expressed in amounts detectable in the experiment.

Table 1 – Results of the histomorphometric analysis of the right (R) and left (L) median nerve, in relation to the axon count.

	Right (injured) ^a	Left (control) ^a
<i>Normal</i>		
G1	47.21 ± 44.95	66.50 ± 50.92
G2	73.58 ± 57.05	129.8 ± 34.36
G3	40.96 ± 56.92	104.9 ± 15.11
<i>Degenerated</i>		
G1	8.00 ± 12.43	3.62 ± 8.88
G2	5.17 ± 11.36	0 ± 0
G3	31.96 ± 35.85	0 ± 0

^a Significant differences were observed between sides.

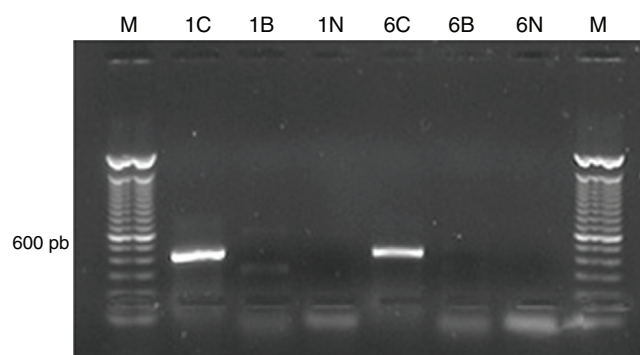


Fig. 1 – Analysis of the products amplified by RT-PCR in 1% agarose gel electrophoresis. M = DNA ladder 100 pb; 1C and 6C cDNA amplified for the G3PDH control gene (amplified band of 430 bp). 1B and 6B: cDNA amplified with the BDNF primers and 1N and 6N: cDNA amplified with the NGF primers. gr1.

A weak amplification of the BDNF gene was observed in group 1B (385 bp amplified band).

Discussion

Although NM is used to gain flexibility,^{13,14} muscle strength,¹⁵ reduce pain,¹⁶⁻¹⁹ and accelerate tissue repair,¹¹ there are controversies regarding the efficacy of this technique in experimental studies in individuals with nerve compression; this might be due to the diversity of protocols used, with different intensities and positioning.⁴ The present study also presented a different protocol, which sought to adapt, in an animal model, the positioning of median nerve stretching done in clinical practice with humans.²⁰

The hypothesis on the benefits of the technique are that it facilitates nerve gliding, reduces adhesions, disperses noxious fluids, increases neural vascularization, and improves axoplasmic flow. However, these mechanisms still require validation.²¹ According to Ginanneschi et al.,²² the tension produced is capable of reducing nerve conduction failures; caution should be exercised when using such techniques in patients with CTS.

Regardless of the time span of 1 or 3 min, NM did not present differences in relation to the control group; smaller values of cells with normal characteristics and a greater amount of cells in degeneration were observed. These findings were consistent with a previous study, in which no improvement was observed with NM in this experimental model of injury, in variables such as nerve fibers and axon diameter, myelin sheath thickness, myelin/axon ratio, and G quotient, as well as there was no nociceptive reduction.¹¹ Despite the lack of improvement in such parameters, it was believed that the mechanical stimulus applied with the MN technique could stimulate the nerve budding²³ and thus increase the number of nerve fibers, as well as the production of neurotrophins with the aim of repairing nervous tissue.²⁴

Santos et al.²⁵ also used nerve compression by tying suture lines, but in the sciatic nerve of rats, and performed NM 14 days after the injury protocol on alternate days for ten

sessions; those authors observed functional improvement of treated animals, recovery of the anterior tibial muscle strength, and increased number of opioid-kappa receptors in the periaqueductal gray matter. In another study, the authors²⁶ observed that the treated animals presented lower nociception (both allodynia and hyperalgesia) and reduced levels of NGF in the dorsal root ganglia ipsilateral to the lesion, which could be a possible reason for the reduction in pain.

Nonetheless, another study from the same group²⁷ indicated that neural mobilization produced some recovery characteristics, such as a greater number of axons with normal thickness myelin sheaths and less adhesions between axons, but locally there was an increase in the NGF concentration evaluated by Western blotting.

In the present study, the authors also sought to analyze the expression of neurotrophins at the compression site; however, unlike the above-mentioned authors, no differences were observed in their expression with the use of the RT-PCR technique. It should be noted that neural mobilization was used early, that is, in the first two weeks after compression through suture lines; it would be possible to delay treatment onset and it could be beneficial. This is another limitation of the study and a possible theme for future studies.

Conclusion

With the protocols used, NM did not favor nerve regeneration in a median nerve compression model of Wistar rats, which maintained normal recovery rates.

Conflicts of interest

The authors declare no conflicts of interest.

Acknowledgments

To the Physical Rehabilitation Center of Unioeste for the partial funding of this research.

REFERENCES

- Gillig JD, White SD, Rachel JN. Acute carpal tunnel syndrome. *J Am Acad Orthop Surg.* 2008;16(3):276-82.
- Li Z-J, Wang Y, Zhang H-F, Ma X-L, Tian P, Huang Y. Effectiveness of low-level laser on carpal tunnel syndrome: a meta-analysis of previously reported randomized trials. *Medicine (Baltimore).* 2016;95(31):e4424. Available from: <http://www.ncbi.nlm.nih.gov/pubmed/27495063>.
- Huisstede BM, Fridén J, Coert JH, Hoogvliet P. Carpal tunnel syndrome: hand surgeons, hand therapists, and physical medicine and rehabilitation physicians agree on a multidisciplinary treatment guideline—results from the European HANDGUIDE study. *Arch Phys Med Rehabil.* 2014;95(12):2253-63.
- Coppieters MW, Andersen LS, Johansen R, Giskegjerde PK, Høivik M, Vestre S, et al. Excursion of the sciatic nerve during nerve mobilization exercises: an in vivo cross-sectional study using dynamic ultrasound imaging. *J Orthop Sports Phys Ther.* 2015;45(10):1-23.

5. Efstathiou MA, Stefanakis M, Savva C, Giakas G. Effectiveness of neural mobilization in patients with spinal radiculopathy: a critical review. *J Bodyw Mov Ther.* 2015;19(2):205-12.
6. Silva AKC, Assis T, de O. Influência da mobilização neural na reabilitação da síndrome do túnel do carpo: uma revisão sistemática. *Rev Bras Ciênc Saúde.* 2011;9(28):43-7.
7. Mazzer PY, Barbieri CH, Mazzer N, Fazan VP. Morphologic and morphometric evaluation of experimental acute crush injuries of the sciatic nerve of rats. *J Neurosci Methods.* 2008;173(2):249-58.
8. Cámara-Lemarroy CR, Guzmán-de la Garza FJ, Fernández-Garza NE. Molecular inflammatory mediators in peripheral nerve degeneration and regeneration. *Neuroimmunomodulation.* 2010;17(5):314-24.
9. Levi-Montalcini R. The nerve growth factor: thirty-five years later. *EMBO J.* 1987;6(9):2856.
10. Chen J, Lue J, Lin L, Huang C, Chiang RP, Chen C, et al. Effects of pre-emptive drug treatment on astrocyte activation in the cuneate nucleus following rat median nerve injury. *Pain.* 2010;148(1):158-66.
11. Marcioli MA, Coradini JG, Kunz RI, Ribeiro LD, Brancalhão RM, Bertolini GR. Nociceptive and histomorphometric evaluation of neural mobilization in experimental injury of the median nerve. *Sci World J.* 2013;2013:1-6.
12. Geuna S, Tos P, Guglielmono R, Battiston B, Giacobini-robecchi MG. Methodological issues in size estimation of myelinated nerve fibers in peripheral nerves. *Anat Embryol.* 2001;204(1):1-10.
13. Sharma S, Balthillaya G, Rao R, Mani R. Short term effectiveness of neural sliders and neural tensioners as an adjunct to static stretching of hamstrings on knee extension angle in healthy individuals: a randomized controlled trial. *Phys Ther Sport.* 2016;17:30-7.
14. Nunes MK, Santos GF, Silva DC, Freitas AC, Henriques IF, Andrade PM, et al. Acute effects of neural mobilization and infrared on the mechanics of the median nerve. *J Phys Ther Sci.* 2016;28(6):1720-3.
15. Araujo BF, do Nascimento CM, Busarello FO, Moreira NB, Baroni MP, de Carvalho AR, et al. Assessment of handgrip strength after neural mobilization. *Rev Bras Med Esp.* 2012;18(4):242-5.
16. Beltran-Alacreu H, Jiménez-Sanz L, Fernández Carnero J, La Touche R. Comparison of hypoalgesic effects of neural stretching vs neural gliding: a randomized controlled trial. *J Manip Physiol Ther.* 2015;38(9):644-52.
17. Silva LI, Rocha BP, Antunes JS, Karvat J, Kakihata CMM, Mattjie TF, et al. Evaluation of the pressure pain threshold after neural mobilization in individuals with sciatica. *Eur J Physiother.* 2013;15:146-50.
18. Frutos AL, Araujo BF, Silva EAA, Bertolini GRF. Pain threshold assessment in relation to neural mobilization therapy. *Acta Sci Health Sci.* 2012;34:303-8.
19. Kim MK, Cha HG, Ji SG. The initial effects of an upper extremity neural mobilization technique on muscle fatigue and pressure pain threshold of healthy adults: a randomized control trial. *J Phys Ther Sci.* 2016;28(3):743-6.
20. Oliveira Junior F, Teixeira AH. Mobilização do sistema nervoso: avaliação e tratamento. *Fisioter Mov.* 2007;20(3):41-53.
21. Ellis RF, Hing WA. Neural mobilization: a systematic review of randomized controlled trials with an analysis of therapeutic efficacy. *J Man Manip Ther.* 2008;16(1):8-22.
22. Ginanneschi F, Cioncoloni D, Bigliuzzi J, Bonifazi M, Lorè C, Rossi A. Sensory axons excitability changes in carpal tunnel syndrome after neural mobilization. *Neurol Sci.* 2015;36(9):1611-5.
23. Dahlin LB. The biology of nerve injury and repair. *J Am Soc Surg Hand.* 2004;4(3):143-55.
24. Boucher TJ, McMahon SB. Neurotrophic factors and neuropathic pain. *Curr Opin Pharmacol.* 2001;1(1):66-72.
25. Santos FM, Grecco LH, Pereira MG, Oliveira ME, Rocha PA, Silva JT, et al. The neural mobilization technique modulates the expression of endogenous opioids in the periaqueductal gray and improves muscle strength and mobility in rats with neuropathic pain. *Behav Brain Funct.* 2014;10(19). [PMC4050394](https://doi.org/10.1186/1744-8069-8-57).
26. Santos FM, Silva JT, Giardini AC, Rocha PA, Achermann AP, Alves AS, et al. Neural mobilization reverses behavioral and cellular changes that characterize neuropathic pain in rats. *Mol Pain.* 2012;57(8), <http://dx.doi.org/10.1186/1744-8069-8-57>.
27. da Silva JT, Santos FM, Giardini AC, Martins DO, de Oliveira ME, Ciena AP, et al. Neural mobilization promotes nerve regeneration by nerve growth factor and myelin protein zero increased after sciatic nerve injury. *Growth Factors.* 2015;33(1):8-13.