



## Original Article

# Surgical treatment of femoral head fractures through previously controlled hip luxation: four case series and literature review<sup>☆</sup>



Guilherme Augusto Stirma\*, Christiano Saliba Uliana, Weverley Rubele Valenza, Marcelo Abagge

Universidade Federal do Paraná (UFPR), Hospital do Trabalhador SESA, Curitiba, PR, Brazil

## ARTICLE INFO

## Article history:

Received 6 March 2017

Accepted 28 March 2017

Available online 5 April 2018

## Keywords:

Hip fracture

Femur head

Hip dislocation

## ABSTRACT

**Objective:** To report a series of cases of patients treated by fracture of the femoral head through the Ganz pathway with controlled dislocation of the hip.

**Method:** All patients who were surgically treated with a Ganz access route for femoral head fractures were identified in a tertiary referral service for trauma. A review of medical records with X-rays and CT scans was carried out. The radiographic evaluation was classified according to Pipkin and the functional evaluation was performed through the application of the modified Harris Hip Score. Data regarding the quality of reduction, type of fixation, and postoperative complications were collected.

**Results:** The sample consisted of three men and one woman, with a mean age of 30 years (20–51). Regarding Pipkin's classification, two cases were type I, one type II, and one type IV. Regarding the Harris Hip Score, an average of 65.75 points was obtained (range: 20–86). All cases had anatomical reduction in the intraoperative period. One case presented post-traumatic sciatic nerve praxis and evolved with infection at the surgical site.

**Conclusion:** Surgical treatment of femoral head fractures through controlled hip dislocation is a viable option and can be considered an alternative to classical approaches.

© 2018 Published by Elsevier Editora Ltda. on behalf of Sociedade Brasileira de Ortopedia e Traumatologia. This is an open access article under the CC BY-NC-ND license (<http://creativecommons.org/licenses/by-nc-nd/4.0/>).

## Tratamento cirúrgico das fraturas da cabeça femoral através da luxação anterior controlada do quadril – Série de quatro casos e revisão da literatura

## RESUMO

**Objetivo:** Relatar uma série de casos de pacientes com fratura da cabeça femoral tratados através da via de Ganz com luxação controlada do quadril.

**Método:** Identificaram-se todos os pacientes tratados cirurgicamente com via de acesso de Ganz para fraturas da cabeça femoral em um serviço terciário referência em trauma. Fez-se

## Palavras-chave:

Fraturas do quadril

Cabeça do fêmur

Luxação do quadril

<sup>☆</sup> Study conducted at Hospital do Trabalhador SESA (UFPR), Grupo de Trauma Ortopédico, Curitiba, PR, Brazil.

\* Corresponding author.

E-mail: [guilhermeaugusto89@hotmail.com](mailto:guilhermeaugusto89@hotmail.com) (G.A. Stirma).

<https://doi.org/10.1016/j.rboe.2018.03.013>

2255-4971/© 2018 Published by Elsevier Editora Ltda. on behalf of Sociedade Brasileira de Ortopedia e Traumatologia. This is an open access article under the CC BY-NC-ND license (<http://creativecommons.org/licenses/by-nc-nd/4.0/>).

uma revisão de prontuários com as radiografias e tomografias computadorizada. A avaliação radiográfica foi classificada de acordo com Pipkin e a avaliação funcional foi feita com o *Harris Hip Score* modificado. Foram coletados dados referentes à qualidade de redução, ao tipo de fixação e às complicações pós-operatórias.

**Resultados:** A amostra foi composta por três homens e uma mulher, com média de 30 anos (20-51). Em relação à classificação de Pipkin, dois casos eram do tipo I, um do tipo II e um do tipo IV. Em relação ao *Harris Hip Score*, observou-se uma média de 65,75 pontos (20 a 86). Todos os casos obtiveram redução anatômica no intraoperatório. Um caso apresentou praxia do nervo ciático pós-trauma e evoluiu com infecção do sítio cirúrgico.

**Conclusão:** O tratamento cirúrgico das fraturas da cabeça do fêmur através da luxação controlada do quadril é uma opção viável e pode ser considerada uma opção às vias clássicas de abordagem.

© 2018 Publicado por Elsevier Editora Ltda. em nome de Sociedade Brasileira de Ortopedia e Traumatologia. Este é um artigo Open Access sob uma licença CC BY-NC-ND (<http://creativecommons.org/licenses/by-nc-nd/4.0/>).

## Introduction

Femoral head fractures are rare injuries; they are almost always associated with high-energy trauma, such as automobile accidents. Approximately 95% of the patients require hospital treatment, to treat the fracture itself or associated injuries.<sup>1,2</sup>

Traditionally, the Kocher-Langenbeck and the Smith-Petersen anterior approach are the two access routes used in femoral head fracture reduction and fixation.<sup>3-5</sup>

More recently, the controlled hip dislocation technique was introduced for the treatment of traumatic injuries of this joint. This approach was originally described in the early 1990s by Reinhold Ganz for the open treatment of femoroacetabular impact. It allows visualization of the entire circumference of the femoral head, with minimal risks of vascular supply injury. Another advantage is the facility to directly reduce the fragments and to secure them with appropriate implants. This access requires greater trochanter osteotomy and controlled anterior dislocation of the femoral head.<sup>1</sup> To date, few studies have described the results and the evolution of this approach for femoral head fractures.<sup>4</sup>

This study is aimed at reporting the cases of patients with femoral head fracture treated through the Ganz approach with controlled hip dislocation, assessing their radiographic and functional clinical evolution.

## Methods

This project was submitted to the ethics committee in research of human beings and was approved on April 6, 2016 under the No. 54336716.2.0000.5225.

Based on the procedure codes, the records book of surgeries and medical charts, all patients surgically treated with Ganz approach for femoral head fractures in a tertiary referral unit for trauma were included.

Physical and electronic records were reviewed; the radiographs and computed tomography images of all

cases were retrieved. The analysis consisted in identifying the patient's age at the time of trauma, gender, trauma mechanism, date of surgery, associated injuries, surgical time, complications during surgery, number and types of screws used, complications, and follow-up (range of motion assessment and follow-up duration). The radiographic evaluation, whether printed or in the database of images of the radiology department, was classified using the Pipkin classification.

Functional assessment was performed using the modified Harris Hip Score.<sup>6</sup>

The inclusion criteria comprised of cases surgically treated for femoral head fractures in which the Ganz approach was used. Patients with femoral head fracture treated by methods other than the controlled dislocation technique were excluded.

## Surgical technique

The patient is placed in a lateral decubitus position. After routine asepsis, antisepsis and lower limb preparation, a 20 cm incision is made, centered on the greater trochanter apex. The subcutaneous tissue is dissected and the fascia lata is opened.

Superficial muscular dissection is made in the intermuscular plane between the fascia lata tensor and the anterior border of the gluteus maximus muscle. The internal rotation of the hip exposes the posterior border of the greater trochanter, the external rotators, and the posterior portion of the gluteus medius muscle.

The osteotomy demarcation is made from the postero-superior border of the greater trochanter, extending to the border of the vastus lateralis. The trochanteric osteotomy is performed along this line. The bone is cut with an osteotome or electric saw, in a posterior to anterior direction. The thickness of the cut should be between 1 and 1.5 cm. The external rotators are preserved and remain inserted to the greater trochanter during the procedure. The main branch of the medial femoral circumflex artery is located distal to the

obturator externus muscle, and must be protected throughout the procedure.<sup>7</sup>

The detached fragment is mobilized anteriorly, the remnant of the gluteus medius is released from the apex of the greater trochanter, and the upper border of the piriform tendon is identified. The gluteus minimum is then dissected from the posterior capsule. The hip is flexed and externally rotated. Flexion is performed in a progressive manner to allow visualization of the joint capsule. The capsule is then incised from the acetabular ridge. A Z-shaped capsulotomy is made; the flap is positioned toward the medial border of the femoral neck. The incision begins at the anterior border of the acetabulum and is curved posteriorly along the acetabular border, proximal to the labrum. At this point, the joint is exposed. The teres femoris ligament is cut, and the maneuver is performed in a combined external rotation and flexion for controlled dislocation of the hip. A hook may be used to facilitate the femoral head dislocation. After the dislocation, the head is inspected at 360°; the remaining fragments in the acetabulum are identified. In the acetabular portion, possible ridge impingements or labral lesions that may occur adjacent to the fracture edges are identified.<sup>7</sup>

The deflected fragments are reduced manually or with the aid of bone tongs; they are temporarily secured with steel wires that can be used for the insertion of headless cannulated screws. Comminuted and intra-articular fragments are debrided. Labral avulsions in the acetabulum are repaired.<sup>7</sup>

The femoral head is repositioned in the acetabulum with internal rotation and hip extension. The joint capsule is repaired with Vicryl sutures. The greater trochanter is secured with two 4.5 mm cortical screws. The fascia lata and the subcutaneous cellular tissue are closed with absorbable sutures and the skin, with non-absorbable sutures.

## Results

During the period of time studied, four patients with femoral head fracture were surgically treated with controlled hip dislocation. The sample consisted of three men and one woman, with a mean age of 30 years (20–51). The right side was affected in three cases.

All fractures were caused by high-energy trauma: three cases of automobile collision and one fall from a height (10 m).

Two cases were classified as Pipkin type I (fracture below the fovea), one as type II (fracture above the fovea), and one as type IV (association with acetabulum fracture).

The mean surgical time was 140 min (75–275), from access to skin closure. In all cases, at least one associated lesion was identified. The associated lesions were ankle fractures, compound fractures of the distal third of the radius, rib fracture, hand fracture, olecranon fracture, and abdominal lesions. Sciatic neurapraxia was observed in one case.

The greater trochanter osteotomy was secured with 4.5 mm cortical screws in three cases and with cancellous screws in one case. At eight weeks postoperatively, all osteotomies were consolidated.

**Table 1 – HHS score vs. follow-up of the four patients.**

HHS	86	73	84	20
Follow-up	9 months	7 months	2 years and 6 months	1 year

The implants used for fracture fixation were Herbert screws in two cases, 2.0 mm cortical screws in one case, and 2.7 mm cortical screws in one case.

The longest follow-up was two years and six months, and the mean was one year and three months. One case progressed to deep surgical site infection. After treatment of the infection, this patient underwent total hip arthroplasty after one year of follow-up. One case evolved with heterotopic calcification. No cases of femoral head necrosis were identified.

The mean Harris Hip Score was 65.75 points (20–86). Table 1 shows the score of each patient at last follow-up.

## Discussion

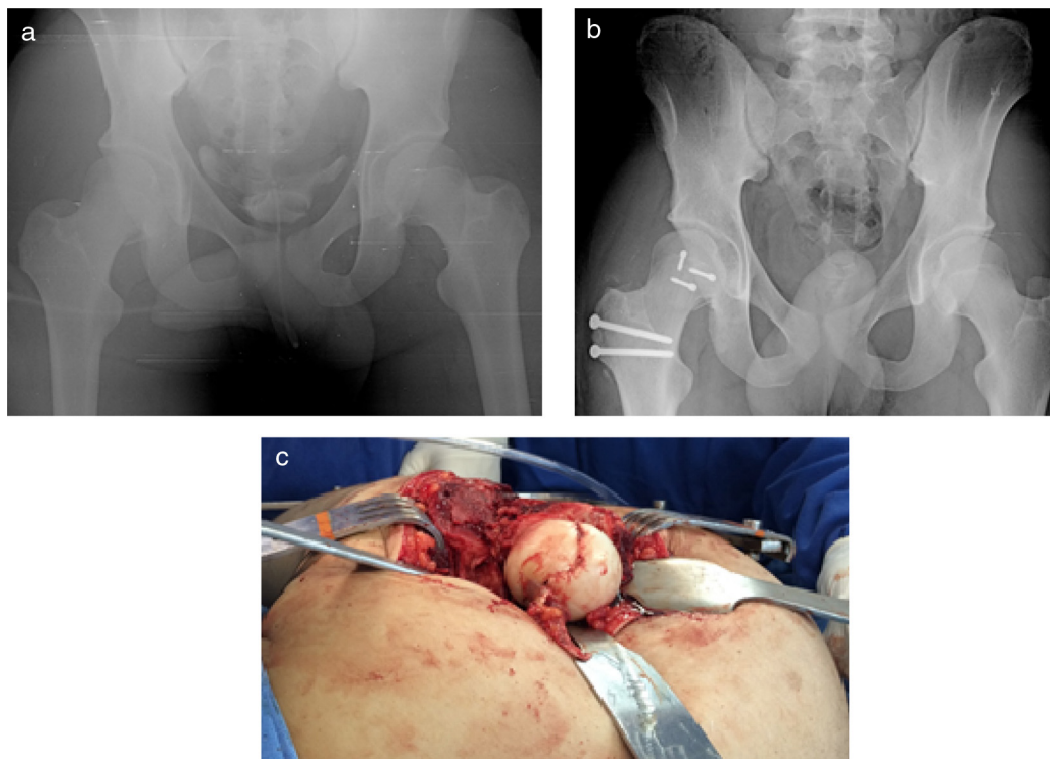
Most femoral head fractures are treated surgically. However, there is a controversy regarding which surgical approach provides lower rates of complications and better results.<sup>3</sup>

The Ganz approach, originally described for the open treatment of femoroacetabular impact, presents some advantages when compared to other access routes. This technique provides a better visualization of the entire circumference of the femoral head, with minimal risks of vascular supply injury and a lower percentage of postoperative complications.<sup>1,5</sup>

In the present series of four cases, it was observed that all the patients suffered high-energy trauma. This finding is in agreement with data from the study by Henle et al.,<sup>8</sup> which showed that of the 13 femoral head fractures studied, 12 were caused by trauma mechanisms similar to those of the present cohort (fall from a height, or motorcycle or car collision).

The authors believe that the main advantage of the controlled dislocation technique is the wide visualization of the femoral head and fracture fragments. Through this approach, the fragments are easily manipulated, reduced, and secured. In spite of the authors' initial experience, anatomical reduction and fracture fixation with the appropriate implants were achieved in all procedures.

In general, the literature demonstrates good results in the treatment of femoral head fractures with controlled hip dislocation. Massè et al.<sup>4</sup> studied 13 patients, and only one presented a poor outcome. Henle et al.<sup>8</sup> reported that of 12 patients treated, ten presented good or excellent results in follow-up, classified in accordance with the hip function score by Merle d'Aubigne and Postel *apud* Ugino et al.<sup>9</sup> In the present series, the mean Harris Hip Score was 65.75 (20–86). A poor result was observed in one case, with a Harris Hip Score of 20 points. This patient presented sciatic neurapraxia in the preoperative period and evolved with surgical site infection and the need for conversion to total hip arthroplasty after one year of follow-up. Two other patients presented good results (patient 1; Fig. 1A–C), with Harris Hip Score above 80 points.



**Fig. 1 – Patient 1. (A) Femoral head fracture, Pipkin I; (B) 15 days postoperative; (C) intraoperative photograph.**

Femoral head necrosis may be caused by damage to the artery at the time of trauma or surgical procedure. This complication may occur independently of the surgical approach; the incidence reported in the literature ranges from 8% to 24%.<sup>4-10</sup> In the present study, no cases of necrosis were observed, but a fact to be considered is that one year and three months of follow-up is rather short, as this complication can occur up to two years after fracture and surgical correction.

One of the limitations of this case series is the number of patients included. However, it is important to note that femoral head fractures are rare injuries and that the Ganz access has only gained popularity in recent years. This study is aimed at presenting an alternative to the traditional approaches to treat this rare injury, as well as the preliminary clinical results. Other cases with the same type of injury were operated at this hospital during the same period of time as this study, but were excluded because a Smith-Petersen access route was used.

The best access for surgical treatment of femoral head fractures remains controversial, but there is increasing evidence in the literature that supports the use of the Ganz approach as feasible and advantageous.

## Conclusion

Surgical treatment of femoral head fractures through controlled hip dislocation is a viable option and may be an alternative to the classic approaches.

## Conflicts of interest

The authors declare no conflicts of interest.

## REFERENCES

1. Gaçala J. Anterior approach according to Ganz surgical dislocation of hip joint. *Ortop Traumatol Rehabil.* 2010;12(6):493-503.
2. Bucholz RW, Heckman JD, Court-Brown CM, Tornetta P 3rd. Hip dislocations and fractures of the femoral head. In: Bucholz RW, Heckman JD, Court-Brown CM, Tornetta P 3rd, editors. *Rockwood and Green's fractures in adults.* 7th ed. Philadelphia: Lippincott Williams & Wilkins; 2009. p. 3-82.
3. Viveiros AMC, Silva AC, Meirelles AV, Costa Junior HL, Santos RN, Gomes SBS, et al. Abordagem às lesões traumáticas do quadril com técnica de luxação controlada da cabeça femoral. In: *Anais do XVII Congresso Brasileiro de Trauma Ortopédico.* 2011.
4. Massè A, Aprato A, Alluto C, Favuto M, Ganz R. Surgical hip dislocation is a reliable approach for treatment of femoral head fractures. *Clin Orthop Relat Res.* 2015;473(12):3744-51.
5. Mostafa MF, El-Adl W, El-Sayed MA. Operative treatment of displaced Pipkin type I and II femoral head fractures. *Arch Orthop Trauma Surg.* 2014;134(5):637-44.
6. Guimarães RP, Alves DPL, Silva GB, Bittar ST, Ono NK, Honda E, et al. Translation and cultural adaptation of the Harris Hip Score into Portuguese. *Acta Ortop Bras.* 2010;18(3):142-7.

- 
7. Tornetta P 3rd. Hip dislocations and fractures of the femoral head. In: Bucholz RW, Heckman JD, Court-Brown CM, Tornetta P 3rd, editors. *Rockwood and Green's fractures in adults*. 7th ed. Philadelphia: Lippincott Williams & Wilkins; 2009. p. 30-1.
  8. Henle P, Kloen P, Siebenrock KA. Femoral head injuries: which treatment strategy can be recommended? *Injury*. 2007;38(4):478-88.
  9. Kazue UF, Moraes RC, Lédio ADP, Pereira GR, Kiyoshi HE, Keiske ON, et al. Avaliação da confiabilidade do Método Merle d'Aubigné e Postel Modificado. *Acta Ortop Bras*. 2012;20(4):213-7.
  10. Solberg BD, Moon CN, Franco DP. Use of a trochanteric flip osteotomy improves outcomes in Pipkin IV fractures. *Clin Orthop Relat Res*. 2009;467:929-33.