


Simultaneous Bilateral Knee Varus Stress Radiographic Technique*

Técnica radiográfica de estresse em varo bilateral simultâneo

Felipe Moreira Borges¹ Jacqueline Vieira de Castro¹ Nicholas Kennedy² Marcio Balbinotti Ferrari¹
Joao Luiz Ellera Gomes¹ 

¹Hospital de Clinicas de Porto Alegre, Porto Alegre, Brazil

²Steadman Philippon Research Institute, Vail, United States

Address for correspondence Joao Luiz Ellera Gomes, Hospital de Clinicas de Porto Alegre, Porto Alegre, RS, Brazil (e-mail: joelgo.voy@terra.com.br).

Rev Bras Ortop 2019;54:104–108.

Abstract

Varus stress radiographs are reported as an effective and cost-beneficial diagnostic and decision-making tool for lateral knee injuries, both in the acute and chronic settings. The opening of the lateral compartment is reported to vary according to the number of structures injured, helping to differentiate isolated fibular collateral ligament injury from grade-III posterolateral corner injury. The conventional technique requires the physician or another healthcare provider to apply manual varus stress while obtaining the radiograph on one knee at a time. The present study aimed to describe, in detail, the preferred method of the authors to assess the opening of the lateral compartment in both knees simultaneously, which also avoids the need for the examiner to be present in the imaging room.

Keywords

- ▶ knee
- ▶ fractures
- ▶ stress
- ▶ radiography

Resumo

As radiografias de estresse em varo são descritas como uma técnica efetiva e econômica de diagnóstico e tomada de decisão em lesões laterais do joelho, tanto no contexto agudo quanto crônico. A abertura do compartimento lateral varia de acordo com o número de estruturas danificadas, ajudando a diferenciar lesões isoladas do ligamento colateral fibular das lesões do canto posterolateral de grau III. A técnica convencional exige que o médico ou outro profissional de saúde aplique estresse em varo manual ao obter a radiografia em um joelho de cada vez. O presente estudo teve como objetivo descrever, em detalhes, o método preferido dos autores para avaliar a abertura do compartimento lateral em ambos os joelhos simultaneamente, o que também evita a necessidade da presença do examinador na sala de imagem.

Palavras-chave


- ▶ joelho
- ▶ fraturas
- ▶ estresse
- ▶ radiografia
- ▶ radiografia

Introduction

The posterolateral corner is an important knee ligamentous structure to knee stability, preventing posterior translation and varus/external rotation.¹ Injuries of this knee ligamentous

complex were considered rare injuries in the past, however, a better understanding of the anatomy and better diagnostic resources are suggesting that the real incidence of these injuries are higher.² A prospective study estimates that these lesions are presented in 16% of all ligament knee injuries and 9.1% of all acute knee injuries with hemarthrosis.³ Due to the severe consequences of untreated injuries, the correct diagnosis and treatment of these ligament injuries are essential to avoid future sequelae. A thorough physical examination combined with associated imaging techniques are essential to correctly

* Investigation performed at the Hospital de Clinicas de Porto Alegre, Porto Alegre, RS, Brazil. Published by Elsevier Editora Ltda. © 2017 Sociedade Brasileira de Ortopedia e Traumatologia.

 Joao Luiz Ellera Gomes's ORCID: is <https://orcid.org/0000-0001-7300-4449>.

received
July 11, 2017
accepted
July 27, 2017

DOI <https://doi.org/10.1016/j.rboe.2017.07.009>.
ISSN 0102-3616.

Copyright © 2019 by Sociedade Brasileira de Ortopedia e Traumatologia. Published by Thieme Revinter Publicações Ltda, Rio de Janeiro, Brazil

License terms



diagnose these injuries. The purpose of this technical note is to describe in detail our preferred varus stress radiographic technique to evaluate these injuries.

Technique

Following physical examination of the knee, the patients who would benefit from varus stress radiographs are selected. The patient is brought to the radiographic room and placed in supine position. Following this, the patient is asked to extend the limbs and, place both knees and ankles together. During this period the patient is asked to relax both limbs. A Velcro belt is used at the supramalleolar site, keeping both medial malleoli in contact with each other (► Fig. 1). During this period, it is important to check the anatomic position of the limbs is correct by ensuring that both patellas are perpendicular to the radiographic table. Following this, attention is then turned to the knee.

Soft Wedge Positioning

Once the Velcro strip is placed around the ankles, at the supramalleolar level, a soft wedge (► Fig. 2) is used to apply the varus stress on the knee. Ensuring the correct positioning of the limbs, the soft wedge (made of Ethylene vinyl acetate) is gently placed between the knees that were in close contact. The smaller aspect of the wedge (tip) is directed proximally, while the base of the wedge should remain at the tibial tuberosity level. The physician must ensure that the medial malleoli are in contact and the Velcro belt did not change the position. When inserting the soft wedge between the thighs, the limbs tend to

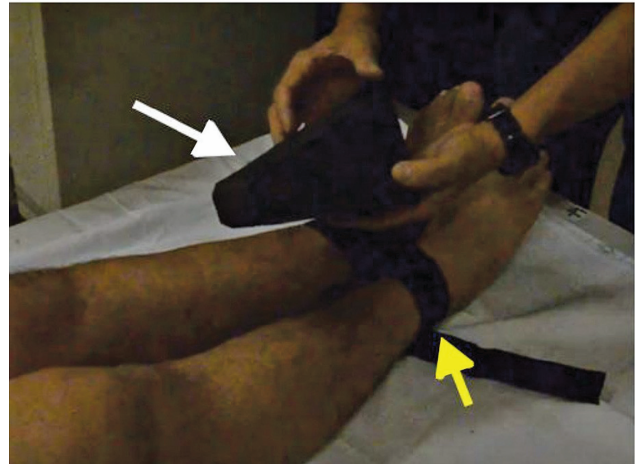
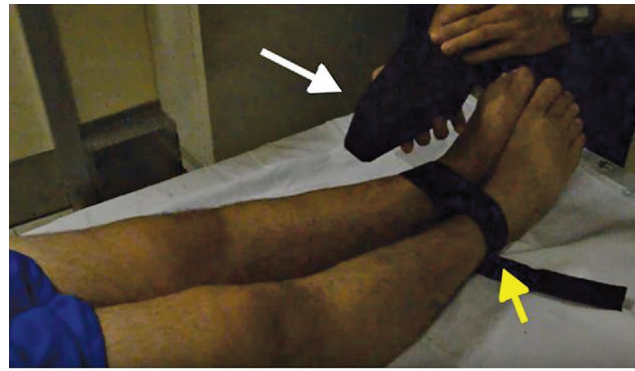
Fig. 2 Following the application of the Velcro strip (yellow arrows) around both ankles at the supramalleolar level, attention is turned to the application of varus stress on the knee. A soft wedge (white arrows), made of Ethylene vinyl acetate, is placed between the knees. It is important to ensure that the base of the wedge is positioned at the tibial tuberosity level and the tip of the wedge is at the distal femur level.

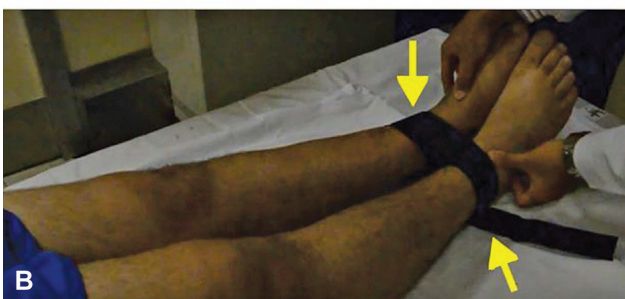
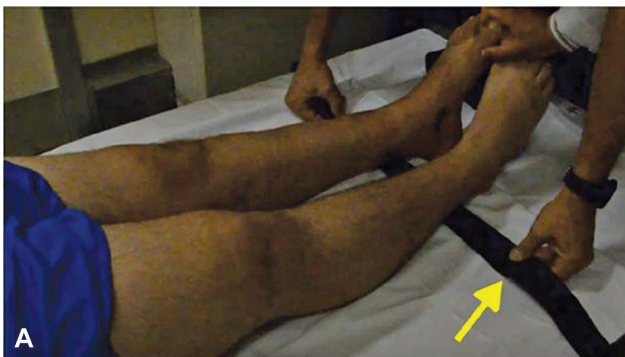
Fig. 1 The patient is placed supine on the radiographic table and asked to extend the knees. The ankles and thighs of both limbs are placed in contact. Following this, a Velcro belt (yellow arrow) is used at the supramalleolar level to keep the medial malleoli in contact.

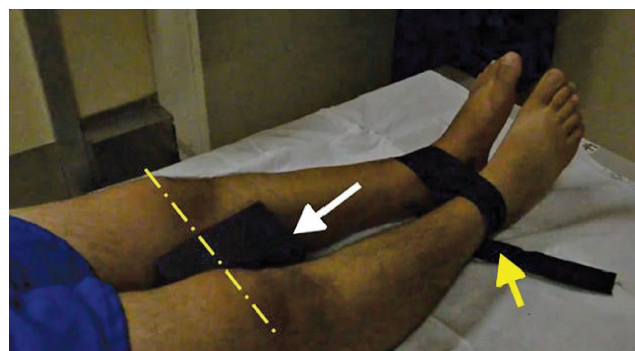

Fig. 3 Once the Velcro belt (yellow arrow) and the soft wedge (white arrow) are correct placed, the force vector applied on the knee simulates the varus manual stress radiographs. Of note, it is essential to ensure that both patellas are perpendicular to the radiographic table and that the patellar level is the even (yellow line).

abduct; however, the Velcro belt placed around the ankles avoid the limb displacement. The result vector is a varus stress performed simultaneously in both knees (► Fig. 3). This test is able to detect lateral laxity simultaneously and bilateral, taking only one radiographic (► Fig. 4). This technique can be performed with the knee in flexion or extension, removing the soft pad on the popliteal fossa to perform in extension. Once all

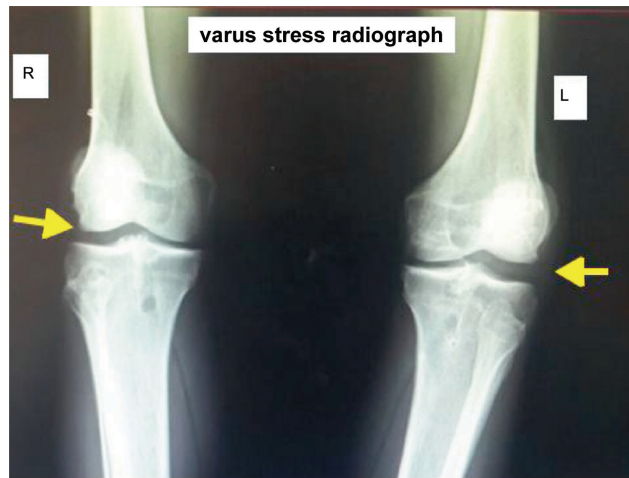

Fig. 4 The final bilateral simultaneous varus stress radiograph is showed in this picture. The soft wedge placed between the knees and the Velcro belt at the supramalleolar level produce a varus stress in both knees at the same time, requiring just one radiograph to evaluate side to side difference in the lateral compartment. The yellow arrows show the lateral gapping. R, right; L, left.

the previous steps are performed, the physician must ensure that both patellas are at the same level. Following this, the radiographic tube is placed 1 m from the radiographic cassette and centered on both patellas and the image is acquired. Advantages and disadvantages of our technique is presented in ►Table 1, while ►Table 2 shows the pearls and pitfalls of this technique.

Discussion

Magnetic resonance images (MRI) have an important role in the diagnosis of knee ligament injuries.⁴ However, this imaging modality is limited when considering the evaluation of the posterolateral corner of the knee due to its complex anatomy of the ligamentous structures of the posterolateral corner. Varus

Table 1 Advantages and disadvantages of our technique

Advantages	Disadvantages
Does not require an additional health care professional to apply the stress force	Needs further studies to confirm the efficacy of this technique
Decreases the need of radiographs due to the evaluation of both knees at the same time	Must be changed in patients with immobilization/external fixation in the leg
Side to side difference can be compared, ensuring that the same force was applied	May not be possible to evaluate the knees bilaterally in extreme obese patients
Easy and cost-effective technique	
Can be performed both at extension and 20–30 degrees of flexion	

Table 2 Pearls and pitfalls of our technique

Pearls	Pitfalls
Use the soft pad under the popliteal fossa to achieve the knee flexion	Radiographs in internal rotation may cause differences in the measurements
Ensure that the rotation and level of the limbs are correct	
The correct position of the soft wedge and the Velcro belt is key to reproduce the varus stress	

stress radiographs are an objective and reliable imaging technique for evaluating posterolateral corner injury.^{5,6}

When using stress radiographs due to interpatient variability, a comparison with the contralateral side is important to evaluate the side-to-side difference. While cadaveric studies such as LaPrade et al.⁵ have described objective measurements for lateral compartment opening associated with both isolated FCL, 2.7 mm, and combined PLC injuries, 4.0 mm, there is a relative paucity of data in regards to clinical studies evaluating varus stress radiographs. James et al. performed a systematic review evaluating the use stress radiography for the diagnosis of knee ligament injuries, which looked at numerous stress techniques, including four varus stress techniques.⁷ They concluded more clinical studies were needed to establish diagnostic gapping benchmarks. They also were unable to find any consensus on superiority of varus stress radiographs when compared with other diagnostic tests.

Gwathmey et al.⁶ correlated the results of varus stress radiographs with MRI findings in patients with posterolateral corner injuries and found that stress radiographs were consistent with the severity of the injuries described on the MRI. In patients with a MRI demonstrating a partial lesion of the posterolateral corner the varus opening was 12.8 mm and those with complete lesions the varus opening increased to 18.6 mm. Furthermore, the authors reported that stress radiographs were essential during the evaluation of partial tears to this complex, becoming a complementary tool for stabilization decision.

Our technique, described in details, is a reliable and cost-effective technique for varus stress test. This technique includes the advantages of less radiation exposure due to the fact that both knees are evaluated at the same time and with the same force applied. Furthermore, there is no necessity for another healthcare provider to be in the X-ray room to apply the stress, thereby decreasing the radiation to health care employees.

Final Remarks

In conclusion, varus radiographs are an important diagnostic and decision making tool in a knee with multi-ligamentous or lateral complex injury, both in acute and chronic settings. While further studies need to be done to evaluate efficacy, we believe that our technique is reliable and cost-effective and

has additional advantages compared with conventional varus stress techniques previously described in the literature.

Conflicts of Interest

The authors declare no conflicts of interest.

References

- 1 Gollehon DL, Torzilli PA, Warren RF. The role of the posterolateral and cruciate ligaments in the stability of the human knee. A biomechanical study. *J Bone Joint Surg Am* 1987;69(2):233–42
- 2 Chahla J, Moatshe G, Dean CS, LaPrade RF. Posterolateral corner of the knee: current concepts. *Arch Bone Jt Surg* 2016;4(2):97–103
- 3 LaPrade RF, Wentorf FA, Fritts H, Gundry C, Hightower CD. A prospective magnetic resonance imaging study of the incidence of posterolateral and multiple ligament injuries in acute knee injuries presenting with a hemarthrosis. *Arthroscopy* 2007;23(12):1341–7
- 4 Farshad-Amacker NA, Potter HG. MRI of knee ligament injury and reconstruction. *J Magn Reson Imaging* 2013;38(4):757–73
- 5 LaPrade RF, Heikes C, Bakker AJ, Jakobsen RB. The reproducibility and repeatability of varus stress radiographs in the assessment of isolated fibular collateral ligament and grade-III posterolateral knee injuries. An in vitro biomechanical study. *J Bone Joint Surg Am* 2008;90(10):2069–76
- 6 Gwathmey FW Jr, Tompkins MA, Gaskin CM, Miller MD. Can stress radiography of the knee help characterize posterolateral corner injury? *Clin Orthop Relat Res* 2012;470(3):768–73
- 7 James EW, Williams BT, LaPrade RF. Stress radiography for the diagnosis of knee ligament injuries: a systematic review. *Clin Orthop Relat Res* 2014;472(9):2644–57