






Missed Tillaux Fracture and Syndesmosis Injury in Adult: Arthroscopic Assisted Reduction and Fixation*

Fratura de Tillaux não percebida e lesão por sindesmose em adultos: Redução e fixação artroscópica assistida

Nuno Oliveira¹ Pedro Pinho¹ Mário Baptista¹ Daniel Freitas¹ Pedro Varanda^{1,2}
Bruno S. Pereira^{1,2,3,4}

¹ Orthopedics and Trauma Surgery Department, Hospital de Braga, Sete Fontes, São Victor, Braga, Portugal

² Instituto de Investigação em Ciências da Vida e Saúde (ICVS), Escola de Medicina, Universidade do Minho, Braga, Portugal

³ Clínica do Dragão, Espregueira Mendes Sports Center, FIFA Medical Center of Excellence, Estádio do Dragão, Porto, Portugal

⁴ Universitat de Barcelona, Gran Via de les Corts Catalanes, Barcelona, Spain

Address for correspondence Nuno Oliveira, MD, Orthopedics and Trauma Surgery Department, Hospital de Braga, Victor, Braga, 4710-243, Portugal (e-mail: nunocruzoliveira1@gmail.com).

Rev Bras Ortop 2021;56(3):399–402.

Abstract

Keywords

- ▶ ankle fractures
- ▶ ankle injuries
- ▶ arthroplasty, replacement, ankle
- ▶ minimally invasive surgical procedures

Resumo

Palavras-chave

- ▶ fraturas no tornozelo
- ▶ lesões no tornozelo
- ▶ artroplastia de substituição do tornozelo
- ▶ procedimentos cirúrgicos minimamente invasivos

Tillaux fractures are fractures of the lateral margin of the distal tibia, usually reported in children between 12 and 14 years old. As intraarticular fractures, they require anatomic reduction and fixation to avoid posttraumatic complications. Since the injury mechanism is external rotation of the foot on the leg, these injuries are commonly associated with other fractures or ligamentous lesions. Currently, arthroscopy is being increasingly used to assist and improve surgical treatment of ankle fractures. The authors describe a 12-month follow-up of a rare case of a missed Tillaux fracture associated with syndesmosis injury in a 76-year-old polytrauma patient, successfully treated by arthroscopically-assisted reduction and internal fixation.

As fraturas de Tillaux são fraturas da margem lateral da tíbia distal, geralmente relatadas em crianças entre 12 e 14 anos. Como fraturas intra-articulares, requerem redução e fixação anatômica para evitar complicações pós-traumáticas. Como o mecanismo de lesão é a rotação externa do pé na perna, essas lesões são comumente associadas a outras fraturas ou lesões ligamentares. Atualmente, a artroscopia está sendo cada vez mais utilizada para auxiliar e melhorar o tratamento cirúrgico das fraturas do tornozelo. Os autores descrevem um acompanhamento de 12 meses de um caso raro de uma fratura não percebida de Tillaux associada a lesão por sindesmose em um paciente de politrauma com 76 anos de idade, tratado com sucesso por redução e fixação interna assistida por artroscopia.

* Work developed at Serviço de Ortopedia e Traumatologia do Hospital de Braga, Braga, Portugal.

received
June 6, 2020
accepted
July 6, 2020
published online
September 25, 2020

DOI <https://doi.org/10.1055/s-0040-1716759>
ISSN 0102-3616.

© 2021. Sociedade Brasileira de Ortopedia e Traumatologia. All rights reserved.
This is an open access article published by Thieme under the terms of the Creative Commons Attribution-NonDerivative-NonCommercial-License, permitting copying and reproduction so long as the original work is given appropriate credit. Contents may not be used for commercial purposes, or adapted, remixed, transformed or built upon. (<https://creativecommons.org/licenses/by-nc-nd/4.0/>)
Thieme Revinter Publicações Ltda., Rua do Matoso 170, Rio de Janeiro, RJ, CEP 20270-135, Brazil

Introduction

Tillaux fractures are intraarticular fractures of the distal tibia caused by avulsion of the anterolateral distal tibia surface by traction exerted on the anterior tibiofibular ligament. These are uncommon injuries mostly seen in adolescents with partially closed distal tibia physis, usually between 12 and 14 years of age, corresponding to a Salter Harris type-III fracture. The injury is commonly called juvenile Tillaux fracture.¹ This type of injury is rarely seen in adults with skeletal maturity because anterior tibiofibular ligament usually tears first.²⁻⁵

Intraarticular fractures require anatomic reduction and stabilization to avoid complications such as ankle instability, ankle pain, and posttraumatic osteoarthritis.^{4,6}

Arthroscopy has several advantages over open approaches, allowing a less aggressive approach, treatment of associated lesions, improvement of intraarticular reduction and with fewer complications.⁷

The authors report arthroscopic assisted treatment of a rare case of Tillaux fracture in adult, associated with syndesmosis injury that was initially missed in a polytrauma patient.

Case Report

A 76-year-old man was admitted in the emergency department following a motor vehicle accident. He sustained severe head and thoracic trauma, with sternum and several rib fractures, a non-displaced scapula fracture, hemopneumothorax, and pulmonary contusion. Spine and pelvic injury were excluded, and the patient was admitted to the intensive care unit (ICU). Three weeks after the initial trauma, the patient complained of pain in his right ankle when he first tried to stand and could not bear weight. A focused physical examination of the right ankle and foot revealed minimal swelling on the lateral aspect of the ankle, moderate tenderness on palpation over the lateral malleoli, and mild restriction of the ankle's range of motion. Initial radiological evaluation with ankle radiographs showed a widened lateral ankle mortise and intra-articular bone fragments (→ **Figura 1**). Computed tomography (CT) showed a displaced Tillaux fracture associated with anterior displacement of the fibula, suggesting syndesmosis injury (→ **Figura 2**).

Under general anesthesia, in supine position and with a tourniquet applied to the right proximal thigh, the patient underwent anterior ankle arthroscopy through standard anteromedial and anterolateral portals. Extensive fibrosis was present. After debridement and loose body removal, fracture and syndesmotom injury were both easily visualized. Fracture reduction was achieved under direct visualization and fixed with one 3.0 mm cannulated interfragmentary screw placed through the anterolateral portal. Syndesmotom lesion was reduced and fixed with two percutaneous 4.5 mm transsyndesmotom cortical screws. Arthroscopic exploration after fixation confirmed satisfactory reduction, which was also confirmed with fluoroscopy (→ **Figs. 3 and 4**, video 1). No

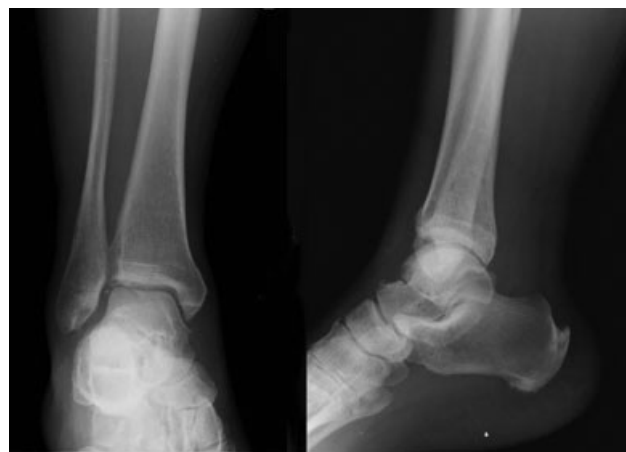

Fig. 1 Initial standard right ankle radiograph.

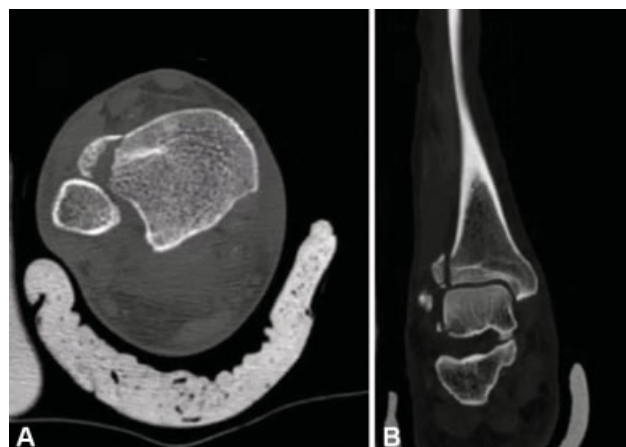

Fig. 2 Computed tomography of right ankle. (A) Axial view; (B) Sagittal view.

immobilization was used after the surgery, enabling early passive and active mobilization.

Video 1

Highlights of arthroscopic procedure.



Transsyndesmotom screws were removed at 8 weeks follow-up, and the patient started weight bearing.

At the 6th month, the patient was asymptomatic with symmetric ankle range of motion and no limitations during daily activities (→ **Fig. 5**). Follow-up continued up to 12 months, and no complications were reported.

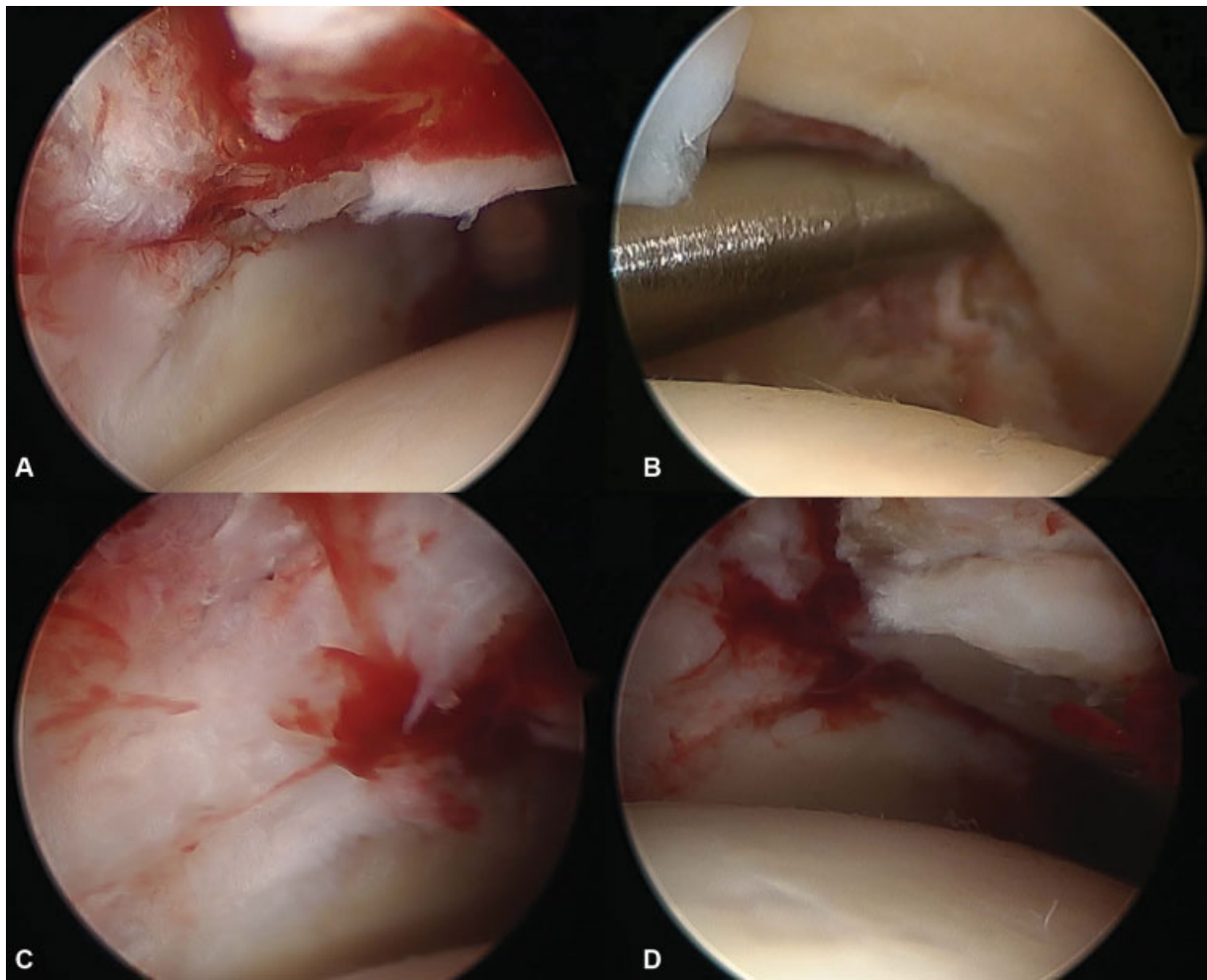


Fig. 3 Arthroscopy view. (A) Fracture displacement and ankle joint incongruity; (B) Widening of syndesmosis; (C) Fracture after reduction and fixation; (D) Syndesmosis after reduction and fixation.

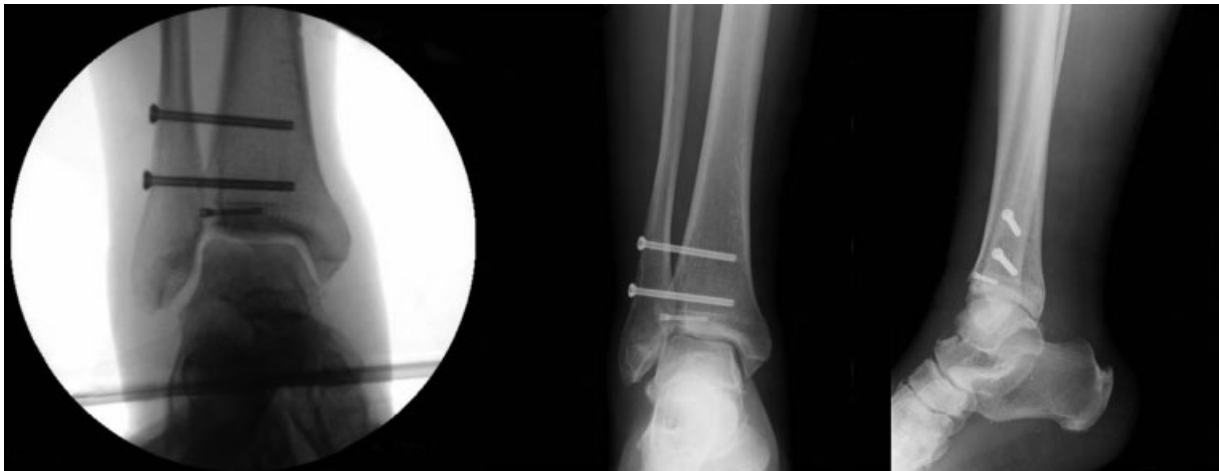

Fig. 4 Intraoperative fluoroscopy control – left; Postoperative radiograph – right.

Discussion

The injury mechanism of the Tillaux fracture is external rotational force of the foot on the leg, which makes the antero-inferior tibiofibular ligament the deforming force.¹

Although this may sometimes occur in adolescents with partially closed physis, it is very rare in skeletally mature adults. When there is less than 2 mm displacement and syndesmosis injury is excluded, these fractures can be managed with conservative treatment by immobilization in a

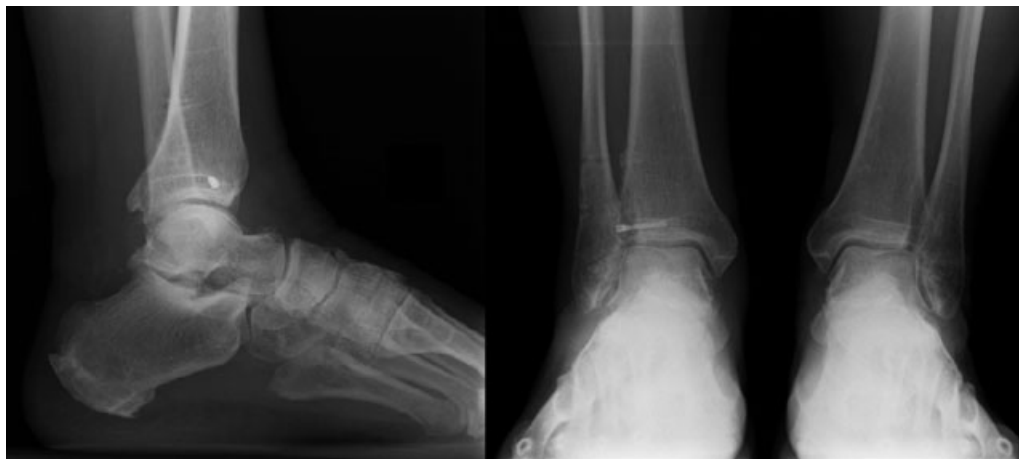

Fig. 5 Weight bearing radiograph at 6 months follow-up.

non-weight bearing cast or ankle braces. Displaced fractures over 2 mm should be managed surgically.^{4,6}

Fracture fragments may be small and may be missed in traditional ankle radiographs; thus, oblique views may be required. A CT scan is more accurate than plain radiographs and allows better assessment of fracture displacement, pattern, and joint congruity.⁶

Arthroscopy has been increasingly used to assist surgical treatment of ankle fractures and to manage posttraumatic complications.⁷ It is a valuable tool because it allows direct visualization of the articular surface needed for anatomical reduction, requires smaller skin incision and dissection, less disruption of the osseous blood supply and less risks of wound complications, infection, delayed union, and non-union. It also allows the diagnosis and potential treatment of associated lesions, as, for instance, chondral lesions.⁷⁻⁹ In our case, in addition to the advantages previously mentioned, arthroscopy allowed a smoother and less aggressive debridement of fibrotic tissue and callus that was already formed at 3 weeks after the injury. Open reduction and internal fixation have been reported to have good to excellent results in up to 80% of cases.¹⁰ Feng et al.⁶ reported good and excellent results in 100% of cases in a series of 19 patients with Tillaux fractures treated with arthroscopy support at 6 months follow-up.

When a fracture of the lateral margin of the distal tibia is present, it usually means that the anterior tibiofibular ligaments are intact. However, tibiofibular syndesmosis injury can also occur.^{1,4} Syndesmosis injury should always be assessed in ankle fractures, whether with preoperative stress radiographs or intraoperative direct visualization of diastasis with stress maneuvers. In this case, syndesmosis injury was evident in both the preoperative radiograph and CT studies and posteriorly confirmed with direct arthroscopic visualization. It required an extensive debridement before reduction due to fibrotic changes that were already present. Anatomic reduction was achieved with minimal aggression to soft-tissue structures, which provided excellent results and fast rehabilitation.

It is important that these lesions are diagnosed in the emergency room to allow an early management and avoid

potential complications. Polytrauma patients may have more life-threatening lesions that might defocus clinical evaluation of peripheral injuries, but a comprehensive extremity examination should be conducted as soon as possible, especially in high-energy traumatic lesions.

Financial Support

There was no financial support from public, commercial, or non-profit sources.

Conflict of Interests

The authors have no conflict of interests to declare.

References

- 1 Protas JM, Kornblatt BA. Fractures of the lateral margin of the distal tibia. The Tillaux fracture. *Radiology* 1981;138(01): 55-57
- 2 Miller MD. Arthroscopically assisted reduction and fixation of an adult Tillaux fracture of the ankle. *Arthroscopy* 1997;13(01): 117-119
- 3 Kumar N, Prasad M. Tillaux fracture of the ankle in an adult: a rare injury. *J Foot Ankle Surg* 2014;53(06):757-758
- 4 Oak NR, Sabb BJ, Kadakia AR, Irwin TA. Isolated adult Tillaux fracture: a report of two cases. *J Foot Ankle Surg* 2014;53(04): 489-492
- 5 Mishra PK, Patidar V, Singh SP. Chaput Tubercle Fracture in an Adult- A Rare Case Report. *J Clin Diagn Res* 2017;11(03): RD01-RD02
- 6 Feng SM, Sun QQ, Wang AG, Li CK. "All-Inside" Arthroscopic Treatment of Tillaux-Chaput Fractures: Clinical Experience and Outcomes Analysis. *J Foot Ankle Surg* 2018;57(01):56-59
- 7 Hamilton GA, Doyle MD, Castellucci-Garza FM. Arthroscopic-Assisted Open Reduction Internal Fixation. *Clin Podiatr Med Surg* 2018;35(02):199-221
- 8 Leontaritis N, Hinojosa L, Panchbhavi VK. Arthroscopically detected intra-articular lesions associated with acute ankle fractures. *J Bone Joint Surg Am* 2009;91(02):333-339
- 9 Bonasia DE, Rossi R, Saltzman CL, Amendola A. The role of arthroscopy in the management of fractures about the ankle. *J Am Acad Orthop Surg* 2011;19(04):226-235
- 10 Zhao J, Shu H, Li W, Liu Y, Shi B, Zheng G. Clinical features and surgical effectiveness of ankle fractures involving Tillaux-Chaput in adults. *Zhongguo Xiu Fu Chong Jian Wai Ke Za Zhi* 2015;29(03): 288-291