

# Minimally Invasive Chevron Surgery and Bosch Percutaneous Osteotomy in Hallux Valgus Treatment. Midterm Results. Comparative Radiological Study\*

## *Cirurgia minimamente invasiva de chevron e osteotomia percutânea de Bosch no tratamento de hálux valgo. Resultados em médio prazo. Estudo radiológico comparativo*

Juan Manuel Yañez Arauz<sup>1,2</sup> Nicolás Raimondi<sup>1</sup> Andrés Eksarho<sup>1</sup> Diego Lauritto<sup>1</sup>  
 Maria Eugenia Yañez Arauz<sup>1</sup> Juan Martin Yañez Arauz<sup>2</sup>

<sup>1</sup>Foot and Ankle Service, Hospital Universitario Austral, Buenos Aires, Argentina

<sup>2</sup>Faculty of Medicine, Universidad Austral, Buenos Aires, Argentina

Address for correspondence Juan Manuel Yañez Arauz, MD, Gral. Urquiza 340. Acassuso. Buenos Aires, Argentina. PC:1641 (e-mail: juanyanezarauz@gmail.com).

Rev Bras Ortop 2022;57(2):250–256.

### Abstract

**Objective** The purpose of the present study is to compare the radiological results of angular correction and its maintenance in the medium term between two minimally invasive techniques for the treatment of hallux valgus (minimally invasive chevron surgery vs. Bosch technique).

**Methods** A comparative prospective analysis of patients undergoing surgery for symptomatic hallux valgus deformity was performed. We compared two minimally invasive techniques in homogeneous groups of population. Two groups of 62 and 63 feet respectively, were constituted. We compared first ray angular corrections and consolidation as well as the correction power of both osteotomies and their maintenance over time. The postoperative complications and surgical time in both study groups were also evaluated. The minimum follow-up was 2 years.

**Results** There were differences between both groups in the intermetatarsal angle at 24 months postsurgery. There were no differences between both groups regarding metatarsophalangeal angle, and distal metatarsal articular angle. There were no intraoperative complications in either group. The surgical time between both groups had statistically significant differences.

**Conclusions** Both screw-stabilized, Bosch surgery and minimally invasive chevron (hybrid when associated with percutaneous Akin osteotomy) present adequate

### Keywords

- ▶ minimally invasive surgical procedures
- ▶ hallux valgus
- ▶ osteotomy
- ▶ hallux valgus/ diagnostic imaging
- ▶ hallux valgus/surgery

\* Study developed at Hospital Universitario Austral, Buenos Aires, Argentina.

received  
 August 20, 2020  
 accepted  
 December 1, 2020  
 published online  
 November 11, 2021

DOI <https://doi.org/10.1055/s-0041-1729590>.  
 ISSN 0102-3616.

© 2021. Sociedade Brasileira de Ortopedia e Traumatologia. All rights reserved.

This is an open access article published by Thieme under the terms of the Creative Commons Attribution-NonDerivative-NonCommercial-License, permitting copying and reproduction so long as the original work is given appropriate credit. Contents may not be used for commercial purposes, or adapted, remixed, transformed or built upon. (<https://creativecommons.org/licenses/by-nc-nd/4.0/>)

Thieme Revinter Publicações Ltda., Rua do Matoso 170, Rio de Janeiro, RJ, CEP 20270-135, Brazil

correction of moderate hallux valgus. However, patients treated with Bosch percutaneous surgery had a greater correction power of the intermetatarsal angle in the medium term, as well as a shorter surgical time, when compared with those who were treated with chevron osteotomy. Both techniques had a similar evolution over time regarding loss of correction and postoperative complications.

## Resumo

**Objetivo** O objetivo deste estudo é comparar os resultados radiológicos da correção angular e sua manutenção no médio prazo entre duas técnicas minimamente invasivas para o tratamento de hálux valgo (cirurgia minimamente invasiva em chevron vs. técnica de Bosch).

**Métodos** Foi realizada uma análise prospectiva comparativa de pacientes submetidos à cirurgia para deformidade sintomática de hálux valgo. Comparamos duas técnicas minimamente invasivas em grupos homogêneos de população. Dois grupos de 62 e 63 pés, respectivamente, foram constituídos. Comparamos correções angulares de primeiro raio e consolidação, bem como o poder de correção tanto das osteotomias quanto de sua manutenção ao longo do tempo. As complicações pós-operatórias e o tempo cirúrgico em ambos os grupos de estudo também foram avaliados. O seguimento mínimo foi de 2 anos.

**Resultados** Houve diferenças entre ambos os grupos no ângulo intermetatarsal aos 24 meses após a cirurgia. Não houve diferenças entre ambos os grupos em relação ao ângulo metatarsal-falângico e ao ângulo articular metatarso-distal. Não houve complicações intraoperatórias em nenhum dos grupos. O tempo cirúrgico entre ambos os grupos apresentou diferenças estatisticamente significativas.

**Conclusões** Sendo as duas técnicas estabilizadas por parafusos, tanto a osteotomia de Bosch quanto a cirurgia minimamente invasiva em chevron (híbrida quando associada à osteotomia percutânea de Akin) apresentam correção adequada de hálux valgo moderado. No entanto, os pacientes tratados com a osteotomia percutânea Bosch apresentaram maior poder de correção do ângulo intermetatarsal no médio prazo, bem como e menor tempo cirúrgico, em relação aos que foram tratados com osteotomia em chevron. Ambas as técnicas apresentaram evolução semelhante ao longo do tempo no que se refere à perda de correção e complicações pós-operatórias.

## Palavras-chave

- ▶ procedimentos cirúrgicos minimamente invasivos
- ▶ hálux valgo
- ▶ osteotomia
- ▶ hallux valgus/diagnóstico por imagem
- ▶ hallux valgus/cirurgia

## Introduction

Hallux valgus is a frequent, complex, and progressive deformity of the forefoot, which produces multiple clinical manifestations. It has a multifactorial etiology.<sup>1</sup> The deformity and the clinical manifestations of this pathology occur between the 3<sup>rd</sup> and 5<sup>th</sup> decade in 65% of the population. It is more frequent in women.<sup>2,3</sup>

Multiple surgical techniques have been described for the treatment of hallux valgus, and most of them include a first metatarsal osteotomy. This osteotomy can be performed in different areas of the first metatarsal: (distal, mid-diaphyseal and/or proximal), associated or not with soft-tissue release.<sup>4,5</sup>

The distal chevron osteotomy, popularized by Austin and Leventen,<sup>6</sup> is accepted as a good option for the treatment of mild-to-moderate hallux valgus, obtaining good results in angular and symptomatic correction.<sup>7</sup>

In the last decades, percutaneous techniques for the treatment of hallux valgus have been popularized, supported by the

theory of shorter surgical time, less surgical trauma, less postoperative pain, and faster recovery.<sup>8</sup> Peter Bosch modified the popular Kramer osteotomy and did it through a minimal incision. He used a K-wire to stabilize the osteotomy. In 1990 Bosch<sup>9</sup> published his percutaneous osteotomy technique, in which he described a lateral cephalic displacement of  $\frac{3}{4}$  of the metatarsal diameter minimum, obtaining a consolidation of 100%. Percutaneous techniques have been described in several publications.

Similar results have been demonstrated and were, sometimes, superior to those of the open techniques.<sup>10</sup> However, despite the results described in these papers, the minimally invasive surgery's follow-up time and the levels of evidence (III and IV) remain a subject of debate and controversy.<sup>11</sup>

Some authors<sup>12</sup> described combined procedures, using mini-open techniques associated with purely percutaneous techniques to treat a foot deformity. They called them "hybrid techniques".

The main objective of the present study is to compare the radiological results of angular correction, and its maintenance in the medium term, between two minimally invasive techniques for the treatment of hallux valgus (minimally invasive chevron surgery vs. Bosch technique).

The secondary objective is to evaluate the postoperative complications and surgical time in both study groups.

The hypothesis was that the percutaneous technique of Bosch presents similar results regarding the correction of the deformity and its maintenance in time, with lower complication rates and shorter surgical time, compared to the minimally invasive chevron osteotomy.

## Materials and Methods

A comparative prospective analysis of patients undergoing surgery for symptomatic hallux valgus deformity was performed. We compared two minimally invasive techniques in homogeneous groups of population, regarding their deformity of first ray, age group, and functional demand.

From January 2014 to January 2015, 125 feet from 96 patients were included in the present study, with a minimum follow-up of 2 years. The main reasons for surgery were pain and difficulty in wearing closed shoes.

The severity of the deformity, according to the preoperative metatarsophalangeal angle (MPA), was defined as normal ( $\leq 15$  degrees), mild (16–20 degrees), moderate (21–39 degrees), or severe ( $\geq 40$  degrees).<sup>13</sup> Presence of a MPA greater than 20 degrees in the postoperative period was defined as a recurrence of deformity.<sup>14</sup> Only patients with moderate deformities were included in this study.

### Population

Two groups of patients were conformed according to the surgical technique:

Group 1: 62 feet of 48 patients. This group included 4 men (3 bilateral deformities) and 44 women (11 bilateral deformities). All feet had moderate hallux valgus. The operated feet included 28 left and 34 right feet. The surgical technique was a **Bosch percutaneous osteotomy**, stabilized with osteosynthesis with cannulated screw in addition to the endomedular K-wire. In all cases, lateral tendon release was performed through a percutaneous incision.

Group 2: 63 feet of 48 patients. This group included 3 men (one bilateral deformity) and 45 women (14 bilateral deformities). All feet had moderate hallux valgus. The operated feet included 33 right and 30 left feet. The surgical technique was a minimally invasive distal chevron osteotomy, stabilized with cannulated screw. **Table 1** describes the groups.

All surgeries were performed in the same hospital by 3 specialists in foot and ankle surgery. Although the choice of the technique was not random, surgeon “one” always performed the Bosch technique for his patients with moderate hallux valgus. The other two surgeons performed the minimally invasive chevron technique.

Inclusion criteria:

- 1- Symptomatic moderate hallux valgus

**Table 1** Characteristics of both groups

Technique	Chevron MIS	Bosch
Patients	48	48
Average age	47	51
Sex	45 female 3 male	44 female 4 male
Side	30 left 33 right	28 left 34 right
MPA	63 moderate	62 moderate
Bilaterality	15	14
Number of feet	63	62

Abbreviations: MIS, minimally invasive surgery; MPA, metatarsophalangeal angle.

- 2- Patients older than 18 years.

Exclusion criteria:

- 1- Previous hallux valgus surgeries.
- 2- Rheumatoid arthritis or other destructive arthritis.
- 3- Severe deformities.
- 4- Evidence of cuneo-metatarsal instability.
- 5- Patients with neuromuscular diseases.

### Radiographic Evaluation.

In both groups, radiographs were taken in weight bearing position, in two incidences: anteroposterior and lateral X-ray views. We analyzed the X-ray in the preoperative period, at 3 months postoperatively, and in the distant postoperative period, after 24 months. Angular corrections were compared in the short term, and the maintenance or not of these corrections over more than 24 months, which was considered the distant postoperative period.

All images were digital, measured with the MB Ruler software version 4.0 (MB Software Solutions, LLC, Owings Mills, MD, USA).

The authors measured the following angles:

- A) Metatarsophalangeal angle (MPA), measured between the axis of the first phalanx and the first metatarsal;
- B) Intermetatarsal angle (IMA), measured by the Miller<sup>15</sup> measurement technique;
- C) Distal metatarsal articular angle (DMAA), measured as the angle between the longitudinal axis of the first metatarsal and the perpendicular to the line drawn between the most medial and lateral extension of the metatarsal joint surface.<sup>16</sup>

Status and type of consolidation of the osteotomy was determined according with Jones et al.<sup>17</sup> Vicious consolidation was considered in those cases in which, in the lateral projections, the metatarsal osteotomy consolidated with an angular deviation, taking the longitudinal axis of the first metatarsal as reference.<sup>18</sup>

### Statistical Analysis

The data obtained were included in a Excel spreadsheet (Microsoft Corp., Redmond, WA, USA). The loss or not of the

angular correction in the immediate postoperative period was analyzed in both study groups.

The authors measured the angles of the preoperative radiographs, as well as those corrected, at 3 and 24 months postoperatively.

In each group, the average angles and the standard deviations of the samples were registered.

The Pearson chi-squared test was used for the analysis of differences in the distribution of one variable in both groups, considering a  $p$ -value  $< 0.05$  statistically significant.

In order to minimize any possible effect of a statistically significant difference in the measurement of the angles of both groups, we used the percentage of variation of the angles, expressed by the angular recovery rates (RRs), which is defined by the following equation: the difference between the preoperative and postoperative angle, divided by the preoperative angle multiplied by 100.<sup>19</sup>

In each independent group, the preoperative and 3 months postoperative angles were compared using the Mann-Whitney test. Subsequently, the evolutions of each angle were compared in the same group at 3 and 24 months postoperatively, also analyzed by the Mann-Whitney test.

In order to measure significant changes in the same angle at 3 and 24 months postoperatively, we used the McNemar test.

To evaluate if there were differences in the evolution of the three angles (IMA, MPA, and DMAA) between both study groups (Bosch technique vs. minimally invasive chevron technique), the Student t-test was used.

As the two techniques were performed for the treatment of the same pathology, in populations with similar and homogeneous characteristics, we attempted to minimize the influences of uncontrolled variables.

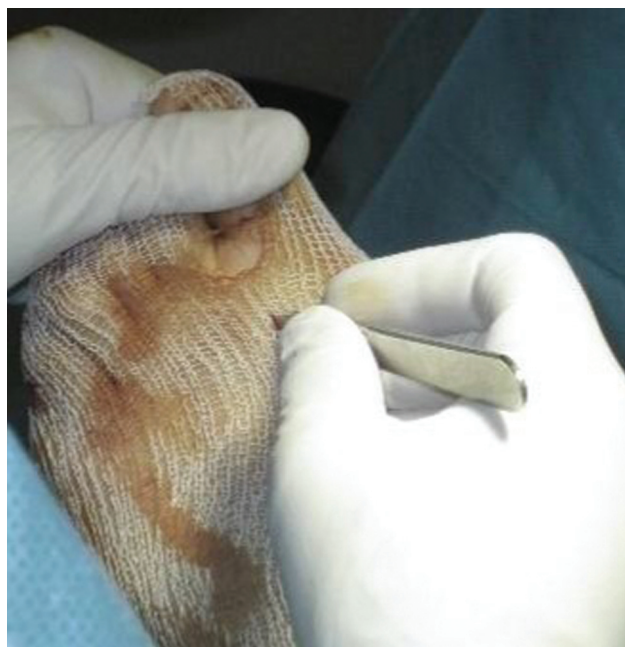### Abstract of the Bosch Technique

Patient supine, feet on the edge of the surgical table, or slightly protruding from it. This allows us to position ourselves comfortably in front the foot to be operated on, and to handle the instruments while working and use the fluoroscopy.

- Release of the adductor hallucis tendon (with percutaneous technique) (→ Fig. 1).
- Medial paraungual incision of the first toe, and progression of a retrograde 2.0-mm K-wire to the distal metaphysis of the first metatarsal.
- Transversal distal metatarsal osteotomy is done using a burr (long Shannon 44), through a medial portal of the metatarsal neck, with a perpendicular cut to the axis of the first metatarsal bone. Afterwards, the metatarsal head may be displaced more than 75% of the diameter of the first metatarsal if necessary, allowing corrections of severe IMAs. It is a complete osteotomy, and must be stabilized with intramedullary K-wire. Control the position with fluoroscope in lateral and anteroposterior views.
- Stabilization using a cannulated screw (→ Fig. 2).

### Abstract of the Minimally Invasive Chevron Technique.

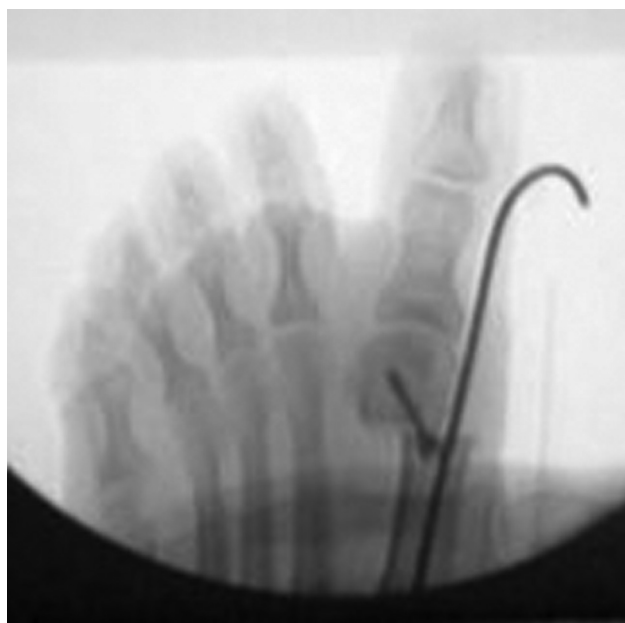
- Patient supine, feet on the edge of the surgical table or slightly protruding from it.



**Fig. 1** Percutaneous release of the adductor hallucis tendon.

- 30 mm medial approach on the medial first metatarsal head.
- “V” or longitudinal capsulotomy.
- Medial metatarsal head bunionectomy.
- Lateral release by the same approach.
- Osteotomy in inverted “L” (chevron modified by Johnson). Lateral displacement. Osteosynthesis using a cannulated screw.
- Capsuloplasty and skin synthesis.

Postoperative management and return to activities were similar in both groups. The only difference was that in the Bosch technique, the K-wire was removed at 3 weeks, and



**Fig. 2** Bosch technique.

active and passive joint mobility began from there. In the chevron technique, joint mobility began at 2 weeks postoperatively.

## Results

The average age of the patients was 49.3 (range, 77–19) years. Seven patients were men and 89 were women.

There were 58 left and 67 right feet. Twenty-nine patients presented bilateral surgical pathology.

In group 1 (Bosch), the mean correction for the MPA, IMA, and DMAA was 20.19°; 8.66°; and 9.03° at 3 months; and 19.62°; 8.14° and 9.66° at 24 months.

In group 2 (chevron), the average correction for the MPA, IMA, and DMAA were 20.49°, 6.47°, and 10.63° respectively at 3 months; and 19.47°, 5.9°, and 9.5° at 24 months. The results regarding angular corrections in both groups were similar (► **Table 2**).

### Preoperative Measurements

1. The distribution of preoperative congruence by technique can be seen in ► **Table 3**. Differences in the congruence distribution between both techniques were statistically significant ( $p$ -value: 0.008).
2. A significant difference ( $p$ -value: 0.012) was observed only in the preoperative IMA of both groups. The other preoperative angles in both groups did not present significant differences (► **Table 4**).

### Measurement at 3 months Postoperative and Comparison with Preoperative.

1. Significant differences were found between the preoperative and postoperative metatarsophalangeal congruence at 3 months in patients treated with the Bosch method:  $p$ -value = 0.00225 Mc Nemar test. No differences registered in the chevron technique.
2. Regarding angular correction, we compared the evolution of each angle by group (Bosch and chevron) between preoperative and 3 months and did not find statistically significant differences. However, the RR for the 3-month IMA was 63% in the Bosch technique, whereas in chevron-treated patients it was 55% ( $p = 0.0668$ ). Although not statistically significant, it shows a greater IMA potential correction with the Bosch technique.

**Table 2** Average correction in degrees of the angles in both groups at 3 and 24 months

Average correction	Bosch 3 months	Chevron 3 months	Bosch 24 months	Chevron 24 months
MPA	20.19	20.49	19.62	19.47
IMA	8.66	6.47	8.14	5.9
DMAA	9.03	10.63	9.66	9.5

Abbreviations: DMAA, distal metatarsal articular angle; IMA, intermetatarsal angle; MPA, metatarsophalangeal angle.

**Table 3** Distribution of preoperative joint congruence in both groups

	no congruence	congruence	Total
Bosch	20	42	62
Chevron	8	55	63
Total	28	97	125

### Measurement at 24 Months after Surgery and Comparison to the Preoperative Period.

1. There were no statistically significant differences between preoperative and postoperative congruence at 24 months in patients who underwent chevronosteotomy:  $p$ -value = 0.72; but we found significant differences in patients treated with the Bosch technique:  $p$ -value = 0.0013
2. The evolutions by technique were compared in each of the angles considered, between the preoperative measurements and those measured at 24 months, and statistically significant difference was found in the IMA between the Bosch and chevron techniques (► **Table 5**).
3. There were no differences in the evolution of both groups (3–24 months) in the IMA, MPA, and DMAA ( $p > 0.79$ ). Therefore, these angles maintained the correction over time.

**Complications:** There were no intraoperative complications in either group.

There were 10 cases of postoperative complications in the Bosch group and 7 in the chevron group. However, the incidence of complications between the two techniques was similar (chi-squared test,  $p$ -value = 0.41). From the analysis of complications, in group 1 (Bosch), 5 cases of cellulitis were found on K-wire insertion, 1 implant rupture, 1 neuritis, 1 osteomyelitis, 1 hematoma, and a case of deep venous thrombosis. In group 2 (chevron), there were 3 cases of cellulitis, 2 neuritis, 1 relapse, and 1 hallux varus.

Surgical time: surgical time was measured from when the patient entered the operating room until he/she left the operating room. Average of the chevron group: 107 minutes; Bosch group: 50 minutes ( $p$ -value < 0.0001).

## Discussion

Minimally invasive surgery applied to the foot became popular in the 1980s and has been growing in the last decade based on the theory of obtaining better results in those patients who did not recover well from traditional open surgeries.

Portaluri,<sup>18</sup> in 2000, and then Magnan et al.,<sup>20</sup> in 2008, published a series of cases with 118 feet treated with the Bosch technique without screw, with an average follow-up of 35.9 months, and they mention that clinical results are comparable to those obtained through conventional open surgery.

In 2007, Migues et al.<sup>21</sup> published their experience in an evaluated series of 242 feet treated with the Bosch technique, basing the measurement in millimeters of head displacement.

**Table 4** Comparison of both groups. Average angle values and statistical significance

	Group 1	Group 2	Mean (1)	Mean (2)	SD (1)	SD (2)	P-value
MPA	Bosch	Chevron	29.94	29.52	6.69	7.51	0.7686
IMA	Bosch	Chevron	12.71	11.65	3.15	2.63	<b>0.0120</b>
DMAA	Bosch	Chevron	16.94	18.08	4.75	7.98	0.9171

Abbreviations: DMAA, distal metatarsal articular angle; IMA, intermetatarsal angle; MPA, metatarsophalangeal angle.

**Table 5** Comparison of the potential correction in both groups between 1 month preoperative and 24 months postoperative

Variable	Group 1	Group 2	Mean (1)	Mean (2)	SD (1)	SD (2)	Med (1)	Med (2)	p value
RR MP 24m	Bosch (n = 62)	Chevron (n = 63)	0.66	0.64	0.19	0.19	0.69	0.68	0,5651
RR IM 24m	Bosch (n = 62)	Chevron (n = 63)	0.58	0.49	0.27	0.24	0.59	0.46	<b>0,0188</b>
RR DMAA 24m	Bosch (n = 62)	Chevron (n = 63)	0.47	0.44	0.34	0.31	0.56	0.50	0,4693

Abbreviations: DMAA, distal metatarsal articular angle; IMA, intermetatarsal angle; MPA, metatarsophalangeal angle; RR, recovery rate; SD, standard deviation.

By analyzing the international bibliography, we found many series of cases of minimally invasive surgery, and very few comparisons of this technique with the conventional one.<sup>22–24</sup> The average correction reported in minimally invasive surgery for MPA and IMA is 26.7° to 33.3° and 11.8° to 13°, respectively.<sup>25–27</sup>

The results obtained in group 1, treated in a minimally invasive manner, hallux valgus and IMA of 29.66° and 13.29°, respectively, are comparable to those published.

Giannini et al.<sup>22</sup> performed a randomized study comparing the clinical-radiological results of 40 patients treated with bilateral hallux valgus. On one foot they did a scarf osteotomy, and on the other foot a traditional percutaneous Bosch surgery without screw. They found no statistically significant difference in postoperative angular measurements. However, percutaneous surgery yields shorter surgical times. They concluded that both techniques are effective in correcting the deformity. But they believe that the shorter surgical time, less aggressiveness, and simplicity in stabilization of percutaneous surgery improves clinical outcomes. Agreeing with the results of other publications, in our study, we obtained similar angular corrections in both groups, but the surgical time in the percutaneous Bosh surgery was shorter.

Brogan<sup>28</sup> compares percutaneous versus conventional chevron osteotomy. The postoperative clinical and radiological scores of all angles were substantially improved in both groups ( $p < 0.001$ ), but there was no statistically significant difference in angular improvement between the open group and the minimally invasive surgery group ( $p > 0.05$ ). He also found no significant difference in complications ( $p > 0.5$ ). Following the author, in our study, there were no statistically significant differences between the groups regarding angular corrections and complications ( $p$ -value = 0.41).

One weakness of our study is that we did not correlate the radiological results with the clinical ones, although the aim was to do a radiological analysis. However, we performed a complete statistical analysis comparing two techniques, which have not been analyzed in other studies, and evaluating radiographic angular corrections over time (medium term),

as well as possible loss of correction. For this reason, we do not agree that both techniques are similar in the correction of all angles, since we have found a potential greater medium-term correction of the intermetatarsal angle in the Bosch technique group. However, both techniques present a similar behavior in the evolution over time and do not present statistically significant differences in correction loss.

Ianno et al.<sup>19</sup> published a case series of percutaneous surgery, using a Bosch technique without osteosynthesis, and reported a high incidence of complications; among them, 4 cases of vicious consolidation, osteonecrosis, and 16 cases of recurrences. Our study, with a statistically significant number of Bosch techniques, did not present recurrences, osteonecrosis, or hallux varus.

## Conclusions

Both screw-stabilized, Bosch surgery and minimally invasive chevron (hybrid when associated with percutaneous Akin osteotomy) present adequate correction of moderate hallux valgus. However, patients treated with Bosch percutaneous surgery had a greater correction power of the intermetatarsal angle in the medium term, as well as a shorter surgical time, when compared to those treated with chevron osteotomy. Both techniques progressed similarly in the evolution over time, regarding loss of correction and postoperative complications.

### Financial Support

There was no financial support from public, commercial, or non-profit sources.

### Conflict of Interests

The authors have no conflict of interests to declare.

## References

- 1 Mann RA, Coughlin MJ. Hallux valgus—etiology, anatomy, treatment and surgical considerations. *Clin Orthop Relat Res* 1981; (157):31–41

- 2 Coughlin MJ. Hallux valgus in men: effect of the distal metatarsal articular angle on hallux valgus correction. *Foot Ankle Int* 1997; 18(08):463–470
- 3 Coughlin MJ, Thompson FM. The high price of high-fashion footwear. *Instr Course Lect* 1995;44:371–377
- 4 Baravarian B, Briskin GB, Burns P. Lapidus bunionectomy: arthrodesis of the first metatarsocunieform joint. *Clin Podiatr Med Surg* 2004;21(01):97–111
- 5 Biz C, Corradin M, Petretta I, Aldegheri R. Endolog technique for correction of hallux valgus: a prospective study of 30 patients with 4-year follow-up. *J Orthop Surg Res* 2015;10:102
- 6 Austin DW, Leventen EO. A new osteotomy for hallux valgus: a horizontally directed “V” displacement osteotomy of the metatarsal head for hallux valgus and primus varus. *Clin Orthop Relat Res* 1981;(157):25–30
- 7 Schneider W, Aigner N, Pinggera O, Knahr K. Chevron osteotomy in hallux valgus. Ten-year results of 112 cases. *J Bone Joint Surg Br* 2004;86(07):1016–1020
- 8 Maffulli N, Longo UG, Marinozzi A, Denaro V. Hallux valgus: effectiveness and safety of minimally invasive surgery. A systematic review. *Br Med Bull* 2011;97:149–167
- 9 Bösch P, Markowski H, Rannicher V. Technik und erste ergebnisse der subkutanen distalen metatarsale-I osteotomie. *Orthop Praxis* 1990;26:51–56
- 10 De Prado M, Ripoll PL, Golano P. Minimally invasive foot surgery: surgical techniques, indications, anatomical basis. Barcelona: About Your Health Publishers; 2009
- 11 Perera AM, Redfern A, Singh D, Lomax A. Minimally invasive forefoot surgery. *J Trauma Orthop* 2015;3(01):50–55
- 12 Yáñez Arauz JM, Del Vecchio J, Eksarho A, Ghioldi M, Escobar G, Yáñez Arauz ME. Cirugía “híbrida” del hallux valgus moderado: resultado radiológicos a mediano plazo. Hybrid surgery for moderate hallux valgus: midterm radiographic results. *Tobillo y Pie* 2015;7(01):43–47
- 13 Coughlin MJ. Hallux valgus. *J Bone Joint Surg Am* 1996;78(06): 932–966
- 14 Chiang CC, Lin CF, Tzeng YH, Huang CK, Chen WM, Liu CL. Distal linear osteotomy compared to oblique diaphyseal osteotomy in moderate to severe hallux valgus. *Foot Ankle Int* 2012;33(06): 479–486
- 15 Miller JW. Distal first metatarsal displacement osteotomy. Its place in the schema of bunion surgery. *J Bone Joint Surg Am* 1974;56(05):923–931
- 16 Deenik AR, de Visser E, Louwerens JW, de Waal Malefijt M, Draijer FF, de Bie RA. Hallux valgus angle as main predictor for correction of hallux valgus. *BMC Musculoskelet Disord* 2008;9:70
- 17 Jones KJ, Feiwel LA, Freedman EL, Cracchiolo A 3rd. The effect of chevron osteotomy with lateral capsular release on the blood supply to the first metatarsal head. *J Bone Joint Surg Am* 1995;77 (02):197–204
- 18 Portaluri M. Hallux valgus correction by the method of Bösch: a clinical evaluation. *Foot Ankle Clin* 2000;5(03):499–511
- 19 Iannò B, Familiari F, De Gori M, Galasso O, Ranuccio F, Gasparini G. Midterm results and complications after minimally invasive distal metatarsal osteotomy for treatment of hallux valgus. *Foot Ankle Int* 2013;34(07):969–977
- 20 Magnan B, Samaila E, Viola G, Bartolozzi P. Minimally invasive retrocapital osteotomy of the first metatarsal in hallux valgus deformity. *Oper Orthop Traumatol* 2008;20(01):89–96
- 21 Migués A, Campaner G, Slullitel G, Sotelano P, Carrasco M, Solari G. Minimally invasive surgery in hallux valgus and digital deformities. *Orthopedics* 2007;30(07):523–526
- 22 Giannini S, Faldini C, Vannini F, et al. Surgical treatment of hallux valgus: a clinical prospective randomized study comparing linear distal metatarsal osteotomy with scarf osteotomy. *Orthop Proc* 2009;91-B(Suppl 1):162
- 23 Maffulli N, Longo UG, Oliva F, Denaro V, Coppola C. Bosch osteotomy and scarf osteotomy for hallux valgus correction. *Orthop Clin North Am* 2009;40(04):515–524
- 24 Radwan YA, Mansour AM. Percutaneous distal metatarsal osteotomy versus distal chevron osteotomy for correction of mild-to-moderate hallux valgus deformity. *Arch Orthop Trauma Surg* 2012;132(11):1539–1546
- 25 Bauer T, de Lavigne C, Biau D, De Prado M, Isham S, Laffenêtre O. Percutaneous hallux valgus surgery: a prospective multicenter study of 189 cases. *Orthop Clin North Am* 2009;40(04):505–514
- 26 Huang PJ, Lin YC, Fu YC, Yang YH, Cheng YM. Radiographic evaluation of minimally invasive distal metatarsal osteotomy for hallux valgus. *Foot Ankle Int* 2011;32(05):S503–S507
- 27 Magnan B, Bortolozzi R, Samaila E, Pezzè L, Rossi N, Bartolozzi P. Percutaneous distal metatarsal osteotomy for correction of hallux valgus. Surgical technique. *J Bone Joint Surg Am* 2006;88(Suppl 1 Pt 1):135–148
- 28 Brogan K, Lindsfarne E, Akehurst H, Farook U, Shrier W, Palmer S. Minimally Invasive and Open Distal Chevron Osteotomy for Mild to Moderate Hallux Valgus. *Foot Ankle Int* 2016;37(11):1197–1204