

Results of Latissimus Dorsi Transfer using a Tendinous Allograft through a Single Deltopectoral Approach for Irreparable Posterosuperior Rotator Cuff Tears

Resultados da Transferência do Grande Dorsal Alongado com Enxerto Tendíneo Homólogo por Via Delto-Peitoral para Lesões Pósterio-Superiores Irreparáveis do Manguito Rotador

Alberto Naoki Miyazaki¹ Caio Santos Checchia¹ João Manoel Fonseca Filho^{1,2}
 João Roberto Polydoro Rosa^{1,2} Guilherme do Val Sella¹ Luciana Andrade da Silva¹

¹Shoulder and Elbow Surgery Group, Department of Orthopedics and Traumatology, Faculdade de Ciências Médicas, Santa Casa de São Paulo, São Paulo, SP, Brazil

²Department of Orthopedic Surgery, Hospital Alemão Oswaldo Cruz, São Paulo, SP, Brasil

Address for correspondence Caio Santos Checchia, Grupo de Ombro e Cotovelo, Departamento de Ortopedia e Traumatologia, Faculdade de Ciências Médicas, Santa Casa de São Paulo, Rua Dr. Cesario Mota Junior, 112, Consolação, São Paulo, SP, 01221-020, Brazil (e-mail: caio.checchia@gmail.com).

Rev Bras Ortop 2022;57(4):590–598.

Abstract

Objective The primary aim of the present study is to evaluate the functional results of a modification to the latissimus dorsi (LD) transfer around the shoulder for irreparable posterosuperior rotator cuff tears. The secondary aim is to evaluate variables that might influence the outcomes.

Surgical Technique Through a single deltopectoral approach, the LD tendon is detached, reinforced, and elongated with a tendinous allograft, transferred around the humerus, and fixed superolaterally to the greater tuberosity and anteriorly to the subscapularis.

Methods Retrospective functional evaluation of 16 cases. The average follow-up was 21 months (12–47). The postoperative results (at last follow-up) were compared with the preoperative ones, as well as to other pre, intra, and postoperative variables.

Results All (but one) patients were satisfied. Average University of California, Los Angeles (UCLA) score increased from 11.6 (8–16) to 27.3 (17–30) ($p < 0.001$). Improvements of shoulder pain, function, and strength achieved statistical significance ($p < 0.001$). Nonetheless, normal strength was never restored. Average active range of

Keywords

- ▶ rotator cuff injuries
- ▶ tendon transfer
- ▶ shoulder
- ▶ orthopedic procedures

Study developed at Shoulder and Elbow Surgery Group from the Department of Orthopedics and Traumatology of Faculdade de Ciências Médicas da Santa Casa de São Paulo, São Paulo, Brazil.

received
August 7, 2020
accepted
October 2, 2020
published online
March 31, 2021

DOI <https://doi.org/10.1055/s-0041-1724073>.
ISSN 0102-3616.

© 2021. Sociedade Brasileira de Ortopedia e Traumatologia. All rights reserved.

This is an open access article published by Thieme under the terms of the Creative Commons Attribution-NonDerivative-NonCommercial-License, permitting copying and reproduction so long as the original work is given appropriate credit. Contents may not be used for commercial purposes, or adapted, remixed, transformed or built upon. (<https://creativecommons.org/licenses/by-nc-nd/4.0/>)

Thieme Revinter Publicações Ltda., Rua do Matoso 170, Rio de Janeiro, RJ, CEP 20270-135, Brazil

motion improved as follows: forward elevation, from 106° (60–140°) to 145° (130–160°) ($p < 0.001$); external rotation from 30° (0° to 60°) to 54° (40–70°) ($p < 0.001$); and internal rotation from L1 (gluteus to T7) to T10 (T12–T3) ($p < 0.05$). No complication has occurred. Preoperative pseudoparesis was reverted in all the six cases in which it was present. None of the variables analyzed influenced the outcomes, including pseudoparesis.

Conclusions At early follow-up, this technique is safe and effective at recovering from pseudoparesis and at improving shoulder pain, function, and strength.

Resumo

Objetivo O objetivo primário do presente trabalho é avaliar os resultados funcionais de uma modificação na transferência do grande dorsal no ombro para tratamento de lesões póstero-superiores irreparáveis do manguito rotador. O objetivo secundário é avaliar as variáveis que podem influenciar os resultados.

Técnica Cirúrgica Por meio de uma única abordagem deltopeitoral, o tendão do músculo grande dorsal é desinserido reforçado e alongado com um enxerto tendíneo homólogo, transferido ao redor do úmero e fixado em posição superolateral ao tubérculo maior, anteriormente, ao músculo subescapular.

Métodos Avaliação funcional retrospectiva de 16 casos. O período médio de acompanhamento foi de 21 meses (12–47 meses). Os resultados pós-operatórios (no último acompanhamento) foram comparados aos pré-operatórios, bem como a outras variáveis pré, intra e pós-operatórias.

Resultados Todos os pacientes ficaram satisfeitos (exceto um). A pontuação média da *University of California, Los Angeles* (UCLA) aumentou de 11,6 (8–16) para 27,3 (17–30) ($p < 0,001$). A dor, a função e a força do ombro apresentaram melhora estatisticamente significativa ($p < 0,001$). A força, porém, não voltou ao valor normal. A amplitude de movimento ativa média apresentou as seguintes melhoras: elevação frontal, de 106° (60–140°) para 145° (130–160°) ($p < 0,001$); rotação externa, de 30° (0–60°) para 54° (40–70°) ($p < 0,001$); rotação interna, de L1 (glúteo a T7) para T10 (T12–T3) ($p < 0,05$). Nenhuma complicação foi observada. A pseudoparesia pré-operatória foi revertida em todos os seis casos em que foi observada. Nenhuma das variáveis analisadas influenciou os desfechos, nem mesmo a pseudoparesia.

Conclusões No curto prazo, essa técnica é segura e eficaz na recuperação da pseudoparesia e na melhora da dor, da função e da força do ombro.

Palavras-chave

- ▶ lesões do manguito rotador
- ▶ transferência de tendão
- ▶ ombro
- ▶ procedimentos ortopédicos

Introduction

Chronic irreparable rotator cuff tendon tears lead to atrophy, fatty infiltration, and functional impairment of their respective muscle bellies.¹ When they affect the posterosuperior rotator cuff (supra and infraspinatus tendons), they mostly result in pain, reduction of shoulder strength for external rotation and forward flexion, and difficulty in positioning the hand in space.^{1,2}

Due to the irreparability of these tears, several surgical techniques were described to improve shoulder function. Reverse total shoulder arthroplasty has been shown to provide good and predictable functional outcomes at short and medium-term follow-up.³ Nevertheless, two important concerns suggest that it should be reserved for older patient populations (65 years or older): (1) there is evidence showing that after 10 years postoperatively, these good functional results deteriorate and the complication rates increase sig-

nificantly⁴; (2) reverse total shoulder arthroplasty has been widely used for a relatively short period (since 2004 in the USA⁵) and, therefore, there is little evidence of its long-term results.

Because of these reasons, other techniques are recommended for younger and more active patients.⁶ The three most commonly used techniques are: (1) latissimus dorsi tendon (LDT) transfer to the greater tuberosity,^{1,2,7–13} (2) superior capsular reconstruction,^{14,15} and (3) lower trapezius tendon transfer to the greater tuberosity.^{16,17}

Despite some publications regarding the outcomes^{14,15} in the last few years for superior capsular reconstruction, its medium and long-term results are still unknown. Similarly, the works concerning trapezius tendon transfers outcomes are still very few and recent.^{16,17}

Conversely, LDT transfer was initially described by Gerber et al.¹ in 1992, and there are several publications about its results, including long-term ones.^{2,11,18} Among

them, several authors have demonstrated the possibility of obtaining good outcomes.^{2,9-11,19,20} However, up to 36% of clinical failures (as well as 38% of transfer tears) were found.²¹ In addition to that, findings about the predictive factors of bad results are still scarce and controversial.^{2,4,22,23}

There is, however, evidence that most failures are due to one of the following reasons: (1) transfer rupture from the greater tuberosity,^{12,13} and (2) deltoid origin disruption.²⁴ As such, some authors have recently proposed changes to the original Gerber technique. The use of arthroscopy^{8,12,21} or a single approach,⁹ for instance, has been recommended to prevent deltoid violation. Latissimus dorsi detachment along with some bone fragments of the humeral cortex has been recommended to reinforce the healing of the transfer along the greater tuberosity.¹³

Nonetheless, the current literature lacks a technique that simultaneously prevents these two complications. With this in mind, we have proposed and recently published²⁵ the following modifications to the surgical technique: the LDT is elongated and reinforced with a tendinous allograft, enabling its transfer to be performed through a single deltopectoral approach.

The primary objective of the present paper is to assess, through a retrospective analysis of cases, the short-term functional results of shoulders that have been submitted to this technique. The secondary objective is to analyze possible pre and intraoperative variables that may influence the outcomes.

Materials and Methods

The surgical technique used, and the rehabilitation protocol followed were the same as those of the technique previously published.²⁵ It is summarized in **–Figs. 1–2** through **3**.

Between November 2013 and August 2018, we performed the aforementioned technique²⁵ in 20 patients with irreparable posterosuperior rotator cuff tears (RCTs). Their medical records were retrospectively evaluated for data related to epidemiological as well as pre and postoperative clinical findings.

The surgery was proposed to patients after failure of conservative treatment with physiotherapy, and only after explaining that there would be no expectation of full functional recovery.

Diagnosis was performed by MRI and confirmed intraoperatively. Fatty infiltration of subscapularis, supraspinatus, and infraspinatus were classified according to the Goutallier Classification, modified by Fuchs et al.²⁶ Likewise, preoperative radiographs were used for the Hamada classification.²⁷

Irreparability of tendons was determined by intraoperative impossibility of its reduction to the greater tuberosity with the shoulder at 45° of abduction, after proper tendon release.⁶ In every patient in this study, no partial repair was possible due to tendon retraction.

Both pre and postoperatively active and passive range of motions (ROMs) were registered according to the method proposed by the American Academy of Orthopedic Surgeons.²⁸ Pre and postoperative functions were evaluated according to the University of California, Los Angeles (UCLA)'s score, as modified by Ellman et al.²⁹

The inclusion criteria were adult patients with irreparable RCTs treated with this technique, and with a minimum postoperative follow-up of 1 year. The exclusion criteria were no consent to participate in the study, noncompliance to rehabilitation protocol, and previous shoulder surgery.

Out of the 20 operated patients, 16 met the inclusion criteria (three exclusions occurred due to short follow-up, and one due to noncompliance to rehabilitation protocol

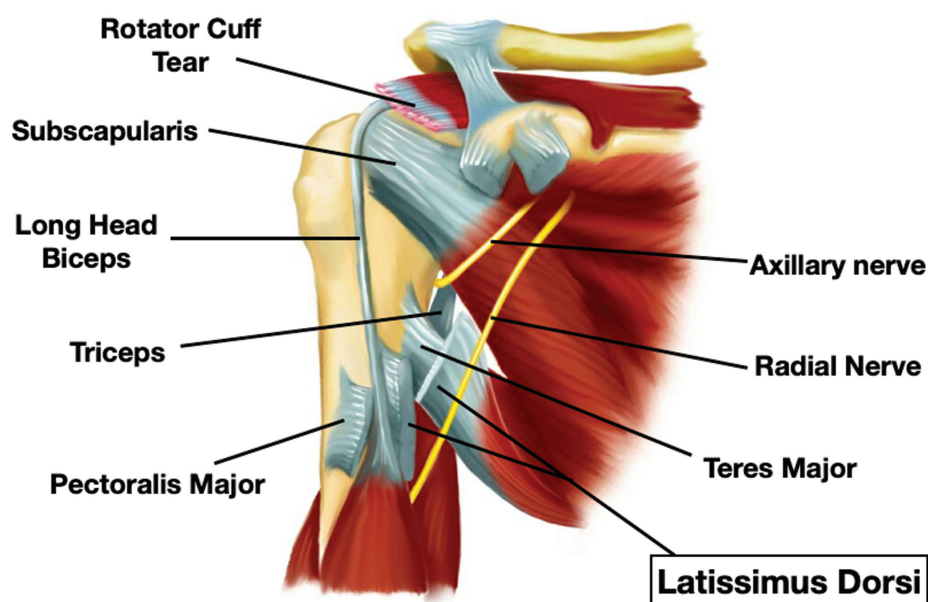


Fig. 1 Illustration of a right shoulder (anterior view) depicting the anatomical structures (the pectoralis major has been tenotomized and retracted; the latissimus dorsi tendon humerus insertion has already been detached).

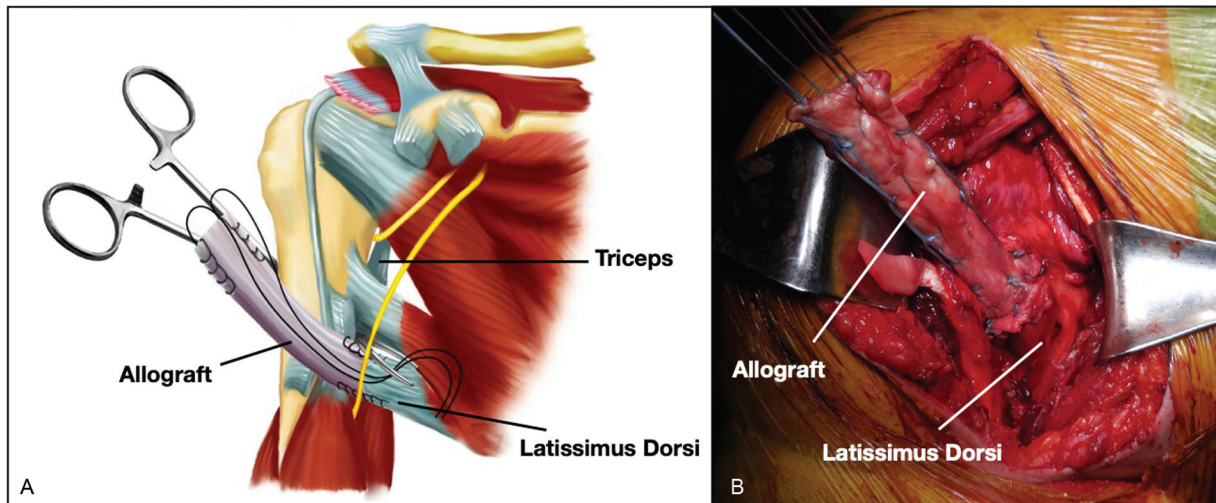


Fig. 2 (A) Illustration of a right shoulder (anterior view), showing the surgical step in which the tendinous allograft has already been sutured to the native latissimus dorsi tendon and a surgical tweezer has been passed posterior to the humeral shaft. (B) Intraoperative photograph of a right shoulder during this surgical step.

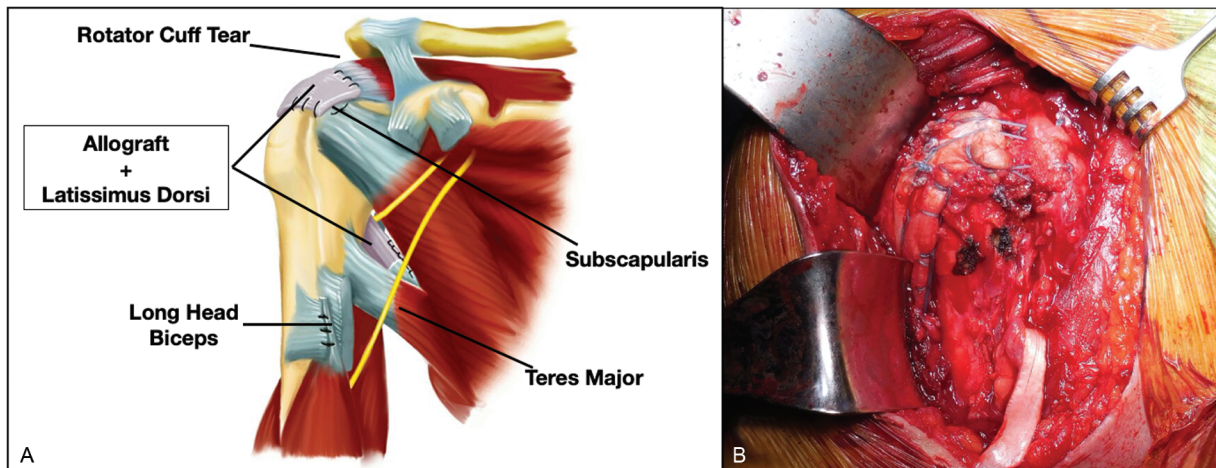


Fig. 3 (A) Illustration (anterior view) and (B) photograph (lateral view) showing the final aspect of surgery, where the elongated latissimus dorsi tendon transfer is sutured to the posterolateral aspect of the greater tuberosity.

[suffered a stroke 3 months after surgery]). Six (37.5%) were male and 10 (62.5%) were female. The average age at surgery was 65 years (56 to 82 years). Thirteen were dominant shoulders (81%). The etiology was traumatic in 8 patients (50%) and degenerative in 8 (50%) (►Table 1).

The average period from symptoms until surgery was 32 months (7 to 96 months), with a follow-up period of at least 12 months and no longer than 47 (average of 21 months) (►Table 1).

Supraspinatus Goutallier classifications were: three cases as grade II, eight as grade III, and eight as grade IV (►Table 1).

There were two subscapularis tears, and they were all limited to the proximal half of their respective tendons. They were all repairable tears. The proximal half of the muscle bellies of these two cases were classified as Goutallier grade IV (the distal halves were grade 0) (►Table 1).

Eleven shoulders were classified as Hamada grade 1, 3 as grade 2, 1 as grade 3, and 1 as grade 4B (►Table 1).

Eight of the allografts used were patellar tendons, six were fasciae latae, and one was a quadriceps tendon. All of them were frozen allografts (►Table 1).

The average preoperative results were compared with the average postoperative results (►Table 2). Furthermore, patients were split into subgroups for average results comparison concerning the following variables:

- Age at the time of surgery
- Preoperative active forward flexion (six pseudoparetic [from zero to 90°] versus 10 nonpseudoparetic [higher than 90°]) (►Table 3).
- Time span between 1st symptoms and surgery (10 shorter than 26 months versus 6 longer than 35 months)
- Type of allograft used (eight fasciae latae versus seven patellar tendon).
- Etiology of RCT (atraumatic versus traumatic).
- Postoperative follow-up period (9 shorter than 17 months versus 7 longer 18 months).

Table 1 Preoperative data

Case #	Gender	Age	Dominance	Trauma?	Symptoms (in months)	Goutallier			HAMADA	Graft	Follow-up (in months)
						SUPRA	INFRA	SUBSCAP			
1	M	77	+	-	36	3	3	1	1	Patellar	13
2	M	56	-	-	24	2	3	1	2	Fascia Lata	13
3	M	61	-	+	25	3	4	0	2	Patellar	21
4	F	52	+	+	10	3	4	1	1	Patellar	31
5	F	63	+	+	24	4	4	0	1	Patellar	43
6	F	68	+	-	36	4	4	4	1	Fascia Lata	12
7	F	64	+	-	96	4	4	4	3	Patellar	47
8	F	68	+	+	52	2	2	2	4B	Quadricipital	19
9	M	68	+	+	7	3	3	0	1	Fascia Lata	15
10	F	59	+	-	17	2	3	0	1	Fascia Lata	15
11	F	67	+	-	36	3	3	1	2	Fascia Lata	16
12	F	56	+	-	24	4	4	0	1	Fascia Lata	14
13	F	61	+	+	23	3	3	2	1	Patellar	28
14	F	82	+	+	24	4	4	2	1	Patellar	19
15	M	67	-	+	7	3	3	1	1	Fascia Lata	12
16	M	67	+	+	72	3	3	1	1	Fascia Lata	15
AVERAGE		65			32						21

Abbreviations: Age, age at time of surgery; F, female; INFRA, infraspinatus; M, male; SUBSCAP, subscapularis; SUPRA, supraspinatus; Trauma?, Traumatic etiology?.

Comparisons of continuous variables within the same group were done through paired *t*-tests. Comparisons of continuous variables between different groups were done through unpaired *t*-tests. Correlations between continuous variables were determined by calculating the Pearson correlation coefficient. Values of $p \leq 0.05$ were considered significant.

Results

The average postoperative follow-up was 21 months (12–47 months) (► **Table 1**). The passive range of motion (ROM) in all shoulders was normal, equal to the contralateral shoulder, including case 8 (► **Table 1**), classified as Hamada 4B.

The average active forward flexion (FF) was 106° preoperatively (70–104°) and 145° postoperatively (50–160°) ($p < 0.001$). The average preoperative active external rotation was 30° (0–60° and postoperative average was 54° (40–70°) ($p < 0.001$). The active internal rotation averaged at L1 preoperatively (range gluteus to T5), and at T10 postoperatively ($p = 0.017$) (► **Table 2**).

According to the UCLA's score, there were 71% (12 patients) of good results (≥ 28 points) and 29% (5 patients) of fair and poor results (≤ 27 points). The average preoperative score was 11.63 (range 8 to 16) while the postoperative average was 27.38 (range 17–30) ($p < 0.001$). The comparisons of pre and postoperative average results for each of the UCLA subscores were statistically significant in all cases (for all five subscores $p < 0.001$) (► **Table 2**).

Comparing the results from subgroups, we found the following:

- For age at the time of surgery, time span between first symptoms and surgery, type of allograft used, etiology of RCT, and postoperative follow-up period, the comparisons of average gains (postoperative results subtracted from preoperative results) from all variables related to the active ROM and the UCLA score did not result in any statistically significant difference.

Those with preoperative pseudoparesis (average forward flexion [FF] at 75°, ranging from 70–90°) and 10 without (average FF at 124.5°, ranging from 100–140°) ($p < 0.001$). The comparisons of both groups' average gains (postoperative results subtracted from preoperative results) did not result in any statistically significant difference concerning external rotation, internal rotation, or the following UCLA score criteria: pain, function, strength, satisfaction, and total score. However, there was a statistically significant difference concerning the FF range improvement, which was 73.33 degrees for pseudoparetic patients and 18.5 degrees for nonpseudoparetic ($p < 0.001$), as well as in the UCLA's forward flexion score, which was 2.83 points for pseudoparetic patients and 0.7 for nonpseudoparetic patients ($p < 0.001$). As shown in the last line of ► **Table 3**, this difference in FF gain was able to promote statistically equivalent results in both groups, which was 148.33 degrees for pseudoparetic patients and 143 degrees for nonpseudoparetic patients ($p = 0.41$), therefore showing that pseudoparesis was not a predictor of worse outcome (► **Table 3**).

Table 2 Comparison between pre and postoperative results

Case #	ROM			UCLA														
	FLEX PRE	FLEX POST	EXT ROT PRE	EXT ROT POST	INT ROT PRE	INT ROT POST	PAIN PRE	PAIN POST	FUNCTION PRE	FUNCTION POST	FLEX PRE	FLEX POST	STRENGTH PRE	STRENGTH POST	SATISF PRE	SATISF POST	TOTAL PRE	TOTAL POST
1	70	160	45	70	Gluteus	T12	4	8	4	8	3	5	3	3	0	5	14	29
2	70	150	0	45	Gluteus	T3	2	8	2	8	2	5	2	3	0	5	8	29
3	120	160	0	50	T9	T5	6	8	2	4	3	4	2	3	0	5	13	24
4	140	150	50	60	T10	T12	2	6	2	6	4	5	3	4	0	5	11	26
5	120	160	40	45	T10	T8	4	8	4	8	4	5	3	4	0	5	15	30
6	120	140	45	45	T12	L1	4	8	4	6	4	4	3	3	0	5	15	27
7	70	160	45	60	T12	T10	1	5	4	8	2	5	2	3	0	5	9	26
8	130	140	30	60	Gluteus	T7	2	8	2	8	4	5	3	4	0	5	11	30
9	120	140	20	50	T12	T12	1	10	1	8	3	3	2	4	0	5	7	30
10	80	160	60	60	T12	T12	4	8	2	8	1	5	2	4	0	5	9	30
11	130	130	45	45	T10	T10	2	2	8	8	3	3	3	4	0	0	16	17
12	140	140	50	60	T7	T7	2	10	8	8	3	3	3	4	0	5	16	30
13	125	140	30	70	T9	T10	2	10	4	8	3	5	2	4	0	5	11	29
14	90	130	0	60	L5	T12	4	6	2	6	1	3	1	3	0	5	8	23
15	100	130	20	40	T12	T9	4	8	4	8	3	4	2	4	0	5	13	29
16	70	130	0	40	Gluteus	T12	4	8	2	8	1	4	3	4	0	5	10	29
AVERAGE	105.94	145	30	53.75	L1	T10	3.00	7.56	3.44	7.38	2.75	4.25	2.44	3.63	0.00	4.69	11.63	27.38
P	< 0.001		< 0.001				< 0.001		< 0.001		< 0.001		< 0.001		< 0.001		< 0.001	

Abbreviations: EXT ROT, external rotation; FLEX, forward flexion; UCLA - FLEX, active forward flexion subscore; UCLA - FUNCTION, function subscore; INT ROT, internal rotation; UCLA - PAIN, pain subscore; POST, postoperative; PRE, preoperative; ROM, range of motion; UCLA - SATIF, satisfaction of the patient subscore; UCLA - STRENGTH, strength of forward flexion subscore; UCLA - TOTAL, total score (sum of the previous 5 subscores); UCLA, University of California, Los Angeles shoulder score.

Table 3 Comparison of pseudoparetic and nonpseudoparetic patients

Average gain of	PSEUDOPARETIC (6 cases)	NONPSEUDOPARETIC (10 cases)	p
ROM - FLEX	73.33°	18.5°	< 0.001 ***
ROM - EXT ROT	30.83°	19.5°	0.27
ROM - INT ROT	6.17°	1.7°	0.09
UCLA - PAIN	4	4.9	0.48
UCLA - FUNCTION	5	3.3	0.12
UCLA - FLEX	2.83	0.7	< 0.001 ***
UCLA - STRENGTH	1.17	1.2	0.925
UCLA - SATISF	5	4.5	0.458
UCLA - TOTAL	18	14.4	0.183
ROM - FLEX PREOP	75°	124.5°	< 0.001 ***
ROM - FLEX POSTOP	148.33°	143°	0.41

Abbreviations: EXT ROT, external rotation; FLEX, forward flexion; UCLA - FLEX, active forward flexion subscore; UCLA - FUNCTION, function subscore; INT ROT, internal rotation; UCLA - PAIN, pain subscore; POSTOP, postoperative; PREOP, preoperative; ROM, range of motion; UCLA - SATISF, satisfaction of the patient subscore; UCLA - STRENGTH, strength of forward flexion subscore; UCLA - TOTAL, total score (sum of the previous 5 subscores); UCLA, University of California, Los Angeles shoulder score.

*** = Statistically significant difference.

Discussion

The main objectives of LDT transfer for treating irreparable RCTs are improvements in shoulder's active ROM, pain, function, and strength, as well as improvement in patient satisfaction. As shown in the results, all of these objectives have been met.

The improvements obtained in active external rotation, internal rotation, and FF ROM were similar to those of other published works,^{1,2,9-11,19,20} with average gains of 39 degrees ($p < 0.001$), 3 vertebral levels ($p = 0.017$) and 24 degrees ($p < 0.001$), respectively (► **Table 2**).

This technique seems effective in improving pain relief, considering the average gain of 4.53 points ($p < 0.001$) to the UCLA score criterion for pain (which ranges from 0-10), besides also being efficient to improve shoulder function, as we can see with the average gain of 3.71 points ($p < 0.001$) to the UCLA score criterion for function (which ranges from 0-10). Both findings were similar to those of most other works,^{1,2,9-11,19,20} such as Grimberg et al.,⁸ which reported an average gain of 28.4 points (from 37.0-65.4) to the overall Constant score, as well as an average gain of 10.9 points (from 1.7 preop to 12.6 postop) to pain as a Constant subscore.

The improvements to FF strength occurred in all patients, except in the first two cases, in whom strength remained the same. However, in no case did it return to normal (grade 5), remaining at grade 3 in 6 patients, and at degree 4 in 5 patients. One concern is that the elongation of the transferred tendon could harm the shoulder's FF strength. However, analysis of the literature shows that the strength recovery was very similar to that of other series (no graft used),^{2,8-11,19,30} such as Gerber et al.,³⁰ which obtained mean strength improvement from 0.9 kg preoperatively to 1.8 kg postoperatively ($p < 0.0001$) in the 65 shoulders that were evaluated.

Surprisingly, and contrary to the findings of Iannotti et al.¹⁰ (conventional technique), pseudoparesis was re-

solved in all cases. We believe this occurred because the tendon grafts used were thicker than the native LDT and, therefore, could also have worked as a subacromial spacer. Thus, it would be easier to maintain stability to the shoulder center of rotation, favoring the deltoid's FF function.

According to the UCLA score, we have obtained 71% of good results and 29% of fair and poor results. Such findings are similar to those in the literature, where around 30% of unsatisfactory results are found, such as the findings of Kany et al.²¹ Despite these unsatisfactory results, we believe these patients will have fewer complications at medium and long terms, since this technique is possibly less prone to new ruptures, as Kany et al.¹² have shown from 15 to 46% of ruptures in arthroscopic LDTs at 3 months of postoperative follow-up.

Reverse shoulder arthroplasty (RSA) is arguably the last surgical resource after failure of a tendon transfer. However, for an RSA to work, a functioning deltoid is required, because it is the last motor unit available capable of generating upward force vectors that would result in FF.² Thus, we can argue that it is extremely wise to avoid any deltoid surgical violation, as it is performed in superior approaches. Therefore, only three deltoid-sparing surgical approaches are available: a single posterior approach; an axillary approach followed by an arthroscopic one; and a single anterior approach.

The major shortcoming of a single posterior approach is that it precludes treatment of lesions to the long head of the biceps and to the subscapularis tendon.

Similarly, an axillary approach does not allow an eventual primary repair of the RCT, which should always be attempted before performing any tendon transfer.

The advantages of a single deltopectoral approach are that it is a customary approach; it allows primary repair of the RCT when possible; and that long head of the biceps and subscapularis lesions can be easily treated. Its only

disadvantage is the impossibility of dissecting the latissimus dorsi muscle belly, therefore preventing it from being pulled to the upper portion of the humeral head. However, given that this tendon is extremely thin and friable, it is recommended that its insertion to the greater tuberosity be somehow reinforced, since its postoperative rupture, which usually occurs in the first 2 years of postoperative follow-up, is one of the few statistically proven predictors of poor functional results.² Therefore, we believe that the use of a tendon graft may be able to simultaneously solve both problems: it allows the use of a single (deltoid-sparing) approach and it reinforces the insertion of the tendon to the greater tuberosity.

There are concerns about three possible complications: (1) fragility between the graft and the native tendon; (2) the allograft's ability to heal to the bone; and (3) the possibility of the LDT being too elongated, overly reducing the resulting final strength on the humerus. Although the present work hasn't directly evaluated these three possible complications, they did not seem to occur, since all patients have shown improvements in the UCLA strength score, as previously discussed.

As a secondary objective, we have assessed whether some preoperative (age, pseudoparesis, symptom duration, and etiology of RCT), intraoperative (the type of allograft used), and postoperative ("follow-up period") variables have influenced the results. Despite the limited number of patients, the results have shown that none of them have significantly influenced the outcomes.

It is worth pointing out cases 6 and 7, which had complete tears of the proximal subscapularis half. Both had their tears repaired (at the same time of the transfer), and both had noticeable improvement of shoulder motion and UCLA score (► **Tables 1** and **2**). Likewise, cases 7 and 8 had advanced joint degeneration (Hamada 3 and 4B, respectively), and they also were able to recover shoulder ROM and achieve noticeable improvement of UCLA score (► **Tables 1** and **2**).

Lastly, it is worth highlighting the flaws of this work: as a retrospective analysis of cases, there was no control group and, therefore, all of the comparisons had to be done with preoperative findings or findings from other published works that have used different methodologies. Also, even though the sample loss was of only 20% (or 4 cases), the total number of evaluated cases was small, compromising the power of statistical analysis.

Conclusion

At short and medium follow-ups, the studied technique was effective as a treatment for irreparable posterosuperior RCTs, with 71% of satisfactory results. None of the evaluated variables, including preoperative pseudoparesis, has influenced the final outcomes.

Financial Support

There was no financial support from public, commercial, or non-profit sources.

Conflict of Interests

All authors declare that there is no conflict of interests.

References

- Gerber C. Latissimus dorsi transfer for the treatment of irreparable tears of the rotator cuff. *Clin Orthop Relat Res* 1992;(275): 152-160
- El-Azab HM, Rott O, Irlenbusch U. Long-term follow-up after latissimus dorsi transfer for irreparable posterosuperior rotator cuff tears. *J Bone Joint Surg Am* 2015;97(06):462-469
- Mulieri P, Dunning P, Klein S, Pupello D, Frankle M. Reverse shoulder arthroplasty for the treatment of irreparable rotator cuff tear without glenohumeral arthritis. *J Bone Joint Surg Am* 2010;92(15):2544-2556
- Gerber C, Canonica S, Catanzaro S, Ernstbrunner L. Longitudinal observational study of reverse total shoulder arthroplasty for irreparable rotator cuff dysfunction: results after 15 years. *J Shoulder Elbow Surg* 2018;27(05):831-838
- Westermann RW, Pugely AJ, Martin CT, Gao Y, Wolf BR, Hettrich CM. Reverse Shoulder Arthroplasty in the United States: A Comparison of National Volume, Patient Demographics, Complications, and Surgical Indications. *Iowa Orthop J* 2015;35:1-7
- Checchia C, Domos P, Grimberg J, Kany J. Current Options in Tendon Transfers for Irreparable Rotator Cuff Tears. *JBJS Rev* 2019; 7(02):e6
- Castricini R, Longo UG, De Benedetto M, et al. Arthroscopic-Assisted Latissimus Dorsi Transfer for the Management of Irreparable Rotator Cuff Tears: Short-Term Results. *J Bone Joint Surg Am* 2014;96(14):e119
- Grimberg J, Kany J, Valenti P, Amaravathi R, Ramalingam AT. Arthroscopic-assisted latissimus dorsi tendon transfer for irreparable posterosuperior cuff tears. *Arthroscopy* 2015;31(04): 599-607.e1
- Habermeyer P, Magosch P, Rudolph T, Lichtenberg S, Liem D. Transfer of the tendon of latissimus dorsi for the treatment of massive tears of the rotator cuff: a new single-incision technique. *J Bone Joint Surg Br* 2006;88(02):208-212
- Iannotti JP, Hennigan S, Herzog R, et al. Latissimus dorsi tendon transfer for irreparable posterosuperior rotator cuff tears. Factors affecting outcome. *J Bone Joint Surg Am* 2006;88(02):342-348
- Irlenbusch U, Bracht M, Gansen H-K, Lorenz U, Thiel J. Latissimus dorsi transfer for irreparable rotator cuff tears: a longitudinal study. *J Shoulder Elbow Surg* 2008;17(04):527-534
- Kany J, Sekaran P, Grimberg J, et al. Risk of latissimus dorsi tendon rupture after arthroscopic transfer for posterior superior rotator cuff tear: a comparative analysis of 3 humeral head fixation techniques. *J Shoulder Elbow Surg* 2020;29(02):282-290
- Moursy M, Forstner R, Koller H, Resch H, Tauber M. Latissimus dorsi tendon transfer for irreparable rotator cuff tears: a modified technique to improve tendon transfer integrity. *J Bone Joint Surg Am* 2009;91(08):1924-1931
- Mihata T, Lee TQ, Fukunishi K, et al. Return to Sports and Physical Work After Arthroscopic Superior Capsule Reconstruction Among Patients With Irreparable Rotator Cuff Tears. *Am J Sports Med* 2018;46(05):1077-1083
- Burkhart SS, Hartzler RU. Superior Capsular Reconstruction Reverses Profound Pseudoparesis in Patients With Irreparable Rotator Cuff Tears and Minimal or No Glenohumeral Arthritis. *Arthroscopy* 2019;35(01):22-28
- Aibinder WR, Elhassan BT. Lower trapezius transfer with Achilles tendon augmentation: indication and clinical results. *Obere Extremität* 2018;13(04):269-272
- Elhassan BT, Wagner ER, Werthel JD. Outcome of lower trapezius transfer to reconstruct massive irreparable posterior-superior rotator cuff tear. *J Shoulder Elbow Surg* 2016;25 (08):1346-1353

- 18 Gerber C, Rahm SA, Catanzaro S, Farshad M, Moor BK. Latissimus dorsi tendon transfer for treatment of irreparable posterosuperior rotator cuff tears: long-term results at a minimum follow-up of ten years. *J Bone Joint Surg Am* 2013;95(21):1920–1926
- 19 Grimberg J, Kany J. Latissimus dorsi tendon transfer for irreparable postero-superior cuff tears: current concepts, indications, and recent advances. *Curr Rev Musculoskelet Med* 2014;7(01):22–32
- 20 Warner JJ. Management of massive irreparable rotator cuff tears: the role of tendon transfer. *Instr Course Lect* 2001;50:63–71
- 21 Kany J, Grimberg J, Amaravathi RS, Sekaran P, Scorpie D, Werthel JD. Arthroscopically-Assisted Latissimus Dorsi Transfer for Irreparable Rotator Cuff Insufficiency: Modes of Failure and Clinical Correlation. *Arthroscopy* 2018;34(04):1139–1150
- 22 Costouros JG, Espinosa N, Schmid MR, Gerber C. Teres minor integrity predicts outcome of latissimus dorsi tendon transfer for irreparable rotator cuff tears. *J Shoulder Elbow Surg* 2007;16(06):727–734
- 23 Lehmann LJ, Cafaltzis K, Hünnebeck S, Moursy M. Are there any prognostic prediction parameters (PPPs) in the treatment of the massive rotator cuff tear with latissimus dorsi transfer? Latissimus dorsi transfer in massive rotator cuff tears. *Acta Chir Orthop Traumatol Cech* 2013;80(02):125–130
- 24 Sher JS, Iannotti JP, Warner JJ, Groff Y, Williams GR. Surgical treatment of postoperative deltoid origin disruption. *Clin Orthop Relat Res* 1997;(343):93–98
- 25 Miyazaki AN, Checchia CS, de Castro Lopes W, Fonseca Filho JM, Sella GDV, da Silva LA. Latissimus Dorsi Tendon Transfer using Tendinous Allograft for Irreparable Rotator Cuff Lesions: Surgical Technique. *Rev Bras Ortop (Sao Paulo)* 2019;54(01):99–103
- 26 Fuchs B, Weishaupt D, Zanetti M, Hodler J, Gerber C. Fatty degeneration of the muscles of the rotator cuff: assessment by computed tomography versus magnetic resonance imaging. *J Shoulder Elbow Surg* 1999;8(06):599–605
- 27 Hamada K, Fukuda H, Mikasa M, Kobayashi Y. Roentgenographic findings in massive rotator cuff tears. A long-term observation. *Clin Orthop Relat Res* 1990;(254):92–96
- 28 Codi M. Clinical evaluation of shoulder problems. In: Rockwood CA Jr, Matsen FA 3rd, Wirth MA, Lippitt SB, editors. *The shoulder*. 4th ed. Philadelphia, PA: Saunders Elsevier; 2009:148–176
- 29 Ellman H, Hanker G, Bayer M. Repair of the rotator cuff. End-result study of factors influencing reconstruction. *J Bone Joint Surg Am* 1986;68(08):1136–1144
- 30 Gerber C, Maquieira G, Espinosa N. Latissimus dorsi transfer for the treatment of irreparable rotator cuff tears. *J Bone Joint Surg Am* 2006;88(01):113–120