



Atypical femur fractures associated with chronic bisphosphonates use: A case series with 66 patients*

Fraturas atípicas do fêmur associadas ao uso crônico de bisfosfonatos: Uma série de casos de 66 pacientes

Guilherme Guadagnini Falotico¹ Jose Fernando Flores Cunza¹ Gabriel Ferraz Ferreira¹
Victor Otávio Oliveira¹ Daniel Oksman¹ Gustavo Gonçalves Arliani¹

¹ Department of Orthopedics and Traumatology, Instituto Prevent Senior, São Paulo, SP, Brazil

Address for correspondence Gabriel Ferraz Ferreira, MD, MSc, Rua Cerro Corá, 585, Sala 605, Torre 1, São Paulo, SP, Brazil (e-mail: gabriel.ferraz38@yahoo.com.br).

Rev Bras Ortop 2022;57(5):851–855.

Abstract

Objective The present study aims to describe outcomes from a series of surgically treated patients with atypical femoral fracture due to bisphosphonates use, in addition to correlate the time of previous medication use with fracture consolidation time, and to compare the consolidation time of complete and incomplete fractures.

Methods This is an observational, retrospective study with 66 patients diagnosed with atypical femur fractures associated with chronic bisphosphonates use. The patients underwent orthopedic surgical treatment at a referral hospital from January 2018 to March 2020.

Results All patients were females, with two bilateral cases. Fracture consolidation occurred in all cases, with an average time of 2.3 months and a follow-up time of 5.8 months. The average time of bisphosphonates use was 7.8 years. There was no correlation between the time of previous bisphosphonates use and the time for fracture consolidation. Consolidation time differed in complete and incomplete fractures.

Conclusion Surgical treatment with a long cephalomedullary nail resulted in consolidation in all patients. The consolidation time was longer in complete fractures when compared with incomplete lesions, and there was no correlation between the time of previous bisphosphonates use and the consolidation time.

Level of evidence Level IV, case series

Keywords

- ▶ femoral fractures
- ▶ bisphosphonate
- ▶ osteoporosis

* Study developed at the Department of Orthopedics and Traumatology, Instituto Prevent Senior, São Paulo, SP, Brazil.

received
September 16, 2020
accepted
December 1, 2020
published online
March 31, 2021

DOI <https://doi.org/10.1055/s-0041-1726066>.
ISSN 0102-3616.

© 2021. Sociedade Brasileira de Ortopedia e Traumatologia. All rights reserved.

This is an open access article published by Thieme under the terms of the Creative Commons Attribution-NonDerivative-NonCommercial-License, permitting copying and reproduction so long as the original work is given appropriate credit. Contents may not be used for commercial purposes, or adapted, remixed, transformed or built upon. (<https://creativecommons.org/licenses/by-nc-nd/4.0/>)

Thieme Revinter Publicações Ltda., Rua do Matoso 170, Rio de Janeiro, RJ, CEP 20270-135, Brazil

Resumo

Objetivo Descrever os resultados de uma série de pacientes tratados cirurgicamente com diagnóstico de fratura femoral atípica associada ao uso de bisfosfonatos, assim como correlacionar o tempo de uso prévio da medicação com o tempo de consolidação da fratura e comparar o tempo de consolidação das fraturas completas e incompletas.

Métodos Trata-se de um estudo observacional e retrospectivo de 66 pacientes com diagnóstico de fratura atípica do fêmur associada ao uso crônico de bisfosfonatos. Os pacientes foram submetidos ao tratamento cirúrgico ortopédico em hospital de referência no período de janeiro de 2018 a março de 2020.

Resultados Os pacientes incluídos no estudo eram todos do sexo feminino, com dois casos bilaterais. A consolidação da fratura ocorreu em todos os casos com tempo médio de 2,3 meses e seguimento de 5,8 meses. O tempo médio de uso de bisfosfonatos foi de 7,8 anos. Não houve correlação do tempo de uso prévio de bisfosfonatos com o tempo de consolidação das fraturas. Houve uma diferença do tempo de consolidação entre as fraturas completas e incompletas.

Conclusão Houve consolidação após tratamento cirúrgico com haste cefalomedular longa em todos os pacientes do presente estudo, sendo o tempo de consolidação maior nas fraturas completas em relação às incompletas, e não houve correlação entre o tempo de uso prévio de bisfosfonatos e o tempo de consolidação.

Nível de evidência Nível IV, série de casos

Palavras-chave

- ▶ fraturas do fêmur
- ▶ bisfosfonato
- ▶ osteoporose

Introduction

Osteoporosis is defined as gradual, progressive reduction of bone mass. The main risk factors for osteoporosis include a sedentary lifestyle, alcoholism, smoking, prolonged use of corticosteroids, and a reduced calcium and vitamin D bio-availability.¹ Hip, spinal, distal radial, and proximal humeral fractures are the most associated with osteoporosis.² Medical treatment of osteoporosis is recommended as primary prevention for these fractures, with bisphosphonates as first-line drugs.³

Prolonged bisphosphonates use can result in a progressive loss of bone elastic properties,⁴ representing a risk factor for atypical femoral fractures. These injuries are defined as both incomplete (affecting the lateral cortex alone) and complete (in a transverse pattern) fractures occurring between the lesser trochanter and the supracondylar region of the femur (subtrochanteric or diaphyseal fracture) after minimal trauma.⁵⁻⁸

The risk for atypical fracture increases in people using oral bisphosphonates for > 3 years (average treatment, 7 years). The absolute risk in females is three times higher when compared with males, and alendronate is associated with the highest risk for atypical fractures.⁵

The literature describes good outcomes from the treatment of these fractures using intramedullary nails.⁹ However, the consolidation time is often quite prolonged, potentially because bisphosphonates acts on the soft callus to suppress its remodeling.¹⁰

The present study aims to describe outcomes from a series of surgically treated patients with atypical femoral fractures due to bisphosphonates use, to correlate the time of previous medication use with fracture consolidation time, and to

compare the consolidation time in complete and incomplete fractures.

Material and Methods

This is an observational, retrospective study with 66 patients (2 bilateral cases), totaling 68 atypical femur fractures associated with chronic bisphosphonates use. The patients underwent orthopedic surgical treatment at a referral hospital from January 2018 to March 2020.

Inclusion and exclusion criteria

The following inclusion criteria were applied: 1) symptomatic complete and incomplete atypical femur fractures; 2) chronic (> 5 years) bisphosphonates use; 3) age > 60 years old.

The following exclusion criteria were applied: 1) previous or current ipsilateral osteoarticular hip infection; 2) typical femoral osteoporotic fractures (femoral neck, transtrochanteric, subtrochanteric injuries); 3) pathological fractures associated with primary or metastatic tumors and other bone conditions (for example, Paget disease or fibrous dysplasia).

Data Collection, Radiographic Evaluation, and Surgical Technique

Data were collected directly from the electronic medical records of the hospital after approval by the ethics committee. Variables included gender, age, body mass index (BMI), and time of previous continuous bisphosphonates use.

Radiographic images were obtained in a standardized manner on a digital device with a predefined 100% magnification. Images were analyzed digitally with the Centricity

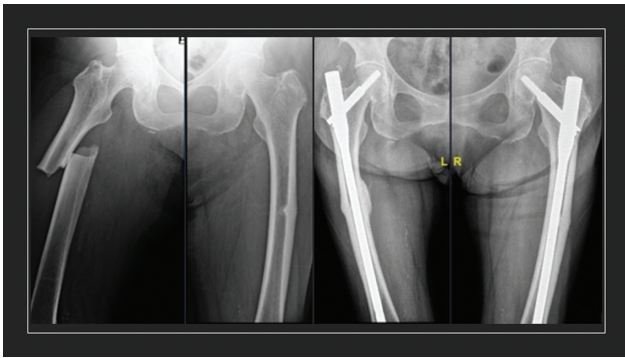


Fig. 1 (A) Preoperative radiographic image of an atypical bilateral fracture. (B) Radiographic image 7 months after surgery.

Universal Viewer Zero Footprint software (GE Healthcare, Barrington, IL, USA). Consolidation was defined by the formation of bridge calluses in at least three cortical layers in two radiographic views (anteroposterior and lateral views), using the reliability of the radiographic union scale in tibial fractures (RUST) score expanded for femoral fracture consolidation.¹¹

The lack of radiographic signs of consolidation after ≥ 6 months postoperatively was defined as pseudoarthrosis. All radiographic evaluations were performed independently by 2 orthopedists with > 5 years of experience. If there was no consensus among the evaluators, the final decision was taken by the senior researcher of the study.

All patients were submitted to surgical treatment with closed reduction on an orthopedic table, using a long cephalomedullary nail, a cephalic screw with an antirotating device and a distal locking screw (\rightarrow **Figure 1**).

The postoperative procedures were standardized. Partial load with a walker was allowed as tolerated starting at the 1st postoperative day. The patients continued on motor physical therapy until fracture consolidation. Bisphosphonate therapy was suspended after fracture, and teriparatide, 20 mcg per day subcutaneously for 2 years, was indicated according to the institutional protocol. Follow-up was carried out at the outpatient clinic specialized in bone metabolism.

Statistical Analysis

Categorical variables were shown as proportions, and continuous variables as mean and standard deviation (SD) values. The Wilcoxon test compared continuous nonparametric variables after distribution assessment using the Shapiro test. All statistical evaluations were performed with the open-source Stats package from the R software (R Foundation, Vienna, Austria).¹² Variables were correlated using the Pearson test.

Results

All patients were females, and two cases were bilateral. The patients were followed-up on an outpatient basis until fracture consolidation, which occurred in all subjects. The average follow-up time was 5.8 months. The mean age was 78.4 years old, with a an SD value of 6.5. Most fractures

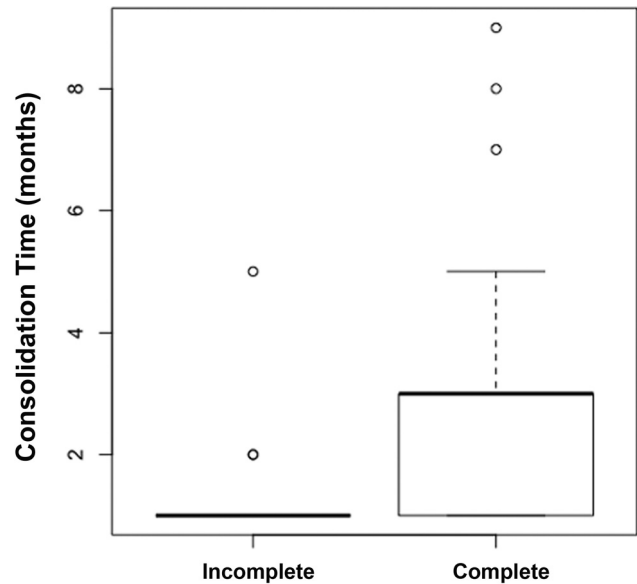


Fig. 2 Consolidation time (in months) in complete or incomplete fractures.

occurred on the left side (56.5%). The mean BMI was 26.6, with an SD value of 2.4.

Regarding fracture location, 65% were diaphyseal injuries and 45% occurred at the subtrochanteric region of the femur. Regarding the anatomical type of fracture, there were 55 cases of atypical complete fractures (81%), mostly transverse, followed by oblique fractures and 1 case of a simple wedge fracture. There were 13 cases of atypical incomplete fractures, representing $\sim 19\%$.

According to the radiographic analysis using the RUST score, fracture consolidation occurred in an average period of 2.3 months, with an SD value of 1.6. Incomplete fractures consolidated on an average period of 1.4 months, while complete fractures consolidated within 2.5 months; this difference was statistically significant ($p < 0.05$), as shown in \rightarrow **Figure 2**.

There was no evidence of a correlation between the time of previous bisphosphonate use and consolidation time, since the Pearson test revealed a correlation index of 0.05 and $p = 0.63$.

Cortical thickening was identified in all cases. The most common bisphosphonate was alendronate (84.0%), followed by risendronate (8.7%), ibandronate (4.3%), and pamidronate and denosumab (1.5% each).

The trauma mechanism was fall from own height in most cases (82.6%); there was no history of trauma in the remaining cases. Only 26% of the patients included in the study reported pain prior to the fracture. The mean time of bisphosphonates use was 7.8 years, with an SD value of 5.7 years.

Discussion

The main finding of the present study is the lack of correlation between the time of previous bisphosphonate use and the fracture consolidation time after treatment with a long

cephalomedullary nail. There was a statistically significant difference in the consolidation time when complete and incomplete fractures were compared.

Intramedullary fixation has biomechanical and biological advantages over plate osteosynthesis in atypical fractures.¹³ In a study, the plate failure rate was higher in atypical fractures (30%) when compared with typical fractures (0%). Patients treated with intramedullary nail presented a 98% consolidation rate, as in our study, with a long consolidation time (8.3 months).

Weil et al.¹⁴ showed that 7 (46%) of the 17 fractures treated with a long milled intramedullary nail required a revision surgery. The high failure rate was attributed to impaired bone healing related to the prolonged bisphosphonate therapy, not to the surgical technique. In addition, these authors observed differences in consolidation time between atypical femoral fractures submitted to anatomical and nonanatomical reduction; anatomically reduced fractures healed an average of 3.7 months faster than those fixed in a varus position.

Incomplete atypical femoral fractures represent a diagnostic challenge, as patients may only experience discomfort in the thigh when walking. Thus, diagnosis is often made only in the context of a complete fracture with major associated functional limitation. A plain radiograph of the contralateral femur is recommended in patients with complete fracture.¹⁵⁻¹⁷ As a result, prophylactic fixation is recommended to patients with persistent pain.

However, the decision to proceed with prophylactic surgery for an incomplete fracture is based on several factors, including the presence of a bilateral incomplete fracture, persistent pain, and a complete fracture on the opposite side. Prophylactic surgery may not be warranted in an asymptomatic patient.¹⁸ In the present study, incomplete fractures in symptomatic patients were surgically fixed.

The literature lacks definitive evidence regarding the consolidation time in surgically treated complete and incomplete fractures. Some studies report a longer consolidation time both in conservatively treated incomplete fractures and surgically treated complete fractures. Authors attribute these findings to the biological effect of bisphosphonate and to a reduction leaving a small diastasis at the fracture focus in some cases.^{17,19,20}

The average age described in the literature for patients with atypical femur fractures is ~ 75 years old,⁶ as in our study. Nevertheless, despite affecting elderly patients, atypical femur fractures are not associated with an increased mortality.⁷

Bisphosphonate treatment must be discontinued in patients with atypical femoral fractures.^{4,5,15,21} In addition, there is evidence that antiosteoporotic agents with potent bone-forming effects, such as strontium ranelate and especially teriparatide, can improve bone turnover and microarchitecture.^{22,23} After diagnosis, all patients in the present study stopped using bisphosphonate and were prescribed teriparatide.

Our study has some limitations. As it is retrospective, it suggests a potential information bias regarding data collec-

tion from medical records. In addition, the methodology employed in a single group does not allow a statistical verification of risk factors related to this type of fracture. For the future, the authors plan to assess risk factors in a case-control design and to establish a protocol for the prospective follow-up of patients with atypical fractures.

Conclusion

All patients presented consolidation after surgical treatment with a long cephalomedullary nail. The consolidation time was longer for complete fractures when compared with incomplete injuries. There was no correlation between the time of previous bisphosphonate use and the consolidation time for atypical femoral fractures.

Conflict of Interests

The authors no conflict of interests to declare.

References

- 1 Assessment of fracture risk and its application to screening for postmenopausal osteoporosis. Report of a WHO Study Group. World Health Organ Tech Rep Ser 1994;843:1-129
- 2 Cummings SR, Melton LJ. Epidemiology and outcomes of osteoporotic fractures. *Lancet* 2002;359(9319):1761-1767
- 3 Wells GA, Cranney A, Peterson J, et al. Alendronate for the primary and secondary prevention of osteoporotic fractures in postmenopausal women. *Cochrane Database Syst Rev* 2008;(01):CD001155
- 4 Odvina CV, Zerwekh JE, Rao DS, Maaouf N, Gottschalk FA, Pak CY. Severely suppressed bone turnover: a potential complication of alendronate therapy. *J Clin Endocrinol Metab* 2005;90(03):1294-1301
- 5 Shane E, Burr D, Abrahamsen B, et al. Atypical subtrochanteric and diaphyseal femoral fractures: second report of a task force of the American Society for Bone and Mineral Research. *J Bone Miner Res* 2014;29(01):1-23
- 6 Schilcher J, Michaëlsson K, Aspenberg P. Bisphosphonate use and atypical fractures of the femoral shaft. *N Engl J Med* 2011;364(18):1728-1737
- 7 Russell RG. Bisphosphonates: the first 40 years. *Bone* 2011;49(01):2-19
- 8 Dell RM, Adams AL, Greene DF, et al. Incidence of atypical non-traumatic diaphyseal fractures of the femur. *J Bone Miner Res* 2012;27(12):2544-2550
- 9 Giannoudis PV, Ahmad MA, Mineo GV, Tosounidis TI, Calori GM, Kanakaris NK. Subtrochanteric fracture non-unions with implant failure managed with the "Diamond" concept. *Injury* 2013;44(Suppl 1):S76-S81
- 10 Perren SM. Evolution of the internal fixation of long bone fractures. The scientific basis of biological internal fixation: choosing a new balance between stability and biology. *J Bone Joint Surg Br* 2002;84(08):1093-1110
- 11 Azevedo Filho FA, Cotias RB, Azi ML, Teixeira AA. Reliability of the radiographic union scale in tibial fractures (RUST). *Rev Bras Ortop* 2016;52(01):35-39
- 12 R: A language and environment for statistical computing. [computer program]. Vienna, Austria: R Foundation for Statistical Computing; 2013
- 13 Savaridas T, Wallace RJ, Salter DM, Simpson AH. Do bisphosphonates inhibit direct fracture healing?: A laboratory investigation using an animal model *Bone Joint J* 2013;95-B(09):1263-1268
- 14 Weil YA, Rivkin G, Safran O, Liebergall M, Foldes AJ. The outcome of surgically treated femur fractures associated with long-term bisphosphonate use. *J Trauma* 2011;71(01):186-190

- 15 Das De S, Setiobudi T, Shen L, Das De S. A rational approach to management of alendronate-related subtrochanteric fractures. *J Bone Joint Surg Br* 2010;92(05):679–686
- 16 Capeci CM, Tejawani NC. Bilateral low-energy simultaneous or sequential femoral fractures in patients on long-term alendronate therapy. *J Bone Joint Surg Am* 2009;91(11):2556–2561
- 17 Thompson RN, Phillips JR, McCauley SH, Elliott JR, Moran CG. Atypical femoral fractures and bisphosphonate treatment: experience in two large United Kingdom teaching hospitals. *J Bone Joint Surg Br* 2012;94(03):385–390
- 18 Wang K, Moaveni A, Dowrick A, Liew S. Alendronate-associated femoral insufficiency fractures and femoral stress reactions. *J Orthop Surg (Hong Kong)* 2011;19(01):89–92
- 19 Lee YK, Lee YJ, Lee NK, Nho JH, Koo KH. Low Positive Predictive Value of Bone Scan to Predict Impending Complete Fracture among Incomplete Atypical Femoral Fracture. *J Korean Med Sci* 2018;33(22):e157
- 20 Gustafsson A, Schilcher J, Grassi L, Aspenberg P, Isaksson H. Strains caused by daily loading might be responsible for delayed healing of an incomplete atypical femoral fracture. *Bone* 2016;88:125–130
- 21 Papakostidis C, Psyllakis I, Vardakas D, Grestas A, Giannoudis PV. Femoral-shaft fractures and nonunions treated with intramedullary nails: the role of dynamisation. *Injury* 2011;42(11):1353–1361
- 22 Goh SK, Yang KY, Koh JS, et al. Subtrochanteric insufficiency fractures in patients on alendronate therapy: a caution. *J Bone Joint Surg Br* 2007;89(03):349–353
- 23 Peichl P, Holzer LA, Maier R, Holzer G. Parathyroid hormone 1-84 accelerates fracture-healing in pubic bones of elderly osteoporotic women. *J Bone Joint Surg Am* 2011;93(17):1583–1587