

# WALANT Technique in Percutaneous Scaphoid Osteosynthesis\*

## WALANT na osteossíntese percutânea do escafoide

Celso Ricardo Folberg<sup>1</sup> Jairo Andre de Oliveira Alves<sup>2</sup> Fernando Maurenre Sirena Pereira<sup>2</sup>  
Vitor Bernardes Pedrozo<sup>3</sup>

<sup>1</sup>Hand Surgery Group, Orthopedics and Traumatology Service, Hospital de Clínicas de Porto Alegre (HCPA), Porto Alegre, RS, Brazil

<sup>2</sup>Hand Surgery Group, Orthopedics and Traumatology Service, HCPA, Porto Alegre, RS, Brazil

<sup>3</sup>Orthopedics and Traumatology Service, HCPA, Porto Alegre, RS, Brazil

**Address for correspondence** Celso Ricardo Folberg, Rua Sinke, 236, casa 45, Porto Alegre, RS, 90840-150, Brazil (e-mail: crfolberg@hotmail.com).

Rev Bras Ortop 2022;57(6):1070–1073.

### Abstract

Scaphoid fractures account for 50 to 70% of all carpal bone fractures. Percutaneous scaphoid osteosynthesis can use the dorsal or volar approach, both with good results, and is most commonly performed under general anesthesia or regional nerve block. The wide-awake local anesthesia no tourniquet (WALANT) technique is already considered a safe and cost-effective technique in hand surgery around the world. Local anesthesia with epinephrine causes vasoconstriction, which obviates the need for tourniquet and, consequently, the need to use patient sedation. Thus, the possibility of testing fixation stability under physiological forces is another great advantage of using local anesthesia. In the technique described in the present paper, active wrist and hand motion can be tested immediately after scaphoid fixation. Wide-awake local anesthesia no tourniquet has been increasingly used in soft-tissue hand surgery and in the fixation of metacarpal and phalangeal fractures. However, to date, there is no published literature addressing the use of this technique in percutaneous scaphoid osteosynthesis. The purpose of the present technical note is to describe the use of WALANT for both the dorsal and volar approaches in percutaneous scaphoid osteosynthesis.

### Keywords

- ▶ local anesthesia/ methods
- ▶ local anesthesia/ administration and dosage
- ▶ scaphoid bone
- ▶ wrist
- ▶ fractures, bone

\* Study developed at the Hand Surgery Group, Orthopedics and Traumatology Service, Hospital de Clínicas de Porto Alegre (HCPA), Porto Alegre, RS, Brazil.

received  
November 1, 2020  
accepted  
December 1, 2020  
published online  
April 25, 2022

DOI <https://doi.org/10.1055/s-0041-1726070>.  
ISSN 0102-3616.

© 2022. Sociedade Brasileira de Ortopedia e Traumatologia. All rights reserved.

This is an open access article published by Thieme under the terms of the Creative Commons Attribution-NonDerivative-NonCommercial-License, permitting copying and reproduction so long as the original work is given appropriate credit. Contents may not be used for commercial purposes, or adapted, remixed, transformed or built upon. (<https://creativecommons.org/licenses/by-nc-nd/4.0/>)

Thieme Revinter Publicações Ltda., Rua do Matoso 170, Rio de Janeiro, RJ, CEP 20270-135, Brazil

## Resumo

As fraturas do escafoide representam entre 50 e 70% de todas as fraturas dos ossos do carpo. A osteossíntese percutânea do escafoide pode usar a abordagem dorsal ou volar, ambas com bons resultados. É mais comumente realizada sob anestesia geral ou bloqueio nervoso regional. A técnica de anestesia local com o paciente totalmente acordado e sem torniquete (WALANT, na sigla em inglês) já é considerada uma técnica segura e eficaz na cirurgia da mão. A anestesia local com epinefrina causa vasoconstricção, o que evita o uso de torniquete e, conseqüentemente, a necessidade de sedação do paciente. Assim, a possibilidade de testar a estabilidade da fixação sob forças fisiológicas é outra grande vantagem do uso da anestesia local. Na técnica descrita aqui, o movimento ativo do punho e da mão pode ser testado imediatamente após a fixação escafoide. A técnica WALANT tem sido cada vez mais utilizada na cirurgia da mão em partes moles e na fixação de fraturas de metacarpo e falanges. No entanto, até o momento, não há literatura publicada abordando o uso dessa técnica na osteossíntese percutânea do escafoide. O objetivo desta nota técnica é descrever o uso de WALANT tanto para a abordagem dorsal quanto volar na osteossíntese percutânea do escafoide.

## Palavras-chave

- ▶ anestesia local/ métodos
- ▶ anestesia local/ administração e dosagem
- ▶ osso escafoide
- ▶ punho
- ▶ fraturas ósseas

## Introduction

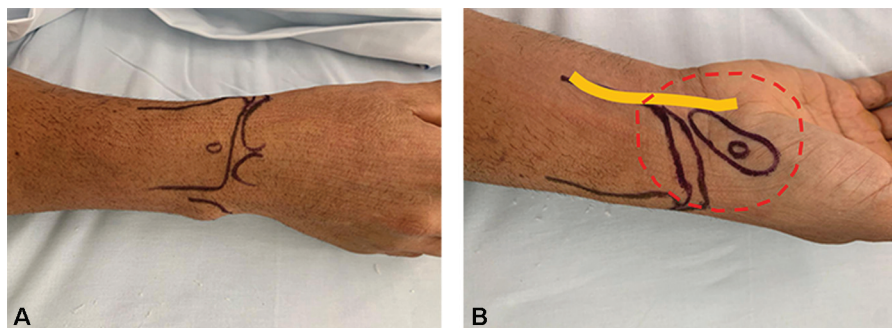
Scaphoid fractures are often observed by trauma physicians and hand surgeons. Surgical treatment is often performed in unstable, displaced, or proximal pole fractures. Percutaneous fixation of these fractures has been reported with excellent results.<sup>1</sup> It may also be indicated as a more comfortable alternative to plaster immobilization. Percutaneous fixation can be performed using the dorsal or volar approach, both with good results.<sup>2</sup>

Percutaneous scaphoid osteosynthesis is most commonly performed under general anesthesia or regional nerve block. The wide-awake local anesthesia no tourniquet (WALANT) technique has been proven to be safe and effective and is widely used worldwide. Advantages of this technique include shorter hospital stay, reduction in materials and hospital supplies and provides high level of patient satisfaction, as it does not require preoperative fasting or routine exams. In hand surgery, WALANT has been increasingly used in soft-

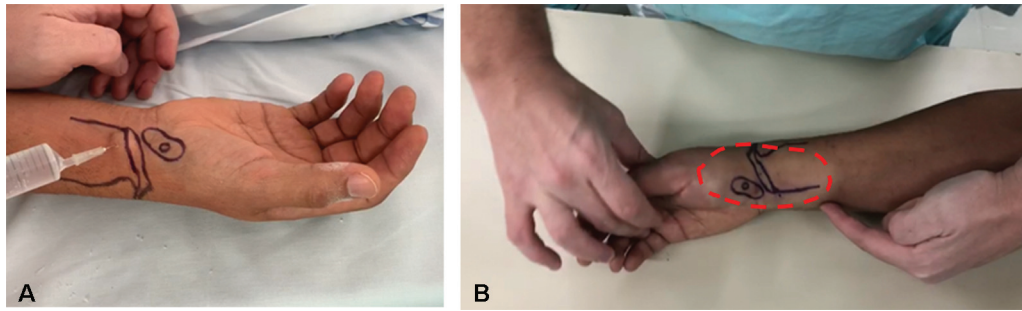
tissue surgery and in the fixation of metacarpal and phalangeal fractures. To date, there is no published literature addressing the use of WALANT in percutaneous scaphoid osteosynthesis. The purpose of the present technical note is to describe the use of WALANT for both the dorsal and volar approaches in percutaneous scaphoid osteosynthesis.

## Local Anesthetic Technique

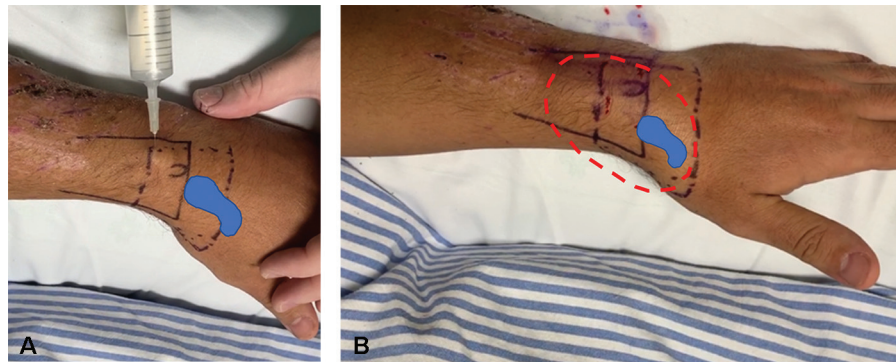
Local anesthesia is injected with the patient lying on a stretcher in the preoperative preparation room. The anesthetic solution is prepared by combining 40 mL of 1% lidocaine with 1:100 000 epinephrine, buffered with 4 mL of 8.4% sodium bicarbonate. The incision site and the scaphoid position are marked with a skin marker, and the anesthetic solution is injected within a radius of 2 cm from all its borders (→ **Figure 1A** and **B**). A median nerve block complements the local anesthetic procedure in both the volar and dorsal approaches.



**Fig. 1** A) Dorsal view of planning. B) Volar view of planning. The 2-cm perimeter around the scaphoid bone is marked in red with dotted lines. The median nerve is marked in yellow.



**Fig. 2** A) Proximal subcutaneous infiltration with a 30-gauge insulin needle. B) At the end of the subcutaneous anesthetic infiltration, distension and change in skin color can be observed (marked in red with dotted lines).



**Fig. 3** A) Dorsal infiltration slightly proximal to the Lister tubercle. B) Appearance after dorsal infiltration.

### Volar Approach

We start by injecting the anesthetic solution proximally with a 30-gauge insulin needle, to cause less pain, and then slowly into the subcutaneous layer with a 25-gauge needle, aiming to fill the entire demarcated area (► **Figure 2A**). The needle must be advanced into the previously infiltrated areas so that there is no discomfort to the patient. In the distal pole of the scaphoid, 1 to 2 mL are injected into the scaphotrapezoidal joint.

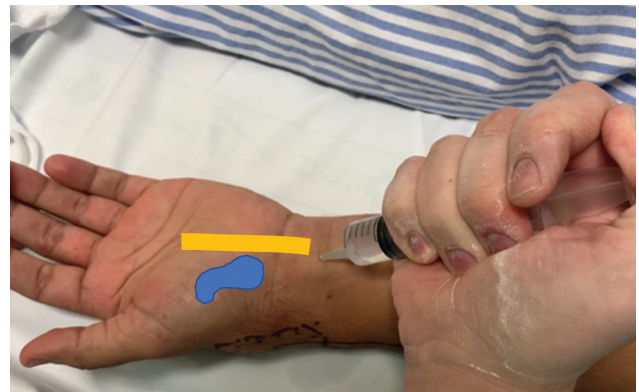A median nerve block is then performed by injecting 3 mL slightly proximal to the flexor crease of the wrist (► **Figure 3A**), in the space between the tendons of the palmaris longus and flexor carpi radialis. We end with anesthetic infiltration of the dorsal part. Starting proximal to the Lister tubercle, 5 mL of the anesthetic solution are injected into the subcutaneous tissue surrounding the proximal pole of the scaphoid, advancing the needle into the radioscaphoid joint to infiltrate an additional 2 mL. At the end of the anesthetic infiltration, it can be observed that the infiltrated area becomes whitish and distended (► **Figure 2B**).

### Dorsal Approach

Once we mark the skin the dorsal area surrounding the scaphoid bone and the incision site for percutaneous fixation slightly distal to the Lister tubercle, we start by subcutaneously injecting the anesthetic solution. With a 30-gauge insulin needle proximally (► **Figure 3A**) and then with a 25-gauge needle, we inject while observing the distension of the skin and subcutaneous tissues and advance the needle into the already distended and anesthetized area (► **Figure 3B**). In the proximal pole of the scaphoid, an additional 2 mL is injected

into the radioscaphoid joint. A median nerve block is then performed by injecting 3 mL slightly proximal to the volar crease of the wrist and in the space between the tendons of the palmaris longus and flexor carpi radialis (► **Figure 4**).

We wait 25 minutes to start the surgical procedure, as this is the optimal time interval to achieve maximal cutaneous vasoconstriction with the use of 1:100 000 epinephrine.<sup>3</sup> Before skin incision, pain sensation is tested by pinching the skin with a toothed Adson forceps. The operation only can be started if the patient has a pain score of 0 on a visual analog scale (VAS). Throughout the procedure, patients are encouraged to express whether they are feeling any pain or discomfort.



**Fig. 4** Proximal median nerve block performed in both the dorsal and volar approaches. Approximately 3 mL are injected.

After screw insertion and guidewire removal, wrist motion is actively tested, and the stability of osteosynthesis is also confirmed by fluoroscopy. At the end of the procedure, patients receive postoperative instructions and are discharged home with no need to stay in the hospital recovery room.

## Discussion

In scaphoid surgery, the use of tourniquet is required to obtain a surgical field with minimal bleeding, which in turn requires general anesthesia or nerve block with sedation. Local anesthesia with epinephrine causes vasoconstriction, which obviates the need for tourniquet and, consequently, the need to sedate patients. Wide-awake local anesthesia no tourniquet is already considered a safe, effective, and cost-saving technique in hand surgery.<sup>4</sup>

Lidocaine has been used for more than 80 years, and its combined use with epinephrine has been employed by dentists on a daily basis without monitoring, venous access, or preoperative testing with rare adverse reactions reported.<sup>5</sup> In our technique, we use 40 mL of lidocaine with epinephrine. Based on previous studies, the recommended standard maximum dose of lidocaine is 7 mg/kg.<sup>6</sup> Therefore, each patient will have a maximum safe dose depending on his/her weight. The safety of using epinephrine in hand surgery is well established.<sup>7</sup> However, some patients may experience transient tremor after the infiltration, and this should always be explained to the patient in advance.

The WALANT technique has been used effectively in hand surgery for a variety of conditions, particularly soft-tissue repair or reconstruction and phalangeal fractures.<sup>8</sup> The possibility of testing fixation stability with physiological forces is a great advantage of using local anesthesia. In the technique described here, active wrist and hand motion can be tested immediately after scaphoid fixation.

A recent report of osteosynthesis of a distal radius fracture under WALANT<sup>9</sup> showed a wider use of local anesthesia in wrist fractures. However, a search on the PubMed database yielded no published studies using local anesthesia in scaphoid osteosynthesis.

The WALANT technique described here for minimally invasive osteosynthesis of scaphoid fractures is cost-effective and offers many of the benefits reported by Lalonde<sup>8</sup>: 1) absence of nausea, vomiting, urinary retention, and other side effects of opioids or sedation; 2) patients do not need to endure tourniquet pain, not even for a short time—no

tourniquet use is also helpful in patients with lymphedema and arteriovenous shunts; 3) surgery under local anesthesia is much cheaper than under sedation, therefore more accessible to more people; 4) patients do not need extra time for preoperative testing; and 5) WALANT is safer than sedation, especially for patients with comorbidities.

## Final Considerations

In conclusion, WALANT, a technique already established for several procedures in hand surgery, is also feasible for minimally invasive osteosynthesis of scaphoid fractures, in both the volar and dorsal approaches. In addition, the technique is easy to use, inexpensive, and reproducible. Further studies will confirm its effectiveness and indications.

### Financial Support

There was no financial support from any public, commercial, or non-profit sources.

### Conflict of Interests

The authors declare that there is no conflict of interests.

## References

- 1 Folberg C, Ruschel P, Pignataro M, Perea C, Caputo G. Percutaneous fixation of mid-third wrist scaphoid bone fractures. *Rev Bras Ortop* 2004;39(07):363–370
- 2 Kang KB, Kim HJ, Park JH, Shin YS. Comparison of Dorsal and Volar Percutaneous Approaches in Acute Scaphoid Fractures: A Meta-Analysis. *PLoS One* 2016;11(09):e0162779
- 3 McKee DE, Lalonde DH, Thoma A, Glennie DL, Hayward JE. Optimal Time Delay between Epinephrine Injection and Incision to Minimize Bleeding: *Plastic and Reconstructive Surgery*. 2013; 131(04):811–814
- 4 Pires Neto P, Moreira L, De Las Casas P. É seguro o uso de anestésico local com adrenalina na cirurgia da mão? Técnica WALANT. *Rev Bras Ortop* 2017;52(04):383–389
- 5 Gaffen AS, Haas DA. Survey of local anesthetic use by Ontario dentists. *J Can Dent Assoc* 2009;75(09):649
- 6 Lalonde DH, Wong A. Dosage of local anesthesia in wide awake hand surgery. *J Hand Surg Am* 2013;38(10):2025–2028
- 7 Mann T, Hammert WC. Epinephrine and hand surgery. *J Hand Surg Am* 2012;37(06):1254–1256
- 8 Lalonde DH. Conceptual origins, current practice, and views of wide awake hand surgery. *J Hand Surg Eur Vol* 2017;42(09): 886–895
- 9 Ahmad AA, Yi LM, Ahmad AR. Plating of Distal Radius Fracture Using the Wide-Awake Anesthesia Technique. *J Hand Surg Am* 2018;43(11):1045.e1–1045.e5