


Intramuscular Hemangioma: A Rare Cause of Omalgia*

Hemangioma intramuscular: Uma causa rara de Omalgia*

Pedro M. Guedes¹  Nuno A. Saldanha¹ Pedro M. Matos¹ Francisco S. Carvalho¹ Graça Veiga¹ Pedro Norton¹

¹Physician, Department of Occupational Medicine São João, University Hospital Center, Occupational Health Service, Porto, Portugal

Address for correspondence Pedro M. Guedes, M.D., Sacadura Cabral Street 116 1° Esquerdo, 4050-529, Porto, Portugal (e-mail: pedro.moura.guedes@gmail.com).

Rev Bras Ortop 2023;58(4):e676–e680.

Abstract

Intramuscular hemangiomas (IHs) are benign soft-tissue tumors that represent less than 1% of all hemangiomas. This clinical entity is rarely considered as a differential diagnosis in cases of musculoskeletal pain. A healthy 38-year-old woman presented to our office with complaint of left omalgia, with 8 months of evolution, limiting her daily activities. She reported the appearance of tumefaction in the previous 4 months. She was medicated with analgesic and antiinflammatory drugs with no clinical improvement. The objective examination showed limitation of left shoulder abduction (0–90°). The patient underwent a magnetic resonance imaging (MRI), in which a well-circumscribed nodular formation was detected in the deltoid muscle. Then, she underwent a biopsy, which confirmed the diagnosis of hemangioma. The patient was referred for sclerotherapy. Intramuscular hemangiomas are usually observed in young patients. The gold-standard examination for diagnosis is MRI, which often forestalls the need for a biopsy. In many cases, IHs are asymptomatic and tend to involute over time. Despite the low frequency of this clinical entity, it is important to place it as a diagnostic hypothesis in cases of chronic pain of the limbs in young patients with poor therapeutic response to antiinflammatory drugs and analgesia.

Keywords

- ▶ intramuscular hemangioma
- ▶ muscles
- ▶ muscular diseases
- ▶ occupational health
- ▶ omalgia

Resumo

Os hemangiomas intramusculares (HIs) são tumores benignos de tecidos moles que representam menos de 1% de todos os hemangiomas. Esta entidade clínica raramente é considerada como diagnóstico diferencial nos casos de dor musculoesquelética.

* Work developed at the São João University Hospital Center, Occupational Health Service, Porto, Portugal.

received
June 6, 2020
accepted
September 17, 2020

DOI <https://doi.org/10.1055/s-0040-1722588>.
ISSN 0102-3616.

© 2021. Sociedade Brasileira de Ortopedia e Traumatologia. All rights reserved.

This is an open access article published by Thieme under the terms of the Creative Commons Attribution-NonDerivative-NonCommercial-License, permitting copying and reproduction so long as the original work is given appropriate credit. Contents may not be used for commercial purposes, or adapted, remixed, transformed or built upon. (<https://creativecommons.org/licenses/by-nc-nd/4.0/>)

Thieme Revinter Publicações Ltda., Rua do Matoso 170, Rio de Janeiro, RJ, CEP 20270-135, Brazil

Uma paciente do sexo feminino, de 38 anos de idade, saudável, se apresentou ao nosso consultório com queixa de omalgia esquerda, com 8 meses de evolução, que limitava suas atividades diárias. Ela relatou o aparecimento de tumefação 4 meses antes da consulta. A paciente estava medicada com analgésico e antiinflamatório sem melhoria clínica. Ao exame objetivo, ela apresentava limitação da abdução do ombro esquerdo (0–90°). A paciente foi submetida a uma ressonância nuclear magnética (RNM) na qual foi detectada uma formação nodular bem circunscrita no músculo deltoide,. Em seguida, foi realizada uma biópsia que confirmou o diagnóstico de hemangioma. A paciente foi então encaminhada para a realização de escleroterapia. Os HIs normalmente são observados em pacientes jovens. O exame padrão-ouro para o diagnóstico é a RNM, que muitas vezes torna a realização de biópsia desnecessária. Em muitos casos, os HIs são assintomáticos e tendem a involuir com o tempo. Apesar da baixa frequência desta entidade clínica, é importante colocá-la como hipótese de diagnóstico em casos de dor crônica dos membros em pacientes jovens com má resposta terapêutica a antiinflamatórios e analgesia.

Palavras-chave

- ▶ hemangioma intramuscular
- ▶ músculos
- ▶ doenças musculares
- ▶ saúde ocupacional
- ▶ omalgia

Introduction

Hemangiomas are a variant of benign soft-tissue tumors that are characterized by abnormal proliferations of vascular tissues; intramuscular hemangiomas (IHs) are rare (< 1% of all hemangiomas) and are mostly congenital, usually found at younger ages (90% before 30 years of age), and, in many cases, they tend to involute spontaneously over time.^{1–3} Intramuscular hemangiomas are rarely considered as a differential diagnosis of musculoskeletal pain. They are usually associated with chronic pain with the appearance of an associated tumefaction, tend to aggravate the symptomatology with efforts and may, in some cases, limit daily activities.^{4–6}

Case description

A 38-year-old woman who worked as an administrative employee in a tertiary hospital, with no relevant personal history, presented to our office with a complaint of pain in the anterior side of the left shoulder, with 8 months of evolution, which was limiting her daily activities, namely at the work and sports levels. She also reported the appearance of symptoms in the 4 months prior to the consultation. She was medicated with analgesic and antiinflammatory drugs with no clinical improvement. The patient associated the symptoms with poor postures as well as repetitive movements with the upper limb performed in her professional activity. The objective examination showed limitation of the left upper limb (LUL) movements, namely shoulder abduction (0–90°), with pain on local palpation. She performed a magnetic resonance imaging (MRI) in which a relatively well circumscribed, heterogeneous nodular formation was detected in the deltoide muscle, , measuring 16 × 16 mm in the axial plane and 45 mm of larger axis in the coronal plane (▶ Figs. 1

and 2). After discussing the case with the radiology service due to the absence of specific characteristics in complementary imaging exams (combination of vascular lesions with non-vascular elements, such as adipose tissue), we opted to perform histological characterization through biopsy. It demonstrated fibro-adipose, musculoskeletal tissues and vascular neoplasia fragment, thus confirming the diagnosis of hemangioma. The patient was referred to an intervention radiology consultation, where sclerotherapy was proposed (▶ Fig. 3). One month after performing

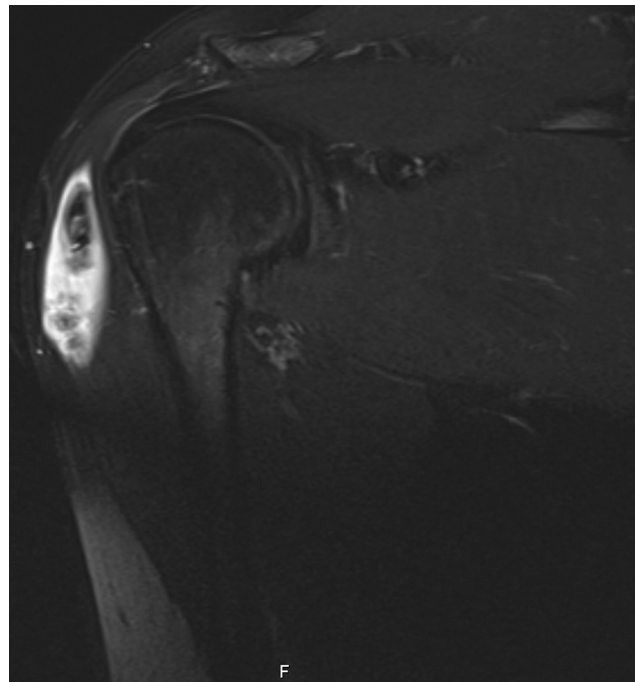


Fig. 1 Magnetic resonance imaging of intramuscular hemangioma of the deltoid.

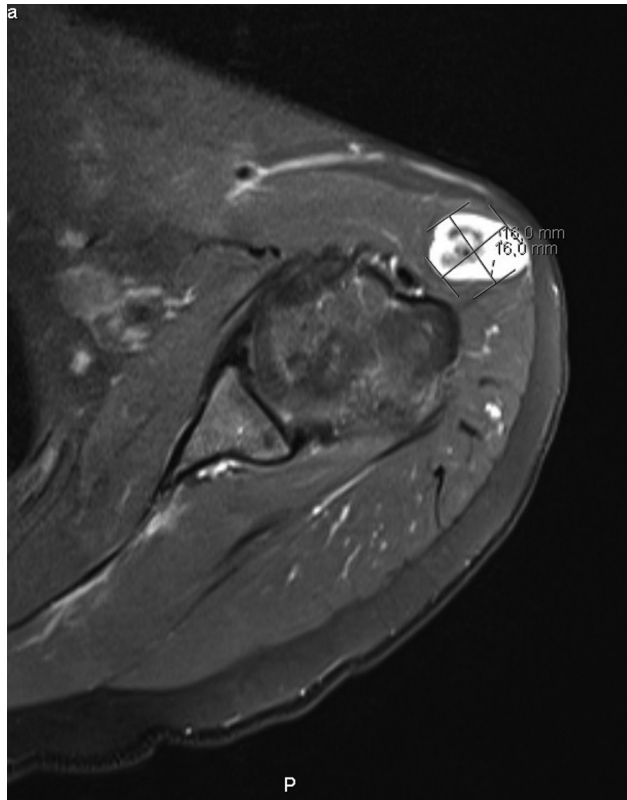


Fig. 2 Magnetic resonance imaging of intramuscular hemangioma of the deltoid.

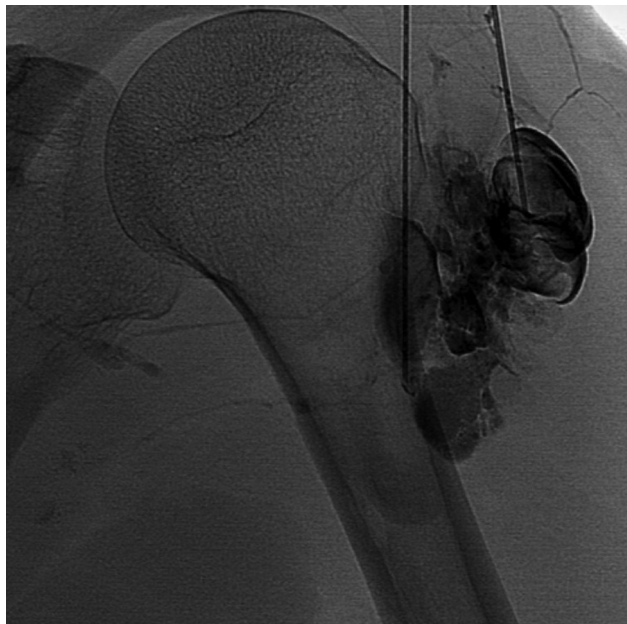

Fig. 3 Sclerotherapy technique for the treatment of intramuscular hemangioma.

sclerotherapy, the patient reported an improvement in symptomatology, namely, of the joint amplitudes of the left shoulder (0–150°) and decreased limitations in daily activities.

Discussion

Intramuscular hemangiomas are usually observed at young ages (before 30 years) and are almost always associated with palpable tumefaction. Despite being a rare entity, it is something to take into account as a differential diagnosis in cases of musculoskeletal pain, especially in the upper and lower limbs, and at young ages.^{4–6} The gold-standard examination for diagnosis is MRI, but ultrasound is something that can be useful in an initial diagnosis. Aspiration biopsy by thick needle should be performed in cases in which the diagnosis cannot be confirmed by imaging.⁷ Pain, as well as limitation of day-to-day activities, is one of the main factors influencing the mode of treatment. The use of antiinflammatory drugs and analgesics as well as physiotherapy are modes of treatment commonly used in mild cases.⁸ It should be considered that excessive efforts with the limb may aggravate the symptomatology due to vasodilation. The treatment options for IHs can range from conservative treatment, given the possibility of spontaneous regression over time, to surgical treatment, in cases of persistent and very disabling pain, aesthetic deformities, neurovascular compression, effects of local compression causing skin necrosis, or suspected malignancy. Sclerotherapy is an alternative form of treatment, when there is poor response to conservative treatment and absence of surgical criteria. This intravascular procedure through the use of sclerosing agents that cause vascular thrombosis and endothelial damage, leading to endofibrosis and vascular obliteration, allow in many cases a complete regression of these tumors.^{1,3,9,10} Another form of treatment consists in combining surgery with embolization 2 to 3 days before the surgical procedure, which is used in more complex, infiltrative and recurrent lesions.⁵

Despite the low frequency of this clinical entity, it is important to place it as a diagnostic hypothesis in cases of chronic pain and limitation of limbs movements of in young patients with poor therapeutic response to antiinflammatory drugs and analgesia.

Financial Support

The authors declare that they have received no financial support for the research, authorship and/or publication of the present article.

Conflict of Interests

The authors declare that there is no conflict of interests.

References

- 1 Cohen AJ, Youkey JR, Clagett GP, Huggins M, Nadalo L, d'Avis JC. Intramuscular hemangioma. *JAMA* 1983;249(19):2680–2682
- 2 Ramon F. Tumors and Tumorlike Lesions of Blood Vessels. In: De Schepper AM, Parizel PM, De Beuckeleer L, Vanhoenacker F, eds. *Imaging of Soft Tissue Tumors* [Internet]. Berlin, Heidelberg: Springer Berlin Heidelberg; 2001 [citado 10 de Janeiro de 2020]. p. 225–44. Disponível em: http://link.springer.com/10.1007/978-3-662-07856-3_13

- 3 Wierzbicki JM, Henderson JH, Scarborough MT, Bush CH, Reith JD, Clugston JR. Intramuscular hemangiomas. *Sports Health* 2013;5(05):448–454
- 4 Wild AT, Raab P, Krauspe R. Hemangioma of skeletal muscle. *Arch Orthop Trauma Surg* 2000;120(3-4):139–143
- 5 Fergusson IL. Haemangiomas of skeletal muscle. *Br J Surg* 1972;59(08):634–637
- 6 Kryzak TJ Jr, DeGroot H 3rd. Adult onset flatfoot associated with an intramuscular hemangioma of the posterior tibialis muscle. *Orthopedics* 2008;31(03):280
- 7 Mitsionis GI, Pakos EE, Kosta P, Batistatou A, Beris A. Intramuscular hemangioma of the foot: A case report and review of the literature. *Foot Ankle Surg* 2010;16(02):e27–e29
- 8 Scott JES. Haemangiomas in skeletal muscle. *Br J Surg* 1957;44(187):496–501
- 9 Brown RA, Crichton K, Malouf GM. Intramuscular haemangioma of the thigh in a basketball player. *Br J Sports Med* 2004;38(03):346–348
- 10 Liu Y, Li R, Liu Z, Wang S, Lu L. Intramuscular hemangioma within the biceps brachii causing the limitations of elbow extension and forearm pronation: A case report. *Medicine (Baltimore)* 2019;98(05):e14343

