

TRANSANAL ENDOSCOPIC MICROSURGERY AND ADJUVANT THERAPY IN THE TREATMENT OF EARLY RECTAL CANCER

Microcirurgia endoscópica transanal e tratamento adjuvante no câncer retal precoce

Roberto da Silveira **MORAES**, Grazielle Moraes **LOSSO**, Jorge Eduardo Fouto **MATIAS**,
Liselote **MAILAENDER**, Jose Ederaldo Queiroz **TELLES**, Osvaldo **MALAFAIA**, Julio Cesar Uilli **COELHO**

From Department of Digestive Surgery, Hospital de Clínicas, Federal University of Paraná, Curitiba, PR, Brasil.

ABSTRACT - Background - The total mesorectal excision is considered the standard operation in the treatment of rectal tumors, although there is no scientific proof that it should be used for all stages of the disease. It has been demonstrated that in selected cases of rectal tumors, promising results can be achieved with local treatment by transanal endoscopic microsurgery. These tumors, called early rectal cancer, T1 tumors, are less than 4 cm, well differentiated without angiolymphatic invasion - pT1 SML. As the risk of lymph node involvement in these tumors is approximately 3%, local resection would have a great chance to be curative. **Aim** - To present the results of a non-random prospective series of patients with early rectal cancer treated by transanal endoscopic microsurgery. **Methods** - Between 2002 and 2010, 38 patients evaluated by preoperative protocol as patients with early rectal cancer underwent endoscopic microsurgical resection of the entire rectal wall including the tumor when located between 2 and 8 cm from the dentate line. The preoperative evaluation consisted of digital rectal examination, rigid sigmoidoscopy macrobiopsies, barium enema and/or colonoscopy, endorectal ultrasound and abdominal computed tomography of the abdomen, chest radiography and serum CEA. Was conducted follow-up with endoscopy and endorectal ultrasound every three months during the first two years, and every six in the next three years, and CEA every six months during the same period of five years. Was evaluated the tumor recurrence, morbidity and mortality. **Results** - Pathologic evaluation considered 29 categorized as low risk and nine being high. The follow-up in the series ranged from one to seven years. Tumor recurrence was confirmed in two of the 38 cases (5.26%), in one the lesion was considered high and another low risk. **Conclusion** - Transanal endoscopic microsurgery associated or not to adjuvant therapy, may be, currently, considered the gold standard in local rectal resection, with encouraging results in cases chosen with early rectal tumors at low risk.

HEADINGS - Early rectal cancer. Local excision. Transanal endoscopic microsurgery. Adjuvant treatment.

Correspondence:

Roberto da Silveira Moraes,
e-mail: rds Moraes@ig.com.br

Source of funding: none
Conflict of interest: none

Received: 21/11/2010
Accepted for publication: 25/01/2011

RESUMO - Racional - A excisão total do mesorreto é considerada a operação padrão no tratamento dos tumores do reto, apesar de não existir comprovação científica de que ela deva ser usada para todos os estádios da doença. Tem sido demonstrado que em casos escolhidos de tumores retais, resultados promissores podem ser conseguidos com tratamento local por microcirurgia endoscópica transanal. Tais tumores, denominados de câncer retal precoce, são tumores T1 - menores do que 4 cm -, bem diferenciados sem invasão angiolinfática pT1 Sm1. Como o risco de comprometimento linfonodal nesses tumores é de aproximadamente 3%, a ressecção local teria grande chance de ser curativa. **Objetivo** - Apresentar os resultados de uma série prospectiva não randômica de pacientes portadores de câncer retal precoce submetidos ao tratamento local por microcirurgia endoscópica transanal. **Métodos** - Entre 2002 e 2010, 38 pacientes avaliados por protocolo pré-operatório como portadores câncer retal precoce foram submetidos à ressecção local endoscópica microcirúrgica de toda a parede retal com o tumor quando localizado entre 2 e 8 cm da linha pectínea. A avaliação pré-operatória consistiu de toque retal, retossigmoidoscopia rígida para macrobiópsias, enema opaco e/ou colonoscopia, ultrassonografia endorectal e abdominal, tomografia axial computadorizada do abdome, radiografia do tórax e dosagem sérica do CEA. Realizou-se seguimento pós-operatório endoscópico e ultrassonográfico endorectal a cada três meses nos dois primeiros anos, e a cada seis nos próximos três anos, além de dosagem do CEA a cada seis meses nesse mesmo período de cinco anos. Avaliou-se a recidiva tumoral, morbidade e mortalidade. **Resultados** - Após avaliação anatomopatológica da lesão, 29 cânceres retais precoces foram categorizados como de baixo risco e nove sendo de alto. O seguimento na série variou de um a sete anos. Recidiva tumoral foi confirmada em dois casos dos 38 (5,26%), uma lesão considerada de alto e a outra de baixo risco. **Conclusão** - Microcirurgia endoscópica transanal, associada ou não à quimiorradioterapia, pode ser considerada atualmente o padrão-ouro na ressecção retal local, apresentando resultados animadores em casos escolhidos de tumores retais precoces de baixo risco.

DESCRITORES - Câncer retal precoce. Excisão local. Microcirurgia endoscópica transanal. Tratamento adjuvante.

INTRODUCTION

Early rectal cancer is defined as invasive adenocarcinoma that extends to the submucosa but not beyond; the tumor is pT1 in the TNM classification^{5,6,14,15,16}. These tumors have less chance of lymph node involvement than those adenocarcinomas that invade lower portions because of the paucity of lymphatics in colorectal submucosa².

Neoplastic cells confined to the colorectal mucosa are properly referred to as dysplasia or adenoma in the UK. In American literature and Japanese inappropriate names of intramucosal carcinoma and carcinoma in situ are used⁵. A local excision for low risk carcinoma of the rectum has been recently increasing in popularity^{2,3,18,29}. However, require careful selection of patients when used as curative treatment.

To indicate the local treatment of rectal carcinoma, without performing lymphadenectomy, must be evaluated the risk of lymph node metastases and also the mortality of radical resection, especially in the elderly. Other key features include detailed histological evaluation, rigorous monitoring and warning the patient of the possible need for additional curative radical resection at any time. The treatment of early rectal cancer aims to offer cure and at the same time, minimize morbidity and mortality.

The anterior resection and abdominoperineal rectum amputation have mortality rate around 7% in the first 30 days and a morbidity rate of 35%, but with poor functional results¹. However, these procedures give patients the best chance of cure. The adjuvant radiochemotherapy may play an important role when using less invasive methods. The staging of early rectal cancer treatment represents a risk, if not properly performed histological evaluation - most important factor in the risk of lymphatic dissemination.

These aspects served as a stimulus for the development of new surgical method, combining good visualization afforded by endoscopy, with the technological advancement of surgical instruments for minimally invasive resection. This method was called Transanal Endoscopic Microsurgery (TEM) to differentiate it from the endoscopic procedure and conventional surgery. Began to be practiced since 1982 in Germany and, currently, is used in major centers. Its introduction in Brazil was due to the first author of this paper in 2002 at the Department of Digestive Surgery, Hospital de Clínicas, Federal University of Paraná in Curitiba, Brazil^{20,21,22,23,24,25}.

This paper presents the results of a non-random prospective series of patients with early rectal cancer

treated by transanal endoscopic microsurgery.

METHODS

Between April 2002 and October 2010 were operated by the same team 38 patients with early rectal carcinoma, aged 25 and 92 years, compiled in non-randomized prospective study, approved by the Ethics Committee of Hospital de Clínicas, Federal University of Paraná and logged in BANPESQ - UFPR (Stock Research UFPR) under the number 2002012334. The clinical history data were recorded on standard protocol with complaint, current morbid history, previous personal or familial diseases and references possibly related to the disease. Were also surveyed and recorded detailed data from the lesion, the additional tests and observations of interest to the pre, as well as, trans and postoperative period. Were eligible to perform the TEM patients with rectal tumors diagnosed by conventional methods currently classified as low-risk pT1. Those patients whose tumors postoperatively showed high risk, and did not accept the radical operation, were treated by adjuvant chemoradiation protocol. Patients accepted the term of consent to procedure they would be exposed, their advantages, disadvantages, benefits, risks and possibility of undergoing radical rescue operation.

Preoperatively, all patients underwent digital rectal examination to consider if the tumor was touchable, to check extension, mobility and location in the rectal circumference using rigid sigmoidoscopy to perform macrobiopsies and, basically, to determine the tumor distance from dentate line, anal verge and its location on the wall of the rectum - if anterior, posterior, left side or right side. Also, patients underwent colonoscopy and/or barium enema to check for injuries and associated diseases, endorectal ultrasound, abdominal ultrasound, abdominal computerized tomography scans, CEA and chest radiography. The proof of the lack of involvement beyond the submucosa indicated the TEM. In addition, preoperative histology included: 1) defining the nature of the neoplastic lesion according to the criteria of WHO and UICC-TNM and 2) morphologic criteria for estimating the risk of angiolymphatic metastasis associated with depth of invasion of primary tumor (uT), the degree of histologic cell differentiation according to WHO, the presence or absence of carcinomatous lymphangiosis (based on the finding of tumor cells within cavities lined by endothelium without muscular elements in the wall). The staging uTNM was made preoperatively based on the sonographic criteria of Hildebrandt: a) uTo - lesion

restricted to the mucosa; b) uT1 - restricted to the submucosa; c) uT2 - restricted to the muscle itself; d) uT3 - restricted to perirectal fat; e) uT4 - invading adjacent organs; f) No - without lymph node invasion; g) N1 - with lymph node invasion²³.

The operative procedure (TEM)

It was conducted through the equipment designed and named Buess retoscope (Richard Wolf Co., Knittlingen, Germany) published in prior paper²³. After appropriate view of the tumor, was fixed in retoscope appropriate support (Martin). The glass diaphragm - which was used to access the display - was replaced by work portal consisting of: a) high frequency electrocautery -which automatically controls the voltage arc and the electric intensity -, to provide instant cut electronic control (Erboton CCI 350M ; Elektromedizin Erbe, Germany); b) rigid telescope binocular with stereoscopic vision; c) an optical device for documentation and to additional view of the surgical procedure. This last optical image was two-dimensional - like that of laparoscopy -, different from the surgeon's one, who was 3-D²³.

The limits of resection were set 2 cm above the dentate line as the lower limit it to 8 cm as the upper limit, ie, extraperitoneal rectum. Total resection of the wall was performed in all tumors with a preoperative diagnosis of carcinoma located in the extraperitoneal rectum (Figure 1).

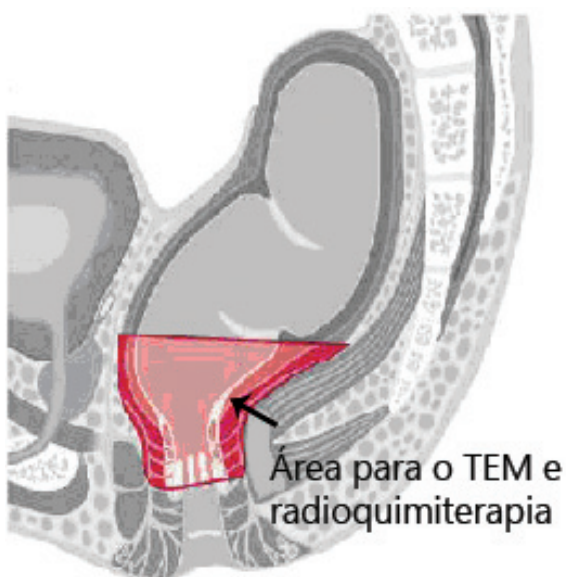


FIGURE 1 – Diagram representing the limits of TEM resection of rectal tumors underwent to radiochemotherapy

Preparation of specimens and pathology

The excised tissue was immediately photographed, smeared on a smooth surface and fixed in formalin solution 10%. After 48 h fixation, it was re-

photographed, painted with Indian ink with two colors to allow identification on histological examination, the resection margins or radial and perimeter limits; additionally was made schematic drawing detailing the samples record; they were numbered and, then, the specimen was fully included (Figures 2 and 3).

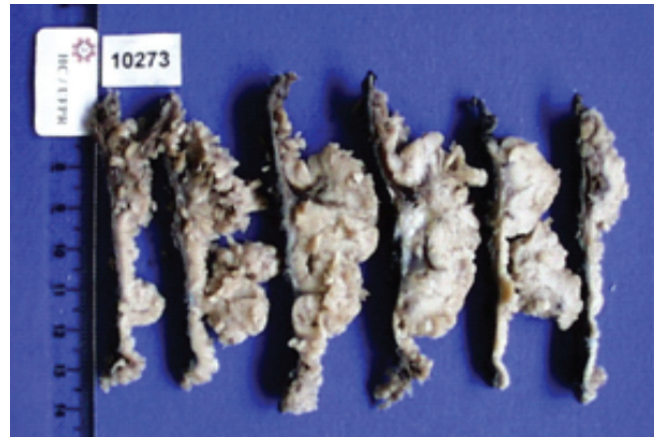


FIGURE 2 – Macroscopic tumor fully included

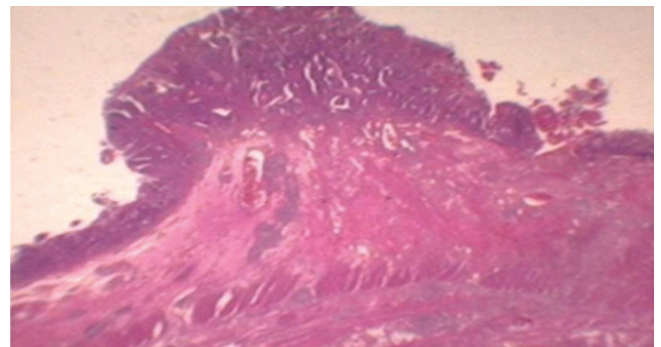


FIGURE 3 – Histological aspect (H & E) of the tumor invading the submucosa (pT1)

To ensure relevant information to the pathologist, it was used a standard form that systematically mentioned the location, macroscopic type (flat, pedunculated or ulcerated), the number of excised lesions and surgeon's uTNM impression. Sections were stained with hematoxylin-eosin (H&E). To estimate the risk of lymphatic metastasis was used the term low risk for adenocarcinomas on grades G1 and G2 without carcinomatous lymphangiosis. The G3 and G4 tumors and those with evidence of carcinomatous lymphangiosis were classified as high risk (H&E). In cases where there were various degrees of differentiation, the less differentiated grade was used. To better visualize miniature blocks and to confirm the phenomenon of lymphatic vascular invasion, immunohistochemical study was performed with CD34 and cytokeratins (Figure 4). The pathology description of TEM specimen contained: a) number of

layers involved; b) nature of lesion; c) depth of invasion; d) histological type and grading; e) assessment of vascular invasion; f) evaluation of the radial margin and perimeter. These criteria were based on Hermaneck proposition²³. Record of any "residual tumor" category was done in cases that showed recurrences and were documented to protocol of reoperation, as follows: R0 = absent residual; R1 = microscopic residual; R2 = macroscopic residual. The R classification refers to the primary tumor, regional lymph nodes and distant metastasis. The final stage in the postoperative period between high and low risk was based on the classification of Haggitti¹⁰ and Kikuchi¹² that divides the submucosa into three thirds; in the superior third the spread has described separately. The classification of Kikuchi was used for sessile tumors and Haggitti's for pedunculated ones.

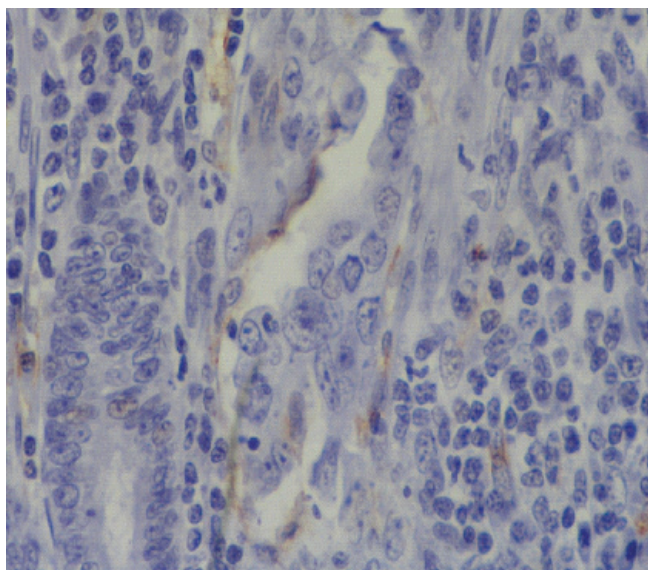


FIGURE 4 – CD34 immunohistochemistry showing tumor in capillar featuring high-risk early rectal cancer after TEM

Radiochemotherapy

In all patients diagnosed with carcinoma at high risk after TEM, was recommended radical surgery or chemoradiation (5-fluorouracil and leucovorin). Exceptionally, was employed cetuximab or folfox 6.

Adjuvant radiotherapy was indicated in those tumors in which the final histological diagnosis after TEM showed that they were at high risk (those with Sm2/Sm3 or angiolymphatic invasion) and/or those who refused to total mesorectal excision. The proposed scheme was: Rt 45-50 Gy associated with chemotherapy 5-FU 420mg/m² + LV 20 mg/m² D1-D5 and six additional cycles of 28/28 days. When conformal 3-D technique was used, the patient was

referred to the total dose of 50.4 Gy in 28 fractions of 1.8 Gy (45y pelvis +5.4 Gy boost)

Postoperative care and follow-up

Flexible proctoscopy was done on the 5th and 21th days after surgery to check the patency of the anastomosis. The follow-up endoscopy and endorectal ultrasound after surgery were made every three months in the first two years and every six months for three years. Consisted of endoscopy with multiple biopsies in the anastomotic area. After the period of risk of relapse, was adopted the screening done for the general population, ie, every five years. The control of CEA was done every six months thereafter for five years.

RESULTS

Were operated by TEM 38 patients with rectal adenocarcinomas classified pT1, being 29 low and nine high risk. The highest incidence of tumors was observed between 60 and 79 years (28 patients). Those considered high-risk pT1, minimum age ranged from 25 to 57 years. The limits of resection for these tumors were 2 cm above the dentate line and up to 8 cm above it - extraperitoneal rectum. In 37 patients was done the resection of the wall. Modified mucosectomy was performed with partial resection of internal sphincter associated with resection of the wall and adjuvant chemoradiation done in one patient. The TEM was considered satisfactory oncologically in 29 patients. All patients with tumors considered high risk and one with low risk were submitted to adjuvant chemoradiation.

Follow-up

Follow-up ranged from 12 months to seven years in this series. Of these 38 patients, 40% have follow-up over five years.

Recurrence

The overall recurrence rate was 5% (2/38), one high and one low risk (Table 1 and Figure 5) respectively 12 and 24 months after TEM. One of these patients died five years and six months after the rescue operation with liver and lung metastasis. In the other, no signs of active disease existed in six years after the rescue operation. A patient of 38 years, with lesions classified as pT1Sm3, refused further treatment and is free of disease seven years by now.

Morbidity

Complications in 38 patients were: one rectovaginal fistula in re-resection procedure after prior endoscopic resection and three post-operative

37 years	TEM- T1sm3 7 years without recurrence Refusal of complementary treatment
38 years	TEM - T1sm3 (Rt + Qt) 7 years without recurrence
53* years	TEM - T1 invasion angiolymphatic 18 months: relapse - Rt + Qt + rescue surgery/ Qt 5 years. 6 months: no recurrence
48*years	TEM - T1 (single focus) 24 months: relapse - Rt + Qt Qt rescue surgery Mol Kras - 48 months: lung metastasis - Qt 5 years (Death with metastatic disease)
42 years	TEM-T1sm3 (Rt + Qt) 4 years: no recurrence
57 years	TEM - T1sm3 (Rt + Qt) 30 months: no recurrence
51 years	TEM-T1sm3 (Rt + Qt) 27 months: no recurrence
25 years	TEM- T1Sm3 + angiolymphatic invasion (Rt + Qt) 12 months: no recurrence

TABLE 1 – Tumor recurrence and follow-up disease free in high-risk pT1 lesions (8/38) in patients with adjuvant chemoradiation and TEM

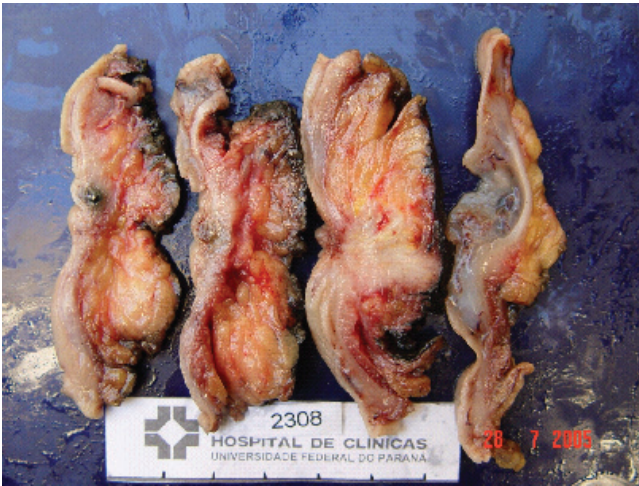

FIGURE 5 – Macroscopic view of the cuts showing recurrence after TEM

bleeding - all in tumors located in the lateral wall of the rectum being two within 24 hours and another on the seventh day. None of them required reoperation and spontaneously ceased, being subject only to volume replacement. Two patients had perineal actinic radiation dermatitis and one partial dehiscence of the anorectal anastomosis

Mortality

Mortality was zero in this patient group

DISCUSSION

"There is a current trend, unfortunately a setback of some surgeons to use less radical surgery in the treatment of rectal cancer with the aim of abolishing the colostomy. But in my experience at the Royal Cancer Hospital, there is conservatism in the treatment

of malignant disease." This text is part of the preface to the second edition of "Rectal Surgery", written by none other than Sir William Ernest Miles, eminence in world colorectal surgery. But this is not an absolute truth in our day. It is true that at that time Sir Miles did not have the scientific advances in nowadays diagnosis and treatment. The literature considers that the standard operation for the treatment of tumors of the rectum is the TME (total mesorectal excision), proposed by Heald for over 20 years. However, there is no scientific literature showing that it should be used at all stages of the disease¹¹. Kath Because of the morbidity associated with this surgical procedure, now more conservative methods such as local resection associated with neoadjuvant or adjuvant treatment in selected cases of rectal tumors^{8,14,16,30} are being used. Among the methods to local resection, the procedure is the standard TEM proposed by Buess in 1982 and introduced by Moraes in Brazil in 2002. Recent series from prospective studies suggest that the TEM associated with adjuvant treatment is a reasonable alternative to radical surgery in selected patients. The local resection alone is only acceptable treatment for tumors without adverse histopathological aspects, while the local resection with adjuvant therapy is an alternative for high-risk pT1 tumors¹⁶. Functional results of local treatment are generally good, morbidity and mortality after the surgery are acceptable. Complications were low. A rectovaginal fistula was observed in a re-resection of pT1 carcinoma due to excessive cauterization of the bloody bed. Conservative treatment was done, with subsequent closure of the fistula²⁴.

There were three post-operative bleeding which stopped spontaneously without reintervention, treated with fluid replacement. All of them were located in the lateral wall of the rectum. According to Kreissler-Haag et al.¹³ they are more frequent at this location and this is due to vascular anatomy of the rectum. Complications are not related to the number of procedures performed.

In this series the mortality was zero and morbidity of 9%, rates similar to that obtained in operations for colorectal adenomas and high-grade intraepithelial neoplasia²³. Besides being less invasive and less morbidity, the advantages of TEM are present in other important aspects. Recently they have analyzed data related to cost effectiveness and cost benefit in a series of patients undergoing TEM. Such parameters compared to conventional techniques of rectal resection (anterior resection or abdominoperineal amputation) also showed significantly favorable tendency²⁴.

In another study, stimulating patients underwent TEM to relate positive and negative aspects of the procedure the main positive aspects

were no postoperative scarring and no permanent colostomy. The negative were related to pain, fear of the possibility of radical surgery and discomfort in the various examinations and preoperative bowel preparation. All reported that they were fully informed about the nature of the procedure and indicate a friend or family member, even those who had complications such as rectovaginal fistula, temporary bypass and relapse²⁵.

The concepts of radiation have been changed in recent years with the expansion of the total dose to 45-50 Gy and combination with chemotherapy, which would add the benefit of a synergistic action in order to control any residual tumor after surgery. Thus, based on comprehensive prospective studies such as those published by the Gastrointestinal Tumors Study Group (GITSG)⁶ and the Mayo Clinic/North Central Cancer Treatment Group (MC / NCCTG)²⁶, was established by a consensus conference sponsored by the National Cancer Institute²⁷ in 1990 that radiation and chemotherapy is the standard adjuvant treatment for rectal cancer. This approach has directly contributed to significant reduction in local recurrence rates, although the impact on survival was still modest in most studies.

Therefore, the functional and oncologic results of local excision and chemoradiation treatment are encouraging.

Randomized clinical trials are needed to determine, in the meantime, if this treatment has control of local recurrence and survival rates comparable to those obtained with radical surgery in the long term. Data from the Memorial Sloan-Kettering Cancer Center suggest that the overall risk of lymph node metastasis in selected patients using the criteria of low risk (pT1) is 10%³⁰. Researchers at the Cancer Center at the University of Minnesota, reviewed their experience with 82 patients with rectal cancer classified as T1 or T2, treated only by conventional transanal local excision, for a period of 10 years. They concluded that the overall estimate of survival rate was 69% after local excision compared with 82% after radical surgery ($p = 0.06$). In similar group of patients treated with local excision plus radiation adjuvant therapy, the free rate of recurrence and survival were respectively 90% and 74%. When high-risk patients were selected for local resection and postoperative radiotherapy, local control rate of recurrence free at five years was 85%. The authors noted that improvement in outcome was evident despite the presence of a population of high risk patients in the group undergoing radiotherapy. They concluded that this modality of treatment combining radiotherapy is indicated for all patients for T2 and T1 high risk who underwent local Minnesota resection¹⁹.

Moreover when was examine the low-risk pT1 tumors alone, ie less than 4 cm well differentiated without angiolymphatic and mainly located in the upper third of the submucosa, the probability of lymph node involvement was around 3% and the relapse average of 7%, which authorizes the performance of minimally invasive procedures². Contributions in recent literature has shown that in selected cases the TEM provides oncological results similar to conventional radical surgery^{2,3,14,18,29}. The choice of surgical treatment is based on clinical, endoscopic, radiological and histological parameters in fundamentally. Two small series from the UK indicate that 49% to 62% of tumors diagnosed at screening are early (pT1-2N0M0; stage I). Treatment by local resection alone requires careful evaluation of the chance of subsequent local recurrence and lymph node involvement unresected. If the tumor treated by local resection is associated with high risk of lymph node involvement and local recurrence, the subsequent holding of classical and rescue operation within 30 days, will not compromise the oncological outcome compared to those of classic primary operation².

Of the 38 patients in this series 29 were considered low risk by TEM after histopathological criteria, and treatment alone was considered satisfactory with 40% of cases following relapse-free in five years. For the remaining¹, considered high-risk patients underwent adjuvant chemoradiation. Of these, three had distinct biologic tumor behavior. The first, a patient with pT1Sm3 without further treatment, there was no evidence of disease seven years by now; the second, classified as pT1 high risk with suspected angiolymphatic coloration H&E not confirmed in the cut for immunohistochemistry, relapsed after 12 months, underwent salvage operation and is free of recurrence five years and four months; the third, with isolated area classified as moderately differentiated pT1 adenoma, relapsed after 24 months, underwent operation redemption, showed K-Ras wild genotype, underwent chemotherapy and immunotherapy dying after five years with widespread metastatic disease; the primary resection was in the posterior wall and the recurrence in anterior wall.

Sometimes, in search of a better quality of life can happens under-treating and decreasing survival. But the bad developments reported above was the result of under-treatment or aggressive tumor behavior? It is known from the literature that the more delayed the diagnosis, more extensive operations and worse prognosis are present.

Another aspect is that when there is recurrence after TEM, reoperation in done in more advanced stages, as happened with two patients. They were pT1N0 and were operated as pT3N0 in the rescue. The

area of early recurrence of rectal cancer treated by local excision can be limited within the mesorectal fascia, rather than on the pelvic wall - as is usually seen in relapses after conventional surgery - which can lead to the rescue operation technically less complex²⁸. This is what can be seen in Figure 5, the wall recurrence more limited than the organ in pelvic space.

In the first two cuts, no tumor, one can observe the presence of a silver clip of the previous operation, in the third, there is clearly the presence of a polypoid lesion in the mucosa of 5 mm and a whitish compromising the whole wall thickness (pT3N0 tumor) in the quarter, the absence of tumor in the perirectal fat.

However, it is often found locally advanced disease, requiring en bloc resection of adjacent pelvic organs. Between 56% to 100% of patients with local recurrence after resection, the classical operation, redemption will be made as appropriate²⁸. Importantly, it can not provide the same result as the initial treatment classic. Rate of disease-free survival between 20% and 53% have been reported. It has also been reported that there is reduced survival if the resection is delayed beyond the exact timing of clinical recurrence, and if the local excision specimen has adverse histological findings. This again emphasizes the importance of early rectal cancer staging and choice of appropriate treatment, since the histology is known^{7,19}.

If you compare to the three cases, the incidental carcinoma should theoretically have evolved better than the other two. Would it have been done in this patient a total mesorectal excision or adjuvant radiotherapy (overtreatment) would have been different outcome? What we have not performed a total mesorectal excision in pT1 tumor and there was surprise appearance of liver metastasis after five years? A radical operation also does not provide 100% cure for pT1 tumors²⁴.

Bach et al.² conducted a multicenter study, 20 centers in English and a Belgian, using a selection of well established, based on the risk spectrum, ie, tumors smaller than 4 cm, well differentiated, without invasion angiolinfatica and invading only the top third of the submucosa. Could conclude that the probability of risk of lymph node invasion is directly related to depth of invasion and that those low-risk lesions is approximately 3%, which authorizes the implementation of TEM alone. For lesions type T2N0 Sm2/Sm3 and considered high risk, the probability of lymph node involvement increases geometrically (ref. simon bach². These patients had inferior treatment to be submitted only if the TEM. It is, therefore, doubt would benefit if all of these patients undergo neoadjuvant radiotherapy. But how to do it is often the best planning is established retrospectively, once the tumor has been removed and staging confirmed?

Moreover, there remains the difficulty of the current methods available to establish safely staging these tumors. So, to answer these questions by Bach and colleagues initiated a prospective randomized study called CRUK/09/032: TREC (transanal endoscopic microsurgery and Radiotherapy in Rectal Cancer Early) that started in January 2010. It's a randomized study comparing the standard surgery total mesorectal excision with this new protocol SCPRT (Short Course Preoperative Radiotherapy) and delayed local resection by TEM. The results will be presented in two years.

In fact, they altered the concept of offering approach preoperatively to patients with early tumors selected a short course of radiotherapy followed by a TEM macrobiopsy eight to ten weeks. Patients who have good response to radiation are observed, the other is offered conversion to total mesorectal excision. Bujko et al.⁴ recently reported data from a small series with similar treatment protocol - preoperative radiotherapy and local resection of rectal cancer with Immediate radical surgery for patients who did not respond.

Adjuvant treatment after local resection can be appropriate treatment for small early rectal tumors (T1), with no adverse histological features (with Sm2/Sm3 angiolymphatic) or patients with T2 invading the muscularis propria. Nine patients in this series, diagnosed with high risk received adjuvant post-MET, by the arguments given above, with encouraging results. Some work with a limited number of cases showed that the survival of rectal cancer classified as T2 after local excision combined with radiochemotherapy is equivalent to the treatment of T1 after local excision alone. The results of larger studies (CALGB8984), in which patients with T1 underwent only local excision was acceptable only for those at low risk, but unacceptable to the top. Patients with small rectal tumors treated with local excision may benefit from adjuvant treatment to high-risk histopathological parameters are present

In a recent provocative study, Habr-Gama et al.⁹, investigating the role of radiochemotherapy in nonoperative treatment of rectal cancer, showed that it can for itself be curative in certain circumstances. These data corroborate those of other studies showing that a complete pathological response to preoperative chemoradiation is associated with improvement in local control of recurrence and survival.

There is a trend toward improved local control with adjuvant therapy after local resection of T1. This suggests an important consideration for patients with negative surgical margins and favorable histological parameters that traditionally are not treated with adjuvant therapy.

Not just because we can realize TEM we should

do it always and in all patients. This prerogative should be thoroughly discussed with patients.

A better preoperative staging, techniques and highly sensitive molecular markers are needed to define which early rectal cancers require high-risk adjuvant or neoadjuvant.

The truth lies in the future. With a better understanding of the molecular behavior of these tumors it can delineate individualized treatment based on tumor biology.

CONCLUSION

Transanal endoscopic microsurgery may be currently considered the gold standard in rectal resection site, with encouraging results in selected cases of early rectal tumors at low risk.

REFERENCES

- Association of Coloproctology of Great Britain and Ireland. Guidelines for the Management of Colorectal Cancer (3rd edn). 2007. <http://www.library.nhs.uk/theatres/Viewresource.aspx?resID=31479>.
- Bach SP, Hill J, Monson JR, Simson JN, Lane L, Merrie A, Warren B, Mortensen NJ. A predictive model for local recurrence after transanal endoscopic microsurgery for rectal cancer. *Br J Surg*. 2009 Mar;96(3):280-90.
- Bretagnol F, Merrie A, George B, Warren BF, Mortensen NJ. Local excision of rectal tumours by transanal endoscopic microsurgery. *Br J Surg*. 2007 May;94(5):627-33.
- Bujko K, Richter P, Kołodziejczyk M, Nowacki MP, Kulig J, Popiela T, Gach T, Oledzki J, Sopyło R, Meissner W, Wierzbiński R, Polkowski W, Kowalska T, Stryczyńska G, Paprota K. Preoperative radiotherapy and local excision of rectal cancer with immediate radical re-operation for poor responders. *Radiother Oncol*. 2009 Aug;92(2):195-201.
- Day DW, Jass JR, Price AB, Shepherd NA, Sloan JM, Talbot IC et al. Epithelial tumours of the large intestine. In *Morson and Dawson's Gastrointestinal Pathology* (4th edn). Blackwell Science: Oxford, 2003; 551-609.
- Douglass HO Jr, Moertel CG, Mayer RJ, Thomas PR, Lindblad AS, Mittleman A, Stablein DM, Bruckner HW. Survival after postoperative combination treatment of rectal cancer. *N Engl J Med*. 1986 Nov 13;315(20):1294-5.
- Friel CM, Cromwell JW, Marra C, Madoff RD, Rothenberger DA, Garcia-Aguilar J. Salvage radical surgery after failed local excision for early rectal cancer. *Dis Colon Rectum* 2002; 45: 875-879.
- Frykholm GJ, Glimelius B, Pahlman L. Preoperative or postoperative irradiation in adenocarcinoma of the rectum: final treatment results of a randomized trial and an evaluation of late secondary effects. *Dis Colon Rectum*. 1993 Jun;36(6):564-72.
- Habr-Gama A, Perez RO, Nadalin W, Sabbaga J, Ribeiro U Jr, Silva e Sousa AH Jr, Campos FG, Kiss DR, Gama-Rodrigues J. Operative versus nonoperative treatment for stage 0 distal rectal cancer following chemoradiation therapy: long-term results. *Ann Surg*. 2004 Oct;240(4):711-7.
- Haggitt RC, Glotzbach RE, Soffer EE, Wruble LD. Prognostic factors in colorectal carcinomas arising in adenomas: implications for lesions removed by endoscopic polypectomy. *Gastroenterology*. 1985 Aug;89(2):328-36.
- Katherine Kahn DVM. Transanal Endoscopic Microsurgery may be preferable to Total Mesorectal Resection for some Rectal Cancer. SAGES 2006: Abstract S049. Presented April 29, 2006.
- Kikuchi R, Takano M, Takagi K, Fujimoto N, Nozaki R, Fujiyoshi T, Uchida Y. Management of early invasive colorectal cancer. Risk of recurrence and clinical guidelines. *Dis Colon Rectum*. 1995 Dec;38(12):1286-95.
- Kreissler-Haag D, Schuld J, Lindemann W, König J, Hildebrandt U, Schilling M. Complications after transanal endoscopic microsurgical resection correlate with location of rectal neoplasms. *Surg Endosc*. 2008 Mar;22(3):612-6.
- Krook JE, Moertel CG, Gunderson LL, Wieand HS, Collins RT, Beart RW, Kubista TP, Poon MA, Meyers WC, Mailliard JA. Effective surgical adjuvant therapy for high-risk rectal carcinoma. *N Engl J Med*. 1991 Mar 14;324(11):709-15.
- Kudo S. Endoscopic mucosal resection of flat and depressed types of early colorectal cancer. *Endoscopy*. 1993 Sep;25(7):455-61.
- Lamont JP, McCarty TM, Digan RD, Jacobson R, Tulanon P, Lichliter WE. Should locally excised T1 rectal cancer receive adjuvant chemoradiation? *Am J Surg*. 2000 Dec;180(6):402-5.
- Lamont JP, McCarty TM, Digan RD, Jacobson R, Tulanon P, Lichliter WE. Should locally excised T1 rectal cancer receive adjuvant chemoradiation? *Am J Surg*. 2000 Dec;180(6):402-5.
- Maslekar S, Beral DL, White TJ, Pillinger SH, Monson JR. Transanal endoscopic microsurgery: where are we now? *Dig Surg*. 2006;23(1-2):12-22.
- Mellgren A, Sirivongs P, Rothenberger DA, Madoff RD, Garcia-Aguilar J. Is local excision adequate therapy for early rectal cancer? *Dis Colon Rectum*. 2000 Aug;43(8):1064-71.
- Moraes RS, Buess G, Campos ACL, Malafaia O, Marinho Jr. CH, Coelho JCU. Transanal Endoscopic Microsurgery in the treatment of superficial rectal cancer. *ABCD Arq Bras Cir Dig*. 2002; 15(1):36-39.
- Moraes RS, Campos ACL, Telles JE, Coelho JCU. Microcirurgia endoscópica transanal (TEM) no contexto da cirurgia minimamente invasiva para o tratamento dos tumores do reto. *ABCD Arq Bras Cir Dig*. 2003;16:3-5.
- Moraes RS, Ferrarini DD, Telles JE, Scaccia E, Moura G. Ressecção oncológica minimamente invasiva de tumor carcinóide do reto por microcirurgia endoscópica transanal (TEM) [resumo]. In: *GASTREN 2004. Recife: Anais da VI Semana do Aparelho Digestivo 2004*. p.80.
- Moraes RS, Malafaia O, Telles JE, Trippia MA, Buess GF, Coelho JC. Transanal endoscopic microsurgery in the treatment of rectal tumors: a prospective study in 50 patients *Arq Gastroenterol*. 2008 Oct-Dec;45(4):268-74
- Moraes RS, Sobottka WH, Zanquet MC, Lima JHF, Morgenstern GA, Schlz GJ, Buess G, Malafaia O, Coelho JCU. Custo comparado da Microcirurgia Endoscópica Transanal (TEM) com a retossigmoidectomia anterior e com a amputação abdominoperineal do reto. *ABCD Arq Bras Cir Dig* 2007;20(3):150-3.
- Moraes RS, Zanquet MV, Sobottka WH, Lima JHF, Morgenstern GA, Malafaia O, Buess G, Coelho JCU. Qualidade de vida do paciente submetido a Microcirurgia Endoscópica Transanal (TEM). *ABCD Arq Bras Cir Dig* 2007;20(1):34-7.
- Morson BC, Bussey HJ. Predisposing causes of intestinal cancer. *Curr Probl Surg*. 1970 Feb:1-46.
- NIH consensus conference. Adjuvant therapy for patients with colon and rectal cancer. *JAMA*. 1990 Sep 19;264(11):1444-50.
- Sharma A, Hartley J, Monson JR. Local excision of rectal tumors. *Surg Oncol*. 2003 Jul;12(1):51-61.
- Stipa F, Burza A, Lucandri G, Ferri M, Pigazzi A, Ziparo V, Casula G, Stipa S. Outcomes for early rectal cancer managed with transanal endoscopic microsurgery: a 5-year follow-up study. *Surg Endosc*. 2006 Apr;20(4):541-5.
- Wagman RT, Minsky BD. Conservative management of rectal cancer with local excision and adjuvant therapy. *Oncology (Williston Park)* 2001; 15: 513-519, 524.