

SCOPINARO MODIFIED OPERATION FOR GASTRIC BANDING FAILURE*Operação de Scopinaro modificado na falha da banda gástrica*Bruno **ZILBERSTEIN**, Juliana Abbud **FERREIRA**, Marnay Helbo de **CARVALHO**, Cely **BUSSONS**,
Arthur Sérgio **SILVEIRA-FILHO**, Henrique **JOAQUIM**, Fernando **RAMOS**

From Gastromed - Zilberstein Institute, São Paulo, SP, Brazil.

ABSTRACT - Background - The laparoscopic adjustable gastric band is one of the most used techniques in Europe and Australia in the treatment of morbid obesity. It is safe procedure with very low mortality, but is not free of complications or failure, requiring reoperation in some cases. **Aim** - To evaluate the results of applying the technique of modified Scopinaro, failure of the application of adjustable gastric band. **Method** - Was used the technique for laparoscopic Scopinaro without resection of the body and gastric antrum (Domene technique). With this procedure, 14 patients were operated, five females, aged between 24 and 68 years, BMI (body mass index) ranging from 35.3 to 55.2 kg/m². **Results** - Mean operative time was three hours. There were no complications during the operation. In the immediate postoperative period, all patients were fed back into the first day. Over the long term, 18 months later, showed a 68% loss of excess and resolution of type II diabetes and dyslipidemia and hypertension improved in all cases. **Conclusion** - The application of modified Scopinaro operation by laparoscopy in the rescue of adjustable gastric banding is the method that promotes weight loss and persistent satisfactory, through a small food restriction, accompanied by a high degree of satisfaction with tolerable side effects.

HEADINGS - Bileopancreatic diversion. Gastric bypass. Adjustable gastric band. Obesity.

Correspondence:Bruno Zilberstein
e-mail: brunozilb@uol.com.brSource of funding: none
Conflict of interest: noneReceived: 18/02/2011
Accepted for publication: 08/03/2011

DESCRIPTOR - Desvio biliar pancreático. Derivação gástrica. Banda gástrica ajustável. Obesidade.

RESUMO - Racional - A banda gástrica ajustável por videolaparoscopia é uma das técnicas cirúrgicas mais utilizadas na Europa e Austrália no tratamento da obesidade mórbida. É procedimento seguro, com muito baixa mortalidade, porém não é isento de complicações ou insucessos, com necessidade de re-operação em alguns casos. **Objetivo** - Avaliar os resultados da aplicação da técnica de Scopinaro modificada, na falha da aplicação da banda gástrica ajustável. **Método** - Utilizou-se a técnica de Scopinaro por videolaparoscopia sem ressecção do corpo e antro gástrico (técnica de Domene). Com este procedimento, foram operados 14 pacientes, sendo cinco do sexo feminino, com idade entre 24 e 68 anos, IMC (índice de massa corpórea) variando entre 35,3 a 55,2 kg/m². **Resultados** - O tempo operatório médio foi de três horas. Não houve complicações durante a operação. No pós-operatório imediato, todos os pacientes foram realimentados no primeiro dia. A evolução em longo prazo, 18 meses após, mostrou perda de 68 % do excesso e resolução da diabetes tipo II e dislipidemia e melhora da hipertensão em todos os casos. **Conclusão** - A aplicação da operação de Scopinaro modificada por videolaparoscopia no resgate da banda gástrica ajustável é método que promove perda de peso satisfatória e persistente, através de pequena restrição alimentar, acompanhada de alto grau de satisfação com efeitos indesejáveis toleráveis.

INTRODUCTION

The consequences of obesity, especially in its most advanced level, are obvious, such as reduction in the expectation and quality of life, psychosocial problems and a higher incidence of degenerative diseases^{14,22}. Obesity has become epidemic and public health problem throughout the world, without distinction of sex and age^{10,13}. The high failure rate in the conservative treatment includes increasing the disease in the surgical sphere^{4,21,24}.

The operation for the treatment of severe obesity has been employed for nearly half a century. It began in the 1950s with the operations causing malabsorption^{11,17}.

Among the wide variety of treatments developed and improved over this period are: adjustable gastric banding, gastroplasty with jejunal bypass - known

as gastric "bypass" in Roux-en-Y with and without ring device (Fobi-Capella) -, biliopancreatic diversion and duodenal diversion - Scopinaro technique.

Restrictive operations, such as adjustable gastric band, the weight loss can be smaller, especially in people who drink liquid foods and with high calories^{2,18}. Moreover, with this intervention may occur technical problems in regard to the durability, the prosthesis infection, extrusion and slip, factors that might lead to weight loss in smaller grades, or to the need to remove the adjustable gastric band^{3,18}.

Based on the analysis of clinical and psychological aspects involved, the indication for surgical treatment aims to reduce obesity-related comorbidities (hypertension, arthropathy, sleep apnea, hernia, diabetes, hyperlipidemia) and reduction of psychosocial problems involved.

The biliopancreatic diversions act less in the intake of foods and more by reducing the absorption of ingested nutrients¹². Are considered to be more efficient in regard to loss of excess weight, but its side effects are recognized as a limiting factor. The weight loss tends to stabilize within a year and the rate of serious surgical complications is generally low^{19,20}.

In order to simplify the procedure proposed by Scopinaro, Domene in our country, has proposed a technical modification and tactical biliopancreatic shunt by laparoscopy without the need for removal of the body and gastric antrum with satisfactory results in the short and long term^{6,9}.

When it is necessary a reoperation in patients who underwent adjustable gastric banding due to method failure, there may be some difficulties in dissection of the esophagogastric area compromising the use of other procedures, such as gastric bypass or vertical gastropasty. To avoid these technical difficulties, these

authors proposed the application of the biliopancreatic diversion of Scopinaro technique modified by Domene in reoperations for failure of the adjustable gastric band.

METHOD

With this procedure, 14 patients were operated on, nine men (64.3%) and five women (35.7%) aged between 24 and 68 years, BMI ranging between 35.2 and 55.2 kg/m². All had undergone previous surgery with adjustable gastric band, with failure in the loss of weight excess. In three (21.4%) patients the band was removed during the same operation and in the remaining patients it had been removed earlier due to complications such as erosion and migration. All procedures were performed by laparoscopy.

The operation consisted on dissection of the stomach in the transition corpus/fundus with oblique section with linear stapler. Then, the proximal gastric pouch was repaired with laminar drain, and passed to the lower abdomen, through an opening made in the mesocolon. The gastric stump was secured with sutures in the mesocolon. After identification of the ileocecal valve, was measured 80 cm proximal in the ileum marked with suture; another measurement with 170 cm in proximal jejunum was made, the jejunum was cut along its mesentery using linear stapler and, then, an anastomosis was made suturing proximal jejunum to the ileum site previously marked. The operation continued with the gastroenteric anastomosis, latero-lateral with 45 linear stapler. Finally was proceeded mesenteric closure (Figures 1 and 2).



FIGURE 1 - Trocars position

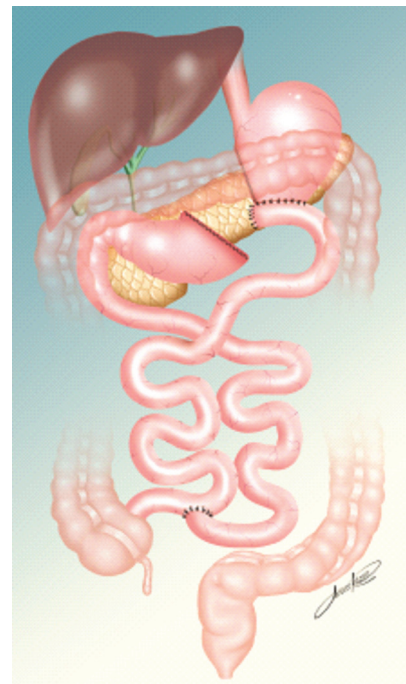


FIGURE 2 - Final aspect of the operation

RESULTS

Mean operative time was three hours. There were no complications during the operation. In the immediate postoperative period, all patients were fed back into the first day. They were encouraged to ambulate early and all were discharged from the second day after surgery. Soft diet was recommended for the first week, progressing then to paste fractionated food. The long-term follow-up, 18 months later, showed a 68% loss of weight excess, resolution of type II diabetes and dyslipidemia, and hypertension improved in all cases.

DISCUSSION

The operation of the adjustable gastric band is without doubt the operation among the lowest mortality surgical procedures for treating severe obesity. Although used for over 25 years, the results are dependent on patient adherence and monitoring done by the multidisciplinary team.

It must be considered the complications inherent with the use of a foreign body on a hollow viscera, like the band on the stomach. Moreover, the band is purely restrictive method without any metabolic component. Thus, there is substantial proportion of failure - around 30% or more -, in weight loss with this method.

In this situation it is necessary to consider other options techniques to be used. The literature describes application of other techniques in the salvage surgery for adjustable gastric band. Often strong adhesions between the liver and stomach at the esophagogastric junction occurs. This region becomes difficult to be manipulated and surgical approaches with other techniques may be impossible - such as gastropasty or vertical operation Fobi-Capella.

Thus the intention of this study was to analyze the immediate and long term results with the application of the modified technique of laparoscopic Scopinaro on failure of adjustable gastric band.

As already described, there were no intraoperative or postoperative complications in the immediate postoperative period (30 days). The oblique transection of the stomach deviated the dissection of the esophagogastric junction and also of adhesions in this region. This procedure greatly facilitated the operation, done in a "non operated territory".

This probably reflected the absence of major complications and discharged within 48 hours. The evolution of the medium and long term also show the safety of the procedure.

There was a significant weight loss, from 55% to 68%^{8,16}. with significant improvement in comorbidities and disappearance of type II diabetes in all cases.

Because of the jejunal loop of 80 cm, only four

patients had diarrhea and bad smell flatulence, dependent on the intake of fatty foods.

Nevertheless, undesirable effects were well tolerated and to date all patients have maintained the weight achieved after surgery, with a high degree of satisfaction^{1,7,23}.

Specific deficiencies in the late follow-up of biliopancreatic diversion are found from 1.5% to 14.5% of patients in relation to low vitamin A, D, K, iron, folic acid, calcium and protein. To avoid such complications, it is suggested systemic use (early years) of proton pump inhibitor, calcium and vitamin supplement, with daily minimum intake of 100g of protein per day, avoid to eat fat and blood analysis every six months for monitoring^{6,15}.

The bileopancreatic derivation has been increasingly accepted because it allows a small restrictive gastric pouch with a capacity of 500 ml volume and weight loss that is independent of the quantity and quality of food ingested, besides, provide a reduction in the absorption of starch and fat⁵.

CONCLUSION

The application of modified Scopinaro operation by laparoscopy in the rescue of adjustable gastric banding is method that promotes persistent weight loss, well tolerated and with a high degree of satisfaction with tolerable side effects.

REFERENCES

1. Ardelt-Gattinger,E; Hofmann,I; Angermann,E et al.-Addictions? Role after bariatric surgery. *Obes Surg* 2001;11:377.
2. Buchwald H. The future of bariatric surgery. *Obes Surg* 2005; 15: 598-605
3. Dixon JB, O'Brien PE. Selecting the optimal patient for LAP-BAND placement. *The American Journal of Surgery* 2002; 184: 175-205.
4. Doldi SB, Micheletto G, Lattuada E, et al. - Adjustable gastric band: 5-year experience. *Obes Surg*, 2000, 10:17. 9.
5. Doldi,SB; Perrini,MM; Mozzi,E- Management of biliopancreatic diversion complications. *Obes Surg* 2001.
6. Domene CE, Volpe P, Puzzo DB, Pimentel MPL, Camargo RB. Derivação Biliopancreática Com Preservação Gástrica Videolaparoscópica Para Tratamento da Obesidade Mórbida. *Rev bras videocir* 2005;3(3): 143-151.
7. Ferraz EM, Arruda PCL, Ferraz AAB, Albuquerque AC, Leão CS. Tratamento cirúrgico da obesidade mórbida. *Rev Col Bras Cir* 2003; 30(2): 98-105.
8. Fobi,MAL; Lee,H; Igwe,D et al.- Transected silastic ring vertical banded bypass with jejunal interposition, a gastrostomy and a gastrostomy site marker (Fobi pouch operation). IN Dietel,M & Cowan Jr,GSM, ed, FDCcommunications Inc, Canada, 2000:203-26.
9. Hauri P, Steffen R, Ricklin T et al. - Treatment of morbid obesity with the Swedish adjustable gastric band (SAGB): complication rate during 12-month follow-up period. *Surgery*, 2000, 127: 484.
10. James WP. The epidemiology of obesity: the size of the problem. *J Intern Med*. 2008;263(4):336-52.
11. Kremen AJ, Linner JH, Nelson CH. An experimental evaluation of the nutritional importance of proximal and distal small intestine. *Ann Surg* 1954;140:439-48.

12. Manlio Basilio Speranzini, Claudio Roberto Deutsch, Osmar Kenji Yagi, Manual de Diagnóstico e Tratamento para o residente de Cirurgia, Atheneu, 2009;938.
13. Monteiro CA, Conde WL, Popkin BM. Is obesity replacing or adding to undernutrition? Evidence from different social classes in Brazil. *Public Health Nutr.* 2001;5(1A):105-12.
14. O'Brien PE, Brown W, Dixon JB. Obesity, weight loss and bariatric surgery. *Med J Aust.* 2005;183(6):310-4
15. Ritchie,JD- Biliopancreatic diversion- postoperative management, challenges, experience with 198 cases over seven years. *Obes Surg* 2001; 11:406.
16. Scopinaro,N; Gianetta,E; Civalleri,D et al.- Biliopancreatic by-pass for obesity: initial experience in man. *Br J Surg* 1979;
17. Scott HW Jr, Dean RH, Shull HJ. Results of jejunoileal bypass in two hundred patients with morbid obesity.*Surg Gynecol Obstet* 1977;145:661-73.
18. Sjöström L, Lindroos AK, Peltonen M, Torgerson J, Bouchard C, Carlsson B, et al.Lifestyle, Diabetes, and Cardiovascular Risk Factors 10 Years after Bariatric Surgery. *N Engl J Med* 2004, 351:2683-2693.
19. Szego,T; Garrido Jr,AB; Matsuda,M et al.- Laparoscopic Roux en Y gastric bypass with silastic ring in the treatment of morbid obesity: early results and comparison to technique without silastic ring. *Obes Surg* 2000; 11:439.
20. Viachos O,I; Stergiou,T; Nead,N et al.- Psychological factors and patient motives in relation to BMI reduction in morbidly obese patients following bariatric surgery. *Obes Surg* 2001; 11:378.
21. Weiss HG, Nehoda H, Labeck B et al. - Treatment of morbid obesity with laparoscopic adjustable gastric banding affects esophageal motility. *Am J Surg,* 2000, 180:47
22. Wolf AM, Falcone AR, Kortner B, Kuhlmann HW. Baros: an effective system to evaluate the results of patients after bariatric surgery. *Obes Surg.* 2000;10(5):445-50.
23. Zilberstein B Pajeccki D; De Brito AC; Gallafrio ST; Eshkenazy R; Andrade CG – Topiramate after Adjustable Gastric banding in patients with Binge eating and Difficulty losing weight. *Obesity Surgery* 2004; 14: 802-5.
24. Zilberstein B, Brito ACG, Joaquim HDG, Carballo MG. Banda gástrica com desvio jejunoileal: nova opção técnica em cirurgia bariátrica. *ABCD Arq Bras Cir Dig* 2010; 23(2): 105-7.