

ARTERY RECONSTRUCTION IN LIVER TRANSPLANTATION: THE BEST RECONSTRUCTION OF RIGHT HEPATIC ARTERY VARIATION

Reconstrução arterial no transplante hepático: a melhor reconstrução para variação da artéria hepática direita

Wellington **ANDRAUS**, Luciana BP **HADDAD**, Liliana **DUCATTI**, Rodrigo B **MARTINO**,
Vinicius Rocha **SANTOS**, Luiz Augusto C **D'ALBUQUERQUE**

From Liver Transplant Unit, Gastroenterology Department, Clinical Hospital of São Paulo University, School of Medicine, São Paulo, SP, Brazil.

ABSTRACT – Introduction – Variations on the anatomy of the hepatic artery are common, with incidence of 20–50%. In liver transplantation, back-table reconstruction is often necessary for an easier and prompt arterial anastomosis and so, the use of arterial patches has been related to lower the incidence of complications. However, when a right hepatic artery variation from the superior mesenteric artery is present, the reconstruction occasionally produces twisting and flow problems. **Methods** - Is described a surgical alternative for right hepatic artery variation reconstruction using a Carrel-patch from the superior mesenteric artery. The patch is anastomosed with the splenic artery stump to allow vertical orientation and improve blood flow. Results: Among 120 liver transplants, four consecutive cases of right hepatic artery variation were reconstructed using this technique. All of them showed good flow and patency in postoperative period. **Conclusion** - The proposed technique proved to be an interesting alternative for the reconstruction of right hepatic artery variation in liver transplantation.

HEADINGS - Laparoscopic surgery. Inguinal hernia. Surgical mesh.

Correspondence:

Wellington Andraus,
e-mail: wellington@usp.br;
wandraus@terra.com.br

Financial source: none
Conflicts of interest: none

Received for publication: 07/09/2012
Accepted for publication: 15/01/2013

DESCRIPTORES - Laparoscopia. Hérnia Inguinal. Tela cirúrgica.

RESUMO – Introdução - Variações na anatomia da artéria hepática são comuns, com incidência de 20–50%. No transplante hepático, reconstruções durante a operação de bandeja são frequentemente necessárias para proporcionar anastomoses arteriais adequadas. O uso de "patch" é frequente, visando reduzir a incidência de complicações. Entretanto, quando está presente a variação da artéria hepática direita, ramo da artéria mesentérica superior, a reconstrução ocasionalmente produz torções e problemas de fluxo. **Métodos** – Descreve-se uma técnica cirúrgica alternativa para reconstrução da variação da artéria hepática direita usando um "patch de Carrel" da artéria mesentérica superior. O "patch" é anastomosado no coto da artéria esplênica permitindo orientação vertical e bom fluxo sanguíneo. **Resultados** - Entre 120 transplantes hepáticos, quatro casos consecutivos de variação da artéria hepática direita foram reconstruídas utilizando essa técnica. Todos eles apresentaram patência e bom fluxo no pós-operatório. **Conclusão** - A técnica proposta mostra-se interessante método alternativo para reconstrução da variação da artéria hepática direita no transplante hepático.

INTRODUCTION

In the general population, anatomic variation of hepatic arteries ranges from 20 to 50% in different series^{4,11,13,23}. Since the original paper done by Michels²⁰, several studies have followed him and developed classification systems for the anatomic variants of hepatic arteries^{1,10,12,13,17}. As a consequence, screening for these variations and a search for vascular reconstruction techniques to optimize the irrigation of the biliary tree and liver graft have taken place¹⁶. Indeed, increased knowledge on three-dimensional anatomical position of these vessels and technological progress in vascular reconstruction have led to the development of techniques aiming to reestablish liver blood supply^{9,18,21,27}. Furthermore, interventional radiological studies have shown that vessel position is very important to the rheological behavior of several anatomical variants and to the reconstructions

performed¹⁰. Thus, quality of reconstruction is essential to prevent arterial thrombosis that ultimately leads to graft loss.

In anatomical variations, when a replaced or accessory right hepatic artery (R/A-RHA) from the superior mesenteric artery exists, the reconstruction anastomosing the superior mesenteric artery with the celiac trunks occasionally produces twisting and flow problems. Therefore these authors attempted to develop a technical surgical alternative for R/A-RHA reconstruction to allow vertical orientation and benefit blood flow. This proposition was successful in attending these requirements and, in the authors point of view, is the best modality for reconstruction of these anatomical variations.

TECHNIC

First, the anatomical right hepatic artery is identified from the superior mesenteric artery. Then, liver arteries are carefully dissected while maintaining the integrity of the superior mesenteric artery branch to the liver (which often has a small diameter). Further, the small R/A-RHA branches to the pancreas are tied and sectioned to expose the artery to the liver.

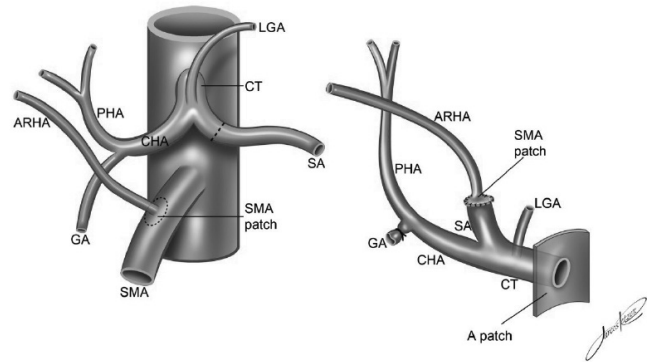
A small trunk of the splenic artery is preserved to perform anastomosis with a patch from the superior mesenteric artery. A small splenic artery length is sufficient because the R/A-RHA's length is always enough to permit this anastomosis. As a bonus such a procedure allows simultaneous pancreas procurement, because there is no need for a long splenic or mesenteric artery stump.

Next is made the section of superior mesenteric artery (5 mm in length on each side of the hepatic branch) and then longitudinally is opened the opposite side of the cylinder, to prepare a "Carrel-patch" with a 5 mm radially to the artery ostium. The Carrel-patch is then adjusted to fit the ostium of the splenic artery by removing the excess of the superior mesenteric artery around the branch.

Then is placed the superior mesenteric artery Carrel-patch on the splenic artery, checking its length and three-dimensional orientation to perform anastomosis without tension or torsion. These conditions are crucial in order to maintain the best flow. Anastomosis is performed with polypropylene suture 7-0 and checked for permeability and integrity by injection of preservation liquid to perform a flow test (Figure 1).

When performing arterial anastomosis on the patient, the positions of the superior mesenteric artery Carrel-patch and the splenic artery are also verified to maintain vertical orientation of the hepatic branches and ensure their normal flow.

Hepatic blood flow is assessed by Doppler ultrasound (Doppler USG) on postoperative days 1 and 5.



GA – gastroduodenal artery; CHA – common hepatic artery; PHA – proper hepatic artery; CT – celiac trunk; LGA – left gastric artery; A patch – aortic patch

FIGURE 1 – Representation of an accessory right hepatic artery (ARHA) from the superior mesenteric artery (SMA), and a reconstruction using a superior mesenteric artery Carrel-patch with the splenic artery (SA)

This technique was successfully applied in four consecutive cases of R/A-RHA in liver transplantation among a total of 120 deceased donor transplants during the year 2010 by the same surgical team at the Department of Liver Transplantation, Hospital das Clínicas, Faculty of Medicine, University of São Paulo, SP, Brazil. Figure 2 shows a typical back-table R/A-RHA reconstruction. Was observed that the procedures, performed as described, facilitated subsequent arterial anastomosis on the recipient patients. After back-table reconstruction was found that the technique allowed a good flow of the preservation solution.

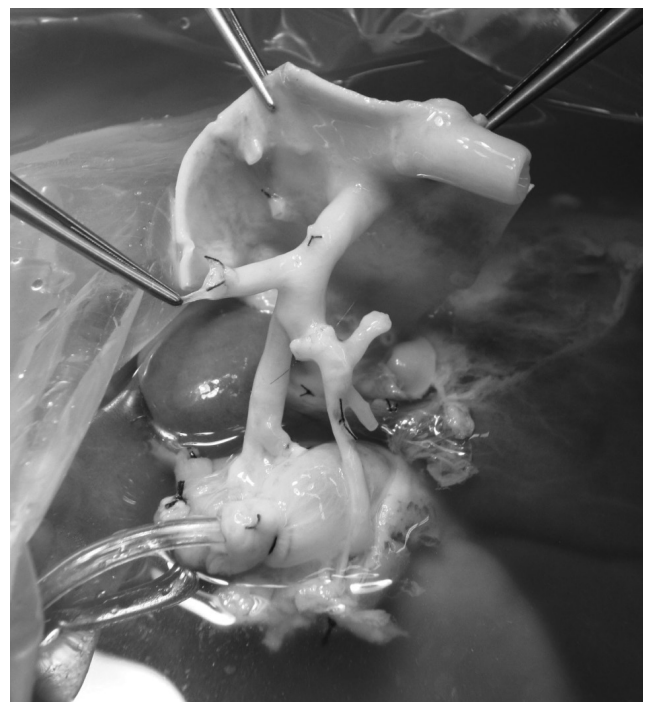

FIGURE 2 – Illustration of an accessory right hepatic artery (ARHA) reconstruction anastomosed with the splenic artery (SA), using a superior mesenteric artery Carrel-patch

Following liver transplant, hepatic blood flow status was checked by performing Doppler USG on postoperative days 1 and 5. This imaging assessment confirmed patency of all hepatic arterial branches, indicating that the reconstruction method employed herein allowed good blood flow.

DISCUSSION

The proposed technique using superior mesenteric artery Carrel-patch in cases of R/A-RHA is an easy and effective method for reconstruction and is capable of promoting a straight position of these vessels after anastomosis. Moreover, it utilizes a Carrel-patch, a method shown to be related to lower incidence of arterial thrombosis¹⁶. Further, this technique did not lead to torsion or kinking in the celiac trunk, and allowed the hepatic artery to form a "Y" shape with the R/A-RHA, similar to the natural bifurcation of the proper hepatic artery.

The high incidence of artery anatomical variations has required careful management to prevent injury or provide alternatives for reconstructions^{12,14,24}. The hepatic vascular anatomy has become particularly important given the increase in liver surgery and transplantation procedures^{1,4,6,11,18,26,28}. Because one of the most frequently encountered arterial variations is the presence of an R/A-RHA from the superior mesenteric artery, several authors have suggested alternatives to surgical reconstruction^{3,15,17,23,27}. However, no consensus exists about the best reconstruction technique in cases of R/A-RHA in liver transplant.

The authors think that the reconstruction technique using the splenic artery with a superior mesenteric artery Carrel-patch (Figure 1) has multiple advantages: 1) the caliber of the splenic artery is always bigger than the R/A-RHA, and it has always a good flow, especially in cirrhotic patients^{8,24}; thus a better flow arrives at its ostium and the anastomosis takes place with a bigger arterial caliber; 2) the use of superior mesenteric artery Carrel-patch allows an easier anastomosis without the need for branch caliber reduction; 3) when Carrel-patch is not used, the small caliber of the R/A-RHA creates a challenge for anastomosis because of the consequent disproportion with the caliber of the splenic artery; 4) in anatomical position, the celiac trunk turns posteriorly and the splenic artery is inferior and bottom-up in relation to the celiac trunk. After the aorta is divided and the celiac trunk is rectified, the splenic artery turns to the right, facing the accessory right hepatic branch, leading to a straight position after the anastomosis (Figure 2); 5) the length of the R/A-RHA is always sufficient to allow a short splenic stump anastomosis; 6) the anastomosis with the splenic artery leaves other options to perform the anastomosis at the recipient subject (aortal patch, celiac trunk, left gastric artery patch); 7) the celiac trunk remains in a straight position

after the reconstruction to perform the recipient anastomosis; 8) only a short stump length is needed for the splenic artery and the superior mesenteric artery, which allows a simultaneous pancreas procurement because the inferior pancreatic arteries are at distances greater than 1cm from the R/A-RHA in most cases⁷.

Although the use of splenic artery stump to anastomose R/A-RHA has been previously mentioned in some reports^{2,11,21,25} for R/A-RHA reconstruction, these authors are the first to describe the advantageous use of an superior mesenteric artery Carrel-patch technique in back-table vascular reconstruction. Carrel-patch is best known in vascular surgeries, but hepatic branch patches are also used in liver transplants during arterial anastomosis in the recipients, having been first described by Quinones-Baldrich et al.²². Furthermore, the use of "patches" liver transplantation is related to a low incidence of arterial complications⁵, and the suture outside the ostium is easier for the surgeon.

CONCLUSION

Preliminary results show that reconstruction of the R/A-RHA with the superior mesenteric artery Carrel-patch directly to the splenic artery stump is a good anastomosis alternative, preserving blood flow, placing the reconstruction in an ideal three-dimensional position and maintaining the celiac axis for the final donor-recipient arterial anastomosis. For all these reasons this technique is recommend for R/A-RHA back-table reconstructions.

REFERENCES

1. Abdullah SS, Mabrut JY, Garbit V, De La Roche E, Olagne E, Rode A, et al. Anatomical variations of the hepatic artery: study of 932 cases in liver transplantation. *Surg Radiol Anat.* 2006;28(5):468-73.
2. Abouljoud MS, Kim DY, Yoshida A, Arenas J, Jerius J, Malinzak L, et al. Impact of aberrant arterial anatomy and location of anastomosis on technical outcomes after liver transplantation. *J Gastrointest Surg.* 2005;9(5):672-8.
3. Allendorf JD, Bellemare S. Reconstruction of the replaced right hepatic artery at the time of pancreaticoduodenectomy. *J Gastrointest Surg.* 2009;13(3):555-7.
4. Bertevello PL, Chaib E. [Hepatic artery system variations correlated to split-liver surgery: anatomic study in cadavers]. *Arq Gastroenterol.* 2002;39(2):81-5.
5. Busuttil RW, Colonna JO, 2nd, Hiatt JR, Brems JJ, el Khoury G, Goldstein LI, et al. The first 100 liver transplants at UCLA. *Ann Surg.* 1987;206(4):387-402.
6. Chen H, Yano R, Emura S, Shoumura S. Anatomic variation of the celiac trunk with special reference to hepatic artery patterns. *Ann Anat.* 2009;191(4):399-407.
7. Cherian PT, Hegab B, Oliff SP, Wigmore SJ. The management of an accessory or replaced right hepatic artery during multiorgan retrieval: results of an angiographic study. *Liver Transpl.* 16(6):742-7.
8. D'Albuquerque LA, Gonzalez AM, Letrinda RF, Copstein JL, Larrea FI, Mansero JM, et al. Use of the splenic artery for arterial reconstruction in living donor liver transplantation. *Transplant Proc.* 2007;39(10):3202-3.

9. Di Benedetto F, Cautero N, De Ruvo N, Masetti M, Montalti R, Gerunda GE, et al. A new reconstruction of the accessory donor right hepatic artery with interposition of the SUPERIOR MESENTERIC ARTERY in liver transplantation. *Surgery*. 2006;140(5):835.
10. Donato P, Coelho P, Rodrigues H, Vigiá E, Fernandes J, Caseiro-Alves F, et al. Normal vascular and biliary hepatic anatomy: 3D demonstration by multidetector CT. *Surg Radiol Anat*. 2007;29(7):575-82.
11. Hevelke P, Grodzicki M, Nyckowski P, Zieniewicz K, Patkowski W, Alsharabi A, et al. Hepatic artery reconstruction prior to orthotopic liver transplantation. *Transplant Proc*. 2003;35(6):2253-5.
12. Hiatt JR, Gabbay J, Busuttil RW. Surgical anatomy of the hepatic arteries in 1000 cases. *Ann Surg*. 1994;220(1):50-2.13. Koops A, Wojciechowski B, Broering DC, Adam G, Krupski-Berdién G. Anatomic variations of the hepatic arteries in 604 selective celiac and superior mesenteric angiographies. *Surg Radiol Anat*. 2004;26(3):239-44.
14. Lafortune M, Denys A, Splenic arteryvuanet A, Schmidt S. [Anatomy of the liver: what you need to know]. *J Radiol*. 2007;88(7-8 Pt 2):1020-35.
15. Lee CC, Jeng LB, Li PC, Yang HR, Lu CW, Chen TH, et al. Innovative technique to reconstruct two branches of the right hepatic artery in living donor liver transplantation. *Transplant Proc*. 2008;40(8):2525-6.
16. Lee KK, Lee SK, Moon IS, Kim DG, Lee MD. Surgical techniques according to anatomic variations in living donor liver transplantation using the right lobe. *Transplant Proc*. 2008;40(8):2517-20.
17. Lopez-Andujar R, Moya A, Montalva E, Berenguer M, De Juan M, Splenic artery Juan F, et al. Lessons learned from anatomic variants of the hepatic artery in 1,081 transplanted livers. *Liver Transpl*. 2007;13(10):1401-4.
18. Melada E, Maggi U, Rossi G, Caccamo L, Gatti S, Paone G, et al. Back-table arterial reconstructions in liver transplantation: single-center experience. *Transplant Proc*. 2005;37(6):2587-8.
19. Merion RM, Burtch GD, Ham JM, Turcotte JG, Campbell DA. The hepatic artery in liver transplantation. *Transplantation*. 1989;48(3):438-43.
20. Michels NA. Newer anatomy of the liver and its variant blood supply and collateral circulation. *Am J Surg*. 1966;112(3):337-47.
21. Molmenti EP, Klein AS, Henry ML. Procurement of liver and pancreas allografts in donors with replaced/accessory right hepatic arteries. *Transplantation*. 2004;78(5):770-1.
22. Quinones-Baldrich WJ, Memsic L, Ramming K, Hiatt J, Busuttil RW. Branch patch for arterialization of hepatic grafts. *Surg Gynecol Obstet*. 1986;162(5):488-90.
23. Settmacher U, Haase R, Heise M, Bechstein WO, Neuhaus P. Variations of surgical reconstruction in liver transplantation depending on vasculature. *Langenbecks Arch Surg*. 1999;384(4):378-83.
24. Silveira LA, Silveira FB, Fazan VP. Arterial diameter of the celiac trunk and its branches. Anatomical study. *Acta Cir Bras*. 2009;24(1):43-7.
25. Splenic artery/splenic artery/one CV, De Carlis L, Rondinara GF, Colella G, Rossetti O, Slim AO, et al. Right hepatic artery replacement from superior mesenteric artery in combined liver-whole pancreas procurement. Technical problems and liver graft artery reconstruction. *Transplant Proc*. 1994;26(6):3537-9.
26. Takatsuki M, Chiang YC, Lin TS, Wang CC, Concejero A, Lin CC, et al. Anatomical and technical aspects of hepatic artery reconstruction in living donor liver transplantation. *Surgery*. 2006;140(5):824-8;
27. Xu X, Zheng SS. Variations and reconstruction of the hepatic artery in liver transplantation. *Hepatobiliary Pancreat Dis Int*. 2006;5(2):170-2.
28. Yoshida A, Okuda K, Splenic arterykai H, Kinoshita H, Aoyagi S. 3D anatomical variations of hepatic vasculature and bile duct for right lateral sector of liver with special reference to transplantation. *Kurume Med J*. 2008;55(3-4):43-53.